

Pneumomediastinum in patients with SARS-CoV-2 treated with non-invasive ventilation

Onn Shaun Thein ,^{1,2} Muhammad Niazi,¹ Abdisamad Ali,¹ Adeel Sahal¹

¹Respiratory Medicine, Sandwell and West Birmingham Hospitals NHS Trust, Birmingham, UK
²Institute of Inflammation and Aging, University of Birmingham, Birmingham, UK

Correspondence to
Dr Onn Shaun Thein;
shaunthein@gmail.com

Accepted 5 March 2021

SUMMARY

SARS-CoV-2, causing the pandemic COVID-19, has rapidly spread, overwhelming healthcare systems. Non-invasive positive pressure ventilation (NIV) can be used as a bridging therapy to delay invasive mechanical ventilation or as a standalone therapy. Spontaneous pneumomediastinum is rare and self-limiting, but there is an increased incidence documented in COVID-19. Here we document two cases of pneumomediastinum-related prolonged NIV therapy in severe COVID-19. Patient 1, a 64-year-old man, who developed symptoms after NIV therapy was weaned and survived. Patient 2, an 82-year-old woman, failed to improve despite NIV therapy, on investigation was found to have a pneumomediastinum. After review, the patient was placed on best supportive care and died 3 days later. We highlight the importance of recognising less common causes of deterioration in severe COVID-19 treated with NIV. In addition, pneumomediastinum in these cases may not always lead to poor outcomes.

BACKGROUND

SARS-CoV-2 is a virus that has caused the ongoing pandemic COVID-19 that originated in Wuhan, China and has spread rapidly across the globe. The threat to healthcare systems overwhelmed with critically unwell patients has led to adapting practices to meet the surge in demand. Non-invasive positive pressure ventilation (NIV) in the treatment of severe COVID-19 has shown benefit as a bridging therapy to invasive mechanical ventilation (IMV).

The increased incidence of spontaneous pneumothorax and pneumomediastinum in COVID-19 pneumonia has been documented throughout the pandemic, potentially being linked to worsening disease.¹ Pneumomediastinum in itself is a self-limiting, conservatively treated condition but has the potential to complicate management for those patients requiring NIV therapy for hypoxia. There have been recent case reports of pneumomediastinum in patients with COVID-19 pneumonia, all of whom survived.^{1–3} In one case, there were delays in diagnosis as deterioration was attributed to progression of disease. Prior to the widespread use of NIV in severe COVID-19, reports of pneumomediastinum from NIV were rare.^{4,5}

Here we report on two patients who developed pneumomediastinum as a complication of NIV therapy for the treatment of COVID-19. Our patients were given NIV therapy in a non-intensive care unit setting, where escalation of treatment to cardiovascular support, intubation and ventilation had been discussed and was not in the patient's best

interests. We wish to highlight the importance of considering pneumomediastinum and axial imaging in a deteriorating patient on NIV or IMV therapy.

CASE PRESENTATION

Patient 1

A 64-year-old man was admitted with a 2-week history of feeling tired and 'run-down' associated with shortness of breath and dry cough. He lived with his parents; his father died 4 days earlier with suspected COVID-19 pneumonia and his mother was unwell with respiratory tract symptoms.

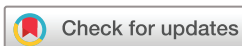His medical history included ulcerative colitis, rheumatoid arthritis and bilateral total knee replacements for osteoarthritis. He had no known drug allergies and regular medications consisted of mesalazine, prednisolone, alendronate, calcium/vitamin D₃ supplement, co-dydramol, etanercept, methotrexate, folic acid and lansoprazole. He was independent of all daily activities and mobilised with two crutches. He did not smoke, had never used any recreational substance, his alcohol intake was within the recommended limits and body mass index (BMI) 26 kg/m².

On examination, his respiratory rate was 22 breaths/min; oxygen saturations 96% on 10L/min of oxygen via venturi; heart rate 92 beats/min and blood pressure 144/77 mm Hg. Chest auscultation revealed bilateral crackles, loudest in the middle zones. The rest of his physical examination was unremarkable. His ECG confirmed sinus tachycardia.

Treatment commenced with intravenous fluids and antibiotics (intravenous benzylpenicillin and oral clarithromycin) and prednisolone doubled to 20 mg once daily. Methotrexate was paused on admission. He was also randomised to the standard of care arm in the RECOVERY trial. He deteriorated on day 3 with a respiratory rate of 35–40 breaths/min and significant desaturation to 84%–88% on 15 L/min oxygen via non-rebreath mask. Awake proning was unsuccessful due to osteoarthritis and he was initiated on continuous positive airway pressure (CPAP).

Positive end expiratory pressure (PEEP) was started at 10 cmH₂O and 10 L/min oxygen, achieving an average tidal volume (V_t) of 430 mL. There was good response to CPAP therapy and on day 6, he tolerated long breaks from CPAP and PEEP reduced to 5 cmH₂O. CPAP was completely weaned on day 7 to 2 L/min supplemental oxygen via nasal cannula.

On day 8, the patient reported central chest tightness and ECG showed sinus tachycardia. Serial



© Author(s) (or their employer(s)) 2021. No commercial re-use. See rights and permissions. Published by BMJ.

To cite: Thein OS, Niazi M, Ali A, et al. *BMJ Case Rep* 2021;**14**:e241809. doi:10.1136/bcr-2021-241809

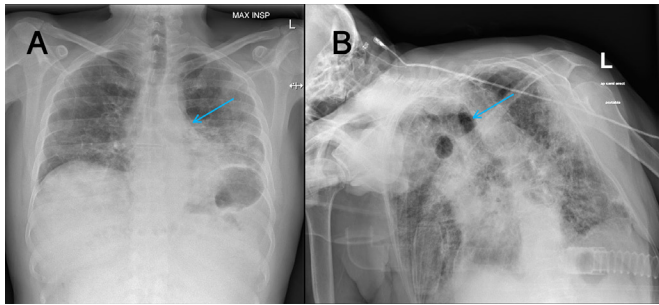


Figure 1 Chest radiographs, pneumomediastinum indicated by arrows. (A) Patient 1 and (B) patient 2 showing worsening bilateral infiltrates and pneumomediastinum with no evidence of obvious pneumothorax.

troponin I were 5 ng/L and 6 ng/L (reference range <5 ng/L). Chest X-ray (CXR) (figure 1A) followed by CT pulmonary angiogram confirmed multiple small locules of air in the anterior mediastinum in keeping with pneumomediastinum (figure 2). There were extensive bilateral patchy ground-glass abnormalities in both lungs in keeping with COVID-19 disease and no evidence of pulmonary embolism. The pneumomediastinum was treated conservatively.

Patient 2

An 82-year-old woman was admitted with a 2-week history of dry cough, fever, shortness of breath and general malaise.

No medical history or regular medications were reported with no drug allergies. She lived with her husband in a house, was independent of all the daily activities and worked part-time in a supermarket as a shop assistant. Her BMI was 27 kg/m².

On examination, she appeared comfortable; her respiratory rate was 17 breaths/min, oxygen saturations 97% on 15 L/min oxygen via a non-rebreathe mask, heart rate 99 beats/min and blood pressure 165/88 mm Hg. Chest auscultation revealed bilateral inspiratory crepitations with no evidence of wheeze or stridor.

The patient was treated with optimal medical care, including supplemental oxygen, intravenous fluids, antibiotics and prophylactic low molecular weight heparin; but despite this, she continued to deteriorate.

On day 6, oxygen saturations were 86% on 15 L/min oxygen via non-rebreathe mask and arterial blood gas showed worsening type 1 respiratory failure with respiratory alkalosis. CXR was consistent with worsening extensive bilateral infiltrates.

She was transferred to the respiratory ward for trial of CPAP; PEEP started at 10 cmH₂O and 10 L/min oxygen. She remained

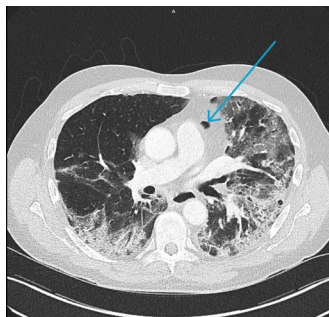


Figure 2 Axial CT slice of CT pulmonary angiogram from patient 1 with arrow demonstrating pneumomediastinum air locule.

Table 1 Baseline investigations for cases, including standard COVID-19 panel used by the NHS Trust

Blood test (units)	Case 1	Case 2	Reference range
Haemoglobin (g/L)	142	140	125–180
White cell count (10 ⁹ /L)	6.3	11.1	4.0–11
Neutrophils (10 ⁹ /L)		10.03	1.70–7.50
Lymphocytes (10 ⁹ /L)	0.52	0.58	1.0–4.5
Platelet count (10 ⁹ /L)	256	291	150–450
C reactive protein (mg/L)	210	86	<1
Sodium (mmol/L)	131	133	133–146
Potassium (mmol/L)	3.5	3.5	3.5–5.3
Urea (mmol/L)	5	6.4	2.5–7.8
Creatinine (μmol/L)	65	80	44–133
GFR (mL/min/1.73 m ²)	>90	60	>90
Albumin (g/L)	34	37	35–50
Alkaline phosphatase (IU/L)	81	129	20–130
ALT (IU/L)	129	16	<41
Troponin (ng/L)	15	18	<5
Ferritin (μg/L)	680	N/A	25–380
LDH (IU/L)	713	N/A	<225
COVID-19 RT-PCR	Positive	Positive	

ALT, alanine aminotransferase; GFR, glomerular filtration rate; LDH, lactate dehydrogenase; N/A, not available; NHS, National Health Service.

stable for the following 10 days, with an average Vt 680 mL and a fluctuating clinical response to therapy. On day 16, she deteriorated with significant respiratory distress (respiratory rate 40) and desaturations despite titrating her PEEP up to 14 cmH₂O. There was no evidence of mask leak, chest auscultation revealed bilateral air entry and the trachea was central. A portable CXR (figure 1B) showed worsening bilateral infiltrates and air locules in the mediastinum suggestive of pneumomediastinum. There was no obvious pneumothorax.

INVESTIGATIONS

Baseline investigations for both patients are shown in table 1. Chest radiographs taken at admission are shown in figure 1.

DIFFERENTIAL DIAGNOSIS

1. Progression of acute respiratory distress syndrome secondary to COVID-19 pneumonia.

Progression of disease has been widely documented in patients and both patients have several risk factors for poor outcomes. Locally, we have had several patients who have remained stable on CPAP therapy that deteriorated and passed away several days into their admission.

2. Pulmonary embolism.

COVID-19 disease is associated with an increased incidence in thromboembolic events, likely due to multiple underlying factors (including immobility and prothrombotic sepsis state).

3. Secondary bacterial infection.

TREATMENT

Both patients were discussed with the local cardiothoracic team, the multidisciplinary ward team and relatives. It was felt that conservative treatment would be the most appropriate treatment for patient 1.

Following her deterioration, further CPAP therapy was felt to be futile for patient 2. After discussion with her family and palliative care, she was started on end-of-life care with active symptom control.

OUTCOME AND FOLLOW-UP

Patient 1

He continued to make clinical improvement and was weaned off oxygen completely on day 10 and successfully discharged home on day 13. At 3-month follow-up, the patient is well and has not been readmitted.

Patient 2

She passed away peacefully 3 days after the decision to withdraw active COVID-19 treatment.

DISCUSSION

Our reports of pneumomediastinum related to COVID-19 pneumonia are not unique, and it has been previously documented as a complication of severe acute respiratory syndrome.⁶ The underlying mechanism is unknown, but may relate to increased diffuse alveolar damage ultimately causing alveolar rupture with resulting air leak leading to a pneumomediastinum.⁷ Previous case reports document spontaneous pneumomediastinum in both well and patients with chronic lung conditions. Mohan and Tauseen document spontaneous pneumomediastinum in a patient previously on home CPAP for sleep apnoea, but the patient was not routinely using this prior to admission or during admission.⁸ Pneumomediastinum from barotrauma is a theoretical complication of NIV, but there are no previous reports of this occurring. Neither of our patients developed a spontaneous pneumothorax, which is a well-documented complication of COVID-19 pneumonia.

NIV and IMV are used routinely in the treatment of severe COVID-19 pneumonia, with contemporary guidelines to commence PEEP at 10 cmH₂O.⁹ Following initial settings, PEEP is titrated to Vt (6–8 mL/kg) and patient comfort.¹⁰ Due to the underlying acute respiratory distress syndrome pathology, lung protective ventilation has been recommended, and the pressures and Vt that we have implemented are similar to that reported from international centres.¹¹ Our patients were treated in line with the British Thoracic Society guidelines. Neither patient had ongoing CPAP after pneumomediastinum was diagnosed. Patient 1 developed chest pain after prolonged CPAP therapy had finished, and patient 2 had deteriorated prior pneumomediastinum diagnosis. We do note that the recommended initial PEEP is higher than used in pulmonary oedema secondary to congestive cardiac failure (5 cmH₂O).¹²

Our patient setting is unique, as CPAP was used in patients as a ceiling of treatment, rather than as a bridging strategy to IMV. Consequently, our patients had a higher age compared with previous reports and remained on CPAP therapy for prolonged periods; for the treatment of cardiogenic pulmonary oedema, one would expect clinical improvement after 180 min of starting CPAP.¹³

In both cases, pneumomediastinum was treated conservatively as in previous reports, with patient 1 making a good recovery and patient 2 started on best supportive care. Post-discharge review of the cases felt that the development of pneumomediastinum was an incidental finding and did not contribute significantly to the clinical course of either patient. However, given the increasing numbers of patients with COVID-19 pneumonia now being considered for CPAP therapy, it is an important complication that should be considered if patients begin to deteriorate.

Learning points

- ▶ Consider alternative causes of acute deterioration in COVID-19 pneumonia and patients on non-invasive positive pressure ventilation therapy.
- ▶ Pneumomediastinum can be difficult to assess on a chest X-ray alone, further axial imaging may be required.
- ▶ Pneumomediastinum may not necessarily suggest poor outcome.

Acknowledgements The authors would like to thank the physicians, nurses and respiratory physiologists at the Respiratory Department of Sandwell and West Birmingham NHS Trust.

Contributors OST drafted and reviewed the manuscript. MN drafted the manuscript. AA drafted the manuscript and obtained the consent. AS reviewed the manuscript and case report.

Funding The authors have not declared a specific grant for this research from any funding agency in the public, commercial or not-for-profit sectors.

Competing interests None declared.

Patient consent for publication Next of kin consent obtained.

Provenance and peer review Not commissioned; externally peer reviewed.

This article is made freely available for use in accordance with BMJ's website terms and conditions for the duration of the covid-19 pandemic or until otherwise determined by BMJ. You may use, download and print the article for any lawful, non-commercial purpose (including text and data mining) provided that all copyright notices and trade marks are retained.

ORCID iD

Onn Shaun Thein <http://orcid.org/0000-0003-0524-9449>

REFERENCES

- 1 Zhou C, Gao C, Xie Y, *et al.* COVID-19 with spontaneous pneumomediastinum. *Lancet Infect Dis* 2020;20:510.
- 2 Goldman N, Ketheeswaran B, Wilson H. COVID-19-associated pneumomediastinum. *Clin Med* 2020;20:e91–2.
- 3 Pooni R, Pandey G, Akbar S. Broadening the differential: pneumomediastinum and COVID-19 infection. *BMJ Case Rep* 2020;13:e237938.
- 4 Dionisio P, Martins L, Moreira S, *et al.* Spontaneous pneumomediastinum: experience in 18 patients during the last 12 years. *J Bras Pneumol* 2017;43:101–5.
- 5 Johnson JN, Jones R, Wills BK. Spontaneous pneumomediastinum. *West J Emerg Med* 2008;9:217–8.
- 6 Chu CM, Leung YY, Hui JYH, *et al.* Spontaneous pneumomediastinum in patients with severe acute respiratory syndrome. *Eur Respir J* 2004;23:802–4.
- 7 Caceres M, Ali SZ, Braud R, *et al.* Spontaneous pneumomediastinum: a comparative study and review of the literature. *Ann Thorac Surg* 2008;86:962–6.
- 8 Mohan V, Tauseen RA. Spontaneous pneumomediastinum in COVID-19. *BMJ Case Rep* 2020;13:e236519.
- 9 NHS B. Guidance for the role and use of non-invasive respiratory support in adult patients with COVID-19 (confirmed or suspected), 2020. Available: <https://www.england.nhs.uk/coronavirus/wp-content/uploads/sites/52/2020/03/specialty-guide-NIV-respiratory-support-and-coronavirus-v3.pdf>
- 10 WHO. *Clinical management of severe acute respiratory infection (SARI) when COVID-19 disease is suspected (version 1.2)*, 2020.
- 11 Fan E, Beitler JR, Brochard L, *et al.* COVID-19-associated acute respiratory distress syndrome: is a different approach to management warranted? *Lancet Respir Med* 2020;8:816–21.
- 12 University Hospital of South Manchester R. Emergency department pathway, acute pulmonary oedema, 2011. Available: [https://www.rcem.ac.uk/docs/Local%20Guidelines_Audit%20Guidelines%20Protocols/12aiV.%20Acute%20pulmonary%20oedema%20\(treatment%20with%20CPAP\)%20\(University%20Hospital%20of%20South%20Manchester,%20Dec%202011\).pdf](https://www.rcem.ac.uk/docs/Local%20Guidelines_Audit%20Guidelines%20Protocols/12aiV.%20Acute%20pulmonary%20oedema%20(treatment%20with%20CPAP)%20(University%20Hospital%20of%20South%20Manchester,%20Dec%202011).pdf)
- 13 Maraffi T, Brambilla AM, Cosentini R. Non-Invasive ventilation in acute cardiogenic pulmonary oedema: how to do it. *Intern Emerg Med* 2018;13:107–11.

Copyright 2021 BMJ Publishing Group. All rights reserved. For permission to reuse any of this content visit <https://www.bmj.com/company/products-services/rights-and-licensing/permissions/>
BMJ Case Report Fellows may re-use this article for personal use and teaching without any further permission.

Become a Fellow of BMJ Case Reports today and you can:

- ▶ Submit as many cases as you like
- ▶ Enjoy fast sympathetic peer review and rapid publication of accepted articles
- ▶ Access all the published articles
- ▶ Re-use any of the published material for personal use and teaching without further permission

Customer Service

If you have any further queries about your subscription, please contact our customer services team on +44 (0) 207111 1105 or via email at support@bmj.com.

Visit casereports.bmj.com for more articles like this and to become a Fellow