

# Diversion proctocolitis and the problem of the forgotten rectum in inflammatory bowel diseases: A systematic review

Arianna Dal Buono<sup>1</sup>  | Michele Carvello<sup>2,3</sup> | David B. Sachar<sup>4</sup> |  
Antonino Spinelli<sup>2,3</sup> | Silvio Danese<sup>5</sup> | Giulia Roda<sup>1</sup>

<sup>1</sup>IBD Center, Department of Gastroenterology, Humanitas Research Hospital – IRCCS, Rozzano, Milan, Italy

<sup>2</sup>Colon and Rectal Surgery Division, Humanitas Research Hospital – IRCCS, Rozzano, Milan, Italy

<sup>3</sup>Department of Biomedical Sciences, Humanitas University, Pieve Emanuele, Milan, Italy

<sup>4</sup>Icahn School of Medicine at Mount Sinai, New York, New York, USA

<sup>5</sup>Gastroenterology and Endoscopy, IRCCS Ospedale San Raffaele and Vita-Salute San Raffaele University, Milan, Italy

## Correspondence

Giulia Roda, IBD Center, Department of Gastroenterology, Humanitas Research Hospital – IRCCS Via Manzoni 56, 20089, Rozzano, Milan, Italy.  
Email: [giuliaroda@gmail.com](mailto:giuliaroda@gmail.com)

## Abstract

**Background and aims:** Diversion proctocolitis (DP) is a non-specific mucosal inflammation arising in the defunctionalized colon and/or rectum following faecal diversion (colostomy, ileostomy). Differential diagnosis of DP from the underlying disease in patients with inflammatory bowel diseases (IBD) is often unclear. As a result, it might be difficult to undertake any specific treatment. We aimed to systematically review the literature evidence on DP in IBD patients.

**Methods:** For this qualitative systematic review, we searched PubMed, EMBASE and Scopus to identify all studies published until July 2021 including IBD patients affected by DP.

**Results:** Overall, 37 papers published between 1982 and 2021 were included. A total of 1.211 IBD patients were included: 613 UC (50.6%), 524 CD (43.3%), 66 IBD-unclassified (IBD-U) (5.4%), 8 unspecified patients (0.7%). Most patients with DP are asymptomatic, although inflammation is detectable in almost all patients with a rectal stump. Reduced short-chain fatty acids and an altered microbiome, may trigger mucosal inflammation and have been proposed as causing factors. An increased risk of developing cancer on DP has been reported in patients with a history of previous dysplasia/cancer.

**Conclusions:** The etiopathogenesis of DP is still unknown. The efficacy of mesalamine, corticosteroids or short-chain fatty acids has not been proven by randomized trials yet. Since the incidence of cancer of the rectal stump can reach 4.5 per 1.000 diverted patients-year, IBD patients undergoing subtotal colectomy with end-ileostomy should undergo close endoscopic surveillance, being eventually counseled for surgery with or without the restoration of the intestinal continuity.

## KEYWORDS

diversion, inflammatory bowel disease, rectal stump, short-chain fatty acids, surgical outcomes

This is an open access article under the terms of the Creative Commons Attribution-NonCommercial-NoDerivs License, which permits use and distribution in any medium, provided the original work is properly cited, the use is non-commercial and no modifications or adaptations are made.

© 2021 The Authors. United European Gastroenterology Journal published by Wiley Periodicals LLC on behalf of United European Gastroenterology.

## INTRODUCTION

Diversion proctocolitis (DP) is defined as a non-specific inflammation arising in the defunctionalized colon and/or rectum after a colostomy or an ileostomy with or without intestinal resection for various indications.<sup>1,2</sup>

The pathological entity was firstly named by Donald Glotzer in 1981.<sup>2</sup> DP occurs in almost all patients (89%–100%) after diversion surgery over a period of 3 months to 3 years,<sup>3,4</sup> although the majority of the patients with intestinal diversions remains asymptomatic.

In patients affected by inflammatory bowel diseases (IBD) undergoing diversion surgery for different indications and suffering from DP with various grades of severity distinguishing DP from the underlying IBD is a delicate matter.

In more detail, up to 70% of patients after diversion surgery for perianal and/or refractory Crohn's proctitis remain diverted, eventually undergoing colectomy within two years, even with an optimization of the postoperative treatment.<sup>5</sup> In patients with severe perianal Crohn's disease (CD) diversion becomes permanent in half of the cases.<sup>6</sup>

In acute severe ulcerative colitis (UC) refractory to medical treatment a subtotal colectomy with end ileostomy is the standard approach,<sup>7</sup> as the rectum is generally left in situ to avoid septic complications.

Staged surgery has been increasingly adopted for UC when colectomy is finally required for refractory disease, even on an elective basis, with delayed surgical management of the rectal stump.<sup>8,9</sup> As concerns IBD-type unclassified (IBDU), a staged surgery is wisely suggested before pouch reconstruction as histology has to be clearly defined.<sup>10</sup>

Overall, data for both UC and CD showed that 13% to 37% of patients are expected to end up with a diverted rectum, although only a few of them keep it permanently.<sup>11,12</sup>

On one hand, DP may occur at the rectal stump until completion proctectomy with or without ileal pouch-anal anastomosis is performed.<sup>13,14</sup> On the other hand, patients undergoing restorative proctocolectomy may experience diversion pouchitis: the corresponding inflammatory disorder affecting the ileal pouch.<sup>1</sup>

If completion proctectomy is not performed, the "forgotten" rectum can cause tenesmus, bleeding or mucous discharge with a decreased quality of life.<sup>11,14,15</sup>

Considering the increased risk of colorectal cancer that ranges from 1.5 to 2.4 times higher in UC than in the general population, increasing linearly after the 8th year of disease and being higher in patients with extensive colitis,<sup>16,17</sup> there is an unquestionable indication to completion proctectomy in this subgroup of patients.<sup>18</sup>

So far, data from literature on DP are mostly derived from small cohorts and have never been comprehensively reviewed. The purpose of our systematic review is to provide an exhaustive overview of the available data on DP in IBD patients.

## METHODS

This work was conducted in accordance with the Cochrane Handbook<sup>19</sup> and Preferred Reporting Items for Systematic Reviews and Meta-Analyses (PRISMA) recommendations for reporting of systematic reviews.<sup>20</sup>

### Data sources and search strategy

For this qualitative systematic review, we designed a comprehensive search strategy and searched PubMed/MEDLINE, Embase and Scopus up to July 2021 to identify eligible studies. A hand-search of abstracts from the annual meetings of Digestive Disease Week, the American College of Gastroenterology, the European Crohn's and Colitis Organization and the United European Gastroenterology Week up to 2021 was also employed.

The search query employed both an exhaustive list of keywords and index terminology whenever possible. The following text words and corresponding Medical Subject Heading/Entree terms were used: "diversion colitis," "diversion proctitis," "diversion proctocolitis," "inflammatory bowel disease," "rectal stump" and "colon/colonic stump." The Medline search strategy was: ((((((diversion proctitis) OR diversion colitis) OR diversion proctocolitis) OR diversion proctocolitis) OR rectal stump) OR colonic stump) OR colon stump) AND (((inflammatory bowel disease) OR Crohn's disease) OR "Colitis, Ulcerative"[Mesh]) OR Crohn). The full search strategy is available in the [Supplementary material](#).

No date or language filters were employed in the search. Literature search was independently performed and verified by two authors (ADB, GR).

### Inclusion and exclusion criteria

The inclusion criteria were: (a) studies including confirmed IBD patients with DP; (b) studies investigating at least one among epidemiology, etiopathogenesis, clinical presentation, endoscopic and histological findings of DP as well as treatment options and outcomes; (c) studies reporting complications of DP. No restriction on the type of study was applied. Full-text papers, conference abstracts and case reports were included. Studies on pediatric populations were excluded. All editorials, letters or review articles were excluded. Animal studies were excluded as recommended in the Cochrane Handbook of Systematic Reviews of Interventions.<sup>19</sup>

### Selection process, data extraction and quality assessment

Two authors (ADB, GR) independently screened the titles and abstracts yielded by the search. Full reports were obtained for all titles that appeared to meet the inclusion criteria or where there was any

uncertainty. Disagreements were resolved through collegial discussion. The reasons for excluding trials were recorded. When there were multiple articles for a single study, the latest publication was used. The selected papers/abstracts were reviewed for the following key issues: demographics, epidemiology, etiopathogenesis, type and indication of surgery, clinical presentation, endoscopic and histological findings of diversion colitis as well as treatment options, outcomes, and complications. The Newcastle-Ottawa Scale (NOS) score was used to assess the quality of nonrandomized clinical trials, while the Jadad score was adopted for randomized clinical trials.<sup>21,22</sup> The NOS score of 6 or higher identified high-quality studies, while scores of 4–5, and lower than 3 indicated moderate- and low-quality studies, respectively. A Jadad score of 3 or higher identified high-quality studies.

## RESULTS

The literature search revealed 661 publications: after excluding any duplicate, 425 were screened. After reviewing the title and abstract and, if necessary, the full publication, 388 records were rejected. After the reviewing process, a total of 37 publications met the inclusion criteria<sup>11,18,23–57</sup>: thirty-three full-text (89.2%)<sup>11,18,23,51,54,56</sup> and four abstracts (10.8%).<sup>52,53,55,57</sup> Figure 1 illustrates the selection process. All studies were single-center experiences, published between 1982 and 2021. The study design was as follows: two randomized studies (5.4%),<sup>30,46</sup> four prospective studies (10.8%),<sup>33,34,38,40</sup> 14 retrospective studies (37.9%),<sup>18,24,25,36,39,42,44,50,52–57</sup> and 17 case reports/series (45.9%).<sup>23,26,29,31,32,35,37,41,43,45,47,49,51,56</sup> Two papers were written in French<sup>34,35</sup> and one in German,<sup>28</sup> all remaining papers were written in English. Table 1 presents all the included studies. According to the NOS score, 12 studies were of high-quality

(32.4%),<sup>11,18,33,36,39,40,44,50,53,55,57</sup> one paper was of low quality,<sup>56</sup> and the remaining studies were moderate-quality studies (59.5%) (Table S1, supplementary material). A Jadad score of 4 was assigned to the randomized studies.<sup>30,46</sup>

A total of 1,211 IBD patients with an intestinal diversion (ileostomy and colostomy) were included: 613 UC (50.6%), 524 CD (43.3%), 66 IBD-unclassified (IBD-U) (5.4%) and 8 unspecified patients (0.7%). More than half of affected patients were female (607 [50.1%]), 539 were male (44.5%), and in 65 cases the gender was not specified (5.4%). The age of the included patients ranged from 16 to 86 years.

## Incidence and pathogenesis of DP in IBD

Five studies investigated the incidence of DP in IBD.<sup>18,28,33,50,54</sup> The incidence of DP in patients with pre-existing IBD ranged from 71.4% to 100%.<sup>18,28,33,50,54</sup> Post-operatively, a variable amount of patients (from 7.5% to 70%) concurrently developed DP and IBD in the diverted segment.<sup>18,50,54</sup> The earliest macroscopic deterioration of the diverted rectum could be observed after 2–3 months after index surgery.<sup>24,28,31,33</sup>

Four studies reported possible pathogenetic factors of DP.<sup>27,34,46,51</sup> The colonic epithelium is damaged due to a deficiency of nutrients derived from the anaerobic bacterial fermentation of starch and proteins by the flora, such as short-chain fatty acids (SCFAs), above all, butyric acid.<sup>46</sup> The lack of oxidative substrates prompts inflammation and damages cell tropism.<sup>46</sup> Anaerobes, especially Gram-positive rods and *Peptostreptococci*, were isolated in higher concentrations from swabs of the rectal/oostomy mucosa in the IBD group rather than in non-IBD diverted patients.<sup>46</sup> An overall diminished in vitro production of SCFAs of the isolated genera was

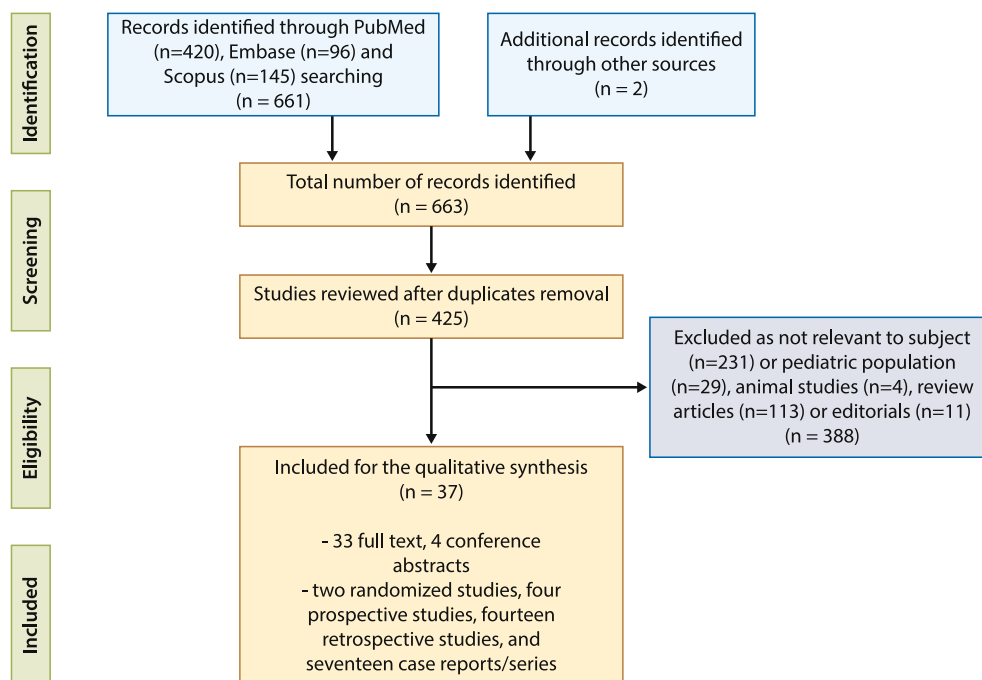


FIGURE 1 Preferred Reporting Items for Systematic Reviews flow diagram

**TABLE 1** Studies included in the analysis

Reference	Year	Study design	N <sup>a</sup>	UC	CD	IBD-U	Type of surgery/diversion	Investigated features
Lavery IC et al. <sup>23</sup>	1982	Case series	5	3	2		Subtotal colectomy	Cancer of rectal stump
Korelitz BI et al. <sup>24</sup>	1985	Retrospective	16		16		13 subtotal colectomies, 1 ileostomy, 2 colostomies	Incidence, clinical presentation, endoscopic features, re-anastomosis
Haas PA, Haas GP <sup>25</sup>	1988	Retrospective	13	13			Subtotal colectomy	Clinical presentation, endoscopy
Harig et al. <sup>26</sup>	1989	Case series	1		1		Sigmoid resection	Treatment with SCFAs
Neut C et al. <sup>27</sup>	1989	Case series	10	2	8		Ileostomy, colostomy	Endoscopic features, pathogenesis
Löhr HF et al. <sup>28</sup>	1989	Case report	2		2		Subtotal colectomy	Clinical presentation, endoscopy
Komorowski RA <sup>29</sup>	1990	Case report	2		2		Colostomy or ileostomy, with/without resection	Histology
Guillemot F et al. <sup>30</sup>	1991	Prospective, randomized, double-blind	4		4		Colostomy or ileostomy, with/without resection	Treatment with SCFAs
Yeong ML et al. <sup>31</sup>	1991	Case series	5	3	2		Subtotal colectomy	Histology
Warren BF et al. <sup>32</sup>	1993	Case series	15	15			Subtotal colectomy	Histology
Winslet MC et al. <sup>33</sup>	1994	Prospective, controlled	22		22		17 subtotal colectomies, 5 hemicolectomies	Histology, pathogenesis, re-anastomosis
Neut C et al. <sup>34</sup>	1995	Prospective	4				NS	Pathogenesis, treatment with SCFAs
Lavoine E et al. <sup>35</sup>	1996	Case series	18	18			Colectomy before ileo-rectal anastomosis	Histology
Geoghegan JG et al. <sup>36</sup>	1998	Retrospective	44		44		Right hemicolectomy or colonic resection	Cancer of rectal stump
Rice AJ et al. <sup>37</sup>	1999	Case report	1		1		Subtotal colectomy with ileostomy	Histology
Schauber J et al. <sup>38</sup>	2000	Prospective, double-blind, crossover	9	1	8		Subtotal colectomy with ileostomy	Treatment with SCFAs
Asplund S et al. <sup>39</sup>	2002	Retrospective	82	22	19	41	De-functioned colorectal resections	Histology
Winther KV et al. <sup>40</sup>	2004	Prospective, observational	42	29	13		Colectomy with terminal ileostomy	Clinical, endoscopic and histological features
Böhm G et al. <sup>11</sup>	2007	Retrospective	31	31			Subtotal colectomy	Complications
Borralho P et al. <sup>41</sup>	2008	Case report	1		1		Subtotal colectomy	Histology
Chetty R et al. <sup>42</sup>	2009	Retrospective	21	18	3		Completion proctectomy and colectomy	Histology
Ishihara S et al. <sup>43</sup>	2011	Case report	1		1		Ileostomy without resection	Complications
Munie S et al. <sup>44</sup>	2013	Retrospective	32	32			Subtotal colectomy	Complications
Gill P et al. <sup>45</sup>	2013	Case series	7	4	3		De-functioned colorectal resections	Histology

TABLE 1 (Continued)

Reference	Year	Study design	N <sup>a</sup>	UC	CD	IBD-U	Type of surgery/diversion	Investigated features
Luceri C et al. <sup>46</sup>	2016	Randomized, double-blind, placebo-controlled	4				Subtotal colectomy	Treatment with SCFAs
Matsumoto S et al. <sup>47</sup>	2016	Case report	1	1			Subtotal colectomy with ileostomy	Treatment
Nyabanga CT et al. <sup>48</sup>	2017	Case report	1	1			Diverting loop ileostomy	Complications, endoscopic treatment
Zundler S et al. <sup>49</sup>	2017	Case report	1		1		Diverting sigmoid ostomy	Treatment with SCFAs
Bettner W et al. <sup>50</sup>	2018	Retrospective	154	75	79		De-functioned colorectal resections	Cancer of the rectal stump
Tominaga K et al. <sup>51</sup>	2019	Case report	1	1			Ileostomy, pouch	Treatment with FMT
Katerji R et al. <sup>52</sup>	2019	Retrospective	19	11	1	7	Colostomy or ileostomy, with/without resection	Histology
Yzet C et al. <sup>53</sup>	2019	Retrospective	81		81		Colostomy or ileostomy, with/without resection	Complications
Ten Hove JR et al. <sup>18</sup>	2019	Retrospective	250	66	167	17	Subtotal colectomy (66.4%)	Complications, cancer of the rectal stump
Wasmann KA et al. <sup>54</sup>	2020	Retrospective	204	204			Subtotal colectomy	Incidence, endoscopy, histology
Kassim G et al. <sup>55</sup>	2020	Retrospective	27		27		Colostomy or ileostomy, with/without resection	Complications
Lane A et al. <sup>56</sup>	2021	Case report	1		1		Hemi-colectomy with loop ileostomy	Treatment
Fu Z et al. <sup>57</sup>	2021	Retrospective	79	63	15	1	NS	Histology

Abbreviations: CD, Crohn's disease; DP, diversion proctocolitis/pouchitis; FMT, fecal transplantation; IBD, inflammatory bowel disease; IBD-U, unclassified IBD; NS, not specified; SCFAs, short chain fatty acids; UC, ulcerative colitis.

<sup>a</sup>Exclusively IBD patients.

reported in comparison with non-diverted controls, with particular respect to butyric acid.<sup>27</sup> Tominaga et al. detected a decreased relative concentration of *Firmicutes* and increased *Proteobacteria* in the ileal pouch affected by diversion pouchitis of an UC patient.<sup>51</sup>

Additionally, a sustained high rate of cellular proliferation in CD patients with exclusion of the fecal stream can be observed.<sup>33</sup> This hyper-proliferation contrasts with the diversion-induced hypoplasia of non-IBD controls.<sup>33</sup>

## Clinical presentation

Symptoms of DP were assessed in 17 studies<sup>11,18,25,26,28,31,36,40,41,44,47,49,55,56</sup>; only a minority of the IBD patients (30%–40%) that develop DP experience symptoms.<sup>11,30,36,40,41,44</sup> Rectal bleeding and rectal pain were reported as DP symptoms in 13 reports<sup>11,18,25,26,29,31,40,41,44,48,49,56</sup> and 7 reports, respectively.<sup>11,18,25,40,41,44,49</sup> respectively. Overall, two cases of severe

active bleeding at presentation, requiring blood transfusion or endoscopic treatment, were described.<sup>11,48</sup> Additionally, tenesmus, lower abdominal pain and mucous discharge may be present.<sup>11,18,25,26,28,31,36,40,41,44,47,49,55,56</sup>

## Endoscopic and histological findings

The endoscopic/macroscopic evaluation of DP in IBD was reported in 16 studies.<sup>18,23,24,26,27,29,31,39,40,43,46,48,50,54,56</sup> Diffuse granularity, erythema, mucous plugs, reduction of the vascular pattern could be detected in the majority of the studies.<sup>18,23,24,26,27,29,31,39,40,43,46,48,50,54,56</sup> Erosions, aphthous-type lesions and ulcerations of various severity may also be associated.<sup>31,47,50,52,54</sup> Harig et al. proposed to score each of five abnormalities (e.g., erythema, edema, friability, granularity and erosions) as 0 (absent), 1 (mild) or 2 (severe), with a total sum ranging from 0 to 10.<sup>26</sup> The inflammation of DP tends to be most

**TABLE 2** Included studies investigating medical treatments

Reference	Year	Study design	N <sup>a</sup>	Intervention	Success rate	P	Outcome
Harig et al. <sup>26</sup>	1989	Case series	1	SCFAs enemas 60 ml/twice daily for two to three weeks  Two patients in maintenance for 6 months (60 ml twice weekly/daily)	1/1	NA	Endoscopic and histological healing  One CD patient included with good response to SCFAs
Guillemot F et al. <sup>30</sup>	1991	Prospective, double-blind	4	SCFAs enemas 60 ml/twice daily versus saline solution enemas, 14 days of treatment	Partial endoscopic response in 1 CD patient	NA	No endoscopic or histologic changes after SCFAs therapy
Neut C et al. <sup>34</sup>	1995	Prospective	4	SCFAs enemas 60 ml/twice daily for 14 days	No difference between the two groups concerning bacterial counts and species	NA	SCFAs enemas do not induce significant changes in the microbial flora
Schauber J et al. <sup>38</sup>	2000	Prospective	9	Treatment with SCFAs versus saline solution	Endoscopic improvement in 5/7 in SCFA group, 2/7 in the placebo group	NA	No superiority of SCFAs enemas over placebo
Luceri et al. <sup>46</sup>	2016	Randomized, double-blind, placebo-controlled	4	Treatment with SCFAs versus saline solution	Significant reduction of the endoscopic grading after treatment (from 1.3 ± 0.21 to 0.4 ± 0.16, n = 10)	<0.01	Endoscopic improvement and microscopic atrophy reduced
Matsumoto S et al. <sup>47</sup>	2016	Case report	1	5-ASA (1g) plus prednisolone (20 mg) enemas once daily	1/1	NA	Endoscopic response one month after therapy start
Nyabanga CT et al. <sup>48</sup>	2017	Case report	1	Endoscopic treatment with 50%-dextrose sprayed solution	1/1	NA	Effective hemostasis in severe bleeding in diversion pouchitis
Zundler S et al. <sup>49</sup>	2017	Case report	1	Treatment with SCFAs (coconut oil as a rectal enema)	1/1	NA	Endoscopic and histologic remission after 8 weeks of treatment
Tominaga K et al. <sup>51</sup>	2019	Case report	1	Treatment with FMT	1/1	NA	Clinical and endoscopic response in diversion pouchitis of a UC patient
Lane A et al. <sup>56</sup>	2021	Case report	1	Exclusive elemental diet - enteral feed	1/1	NA	Clinical remission

Abbreviations: 5-ASA, mesalamine; CD, Crohn's disease; FMT, fecal transplantation; IBD, inflammatory bowel disease; NA, not applicable; SCFAs, short chain fatty acids; UC, ulcerative colitis.

<sup>a</sup>The number of included patients refers exclusively to IBD patients.

prominent and early in the rectum, with a subsequent proximal progression at the later endoscopic evaluations.<sup>24</sup> The severity of endoscopic inflammation was mild in the majority of the patients (60%–80%).<sup>18,23,24,26,27,29,31,39,40,43,46,48,50,54,56</sup>

Histology was assessed in 17 studies.<sup>25,29,31,33,35,37,39,42,45,47,52,54–56</sup> Numerous non-specific microscopic findings such as crypt branching or atrophy, crypt distortion, mucin depletion, regenerative hyperplasia, Paneth cell metaplasia and thickening of muscularis mucosa were present.<sup>29,32,33,40,45</sup> In addition, crypt abscess, ulceration and superficial coagulative necrosis were described.<sup>29,32,33,40,45</sup> IBD patients were found to have superimposed chronic histologic changes.<sup>32,42</sup> In UC patients with concomitant DP histologic features resembling Crohn's disease were observed, which can lead to a misdiagnosis of DP in these patients.<sup>32</sup> A substantial histological overlap between Crohn's disease and DP is acknowledged by further

studies.<sup>42</sup> Transmural lymphoid aggregates and mucosal follicular lymphoid hyperplasia were the main histologic feature of DP and were found, overall, in more than 60% of diverted IBD patients.<sup>25,29,31,33,35,37,39,42,45,47,52,54–56</sup> They were not associated with the duration of the defunctionalization and were equally present in CD and UC patients.<sup>39</sup> Granulomatous vasculitis and lymphocytic phlebitis were also proposed as distinguishing microscopic characteristics of DP superimposed to IBD.<sup>37,42</sup>

## Medical and surgical treatment

Medical or surgical treatment of DP in IBD was investigated in 15 studies,<sup>11,24,26,28,30,33,35,38,46,49,51,56</sup> including one case report investigating a dietary regimen.<sup>56</sup>

**TABLE 3** Different formulations of SCFAs employed in the included studies

Reference	SCFAs formulation	Intervention	Outcome
Harig et al. <sup>26</sup>	Enema of sodium acetate (60 mM), sodium propionate (30 mM), sodium n-butyrate (40 mM), plus sodium chloride (about 22 mM)	60 ml twice daily for two to four weeks (n = 1)	The endoscopic response and microscopic resolution of DP
Guillemot F et al. <sup>30</sup>	Enema of sodium acetate (60 mM), sodium propionate (30 mM), sodium n-butyrate (40 mM), plus sodium chloride (about 22 mM)	60 ml twice daily for 14 days (n = 2)	Endoscopic and histologic response
Neut C et al. <sup>34</sup>	Enema containing acetate (60 mmol/L), propionate (30 mmol/L) and n-butyrate (40 mmol/L)	60 ml twice daily for 14 days (n = 4)	SCFAs enemas do not induce significant changes in the microbial flora of patients with DP
Schauber J et al. <sup>38</sup>	Enema of sodium acetate (80 mM), sodium propionate (30 mM), sodium n-butyrate (40 mM)	60 ml twice daily for 3 weeks (n = 9)	No significant difference between SCFAs and saline as concerns clinical, endoscopic, and histologic response
Luceri et al. <sup>46</sup>	Enema (Naburen©, Promefarm, Italy), containing sodium butyrate (2 g/30 ml; 600 mmol/L)	Twice daily (36 mM totally) for 30 days (n = 10)	The endoscopic grading score was significantly reduced, no adverse effects.
Zundler S et al. <sup>49</sup>	100 ml of coconut oil (abundant in SCFAs) as a rectal enema	Daily coconut oil rectal application (n = 1) continuously for 6 months	Clinical remission, endoscopic and histologic improvement after 6–8 weeks Decrease of epithelial cell necrosis <i>in vitro</i> .

Note: Reported *n* refers exclusively to IBD patients included.

Abbreviations: DP, diversion proctocolitis; IBD, inflammatory bowel disease; SCFAs, short chain fatty acids.

Four studies reported surgical restoration of gut continuity as the curative treatment in DP,<sup>24,28,33,35</sup> able to restore the endoscopic normality, overall, in 34 IBD patients.<sup>24,28,33,35</sup> Indeed, the endoscopic appearance of the colonic and/or rectal mucosa returned to normality within 1 to 8 months from surgical re-anastomosis<sup>24,28,33,35</sup>; a histologic response or remission was also observed.<sup>24,28,33,35</sup>

All the included papers investigating medical therapies for DP in IBD patients are presented in Table 2. Among the treatment options, mesalamine and corticosteroids enemas were employed in a single case report.<sup>48</sup>

Beyond conventional therapies, SCFAs were administrated as treatment for DP in six studies<sup>26,30,34,38,46,49</sup> Table 3 elucidates the different SCFAs formulations employed in the studies included in our analysis. A treatment course with SCFAs instillation induced an endoscopic and histologic response or remission in three studies, totally in six IBD patients.<sup>26,46,49</sup> Notably, the histological examinations of biopsies collected after therapy showed almost a complete remission with disappearance of erosions and crypt abscesses and a reduction in lymphoid follicles.<sup>26</sup> In details, a randomized, double-blind, placebo-controlled clinical trial showed that the endoscopic grading was significantly reduced in the treatment group, particularly in IBD patients (n = 3), receiving sodium butyrate enemas (2 g/30 ml; twice daily for 30 days).<sup>46</sup> The authors demonstrated that SCFAs have anti-inflammatory and regenerative effects including the up-regulation of growth factors for mucosal repair<sup>46</sup>; this effect is supposed to be more prominent in IBD than in non-IBD patients.<sup>46</sup> Conversely, no significant improvement after SCFA irrigation was documented in two studies (n = 13).<sup>30,38</sup>

Finally, fecal transplantation (FMT) induced a clinical and endoscopic response in a single patient with severe diversion pouchitis,

after conventional therapy failure.<sup>51</sup> Endoscopic treatment, specifically 50%-dextrose sprayed via a catheter, was described as an effective hemostatic strategy in severe bleeding.<sup>48</sup>

## Complications and sequelae of the diverted rectum

Eleven studies reported complications of DP in IBD patients.<sup>11,18,23,36,40,43,44,48,50,53,55</sup> Among benign complications, in a large retrospective cohort stenosis and shrinkage of the rectal stump was detected in 29.8% (57/191) and in 25.6% (49/191) of the patients, respectively.<sup>18</sup> Others possible sequelae of the diverted rectum/colon were fistulae, perianal irritation, sexual difficulty and perforation.<sup>43,53,55</sup> The incidence of cancer in the diverted segment was investigated in seven studies.<sup>11,18,23,43,44,50,55</sup> Among the population of these studies taken together (495 patients), 13 cases (2.6%) of rectal and anal cancer and 11 cases (2.2%) of dysplasia occurred.<sup>11,18,23,43,44,50,55</sup> Overall, the mean follow-up was to 55.8 months (range 3.4 – 468 months).<sup>11,18,23,43,44,50,55</sup> When reported, the estimated incidence of cancer in the rectal stump varied from 3.9 to 4.5 per 1.000 diverted patients-year.<sup>18,50</sup> Among the 13 patients that developed cancer, the earliest case occurred after more than 4 years from index surgery,<sup>50</sup> while all the remaining cases occurred after more than 8 years.<sup>18,44,55</sup> As concerns the IBD type, more cases of both cancers and high-grade dysplasia were observed in the UC cohort.<sup>50</sup> Ten Hove et al. proposed that the increased risk of cancer might be due to a genetic background of susceptibility to dysplasia and suggested the potential benefit of proctectomy in patients with a previous history of colorectal neoplasia.<sup>18</sup> In this cohort, the finding of colorectal neoplasia in the removed colon was



associated with advanced rectal stump cancer (RSC).<sup>18</sup> A further study indicated a microscopically active inflammation of the diverted colon and a long disease duration (>10 years) as possible risk factors for cancer/dysplasia of the rectal stump.<sup>50</sup>

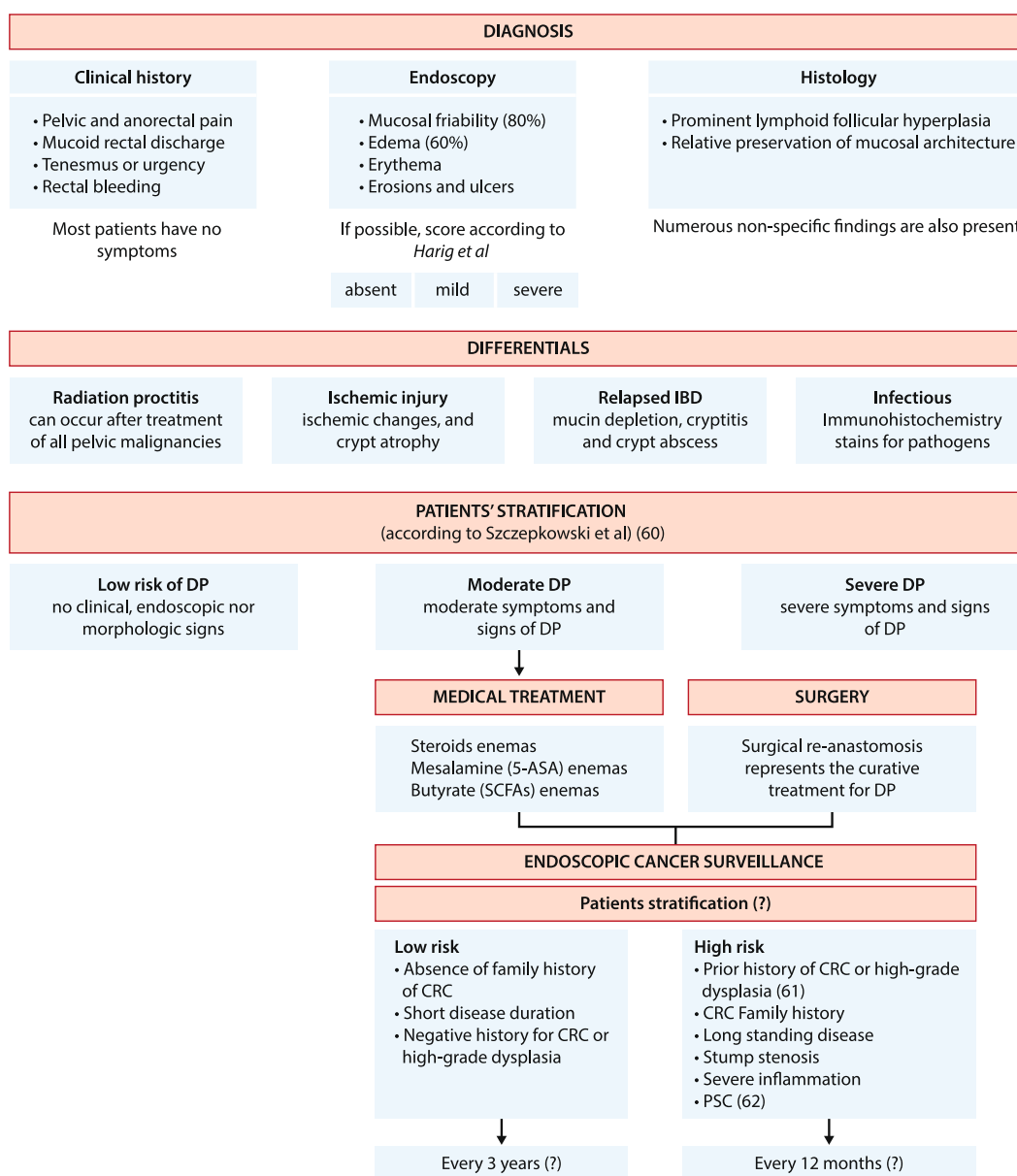
A compliance rate as low as 40% to the advised annual surveillance sigmoidoscopy was observed by Munie et al.<sup>44</sup>

## DISCUSSION

This systematic review illustrates the present understanding of DP in IBD patients. Care for DP in diverted IBD patients is challenging both in the diagnosis and treatment. Up to 67% of stomas in IBD patients would never be reverted<sup>58</sup> with the subsequent occurrence of DP in

almost all patients.<sup>18,28,33,50,54</sup> The presentation can range from no symptoms to an extremely disabling condition. Furthermore, the differential diagnosis represents an issue, and no distinctive endoscopic or histological feature defines DP, except for follicular lymphoid hyperplasia.<sup>25,29,31,33,35,37,39,42,45,47,52,54-56</sup> Due to the absence of univocal characteristics, this entity is probably underdiagnosed and remains a diagnosis of exclusion.

The reversal of diversion by restoration of intestinal continuity is the most effective strategy for the treatment of DP in terms of both endoscopic and histological response,<sup>24,28,33,35</sup> but it carries risks and is not always feasible because re-anastomosis entails inflamed mucosa. Therefore, a conservative approach with topical medications, as monotherapy or in combination, or SCFAs might be used (Figure 2). One of the main findings of our



**FIGURE 2** Proposed algorithm for diversion proctocolitis/pouchitis: from diagnosis to treatment and surveillance. Question marks indicate discussed issues due to literature controversy or scarcity of data



systematic review is that the evidence on the treatment with SCFAs is very poor and too divergent to be incorporated as first/standard line.

Due to the risk of inflammation and stenosis as well as of rectal cancer, the diverted colon/rectum cannot be “forgotten” even in asymptomatic patients. Patients with an acceptable perioperative risk should receive a balanced counseling, also in term of possible sexual, fertility and urinary impairment, and be eventually advised for surgery.

In Figure 2 an algorithm on how to manage IBD patients with diverted colon/rectum is suggested. Concerning the delicate issue of differentiating between a relapsed IBD activity and DP, histology appears the most reliable parameter (Figure 2). Currently, a standardized approach to this disease is required. For example, a validated endoscopic score would implement the evaluation of therapy response. Patients with DP can be stratified only clinically (Figure 2),<sup>59</sup> while an acknowledged endoscopic score (i.e., as proposed by Harig et al.) of severity is needed to drive surveillance as well as the risk assessment of cancer with a major impact on the indication for proctectomy. The attempt to classify the microscopic lesions, especially lymphoid follicular hyperplasia, both quantitatively and qualitatively (i.e., in the lamina propria vs. transmural) seems also possible.

With respect to cancer risk, what emerges from our systematic review is that the incidence of RSC ranges varied from 3,9 to 4,5 per 1.000 diverted patients-year.<sup>18,50</sup>

In a Swedish cohort of patients with UC that underwent subtotal colectomy, with a deviated rectum or an ileorectal anastomosis, a history of severe dysplasia or previous colon cancer, a longer duration of disease and concomitant primary sclerosing cholangitis were recently associated with the rectal cancer (Figure 2).<sup>60</sup> A concomitant primary sclerosing cholangitis has been associated with rectal stump carcinoma in a further retrospective case-control study.<sup>61</sup> However, whether the same risk factors have an impact in DP patients or are rather independent from DP is yet to be established.

A prior history of CRC or high-grade dysplasia, a positive family history for CRC and a long-standing disease can be considered risk factors imposing shorter surveillance intervals (Figure 2).<sup>18,50</sup>

Except for UK recommendations endorsing the need for endoscopic surveillance of the rectal stump and supporting the completion proctectomy as prevention of malignancy,<sup>62</sup> guidelines instructing on the surveillance timing in IBD patients with diverted colon/rectum are lacking.

The strength of our systematic review was to address several practical aspects of DP in IBD with respect to diagnosis, treatment and surveillance; however, the heterogeneity and the moderate quality of the included papers represented a limitation.

In conclusion, despite the data gathered so far, DP remains in the “Twilight Zone” of the inflammatory diseases of the colon-rectum with many open questions regarding pathogenesis, classification and management, warranting clarification from the future research.

## ACKNOWLEDGEMENTS

None.

## CONFLICT OF INTEREST

S Danese has served as a speaker, consultant and advisory board member for Schering- Plough, AbbVie, MSD, UCB Pharma, Ferring, Cellerix, Millenium Takeda, Nycomed, Pharmacosmos, Actelion, Alphawasserman, Genentech, Grunenthal, Pfizer, Astra Zeneca, Novo Nordisk, Cosmo Pharmaceuticals, Vifor and Johnson & Johnson, Nikkiso Europe GMBH, Theravance. A Spinelli has served as a speaker, consultant and advisory board member for Ethicon, Takeda, Pfizer, Frankenman, Sofar, Oasis. M Carvello has served as a speaker for Pfizer G Roda has served as speaker for Abbvie, Takeda and Pfizer. DB Sachar declares no conflict of interest A Dal Buono declares no conflict of interest.

## AUTHORSHIP

Guarantor of the article: Giulia Roda.

## AUTHOR CONTRIBUTIONS

Arianna Dal Buono and Giulia Roda performed the research. Arianna Dal Buono and Michele Carvello wrote the manuscript. David B Sachar, Antonino Spinelli and Silvio Danese critically reviewed the content of the paper. Giulia Roda conceived the subject of the paper, contributed to the critical interpretation and supervised the project. All authors approved the final version of the manuscript.

## DATA AVAILABILITY STATEMENT

Data sharing not applicable to this article as no datasets were generated or analyzed during the current study.

## ORCID

Arianna Dal Buono  <https://orcid.org/0000-0002-8543-4355>

## REFERENCES

1. Tominaga K, Kamimura K, Takahashi K, Yokoyama J, Yamagiwa S, Terai S. Diversion colitis and pouchitis: a mini review. *World J Gastroenterol.* 2018;24(16):1734–47.
2. Glotzer DJ, Glick ME, Goldman H. Proctitis and colitis following diversion of the fecal stream. *Gastroenterology.* 1981;80(3):438–41.
3. Korelitz BI, Cheskin LJ, Sohn N, Sommers SC. Proctitis after fecal diversion in Crohn's disease and its elimination with reanastomosis: implications for surgical management. Report of four cases. *Gastroenterology.* 1984;87(3):710–13.
4. Frisbie JH, Ahmed N, Hirano I, Klein M, Soybel D. Diversion colitis in patients with myelopathy: clinical, endoscopic and histopathological findings. *J Spinal Cord Med.* 2000;23(2):142–9.
5. Bafford AC, Latushko A, Hansraj N, Jambaulikar G, Ghazi LJ. The use of temporary fecal diversion in colonic and perianal Crohn's disease does not improve outcomes. *Dig Dis Sci.* 2017;62(8):2079–86.
6. Singh S, Ding NS, Mathis KL, Dulai PS, Farrell AM, Pemberton JH, et al. Systematic review with meta-analysis: faecal diversion for management of perianal Crohn's disease. *Aliment Pharmacol Ther.* 2015;42(7):783–92.
7. Harbord M, Eliakim R, Bettenworth D, Karmiris K, Katsanos K, Kopylov U, et al. Third European evidence-based consensus on diagnosis and management of ulcerative colitis. Part 2: current management. *J Crohns Colitis.* 2017;11(7):769–84.
8. Mège D, Figueiredo MN, Manceau G, Maggiori L, Bouhnik Y, Panis Y. Three-stage laparoscopic ileal pouch-anal anastomosis is the best

- approach for high-risk patients with inflammatory bowel disease: an analysis of 185 consecutive patients. *J Crohns Colitis*. 2016;10(8):898–904.
9. Hicks CW, Hodin RA, Bordeianou L. Possible overuse of 3-stage procedures for active ulcerative colitis. *JAMA Surg*. 2013;148(7):658–64.
  10. Telakis E, Tsironi E. Indeterminate colitis – definition, diagnosis, characteristics and management. *Ann Gastroenterol*. 2008;21(3):173–9.
  11. Böhm G, O'Dwyer ST. The fate of the rectal stump after subtotal colectomy for ulcerative colitis. *Int J Colorectal Dis*. 2007;22(3):277–82.
  12. Harling H, Hegnhøj J, Rasmussen TN, Jarnum S. Fate of the rectum after colectomy and ileostomy for Crohn's colitis. *Dis Colon Rectum*. 1991;34:931–5.
  13. Magro F, Gionchetti P, Eliakim R, Ardizzone S, Armuzzi A, Barreiro-de Acosta M, et al. Third European evidence-based consensus on diagnosis and management of ulcerative colitis. Part 1: definitions, diagnosis, extra-intestinal manifestations, pregnancy, cancer surveillance, surgery, and ileo-anal pouch disorders. *J Crohns Colitis*. 2017;11(6):649–70.
  14. Block M, Jørgensen KK, Oresland T, Lindholm E, Grzyb K, Cvancarova M, et al. Colectomy for patients with ulcerative colitis and primary sclerosing cholangitis - what next? *J Crohns Colitis*. 2014;8(5):421–30.
  15. Son DN, Choi DJ, Woo SU, Kim J, Keom BR, Kim KH, et al. Relationship between diversion colitis and quality of life in rectal cancer. *World J Gastroenterol*. 2013;19:542–9.
  16. Lopez A, Pouillon L, Beaugier L, Danese S, Peyrin-Biroulet L. Colorectal cancer prevention in patients with ulcerative colitis. *Best Pract Res Clin Gastroenterol*. 2018;32-33:103–9.
  17. Jess T, Rungoe C, Peyrin-Biroulet L. Risk of colorectal cancer in patients with ulcerative colitis: a meta-analysis of population-based cohort studies. *Clin Gastroenterol Hepatol*. 2012;10:639e4.
  18. Ten Hove JR, Bogaerts JMK, Bak MTJ, Laclé MM, Meij V, Derikx LAAP, et al. Malignant and nonmalignant complications of the rectal stump in patients with inflammatory bowel disease. *Inflamm Bowel Dis*. 2019;25(2):377–84.
  19. Higgins JPT, Cochrane Collaboration, editors. *Cochrane handbook for systematic reviews of interventions*. 2nd ed. Hoboken: Wiley-Blackwell; 2020.
  20. Hutton B, Salanti G, Caldwell DM, Chaimani A, Schmid CH, Cameron C, et al. The PRISMA extension statement for reporting of systematic reviews incorporating network meta-analyses of health care Interventions: checklist and explanations. *Ann Intern Med*. 2015;162:777–84.
  21. Anon. Ottawa Hospital Research Institute. [http://www.ohri.ca/programs/clinical\\_epidemiology/oxford.asp](http://www.ohri.ca/programs/clinical_epidemiology/oxford.asp). Accessed 2 July 2021.
  22. Jadad AR, Moore RA, Carroll D, Jenkinson C, Reynolds DJM, Gavaghan DJ, et al. Assessing the quality of reports of randomized clinical trials: is blinding necessary? *Contr Clin Trials*. 1996;17:1–12.
  23. Lavery IC, Jagelman DG. Cancer in the excluded rectum following surgery for inflammatory bowel disease. *Dis Colon Rectum*. 1982;25(6):522–4.
  24. Korelitz BI, Cheskin LJ, Sohn N, Sommers SC. The fate of the rectal segment after diversion of the faecal stream in Crohn's disease: its implications for surgical management. *J Clin Gastroenterol*. 1985;7(1):37–43.
  25. Haas PA, Haas GP. A critical evaluation of the Hartmann's procedure. *Am Surg*. 1988;54(6):380–5.
  26. Harig JM, Soergel KH, Komorowski RA, Wood CM. Treatment of diversion colitis with short-chain-fatty acid irrigation. *N Engl J Med*. 1989;320(1):23–8.
  27. Neut C, Colombel JF, Guillemot F, Cortot A, Gower P, Quandalle P, et al. Impaired bacterial flora in human excluded colon. *Gut*. 1989;30(8):1094–8.
  28. Löhr HF, Mayet WJ, Singe CC, Ramadori G, Meyer zum Büschenfelde KH. Diversion colitis in Crohn disease. A case report and review of the literature. *Z Gastroenterol*. 1989;27(4):221–4.
  29. Komorowski RA. Histologic spectrum of diversion colitis. *Am J Surg Pathol*. 1990;14(6):548–54.
  30. Guillemot F, Colombel JF, Neut C, Verplanck N, Lecomte M, Romond C, et al. Treatment of diversion colitis by short-chain fatty acids. Prospective and double-blind study. *Dis Colon Rectum*. 1991;34(10):861–4.
  31. Yeong ML, Bethwaite PB, Prasad J, Isbister WH. Lymphoid follicular hyperplasia--a distinctive feature of diversion colitis. *Histopathology*. 1991;19(1):55–62.
  32. Warren BF, Shepherd NA, Bartolo DC, Bradfield JW. Pathology of the defunctioned rectum in ulcerative colitis. *Gut*. 1993;34(4):514–16.
  33. Winslet MC, Allan A, Poxon V, Youngs D, Keighley MR. Faecal diversion for Crohn's colitis: a model to study the role of the faecal stream in the inflammatory process. *Gut*. 1994;35(2):236–42.
  34. Neut C, Guillemot F, Gower-Rousseau C, Biron N, Cortot A, Colombel JF. Treatment of diversion colitis with short-chain fatty acids. Bacteriological study. *Gastroenterol Clin Biol*. 1995;19(11):871–5.
  35. Lavoine E, Vissuzaine C, Cadiot G, Sobhani I, Benhamou G, Mignon M, et al. Proctitis of diversion on an excluded rectum in patients with hemorrhagic rectocolitis. *Gastroenterol Clin Biol*. 1996;20(3):243–7.
  36. Geoghegan JG, Carton E, O'Shea AM, Astbury K, Sheahan K, O'Donoghue DP, et al. Crohn's colitis: the fate of the rectum. *Int J Colorectal Dis*. 1998;13(5–6):256–9.
  37. Rice AJ, Abbott CR, Mapstone NM. Granulomatous vasculitis in diversion procto-colitis. *Histopathology*. 1999;34(3):276–7.
  38. Schaubert J, Bark T, Jaramillo E, Katouli M, Sandstedt B, Svenberg T. Local short-chain fatty acids supplementation without beneficial effect on inflammation in excluded rectum. *Scand J Gastroenterol*. 2000;35(2):184–9.
  39. Asplund S, Gramlich T, Fazio V, Petras R. Histologic changes in defunctioned rectums in patients with inflammatory bowel disease: a clinicopathologic study of 82 patients with long-term follow-up. *Dis Colon Rectum*. 2002;45(9):1206–13.
  40. Winther KV, Bruun E, Federspiel B, Guldborg P, Binder V, Brynskov J. Screening for dysplasia and TP53 mutations in closed rectal stumps of patients with ulcerative colitis or Crohn disease. *Scand J Gastroenterol*. 2004;39(3):232–7.
  41. Borralho P, Vieira A, Loureiro R, Pereira PM, de Freitas J. Microcarcinoids associated with diversion colitis in a patient with Crohn's disease. *J Crohns Colitis*. 2008;2(3):246–9.
  42. Chetty R, Hafezi S, Montgomery E. An incidental enterocolic lymphocytic phlebitis pattern is seen commonly in the rectal stump of patients with diversion colitis superimposed on inflammatory bowel disease. *J Clin Pathol*. 2009;62(5):464–7.
  43. Ishihara S, Watanabe T, Nagawa H. Free colonic perforation in a patient with Crohn's disease and loop ileostomy: report of a case. *Int Surg*. 2011;96(2):159–61.
  44. Munie S, Hyman N, Osler T. Fate of the rectal stump after subtotal colectomy for ulcerative colitis in the era of ileal pouch-anal anastomosis. *JAMA Surg*. 2013;148(5):408–11.
  45. Gill P, Chetty R. Filiform polyps and filiform polyp-like lesions are common in defunctioned or diverted colorectum resection specimens. *Ann Diagn Pathol*. 2013;17(4):341–4.
  46. Luceri C, Femia AP, Fazi M, Di Martino C, Zolfanelli F, Dolara P, et al. Effect of butyrate enemas on gene expression profiles and endoscopic/histopathological scores of diverted colorectal mucosa: a randomized trial. *Dig Liver Dis*. 2016;48(1):27–33.

47. Matsumoto S, Mashima H. Efficacy of combined mesalazine plus corticosteroid enemas for diversion colitis after subtotal colectomy for ulcerative colitis. *Case Rep Gastroenterol*. 2016 May 9;10(1):157-60.
48. Nyabanga CT, Shen B. Endoscopic treatment of bleeding diversion pouchitis with high-concentration dextrose spray. *ACG Case Rep J*. 2017;4:e51.
49. Zundler S, Dietz L, Matzel KE, Geppert C-I, Becker E, Rath T, et al. Successful long-term treatment of diversion colitis with topical coconut oil application. *Am J Gastroenterol*. 2018;113(12):1908-10.
50. Bettner W, Rizzo A, Brant S, Dudley-Brown S, Efron J, Fang S, et al. Low incidence of dysplasia and colorectal cancer observed among inflammatory bowel disease patients with prolonged colonic diversion. *Inflamm Bowel Dis*. 2018 Apr 23; 24(5):1092-8.
51. Tominaga K, Tsuchiya A, Yokoyama J, Terai S. How do you treat this diversion ileitis and pouchitis? *Gut*. 2019;68(4):593-758.
52. Katerji R, Gonzalez R, Huber A, Findeis-Hosey J. Histopathology of diversion colitis in inflammatory bowel disease patients: longitudinal examination of pre-and post-diversion specimens. Conference Abstract. *Mod Pathol*. 2019;32:3.
53. Yzet C, Kassim G, Nair N, Colombel JF, Sachar DB. Long-term fate of the excluded rectum in Crohn's disease. *Gastroenterology*. 2019; 156(6):S257-8.
54. Wasmann KA, van der Does de Willebois EM, Koens L, Duijvestein M, Bemelman WA, Buskens CJ. The impact of rectal stump inflammation after subtotal colectomy on pouch outcomes in ulcerative colitis patients. *J Crohns Colitis*. 2020 Sep 9;15(2):299-306. <https://doi.org/10.1093/ecco-jcc/jjaa157>
55. Kassim G, Debebe A, Cholapranee A, Sultan K, Colombel J-F, Sachar D. Long-term outcomes of the excluded rectum in Crohn's disease – results from the CAPER (consortium to assess prognosis of the excluded rectum) study. *Am J Gastroenterol*. 2020;115(1):S409.
56. Lane A, Dalkie N, Henderson L, Irwin J, Rostami K. An elemental diet is effective in the management of diversion colitis. *Gastroenterol Hepatol Bed Bench*. 2021;14(1):81-4.
57. Fu Z, Kmeid M, Arker SH, Lukose G, Lee E, Lee H. Histologic features of diverted colon in IBD are distinct from non-IBD: reappraisal of diversion colitis. Abstracts from USCAP 2021: Gastrointestinal Pathology (311-404). *Lab Invest*. 2021;101:395-514. <https://doi.org/10.1038/s41374-021-00556-y>
58. Orsay CP, Kim DO, Pearl RK, Abcarian H. Diversion colitis in patients scheduled for colostomy closure. *Dis Colon Rectum*. 1993;36(4):366-7.
59. Szczepkowski M, Kobus A, Borycka K. How to treat diversion colitis? Current state of medical knowledge, own research and experience. *Acta Chir Jugosl*. 2008;55(3):77-81.
60. Abdalla M, Landerholm K, Andersson P, Andersson RE, Myrelid P. Risk of rectal cancer after colectomy for patients with ulcerative colitis: a national cohort study. *Clin Gastroenterol Hepatol*. 2017 Jul;15(7):1055-60.e2.
61. Lutgens MW, van Oijen MG, Vleggaar FP, Siersema PD, Broekman MM, Oldenburg B. Dutch Initiative on Crohn and Colitis. Risk factors for rectal stump cancer in inflammatory bowel disease. *Dis Colon Rectum*. 2012;55(2):191-6.
62. Brown SR, Fearnhead NS, Faiz OD, Abercrombie JF, Acheson AG, Arnott RG, et al. ACPGIB IBD Surgery Consensus Collaboration. The Association of Coloproctology of Great Britain and Ireland consensus guidelines in surgery for inflammatory bowel disease. *Colorectal Dis*. 2018;20(Suppl 8):3-117.

#### SUPPORTING INFORMATION

Additional supporting information may be found in the online version of the article at the publisher's website.

**How to cite this article:** Dal Buono A, Carvello M, Sachar DB, Spinelli A, Danese S, Roda G. Diversion proctocolitis and the problem of the forgotten rectum in inflammatory bowel diseases: a systematic review. *United European Gastroenterol J*. 2021;9(10):1157-67. <https://doi.org/10.1002/ueg2.12175>