

New Features of Electrocardiogram in a Case Report of Arrhythmogenic Right Ventricular Cardiomyopathy

A Care-Compliant Article

Haifeng Pei, MD, PhD, Qiujuan Yu, MD, PhD, Xiaohua Su, MD, Zhen Wang, MD, Heng Zhao, MD, Dachun Yang, MD, PhD, Yongjian Yang, MD, PhD, and De Li, MD, PhD

Abstract: Arrhythmogenic right ventricular cardiomyopathy (ARVC) is a crucial health problem. With sudden death often being the first presentation, early diagnosis for ARVC is essential. Up to date, electrocardiogram (ECG) is a widely used diagnostic method without invasive harms. To diagnose and treat ARVC as well as possible, we should clearly elucidate its pathophysiological alterations.

A 66-year-old farmer presented to the Emergency Department with continuous palpitation, chest tightness, profuse sweating, and nausea with no obvious predisposing causes. An ECG indicated ventricular tachycardia (VT). The patient experienced a sudden drop in blood pressure and acute confusion. After an immediate electrical conversion, his consciousness was gradually restored, and symptoms relieved. The patient was then transferred to the Department of Cardiology to receive ECG, echocardiography, coronary angiogram, biochemical assays, endocardiac tracing, and radiofrequency ablation.

In the end, he was diagnosed with ARVC, evidenced by bilateral ventricle dilation and epsilon waves in leads V1–V3. Appropriate therapies were provided for this patient including pharmacological intervention and radiofrequency ablation. Although the diagnosis of ARVC is not difficult, this patient's ECG manifested several interesting features and should be further investigated: T wave inversions were found extensively in the anterior and inferior leads, revealing the involvement of bilateral ventricles; VTs with different morphologies and cycle lengths were found, and some VTs manifested the feature of irregularly irregular rhythm, reminding us to carefully differentiate some special VTs from atrial fibrillation (AF); and epsilon waves gradually appeared in leads V1–V3 and aVR since the onset of ARVC. Most importantly, the epsilon waves behind QRS complex appeared in both sinus rhythm and ventricular premature beats/VT originating from

cardiac apex, whereas the epsilon waves prior to QRS complex occurred in VT originating from right ventricular outflow tract (RVOT).

The features of T wave inversion and epsilon wave in ECGs and the appearance of VTs with different morphologies can reflect the progression of ARVC. The position relationship between epsilon wave and QRS complex in VT depends on ventricular activation sequence, that is, the localization of epsilon wave depends on where VT is originating from.

(*Medicine* 95(16):e3442)

Abbreviations: AF = atrial fibrillation, ARVC = arrhythmogenic right ventricular cardiomyopathy, BNP = B-type natriuretic peptide, ECG = electrocardiogram, RVOT = right ventricular outflow tract, RyR2 = type 2 ryanodine receptor, TWA = T-wave alternans, VT = ventricular tachycardia.

INTRODUCTION

Arrhythmogenic right ventricular cardiomyopathy (ARVC) is characterized by myocytes loss and fibrofatty degeneration of right ventricle, leading to arrhythmogenesis and cardiac dysfunction.¹ It is a common cause of sudden death among young adults and athletes. According to the epidemiological investigation, nearly 50% of ARVC cases reveal a familial background with an autosomal dominant pattern of inheritance.²

CASE REPORT

The institutional review board (Chengdu Military General Hospital) approved this work and waived the need for informed consent. In 2013, a 66-year-old farmer with a history of ventricular tachycardia (VT) and hypertension presented to the Emergency Department with continuous palpitation, chest tightness, profuse sweating and nausea with no obvious predisposing causes. The patient experienced a sudden drop in blood pressure and acute confusion. After an immediate electrical conversion, his consciousness was gradually restored, and symptoms relieved. Then, this patient was transferred to the Department of Cardiology for further evaluations and treatments. The patient's blood pressure was 105/75 mm Hg upon admission, with a heart rate of 75 beats/min, body temperature of 36.6°C and respiration rate of 18 times/min. The heart border extended to the left, with the apical impulse located in the left 5th intercostal space, 1.0 cm lateral to the midclavicular line. The patient had a history of hypertension over 30 years without regular antihypertensive medication. The highest blood pressure was 170/110 mm Hg. There was no family history of early coronary artery disease or sudden cardiac death. He did not smoke cigarettes or use illicit drugs, and rarely consumed alcohol. He also reported no known contacts with sick persons and no recent travel.

Editor: Shizhang Ling.

Received: December 7, 2015; revised: March 25, 2016; accepted: March 28, 2016.

From the Departments of Cardiology (HP, XS, ZW, DY, YY, DL) and Ultrasonography (HZ), Chengdu Military General Hospital, Chengdu; Third Military Medical University, Chongqing (HP, YY), China; and Division of Cardiovascular Medicine, Department of Medicine, Brigham and Women's Hospital, Harvard Medical School, Boston, MA (QY).

Correspondence: Yongjian Yang and De Li, Department of Cardiology, Chengdu Military General Hospital, 270 Tianhui Road, Chengdu 610083, China

(e-mail: yyj10001@126.com [YY] and lide20011@126.com [DL]).

This work was supported by National Science Funds of China (No. 81500208 and 81470396), Youth Breeding Project for Medical Scientific Research Program of PLA (No. 14QNP050), and Science and Technology Project of Sichuan Province (No. 2015JY0277).

The authors have no conflicts of interest to disclose.

Copyright © 2016 Wolters Kluwer Health, Inc. All rights reserved.

This is an open access article distributed under the Creative Commons Attribution-NoDerivatives License 4.0, which allows for redistribution, commercial and non-commercial, as long as it is passed along unchanged and in whole, with credit to the author.

ISSN: 0025-7974

DOI: 10.1097/MD.0000000000003442

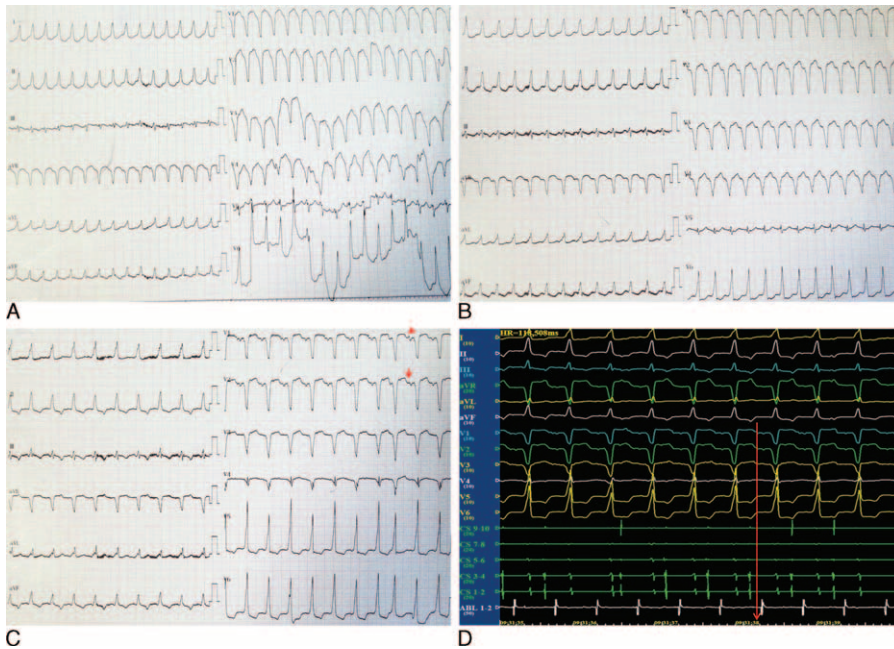


FIGURE 1. ECGs of VT on presentation. (A–C) 12-lead surface ECGs (25 mm/s, 10 mm/mV) with rates of 195, 159, and 120 bpm, respectively; (D) Endocardiac tracing. Epsilon waves (marked by red arrows) are seen in leads V1–V2. ECG = electrocardiogram, VT = ventricular tachycardia, bpm = beats per minute.

Twelve-lead surface electrocardiogram (ECG) of VT indicated that the origin of VT was at the boundary between right ventricular outflow tract (RVOT) and tricuspid valve. When VT increased to 150 beats/min or higher, no epsilon waves were

found in the precordial leads (Figure 1A and B). In contrast, when VT decreased to 120 beats/min or lower, epsilon waves appeared in leads V1–V2 (Figure 1C). Notably, the epsilon waves preceded QRS waves in leads V1–V2, while endocardiac

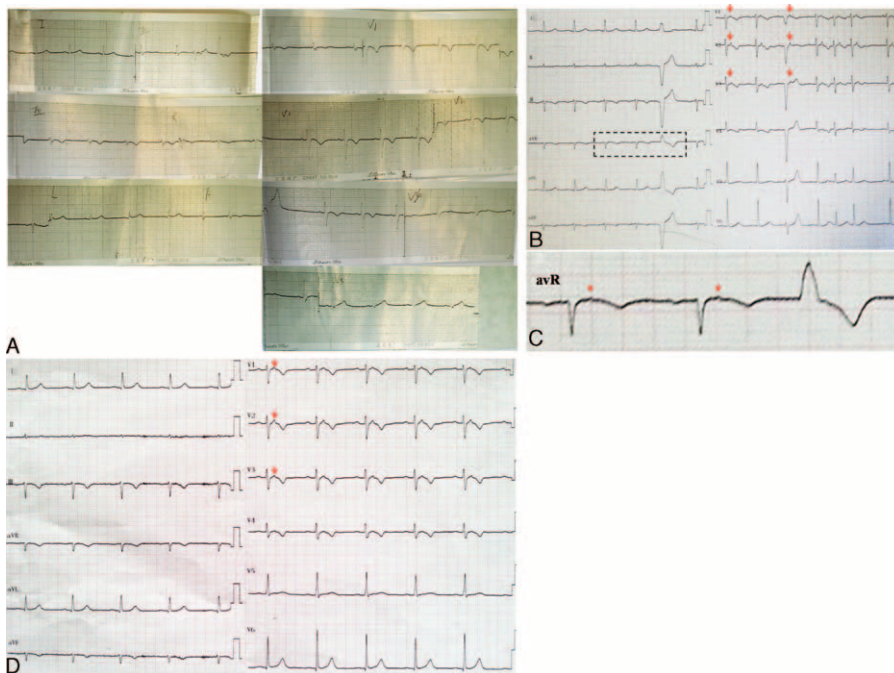


FIGURE 2. Sinus ECGs on presentation. (A) 12-lead surface ECGs (25 mm/s, 10 mm/mV) taken in 1999. Epsilon waves (marked by red arrows) are seen in leads V1–V3 and avR; (B) Magnified view of lead avR, deriving from the dashed box in panel A; (C) 12-lead surface ECGs (25 mm/s, 10 mm/mV) with rate of 87 bpm taken in 2013; (D) Sinus ECG after ablation. Epsilon waves (marked by red arrows) are seen in leads V1–V3. ECG = electrocardiogram.

tracing confirmed that the corresponding local potential originating from RVOT appeared prior to the ventricular rhythm (Figure 1D). Sinus ECG in the year of 2013 suggested a slight left deviation of electric axis, with a heart rate of 87 beats/min and flat T waves in lead II. T wave inversions were found in leads III, avF and V1–V3, meanwhile epsilon waves were found following QRS complex in leads V1–V3 (Figure 2B). When the lead avR was amplified, epsilon waves were also found behind QRS waves (Figure 2C). Atrial premature beats appeared occasionally. Moreover, ventricular premature beats were also found to originate from the right ventricular apex, with epsilon waves appearing behind QRS waves (Figure 2B). In contrast, sinus ECG obtained in the year of 1999 revealed similar left deviation of electric axis, flat T waves and T wave inversions, but absence of epsilon waves (Figure 2A). Data from biochemical assays were as follows: cardiac troponin I level was 0.714 µg/L (normal range, 0–0.06 µg/L), serum B-type natriuretic peptide level was 466.530 pg/mL (normal range, 0–100 pg/mL), serum D-dimer level was 8.14 mg/L (normal range, 0–0.55 mg/L), blood urea level was 11.69 mmol/L (normal range, 2.90–7.20 mmol/L), serum creatinine level was 144.00 µmol/L (normal range, 44–133 µmol/L), serum uric acid level was 611.40 µmol/L (normal range, 100–432 µmol/L), and endogenous creatinine clearing value was 57.90 mL/min (normal range, >80 mL/min). Echo data revealed remarkably enlarged right atrium and right ventricle, and widened ROVT. Uncoordinated motions of the left and right ventricular walls were also detected. Moreover, we also found aortic valve degradation with slight regurgitation, slight mitral regurgitation, and moderate to severe tricuspid regurgitation. The left ventricular diastolic function was

reduced to 55% (Figure 3A and B). The coronary angiogram revealed no vascular stenosis (Figure 3C–E). Based on the above-mentioned examinations, this patient met at least 2 major criteria, the bilateral ventricular dilation and the existence of epsilon waves, providing diagnostic support for ARVC.

A diet with low salt and low fat was suggested. The patient was also treated with metoprolol succinate sustained-release tablets (23.75 mg daily, p.o.), amiodarone (200 mg daily, p.o.), furosemide (20 mg daily, i.v.), and compound α-ketoacid tablets (2.52 g daily, p.o.). Moreover, VTs with different morphologies and cycle lengths were found during radiofrequency ablation (Figure 4). The substrate voltage mapping revealed that the anterior wall of RVOT was wrapped by circular scar (Figure 5A). Considering the association of VT with scar areas, substrate ablation was chosen for this patient. The residual potentials in the scar areas were searched, and then linear and focal ablations were performed (Figure 5B). Neither programmed stimulation nor induced stimulation could induce VT after the procedure was completed, indicating the success of operation. The ECG after radiofrequency ablation showed sinus rhythm, with a heart rate of 61 beats/min, T wave inversions in leads III and avF, and epsilon waves and T wave inversions in leads V1–V3 (Figure 2D). This patient was discharged from hospital on day 9 with a regimen of metoprolol succinate sustained-release tablets (23.75 mg daily, p.o.), amiodarone hydrochloride tablets (200 mg daily, p.o.), spironolactone tablets (40 mg daily, p.o.), and fosinopril sodium tablets (10 mg daily, p.o.). The patient was followed up 3 months after discharge. He had no recurrent palpitation, chest tightness, profuse sweating or nausea. Although ARVC was the main diagnosis at the time of this patient’s initial presentation, it is

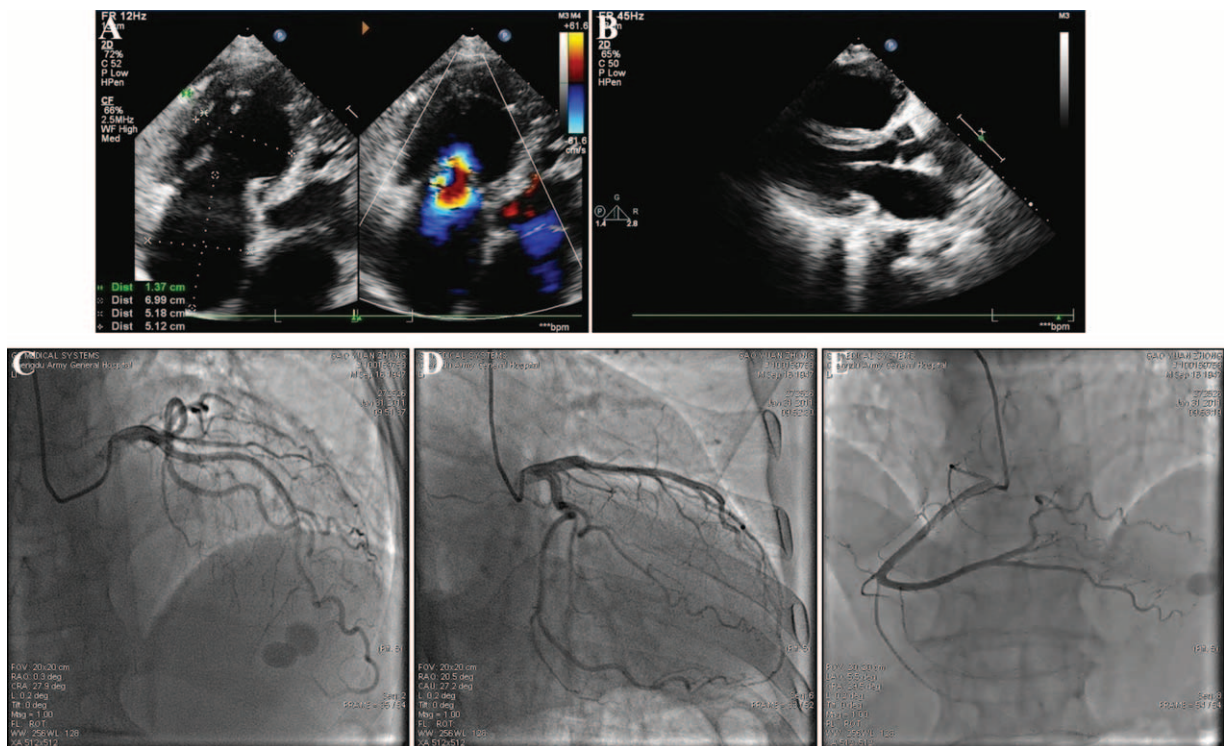


FIGURE 3. Echocardiography on presentation and coronary angiograms. (A) The right atrium and ventricle are significantly enlarged; (B) The right ventricular outflow tract is obviously broadened. The left coronary artery (C, D) and right coronary artery (E) reveal no evidence of plaque rupture or thrombus.

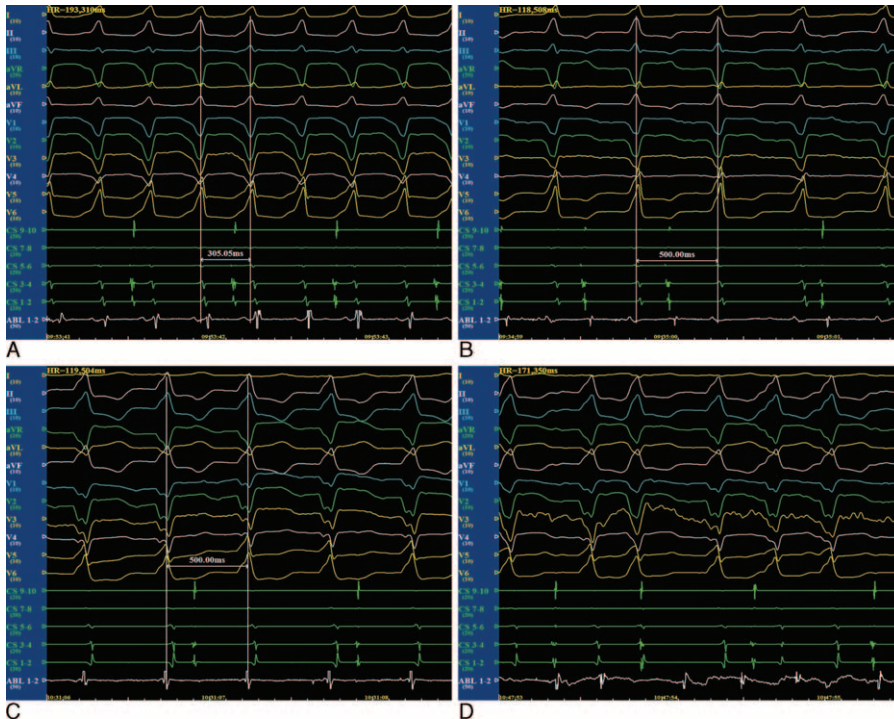


FIGURE 4. Twelve-lead surface ECGs and endocardial tracing of VT during operation. (A, B) The VT exports may reside under the right rear wall of right ventricular outflow tract, with cycle lengths of 305.05 and 500.00 ms, respectively; (C, D) The VT exports may reside under the pulmonary valve near the junction of the anterior wall of right ventricular outflow tract and the anterior septum, with cycle length of 500.00 ms in panel C and unequal cycle lengths in panel D. ABL=ablation electrodes, CS=coronary sinus leads, ECG=electrocardiogram, VT=ventricular tachycardia.

essential in such cases to perform a reassessment for the presence of structural heart disease, which can evolve over time.

DISCUSSION

The clinical manifestations of ARVC usually appear in patients ranging from 30 to 50 years old, and consist of premature ventricular beats, lightheadedness, ventricular arrhythmias, syncope, etc. In desmosome genetic analysis for Han Chinese group study, 21 mutations were identified from 48 cases, and *PKP2* was the most common mutated gene.³ Furthermore, some studies focusing on cytoplasmic calcium overload have led to an apoptotic theory in which fibrofatty infiltration progressively occurs following inappropriate myocardial

apoptosis.⁴ Santulli et al^{5,6} claim that the excitation-contraction coupling in cardiomyocytes is closely linked with type 2 ryanodine receptor (RyR2), the rare mutations of which were identified in patients of catecholaminergic polymorphic VT. Moreover, the augmented oxidative stress in metabolic syndrome patients can impair Na⁺, K⁺, Ca²⁺ channels and Na⁺-Ca²⁺ exchanger activity, leading to cardiac electrical and structural remodeling.⁷ Sardu et al⁸ have revealed that metabolic syndrome can give rise to a higher recurrence rate of outflow tract premature ventricular contraction beats after catheter ablation. Based on Task Force Criteria 2010 proposed by a consensus report,⁹ ARVC can be recognized by electrocardiographic, morphological and functional features.

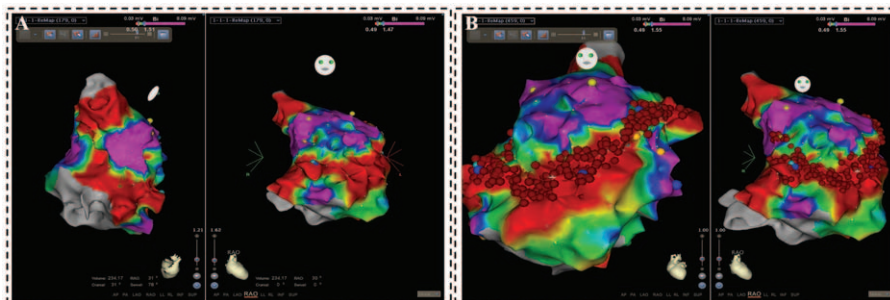


FIGURE 5. Voltage measurement and ablation of the right ventricular outflow tract. (A) The anterior wall of right ventricular outflow tract is surrounded by low voltage. Purple represents normal voltage area, while red stands for low voltage area; (B) Circumferential ablation is implemented in the low voltage area.

Discrimination between ARVC and idiopathic RVOT-VT is very critical, as their prognoses and therapeutic options differ. The positive T-wave alternans test during exercise testing can be used to distinguish ARVC from idiopathic RVOT-VT.¹⁰ However, some recent studies suggested that there were multiple drawbacks in the diagnostic criteria for ARVC.⁹ With the research advancement, more elements may be introduced into the criteria, providing more accurate pieces of evidence for the diagnosis of ARVC.

The electrical manifestations of right ventricle are important to aid in the differential diagnosis of ARVC. More than 90% of ARVC patients present ECG abnormalities which reflect the pathophysiology of right ventricle replaced by fibrous and fatty tissues.¹¹ In our patient, there are some intriguing findings in ECG. First, extensive T wave inversions were found in the inferior and anterior leads, and these repolarization abnormalities may serve as early ECG markers of biventricular involvement. Consistent with our findings, ARVC can no longer be regarded as an isolated disease of right ventricle. In one study of 42 patients, histologic involvement of left ventricle was found in up to 76% of participants.¹² And such correlation could also be confirmed by serial echocardiographic examinations.¹¹ Second, VTs with different morphologies and cycle lengths were found during the operation (Figure 4). In patients with advanced ARVC, abnormal right ventricle may possess multiple arrhythmogenic foci to present several morphologies of VT.¹¹ It is well known that irregularly irregular rhythm is an important feature of atrial fibrillation (AF).¹³ One interesting finding was that some VTs occurred in the operation manifested irregularly irregular rhythm (Figure 4D). After comparing the graphs obtained from surface and coronary sinus electrodes, the ventricular rhythm was confirmed. Therefore, we should differentiate special VT from AF when reviewing ECG. These results suggest that different arrhythmogenic foci share the same export. Third, several important features of epsilon waves were shown in the ECG, as follows: no epsilon waves were found in any lead of the sinus ECG obtained 14 years ago, whereas epsilon waves appeared in the precordial leads in the sinus ECG got during this hospitalization. Our case supports the concept that ARVC is generally progressive in nature, and that surface 12-lead ECG is able to assess disease progression. Although a previous research declared that serial electrocardiographic recordings failed to predict the progression of ARVC,¹⁴ many studies have suggested that ECG changes are generally progressive in ARVC patients,¹⁵ which is in consistent with our present finding. Epsilon waves were found in lead aVR of the present sinus ECGs, but not in his previous ones (Figure 2A-C). Epsilon wave in the lead aVR is an indicator of poor prognosis for ARVC patients. Thus, the prognosis of this patient is not optimistic. The epsilon waves appeared behind QRS complex in both the sinus rhythm and ventricular premature beats/VT originated from heart apex (Figure 2B); in contrast, epsilon waves appeared in front of QRS complex in the VT originated from RVOT (Figure 1C). To our knowledge, this feature has not been reported before. When VT happens, the position relationship between epsilon wave and QRS complex depends on ventricular activation sequence. The amplitude of epsilon wave may be associated with the number of survived cardiomyocytes in residual myocardium islands wrapped by fibrofatty tissues. Deeply understanding these features of epsilon waves can help us differentiate the site and severity of cardiac lesions, and thus

providing pieces of evidence for the prevention and treatments of ARVC.

REFERENCES

- Saprungruang A, Tumkosit M, Kongphatthanayothin A. The presence of epsilon waves in all precordial leads (V1–V6) in a 13-year-old boy with arrhythmogenic right ventricular dysplasia (ARVD). *Ann Noninvasive Electrol. Cardiol.* 2013;18:484–486.
- Nava A, Thiene G, Canciani B, et al. Familial occurrence of right ventricular dysplasia: a study involving nine families. *J Am Coll Cardiol.* 1988;12:1222–1228.
- Zhou X, Chen M, Song H, et al. Comprehensive analysis of desmosomal gene mutations in Han Chinese patients with arrhythmogenic right ventricular cardiomyopathy. *Eur J Med Genet.* 2015;58:258–265.
- Ahmad F. The molecular genetics of arrhythmogenic right ventricular dysplasia-cardiomyopathy. *Clin Invest Med.* 2003;26:167–178.
- Santulli G, Pagano G, Sardu C, et al. Calcium release channel RyR2 regulates insulin release and glucose homeostasis. *J Clin Invest.* 2015;125:1968–1978.
- Santulli G, Pagano G, Sardu C, et al. Calcium release channel RyR2 regulates insulin release and glucose homeostasis. *J Clin Invest.* 2015;125:4316.
- Dong M, Ren J. What fans the fire: insights into mechanisms of leptin in metabolic syndrome-associated heart diseases. *Curr Pharm Des.* 2014;20:652–658.
- Sardu C, Carreras G, Katsanos S, et al. Metabolic syndrome is associated with a poor outcome in patients affected by outflow tract premature ventricular contractions treated by catheter ablation. *BMC Cardiovasc Disord.* 2014;14:176.
- Liu T, Pursnani A, Sharma UC, et al. Effect of the 2010 task force criteria on reclassification of cardiovascular magnetic resonance criteria for arrhythmogenic right ventricular cardiomyopathy. *J Cardiovasc Magn Reson.* 2014;16:47.
- Yalin K, Golcuk E, Aksu T, et al. Distinguishing right ventricular cardiomyopathy from idiopathic right ventricular outflow tract tachycardia with T-wave alternans. *Am J Med Sci.* 2015;350:463–466.
- Corrado D, Basso C, Thiene G. Arrhythmogenic right ventricular cardiomyopathy: diagnosis, prognosis, and treatment. *Heart.* 2000;83:588–595.
- Corrado D, Fontaine G, Marcus FI, et al. Arrhythmogenic right ventricular dysplasia/cardiomyopathy: need for an international registry. Study Group on Arrhythmogenic Right Ventricular Dysplasia/Cardiomyopathy of the Working Groups on Myocardial and Pericardial Disease and Arrhythmias of the European Society of Cardiology and of the Scientific Council on Cardiomyopathies of the World Heart Federation. *Circulation.* 2000;101:E101–E106.
- Ling LH, Khammy O, Byrne M, et al. Irregular rhythm adversely influences calcium handling in ventricular myocardium: implications for the interaction between heart failure and atrial fibrillation. *Circ Heart Failure.* 2012;5:786–793.
- Metzger JT, de Chillou C, Cheriex E, et al. Value of the 12-lead electrocardiogram in arrhythmogenic right ventricular dysplasia, and absence of correlation with echocardiographic findings. *Am J Cardiol.* 1993;72:964–967.
- James CA, Bhonsale A, Tichnell C, et al. Exercise increases age-related penetrance and arrhythmic risk in arrhythmogenic right ventricular dysplasia/cardiomyopathy-associated desmosomal mutation carriers. *J Am Coll Cardiol.* 2013;62:1290–1297.