



Breast Carcinoma After Ocrelizumab Therapy in Multiple Sclerosis Patients: A Case Series and Literature Review

Andrew Kelsey, MD¹, Gabriella Casinelli, MD¹, Medha Tandon, MD², Shitiz Sriwastava, MD^{1,3} 

¹Department of Neurology, Rockefeller Neuroscience Institute, West Virginia University, Morgantown, WV, USA. ²Department of Neurology, University of Pittsburgh Medical Center, Pittsburgh, PA, USA. ³West Virginia Clinical and Translational Science Institute, Morgantown, WV, USA.

Journal of Central Nervous System Disease
Volume 13: 1–7
© The Author(s) 2021
Article reuse guidelines:
sagepub.com/journals-permissions
DOI: 10.1177/11795735211037785


ABSTRACT

Ocrelizumab is a humanized CD20 monoclonal antibody which was approved for management of Relapsing Remitting Multiple Sclerosis (RRMS) and Primary Progressive Multiple Sclerosis (PPMS) in 2017. We present 2 patients, a 67-year-old woman with history of PPMS and a 42-year-old woman with RRMS, who were started on ocrelizumab and were diagnosed with invasive ductal cell breast carcinoma after 2 years of ocrelizumab infusion followed by discontinuation of the drug. Large trials conducted for ocrelizumab showed malignancies in a total of 4 cases with RRMS in OPERA 1 trial conducted over 2 years from 2011 to 2013 (breast cancer, renal cell carcinoma, and melanomas) and in 11 cases with PPMS seen in ORATORIO trial conducted in 2017. There are currently no other published case reports of breast cancer in setting of ocrelizumab use for MS outside of large trials on literature review.

KEYWORDS: ocrelizumab, multiple sclerosis, *in situ* breast carcinoma, malignancy in MS, disease-modifying therapies

TYPE: Case Series

DECLARATION OF CONFLICTING INTERESTS: The authors declared no potential conflicts of interest with respect to the research, authorship, and/or publication of this article.

FUNDING: The authors received no financial support for the research, authorship, and/or publication of this article.

ETHICS STATEMENT: The authors obtained approval by the WVU institutional review board (approval #2011176554) and the article complies with the WVU institutional review board guidelines. Both patients provided informed consent.

CORRESPONDING AUTHOR: Shitiz Sriwastava, MD, Department of Neurology, Rockefeller Neuroscience Institute, West Virginia University Phone: 813-410-2578. Email: shitiz.sriwastava@hsc.wvu.edu

Introduction

Multiple sclerosis (MS) is a debilitating disease caused by an autoimmune demyelinating process affecting the central nervous system (CNS). MS commonly affects women 2–3 times more than men, with peak ages of onset between 20 and 50 years.¹

Despite the aggressive nature of the disease, there have been vast developments of key immunomodulation therapies in the form of disease modifying therapies (DMTs) to help prevent deterioration and disability in the disease process by preventing further inflammatory reactions. The DMTs act by suppressing the immune response against brain cells and to reduce the inflammatory cascade.² Over the years, there has been an evolution of various DMTs with different mechanisms of action that have changed the long-term prognosis of MS.

However, with the increasing use of DMTs for disease control, neurologists must also be mindful of the suspected increased risks associated with DMT use. The disease itself inadvertently increases the risk of infection and malignancy, which is subsequently exaggerated by the additional factors of immunosuppression in patients being managed with DMTs.^{3–5} Unfortunately, there are no clear guidelines with regard to screening or management of malignancy in the setting of DMT related to MS or how to manage a new diagnosis of malignancy in these subgroups of patients. Depending upon the type of

malignancy, there have been varying studies showing increased, decreased, or similar risk of developing cancer in MS patients as compared to the general population.^{3,6–8} There have been overall consensus for certain immunosuppressants such as fingolimod, natalizumab, and alemtuzumab, leading to an increased risk of malignancy with increasing duration of treatment and cumulative dose.^{4,9–15}

Ocrelizumab, an immunosuppressive DMT used in the management of MS, is a humanized monoclonal antibody that targets the pre-B and mature B cells expressing the CD20 antigen on their cell surface. Through modulation of the immune response, ocrelizumab interferes with the disease process at many levels including antigen presentation, cytokine release, antibody production, and aggregation of lymphocytes. Common adverse reactions associated with ocrelizumab are mostly related to increased infections including skin infections and upper respiratory infections; however, malignancy particularly of the breast has been reported earlier in the clinical trials.^{16–18}

Here, we present 2 interesting and unique cases of middle-aged women on ocrelizumab for management of MS who eventually developed breast cancer. We also present various associations of malignancies in patients diagnosed with MS (refer [Table 1](#)) and the associations of various malignancies



Creative Commons Non Commercial CC BY-NC: This article is distributed under the terms of the Creative Commons Attribution-NonCommercial 4.0 License (<https://creativecommons.org/licenses/by-nc/4.0/>) which permits non-commercial use, reproduction and distribution of the work without further permission provided the original work is attributed as specified on the SAGE and Open Access pages (<https://us.sagepub.com/en-us/ham/open-access-at-sage>).

with usage of several DMT medications (refer Table 2). We conducted a thorough literature review in April 2021 using the terms “DMTs and malignancy”; “DMTs and breast cancer”; “Ocrelizumab and breast cancer.” We searched PubMed and

Scopus databases for identifying case series and case reports published between January 01, 1995, and March 15, 2021, whereas review articles and consensus statements were excluded from the analysis.

Table 1. Large Cohort Studies Highlighting the Mean Age at the Diagnosis of Malignancy, Type of MS Medication, Type of Malignancy, and Duration from the Medication Start to the Onset of Malignancy.

AUTHOR/ STUDY YEAR	STUDY TYPE	MEDICATION STUDIED	NUMBER OF MS CASES WITH (GENDER)	NUMBER OF CASES WITH MALIGNANCY	MEAN AGE OF PATIENTS AT MALIGNANCY DIAGNOSIS	TYPE OF MALIGNANCY
Midgard et al ⁶	Retrospective study	NA	1271 (530 M/741 F)	73	NA	Breast cancer; cancer of urinary tract
Etemadifar et al ²¹	Cohort study	NA	1718 (388 M/1330 F)	23	F = 44.1 ± 9.9 M = 34 ± 4	11 had breast cancer, 3 lymphoma, 3 nervous system cancer, and 6 had other types of cancer (endocrine glands, bone, connective tissue, and secondary and unspecified sites)
Møller et al ⁷	Cohort	NA	5359 (NA)	210	(0–49 years: 55%; 50+ years: 45%)	Non-melanoma skin cancer, urinary tract, and nasopharyngeal carcinomas
Sumelahti et al ²²	Cohort prospective	NA	1597 (NA)	85	NA	Hematological Nervous system
Kingwell et al ²⁷	Cohort prospective	NA	6820(NA)	410	NA	Non-melanoma skin cancer
Hajiebrahimi et al ²⁰	Cohort	NA	19330 (NA)	471	<18 = 1 18–40 = 121 41–54 = 205 55–64 = 87 >65 y = 57	Breast cancer
Nørgaard et al ²⁴	Cohort study	NA	10752 (NA)	608	<25 = 8 25–29 = 18 30–34 = 34 35–39 = 65 40–44 = 91 45–49 = 103 50–54 = 109 55–59 = 96 60–64 = 44 65–69 = 26 70–74 = 10 75–79 = 4	Melanoma
Nielsen et al ⁸	Population based register	NA	11817 (NA)	1037	NA	Breast cancer
Achiron et al ²⁵	Cohort	NA	1338 (NA)	63	NA	Non-statistically significant breast cancer

F, female; M, male; MS, multiple sclerosis; NA, not available.

Table 2. Case Report and Case Series Highlighting the Age, Type of MS Medication, Type of Malignancy, and Duration from the Medication Start to the Onset of Malignancy.

AUTHOR/STUDY YEAR	STUDY TYPE	MEDICATION STUDIED	GENDER	AGE	TYPE OF MALIGNANCY
Amaria RN et al/2008	Case report	Patient 1: IFN-β1a	2 F	Pt 1= 53	Breast cancer
		Patient 2: Glatiramer acetate		Pt 2= 48	
Madray et al ¹⁵	Case report	Glatiramer acetate	F	33	Cutaneous anaplastic large cell Lymphoma
Walker et al ²⁶	Case report	Glatiramer acetate	F	43	Melanoma
Landais et al ¹⁶	Case report	Teriflunomide	F	54	Lymphoma
Mahajan et al ¹⁷	Case report	Fingolimod	M	61	Merkel cell carcinoma
Killestein et al ⁹	Case report	Fingolimod	1 M/4F	Pt1=44	Melanoma
				Pt2=38	
				Pt3=44	
				Pt4=32	
				Pt5=45	
Conzett et al ¹⁸	Case report	Fingolimod	F	39	Melanoma
Papathemeli et al ²⁷	Case report	Fingolimod	F	69	Primary cutaneous CD30(+) anaplastic large-cell T-cell lymphoma
Cohan et al ²⁸	Case report	Fingolimod	M	34	Acute lymphoblastic leukemia
Walker et al ²⁹	Case report	Fingolimod	M	46	Kaposi sarcoma
Pace et al ¹¹	Case report	Alemtuzumab	F	34	Melanoma
Bergamaschi et al ³⁰	Case report	Natalizumab	F	39	Melanoma
Schweikert et al ¹⁰	Case report	Natalizumab	M	40	Primary central nervous system lymphoma
Phan-Ba R et al ³¹	Case report	Natalizumab	M	40	Primary central nervous system lymphoma

F, female; M, male; MS, multiple sclerosis.

Case Report #1

A 67-year-old Caucasian woman with hypertension and hyperlipidemia with a prior clinical history of bilateral optic neuritis and balance difficulty since 2003 was diagnosed with PPMS based on MRI and CSF findings. CSF analysis showed isolated oligoclonal bands 7, IgG index of 0.56, protein 38 mg/dl, CSF ACE 1.7, WBC 0, and glucose 52 mg/dl. MRI showed T2/FLAIR changes in periventricular region and MRI cervical spine showed T2 plaque at C5-C6 (refer Figure 1).

She had no past or family history of melanoma or breast cancer which was clearly documented and confirmed prior to starting any therapy. She underwent menopause in her 50s and was not on any hormone replacement therapy. She did not consume alcohol, but she used to smoke cigarettes less than 1/2 pack/day for 3 years, 25 years ago. From December 2017, she was started on ocrelizumab infusions, every 6 months, in view of her persisting balance problems due to her PPMS. Patients' prior annual mammogram reports before starting ocrelizumab

and up till 2018 showed symmetric fibro-glandular breast tissue pattern with no suspicious microcalcification and no mass or skin changes.

She denies any hospital admissions in the past for MS exacerbations. In August 2019, she underwent routine bilateral screening mammogram that revealed architectural distortion in the right breast in the form of a 9 mm × 6 mm irregularly shaped, non-parallel hypoechoic mass with angular margins and no suspicious finding in the left breast. Subsequent ultrasound showed 9 × 9 × 6 mm irregularly shaped hypoechoic mass in the right breast 2 cm deep to the nipple. A biopsy of the mass was performed and she was diagnosed with ER+/PR+/HER2-invasive ductal carcinoma of the right breast T1N0M0 stage 1. She was started on anastrozole 1 mg daily and underwent right partial mastectomy for the management of this condition. Ocrelizumab was discontinued following the diagnosis of malignancy as this correlation has been found in earlier clinical trials of ocrelizumab.^{17,18}

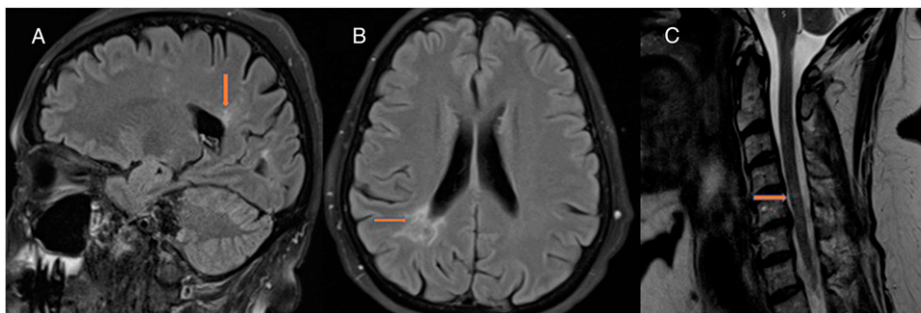


Figure 1. Sagittal (A) and axial (B) FLAIR MRI shows right sided irregular hyperintensity in periventricular region. (C) T2 weighted MRI sagittal section shows hyperintensity in spinal cord at the level of C5 and C6 vertebrae. MRI, magnetic resonance imaging.

Following the surgery, she was counseled about the suspected increased risk of breast cancer with ocrelizumab. Her diagnosis of breast cancer significantly reduced available treatment options and all other DMTs for MS were discussed with her. She opted of on any other MS medications and preferred to be monitored clinically. She was asked to report any new neurological symptom, which could be indicative of a relapse upon which she would be started on steroids. She is currently monitored clinically and radiologically (MRI scan) at an interval of 12 months. She is clinically stable and not currently on any DMT.

Case Report #2

A 42-years old Caucasian woman with history of RRMS with prior clinical events of bilateral lower extremity weakness and right lower extremity numbness in 1999 and cognitive impairment with memory loss. MS diagnosed based on MRI imaging and CSF study. As diagnosis was established at an outside facility, the patient's diagnostic CSF labs are not available at the time. MRI performed in 2019 showed T2/FLAIR changes in the large centimeter size tumefactive lesion in the bilateral periventricular area in the frontal lobe in the atrium and with corresponding patchy enhancement of the left periventricular lesion with a few other discrete lesions in the deep white matter and the frontal white matter. MRI of the T-spine shows T2 plaque at the T10-T11 level (Figure 2).

She had no past personal history of malignancy and no family history of breast cancer. She had a history of excessive menorrhagia requiring radiofrequency ablation therapy, following which she stopped menstruating while using Depo-Provera as birth control. She has never been on any hormone replacement therapy. She has minimal alcohol use and remote tobacco use, having quit in 2011 with only episodic tobacco use prior to this.

Her current treatment includes ocrelizumab infusions, every 6 months, starting October 2019. She was previously on Copaxone and Avonex. She required hospitalization for MS exacerbation in June 2019, when she transferred care to our facility. She was undergoing annual mammogram and ultrasound for the last 10 years due to dense breasts with last negative screening being in February 2020. In October 2020, there was a

lesion on left breast concerning for a nodule 11 mm in size with some microcalcification on routine mammogram. On follow-up breast ultrasound, there was a 6 mm nodule in the right breast and an 11 mm × 9 mm solid nodule with calcification and vascularity in the left breast. A complex cystic aspiration was performed to evaluate the right breast nodule, and a core sample biopsy along with a sentinel lymph node biopsy was performed for the left breast nodule followed by left complete mastectomy. Left breast nodule was histologically consistent with ER+/PR+/HER2-invasive ductal carcinoma with focal associated ductal carcinoma in situ (DCIS) of the left breast T1N0M0 stage 1 with negative margin from resection. All 4 sentinel lymph nodes were negative for metastatic disease. As per radiation oncology, she completed 6 cycles of adjuvant whole breast radiation for the left breast carcinoma. Right breast was biopsy confirmed benign cyst.

As with Case #1, ocrelizumab was discontinued following the diagnosis of malignancy as correlation has been found in earlier clinical trials of ocrelizumab after counseling on suspected increased risk of breast cancer with ocrelizumab.^{17,18} Her diagnosis of breast cancer and plan for neoadjuvant chemotherapy significantly reduced available treatment options, and all other disease modifying therapies for MS were discussed with her. It was decided to start Solu-Medrol 1 g IV monthly and restart Copaxone as disease modifying therapy. She is currently followed clinically every 6 months and radiologically (MRI) yearly. She is currently stable and remains on Copaxone with monthly Solu-Medrol infusions at this time.

Discussion

In this case series, we present 2 cases of breast cancer that are suspected to have developed following ocrelizumab therapy in patients with MS after its FDA approval for RRMS and PPMS since 2017.¹⁶ The use of DMT in MS patients has significantly changed the management of the disease and has shown promising results for reducing the morbidity associated with the disease. Monoclonal antibodies against CD20 cell surface marker such as rituximab, second generation ocrelizumab approved by FDA in 2017 for RRMS and PPMS, and third generation ofatumumab, which was recently approved by the

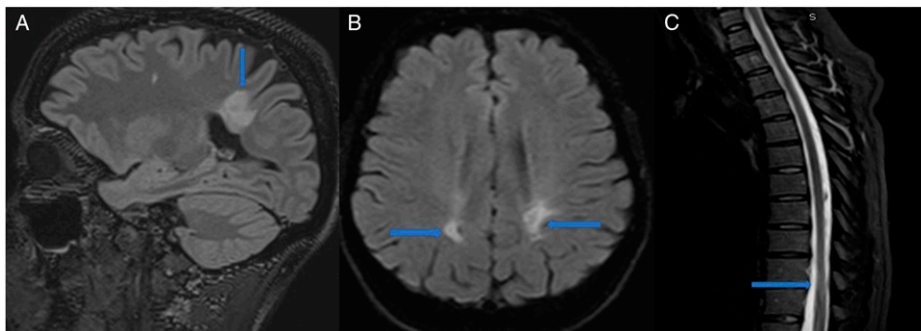


Figure 2. Sagittal (A) and axial (B) FLAIR MRI shows 2 discrete irregular hyperintensity in periventricular region. (C) T2 weighted MRI sagittal section shows hyperintensity in spinal cord at the level of T9 and T10 vertebrae. MRI, magnetic resonance imaging.

FDA in 2020 for RRMS, have revolutionized the treatment of MS.¹⁶ However, the modulation of the innate immune mechanism and the suppression of the immune system caused by the use of DMT is postulated to contribute to an increased risk of malignancy in patients who are on long-term treatment with these drugs.^{4,5} Most of the studies report that there is no significant difference from the general population, but a few studies and clinical trials have documented a significant increased risk of developing varied malignancies with the usage of DMTs, such as melanoma, lymphoma, and breast carcinoma^{4,19-22} (refer Table 2).

Several mechanisms of actions have been postulated for various DMTs, including activity on the CD20 receptors for the medications like rituximab, ocrelizumab, and ofatumumab. Rituximab is also being increasingly used for management against many carcinomas (ie, B-cell lymphomas, Hodgkin lymphoma, Burkitt lymphoma, and B-cell lymphoblastic leukemias) as malignant B cells vastly express CD20 receptors.²³ However, despite the use of anti-CD20 therapies in some cancers, it may also increase the risk for other cancers in treated patients.⁵

Ocrelizumab is a relatively newer generation immunomodulator acting against the CD20 monoclonal antibody.^{16,17} Large trials conducted for ocrelizumab showed malignancies in a total of 4 cases with RRMS in OPERA 1 trial conducted over 2 years from 2011 to 2013 (breast cancer, renal cell carcinoma, and melanomas) and in 11 cases with PPMS seen in ORATORIO trial conducted in 2017.^{17,18} This is likely related to the predisposition of malignancies by the deactivation of the protective mechanisms of the normal B cells against tumor production and lysis of tumor. Recent studies have shown that B-cell suppression can lead to worsening of outcomes in breast cancer patients.⁴ There are no currently published cases documenting development of breast cancer after treatment with ocrelizumab for MS outside of large trials on literature review.

The protective role of CD20 B cells along with cytotoxic T cells plays an important role in prevention of development of malignancies, and their reduced presence in these patients could be detrimental in this population. Moreover, it has been found that timing of initiation of anti-CD20 therapy plays an

important role in cancer development. It was shown in mice that starting anti-CD20 therapy prior to tumor initiation decreased the chance of metastatic involvement, whereas initiation after tumor increased the cancer growth and survival with metastasis.⁴ This should be taken into consideration with MS patients in the context of the stage of cancer when deciding treatment.

In a large cohort study, 11,817 patients enrolled in the Danish Multiple Sclerosis Registry showed an increased risk of breast cancer by 1.6-fold (relative risk [RR], 1.56). On the contrary, it showed 16% decreased risk of all cancers in men, whereas the study did not show an increase in overall risk of cancer in women except for breast cancer risk. It was also noted that tumor size tended to have larger sizes in MS patients when compared to patients without MS. Sixteen percent of women with MS in their studies had tumors ≥ 5 cm compared with 11% in the non-MS population.⁸

In the literature review summarized in Table 1, there are multiple studies, including retrospective, cohort, and registries that evaluate hundreds to thousands of MS patients that eventually developed malignancies during treatment and specifically the commonly diagnosed malignancies. For example, in the studies of Midgard and Etemadifar, there was a higher likelihood of breast cancer diagnosis within the MS patients. Other malignancies were found but were not deemed significant when compared to the general population, including urinary tract, skin cancers, nervous system, or hematological disease such as lymphoma. Hajiebrahimi focused on premenopausal and postmenopausal breast cancer among MS patients,²⁴ which showed an overall increase in postmenopausal breast cancer. As seen with Moller cohort study, the diagnosis of uncommon malignancies may in part be due to over diligence in screening. In Kingswell cohort prospective study, there were 6820 patients, with 410 of them being diagnosed with malignancies, and demonstrated an overall lower cancer risk in this population. Nørgaard demonstrated an overall increase in melanoma compared to other malignancies within thousands of MS patients in the Danish population^{6-8,25-29} (refer Table 1).

Overall, there has been an increase in incidence of malignancy seen in MS patients treated on with immunomodulant therapies that need further investigation^{9-12,19-22,30-34} (refer

Table 2). Given that MS patients can be exposed to many medications over the course of the disease with different mechanisms of action, these can eventually alter the immune system, which indirectly increases their cancer potential. One study demonstrated the higher risk of cancer in MS patients due to prior exposure to DMTs, rather than the disease itself.³⁵ It is clearly evident that these patients need extra caution when selecting therapies, and benefits vs. risks must be weighed on an individual basis. Further large-scale studies are required to formulate proper guidelines in screening and monitoring of the patients with MS on DMTs. Additionally, more studies can be helpful for the clinicians to better understand the available alternatives of DMTs after an association with malignancy has been found.

Conclusion

As immunosuppressive therapy for MS becomes more prevalent, long-term follow-up studies documenting the incidence and prognosis of breast cancer in this cohort are needed. Current data in the literature reflect the need for further study in ascertaining the risk of biologically poor prognosis breast cancer development in patients with MS treated with immunosuppressive therapy. There has been an increase in cancers seen in MS patients treated with immunosuppressive therapies, that needs further investigation. Most of the studies report that there is no significant difference from the general population, but a few studies have demonstrated a significant increased risk of developing breast cancer.

Acknowledgments

West Virginia Clinical and Translational Science Institute, Morgantown, SS supported in part by WVCTSI via US National Institute of General Medical Sciences of National Institute of Health under award under 5U54GM104942-05.

Author Contributions

Conceptualization: SS.

Drafting the manuscript: AK, GC, MT, and SS.

Final edits: SS.

ORCID iD

Shitiz Sriwastava  <https://orcid.org/0000-0001-6844-3287>

REFERENCES

- Weinshenker BG. Epidemiology of multiple sclerosis. *Neurol Clin.* 1996;14(2):291-308. doi:10.1016/s0733-8619(05)70257-7.
- Smith AL, Cohen JA, Hua LH. Therapeutic targets for multiple sclerosis: current treatment goals and future directions. *Neurotherapeutics.* 2017;14(4):952-960. doi:10.1007/s13311-017-0548-5.
- Bahmanyar S, Montgomery SM, Hillert J, Ekblom A, Olsson T. Cancer risk among patients with multiple sclerosis and their parents. *Neurology.* 2009;72(13):1170-1177. doi:10.1212/01.wnl.0000345366.10455.62.
- Melamed E, Lee MW. Multiple sclerosis and cancer: The Ying-Yang effect of disease modifying therapies. *Front Immunol.* 2020;10:2954. doi:10.3389/fimmu.2019.02954.
- Ragonese P, Aridon P, Vazzoler G, Mazzola MA, Lo Re V, Lo Re M, et al. Association between multiple sclerosis, cancer risk, and immunosuppressant treatment: a cohort study. *BMC Neurol.* 2017;17(1):155. doi:10.1186/s12883-017-0932-0.
- Midgard R, Glatre E, Grønning M, Riise T, Edland A, Nyland H. Multiple sclerosis and cancer in Norway. A retrospective cohort study. *Acta Neurol Scand.* 1996;93(6):411-415. doi:10.1111/j.1600-0404.1996.tb00019.x.
- Møller H, Kneller RW, Boice JD Jr, Olsen JH. Cancer incidence following hospitalization for multiple sclerosis in Denmark. *Acta Neurol Scand.* 1991;84(3):214-220. doi:10.1111/j.1600-0404.1991.tb04941.x.
- Nielsen NM, Rostgaard K, Rasmussen S, Koch-Henriksen N, Storm HH, Melbye M, et al. Cancer risk among patients with multiple sclerosis: a population-based register study. *Int J Canc.* 2006;118(4):979-984. doi:10.1002/ijc.21437.
- Killestein J, Leurs CE, Hoogervorst ELJ, van Eijk J, Mostert JP, van den Eertwegh AJM, et al. Five cases of malignant melanoma during fingolimod treatment in Dutch patients with MS. *Neurology.* 2017;89(9):970-972. doi:10.1212/WNL.0000000000004293.
- Schweikert A, Kremer M, Ringel F, Liebig T, Duyster J, Stüve O, et al. Primary central nervous system lymphoma in a patient treated with natalizumab. *Ann Neurol.* 2009;66(3):403-406. doi:10.1002/ana.21782.
- Pace A, Zajicek JP. Melanoma following treatment with alemtuzumab for multiple sclerosis. *Eur J Neurol.* 2009;16(4):e70-e71. doi:10.1111/j.1468-1331.2009.02552.x.
- Bergamaschi R, Montomoli C. Melanoma in multiple sclerosis treated with natalizumab: causal association or coincidence?. *Mult Scler.* 2009;15(12):1532-1533. doi:10.1177/1352458509347154.
- Polman CH, O'Connor PW, Havrdova E, Hutchinson M, Kappos L, Miller DH, et al. A randomized, placebo-controlled trial of natalizumab for relapsing multiple sclerosis. *N Engl J Med.* 2006;354(9):899-910. doi:10.1056/NEJMoa044397.
- Castela E, Lebrun-Frenay C, Laffon M, Rocher F, Cohen M, Leccia NC, et al. Evolution of nevi during treatment with natalizumab: A prospective follow-up of patients treated with natalizumab for multiple sclerosis. *Arch Dermatol.* 2011;147(1):72-76. doi:10.1001/archdermatol.2010.243.
- Sartori DC, Westerberg C, Grundmark B. Natalizumab and rapidly evolving central nervous system lymphoma in VigiBase. *InDrug Safety.* 2017;40(10):974.
- Florou D, Katsara M, Feehan J, Dardiotis E, Apostolopoulos V. Anti-CD20 Agents for Multiple Sclerosis: Spotlight on Ocrelizumab and Ofatumumab. *Brain Sci.* 2020;10(10):758. doi:10.3390/brainsci10100758.
- Hauser SL, Bar-Or A, Comi G, Giovannoni G, Hartung HP, Hemmer B, et al. OPERA I and OPERA II Clinical Investigators. Ocrelizumab versus Interferon Beta-1a in Relapsing Multiple Sclerosis. *N Engl J Med.* 2017;376(3):221-234. doi:10.1056/NEJMoa1601277.
- Gelfand JM, Cree BAC, Hauser SL. Ocrelizumab and Other CD20+ B-Cell-Depleting Therapies in Multiple Sclerosis. *Neurotherapeutics.* 2017;14(4):835-841. doi:10.1007/s13311-017-0557-4.
- Madray MM, Greene JF Jr, Butler DF. Glatiramer acetate-associated, CD30+, primary, cutaneous, anaplastic large-cell lymphoma. *Arch Neurol.* 2008;65(10):1378-1379. doi:10.1001/archneur.65.10.1378.
- Landais A, Alhendji R, Gouverneur A, Teron-Aboud B. A case of lymphoma in a patient on teriflunomide treatment for relapsing multiple sclerosis. *Mult Scler Relat Disord.* 2017;17:92-94. doi:10.1016/j.msard.2017.07.001.
- Mahajan KR, Ko JS, Tetzlaff MT, Hudgens CW, Billings SD, Cohen JA. Merkel cell carcinoma with fingolimod treatment for multiple sclerosis: A case report. *Mult Scler Relat Disord.* 2017;17:12-14. doi:10.1016/j.msard.2017.06.004.
- Conzett K, Kolm I, Jelcic I, Kamarachev J, Dummer R, Braun R, et al. Melanoma occurring during treatment with fingolimod for multiple sclerosis: a case report. *Arch Dermatol.* 2011;147(8):991-992. doi:10.1001/archdermatol.2011.212.
- Salles GA-O, Barrett M, Foà R, Maurer J, O'Brien S, Valente N, et al. Rituximab in B-Cell hematologic malignancies: A review of 20 years of clinical experience. *Adv Ther.* 2017;34(10):2232-2273. doi:10.1007/s12325-017-0612-x.
- Hajiebrahimi MA-O, Montgomery S, Burkil S, Bahmanyar S. Risk of Premenopausal and Postmenopausal Breast Cancer among Multiple Sclerosis Patients. *PLoS One.* 2016;11(10):e0165027. doi:10.1371/journal.pone.0165027.
- Etemadifar M, Jahanbani-Ardakani H, Ghaffari S, Fereidan-Esfahani M, Changaei H, Aghadoost N, et al. Cancer risk among patients with multiple sclerosis: A cohort study in Isfahan, Iran. *Caspian J Intern Med.* 2017;8(3):172-177. doi:10.22088/cjim.8.3.172.
- Sumelahti ML, Pukkala E, Hakama M. Cancer incidence in multiple sclerosis: a 35-year follow-up. *Neuroepidemiology.* 2004;23(5):224-227. doi:10.1159/000079947.
- Kingwell E, Bajdik C, Phillips N, Zhu F, Oger J, Hashimoto S, et al. Cancer risk in multiple sclerosis: findings from British Columbia, Canada. *Brain.* 2012;135(Pt 10):2973-2979. doi:10.1093/brain/awb148.
- Nørgaard M, Veres K, Didden EM, Wormser D, Magyari M. Multiple sclerosis and cancer incidence: A Danish nationwide cohort study. *Mult Scler Relat Disord.* 2019;28:81-85. doi:10.1016/j.msard.2018.12.014.
- Achiron A, Gail M, Mandel M, Pee D, Ayyagari R, Rotstein Z. Cancer incidence in multiple sclerosis and effects of immunomodulatory treatments. *Breast Canc Res Treat.* 2005;89(3):265-270. doi:10.1007/s10549-004-2229-4.

30. Walker J, Smylie A, Smylie M. An Association Between Glatiramer Acetate and Malignant Melanoma. *J Immunother*. 2016;39(7):276-278. doi:10.1097/CJI.0000000000000131.
31. Papathelemi D, Hildebrandt U, Zettl UK, Ulrich J. Development of a primary cutaneous CD30(+) anaplastic large-cell T-cell lymphoma during treatment of multiple sclerosis with fingolimod. *Mult Scler*. 2016;22(14):1888-1890. doi:10.1177/1352458516645868.
32. Cohan S, Godwin J, Gaedeke L. Acute lymphoblastic leukemia in a man treated with fingolimod for relapsing multiple sclerosis. *J Investig Med High Impact Case Rep*. 2015;3(1):2324709615575551. doi:10.1177/2324709615575551.
33. Walker S, Brew B. Kaposi sarcoma in a fingolimod-treated patient with multiple sclerosis. *J Clin Neurosci*. 2016;31:217-218. doi:10.1016/j.jocn.2016.03.001.
34. Phan-Ba R, Fau - Bisig B, Deprez M, De Prijck B, Delrue G, Herens C, Moonen G, et al. Primary central nervous system lymphoma in a patient treated with natalizumab. *Ann Neurol*. 2011;69(6):1060-1061. doi:10.1002/ana.22296.
35. D'Amico E, Chisari CG, Arena S, Zanghi A, Toscano S, Lo Fermo S, et al. Cancer risk and multiple sclerosis: Evidence from a large italian cohort. *Front Neurol*. 2019; 10:337. doi:10.3389/fneur.2019.00337.