

COVID-19 Vaccine-Induced Immune Thrombotic Thrombocytopenia (VITT) and Cerebral Venous Sinus Thrombosis (CVST)- Lessons for India

Erum Khan¹, Shriya Bavishi¹, Arvind K. Sharma^{1,2}, Vijay K. Sharma³, Vinay Goyal⁴

¹Department of Medicine, BJ Medical College and Civil Hospital, Ahmedabad, Gujarat, ²Department of Neurology, Zydus Hospital, Ahmedabad, Gujarat, India, ³Yong Loo Lin School of Medicine, National University of Singapore and Division of Neurology, National University Hospital, Singapore, ⁴Department of Neurology, Medanta The Medicity, Gurugram, Haryana, India

Abstract

The COVID-19 pandemic evolved rapidly, overwhelming health care systems around the world. The cost to life and socioeconomic burden prompted a search for new treatments and vaccines. Several collaborations developed and could deliver state-of-the-art vaccines with acceptable efficacy and safety in record time. Recently, vaccination with Oxford-AstraZeneca and Johnson and Johnson vaccines was halted due to the reported adverse effects of vaccine-induced immune thrombotic thrombocytopenia (VITT) and cerebral venous sinus thrombosis (CVST). Although a detailed risk-benefit analysis led to their reinstatement, physicians across the world are still trying to understand the pathophysiology and mechanisms of these neurological adverse effects in order to better identify, diagnose, and treat them. One of the mechanisms that have been implicated is related to the adenovirus-based vector of these vaccines. COVISHIELD, which is the most widely administered vaccine in India, also shares the same vector. As India enters the next phase of vaccine distribution for younger adults, there are chances that such adverse effects may emerge. In this review, we analyze the temporary suspension of the administration of the vaccines due to VITT/CVST, summarize the existing guidelines about diagnosis and treatment of these neurological disorders as well as the need for increasing pharmacovigilance and awareness among physicians. Screening for potential risk factors, avoiding aggravating factors like dehydration, and providing choices in vaccinating the high-risk populations could help in avoiding these rare but potentially fatal adverse outcome.

Keywords: COVID-19, CVST, vaccine, VITT

INTRODUCTION

Since the first identified cluster of severe acute respiratory syndrome coronavirus 2 (SARS-CoV-2) in Wuhan, China in December 2019, the COVID-19 pandemic has evolved rapidly, overwhelming health care systems around the world.^[1] As of August 13, 2021, more than 205,338,159 confirmed cases and 4,333,094 deaths have been documented globally.^[2] To gauge the magnitude, the number of deaths from COVID-19 has already exceeded the number of people who succumbed to influenza in the century since the last pandemic.^[3]

The cost to life and socioeconomic burden caused by the COVID-19 pandemic necessitated an unprecedented speed in the development and delivery of vaccines.

The effort started with over 200 candidate vaccines, of which 18 entered into a human clinical trial for testing their efficacy and safety. Several multinational pharmaceutical companies sought partners in India for ramping up the production of vaccines (AstraZeneca partnered with Serum Institute of India, whereas Johnson and Johnson engaged Biological E India).^[4]

In India, three approved vaccines – COVISHIELD, COVAXIN, and SPUTNIK V are being administered to the general public.^[5] COVISHIELD is a recombinant, replication-deficient chimpanzee adenovirus vector-based

vaccine, encoding the SARS-CoV-2 Spike (S) glycoprotein. It has been developed by the Oxford-AstraZeneca and is being manufactured locally by the Serum Institute of India (SII).^[6] COVAXIN, an inactivated whole-virion vaccine, is India's indigenous COVID-19 vaccine developed by Bharat Biotech, the Indian Council of Medical Research (ICMR), and the National Institute of Virology (NIV).^[7] Russian Direct Investment Fund (RDIF) collaborated with Dr. Reddy's Laboratories and launched SPUTNIK V, also an adenoviral-vector-based vaccine in major cities in India in May 2021.^[8] Many other candidate vaccines are in various stages of trials in India.

Address for correspondence: Dr. Arvind K. Sharma,
Department of Neurology, Zydus Hospital, Ahmedabad, Gujarat, India.
E-mail: dr_arvind10@yahoo.co.in

Submitted: 22-Jul-2021 **Revised:** 14-Aug-2021 **Accepted:** 25-Aug-2021

Published: 22-Oct-2021

This is an open access journal, and articles are distributed under the terms of the Creative Commons Attribution-NonCommercial-ShareAlike 4.0 License, which allows others to remix, tweak, and build upon the work non-commercially, as long as appropriate credit is given and the new creations are licensed under the identical terms.

For reprints contact: WKHLRPMedknow_reprints@wolterskluwer.com

DOI: 10.4103/aian.aian_669_21

Although mass vaccination is believed to mitigate COVID-19 outbreaks by decreasing infection rate, adverse outcomes, hospitalizations to intensive care units (ICU), and deaths,^[9] monitoring for postvaccination adverse events is important for evaluating the balance between risks and benefits for each authorized vaccine. Of particular concern is the rare occurrence of serious adverse events, especially vaccine-induced immune thrombotic thrombocytopenia (VITT) and cerebral venous sinus thrombosis (CVST). This review highlights the significance of these adverse events with respect to vaccination strategies in India and suggests recommendations to overcome them.

VITT AND CVST

CVST and thrombocytopenia together are called thrombosis-thrombocytopenia syndrome (TTS). TTS associated with COVID-19 vaccination has been termed vaccine-induced immune thrombotic thrombocytopenia (VITT).^[10] The case-finding definition according to the Brighton Collaboration draft for thrombosis with thrombocytopenia syndrome (TTS) is a platelet count $<150 \times 10^9/L$.

Two vaccines that have been associated with TTS include the Oxford-AstraZeneca [AZ] Vaxzevria (ChAdOx nCoV-19) and Johnson and Johnson [JJ] vaccines (AD26.COV2.S).^[11] The Center for Disease Control and Prevention (CDC) and Food and Drug Administration (FDA), investigated 15 reported cases of TTS in the United States (US) in patients who had received the JJ COVID-19 vaccine, whereas the European Medicines Agency's (EMA) investigation reported 169 cases of CVST among adults who had received the AZ vaccine in the European Union. These investigations led to the temporary suspension of vaccination with AZ vaccine in many European countries and the JJ vaccine in the US. This is important to note that both are adenoviral-vector-based vaccines.^[12]

COVISHIELD, the Indian form of the AZ vaccine is, so far, the most frequently used vaccine in India, with 468,183,309 doses administered as of August 13, 2021.^[13] Despite its extensive use, CVST incidents have not been reported in India thus far. However, according to the estimates made by the EMA, India should have had 320 cases for every 80 million doses administered.^[14]

In the initial case series of 39 patients who developed VITT after the AZ vaccine, symptoms developed between 5–24 days after the vaccination, over 80% of the patients were women, and most were <55 years old. The patients were healthy or otherwise medically stable at the time of the vaccination and only a few had prior thrombotic events or risk factors for thrombosis. Importantly, the mortality rates for TTS were approximately 40%.^[15] Similarly, for TTS, all patients in the initial series were white women aged 18–59 years and developed symptoms within a median of 8 days (range: 6–15 days).^[12] In addition to CVST, seven patients suffered from intracerebral hemorrhage and eight had non-CVST thromboses. Platelet nadirs ranged from $19 \times 10^3/\mu L$ to

$127 \times 10^3/\mu$, and D-dimer or fibrinogen values were abnormal in all patients. Due to the possible causal association, CDC updated its interim clinical considerations for use of authorized COVID-19 vaccines to indicate that women aged 18 to 49 years should be aware of the increased risk of TTS after receipt of the JJ vaccine.^[12]

Published estimates of the incidence of VITT range from 1 case per 26,000 to 1 case per 127,000 doses of AZ vaccine administration.^[16] The mortality due to TTS following AZ vaccination was 50% in Europe and 25% in US patients.^[12] Importantly, these mortality rates are much higher as compared to the baseline CVST mortality rate of 4.4%.^[17]

Course of action by national authorities

As of April 2021, 169 cases of CVST associated with TTS were reported amongst the recipients of approximately 34 million AZ vaccines in the European Union, whereas the US regulatory agencies reported 15 cases of TTS from about 7 million JJ vaccinees. Although the causal relationship between these vaccines and TTS was labeled as plausible,^[12] both CDC and EMA clearly stated that the overall benefits of the implicated vaccines outweigh the risks. Consequently, on April 23, 2021, the Advisory Committee on Immunization Practices recommended continued use of both vaccines for those aged ≥ 18 years.^[18] Published reports of cerebral venous thrombosis in association with VITT are shown in Table 1.

Currently, Norway and Denmark have suspended using the AZ vaccine, whereas Iceland and Germany have limited its use to people older than 60 years. The UK states that “it is preferable for adults aged <30 years without underlying health conditions to be offered an alternative nonadenoviral vector-based COVID-19 vaccine, if available.” Canada is offering the AZ vaccine to all adults, with additional warnings on the vaccine label. Similarly, the US has permitted the use of the JJ vaccine in all adults with information on the risk of TTS added to educational materials.^[24]

Table 1: Current published reports of cerebral venous thrombosis in association with vaccine-induced thrombosis-thrombocytopenia

Vaccine	AstraZeneca	Janssen	COVISHIELD
Reported CVST cases	413 ^[15,19-21]	13 ^[20]	1 ^[22]
Confirmed CVST cases	227 ^[15,19-21]	13 ^[20]	NA
Age	21-77 ^[23]	18-59 ^[23]	36 ^[22]
Symptoms	Headache, visual disturbance, leg/arm weakness ^[23]	Headache, lethargy, fever, pain, limb weakness. ^[23]	NA
Days from vaccination	5-24 days	6-15 days (median 8 days)	NA
Platelet factor 4-heparin assay	Positive ^[23]	Positive ^[23]	NA

The adverse effect of concern

CVST most commonly affects young adults (mean age 35–40 years), predominantly women of childbearing age. Over 80% of patients with CVST have at least one identifiable risk factor for thrombosis such as an inherited coagulopathy, an antecedent history of trauma, cancer, or hormonal contraception.^[25] Thrombocytopenia is an uncommon primary cause of CVST. Before the COVID-19 pandemic, registries showed a low prevalence and magnitude of the association between thrombocytopenia and CVST.^[26] In addition to rare thromboses, TTS associated with COVID-19 vaccination currently includes more common thromboses, such as deep vein thrombosis, pulmonary thromboembolism, ischemic stroke, and myocardial infarction.^[27] Both thrombocytopenia and CVST have been reported in patients with COVID-19, and prothrombotic events are a recognized complication.^[28] Studies found that the risk of CVST due to infection with COVID-19 is 8–10 times higher than the risk of CVST after receiving a COVID-19 vaccine.^[29]

CVST should be considered in young patients with unusual headaches or with stroke-like symptoms in the absence of typical cardiovascular risk factors. In cases of suspected CVST, either magnetic resonance imaging (MRI) or computerized tomography (CT) with a venogram can accurately detect CVST. VITT is more likely if symptoms start within the 4 to 28 days after vaccination.^[26] Blood tests should include a complete blood count with platelet count and peripheral smear, a prothrombin time, partial thromboplastin time, fibrinogen, D-dimer, and platelet factor 4 (PF4) antibody by enzyme-linked immunosorbent assay (ELISA). Thrombocytopenia with an elevated D-dimer, a normal blood film (apart from thrombocytopenia), and confirmation of a blood clot or intracranial hemorrhage on diagnostic imaging make the diagnosis of VITT presumptive. This is summarized in Figure 1.^[16] The International Society on Thrombosis and Hemostasis (ISTH) guidelines indicate that markedly elevated D-dimer levels of greater than four times the control value for venous thromboembolism are highly suggestive of VITT and should be treated accordingly.^[30]

Although the pathogenesis of VITT is not entirely clear, high levels of antibodies to PF4-polyanion complexes have been identified, a mechanism similar to autoimmune heparin-induced thrombocytopenia (HIT). However, the distribution of thrombi in patients with HIT differs from that in patients with VITT, where thrombosis occurs in an atypical location such as the cerebral veins, mesenteric veins, hepatic, portal, or splanchnic veins. COVID-19 vector-based vaccines likely induce the formation of antibodies against platelet antigens as part of the inflammatory reaction and immune stimulation. These antibodies subsequently cause massive platelet activation via the Fc receptor.^[15] Alternate mechanisms for VITT/TTS associated with adenoviral vector vaccines may be due to the binding of adenoviral particles to circulating platelets causing their activation and aggregation with subsequent release of PF4. As TTS is also seen in patients

Symptoms of Thrombosis or Bleeding
Onset between 4-28 days after vaccination

- | | |
|---|--|
| <ul style="list-style-type: none"> • New-onset headache • Focal Neurological symptoms • Seizures • Blurred vision • Double vision • Shortness of breath | <ul style="list-style-type: none"> • Chest pain • Abdominal pain • Limb swelling • Limb redness • Cold limbs • Bleeding and Skin bruises |
|---|--|

Figure 1: Flow chart for early recognition of symptoms of VITT and TTS

with COVID-19 infection, the potential cross-reactivity of the anti-SARS-CoV-2 spike protein antibodies with PF4 might play an important role. However, the absence of PF4/heparin-specific antibodies in confirmed COVID-19 patients suggests a different mechanism.^[23]

With the exception of hematologic findings (thrombocytopenia, extracranial thrombosis), the clinical presentation of the patients with TTS following COVID-19 vaccination is similar to typical CVST patients. Traditionally, unfractionated Heparin and Low-molecular-weight Heparins (LMWH) are the preferred initial anticoagulants of choice in CVST.^[31] However, due to some differences with HIT, their use in CVST following COVID-19 vaccination is not recommended. Accordingly, the current treatment recommendations state that patients with suspected CVST due to a COVID-19 vaccine should be treated with nonheparin anticoagulants such as argatroban, bivalirudin, danaparoid, fondaparinux, or a direct oral anticoagulant (DOAC). Heparin infusions and platelet transfusions are discouraged until HIT testing is negative. Intravenous immunoglobulins (IVIG) at a dose of 1 g/kg body-weight daily for 2 days have been recommended after laboratory testing for PF4 antibodies has been sent, to dampen prothrombotic response and improve platelet count. Once the platelet counts normalize, DOAC or vitamin K antagonists may be used.^[16,26]

In regions where there is no access to IVIG, systemic corticosteroid use can be considered.^[32,33] Patients unsuitable or progressing despite anticoagulation should be considered for direct endovascular treatment. In severe cases, progression of brain edema and/or hemorrhage can be rapid, and an early neurosurgical consult should be sought.^[19] The management and treatment guidelines for CVST in the context of VITT has been summarized in the flowchart in Figure 2.^[19]

The context of India

With respect to India's COVID-19 vaccination initiative, Bruce Y Lee (CUNY Graduate School of Public Health and Health Policy, NY, USA) told *The Lancet Infectious Diseases* that "India has the world's second-largest population and over one-seventh of all the people in the world. Therefore, getting high coverage of India's population with the COVID-19 vaccine will be important in controlling the global spread of SARS-CoV-2." According to Brian Wahl (Johns Hopkins Bloomberg School of Public Health, Baltimore, MA, USA), India's strong domestic vaccine sector has enabled the country to launch one of the largest and fastest COVID-19 vaccination campaigns in the world.^[34]

India began the administration of COVID-19 vaccines on 16 January 2021. As of August 13, 2021, India has administered 539,025,361 doses overall, COVISHIELD being the most widely used vaccine constituting 87% of the total doses. The government aims to vaccinate all eligible Indians by the end of this year, but the drive has been hobbled by the slow pace, shortage of doses, and vaccine hesitancy. Therefore, only 8.65% of the people have been fully vaccinated so far, whereas 30.2% have received the first dose.^[13,35]

There has been only one suspected report of VITT from India, out of a total of 304.5 million doses of COVISHIELD vaccine administered, whereas the Adverse Events Following Immunization (AEFI) report dated March 17, 2021 lists only three deaths with a possible temporal relationship to vaccine administration. One of these patients developed cerebrovascular accident and thrombocytopenia which is

highly suspicious for VITT. However, the evidence for a confident classification as a vaccine-related event was very weak. While two deaths were deemed coincidental, one death was unclassified, and one was labeled due to anaphylaxis.^[36] However, these numbers are far from the estimate by EMA. Whether, this can be attributed to misdiagnosis, failure of reporting, or documentation errors remains debatable.^[22]

AEFI surveillance program is an integral part of the routine immunization program in India to monitor vaccine safety during the postlicensure phase. National AEFI surveillance relies on passive surveillance and reporting by the public as well as private health functionaries and practitioners. According to the current guidelines, serious unexplained AEFI which occur within 30 days after vaccination and are not listed on the product label are to be immediately reported for further investigation (within 48 h) and also in the weekly reporting form. They are assessed for a causal association with the vaccine or vaccination process according to a predefined WHO algorithm and protocol. Multidisciplinary AEFI committees have been set up at national, state, and district levels which provide technical support to the program at various levels for investigating, causality assessment, and guidance for follow-up actions needed for serious, severe, and other AEFIs to boost community confidence in vaccines.^[37]

Currently, it is believed that AEFI system may be under-reporting as the current AEFI reporting rate for COVID vaccines is only 0.008%.^[13] One reason behind this belief is derived from the data from Global Vaccine Action Plan (GVAP), according to which country is expected to report at least 10 AEFIs for every 100,000 live births (estimated to be approximately 2600 for India) against the current number of approximately 1100 serious AEFIs annually.^[37]

Immediate response and appropriate medical management of serious AEFI cases is an integral part of the surveillance, especially in cases of serious events like CVST or TTS. Hence, younger recipients of the COVISHIELD vaccine should be instructed to report back immediately if they develop *de novo* headache, fever, or any other unusual clinical features. At the same time, clinicians should have high vigilance and a low threshold for investigating TTS and CVST in recently symptomatic individuals.

Until recently, the phased vaccination drive was biased towards achieving high vaccination rates for the elderly and vulnerable individuals. With India's expansion of the vaccination drive towards the younger population, particularly at higher risk for CVST and TTS, we may expect increasing reports in the near future. A preliminary screening to assess the causal or demographic relationship, if any, with the CVST/VITT episodes can be of benefit. This may include gathering information about the history of thrombophilia conditions among vaccine recipients and their families (like protein S, protein C, or antithrombin III deficiency, hyperhomocysteinemia), history of smoking, medications like oral contraceptive pills or hormone replacement therapies, recent trauma, surgical or

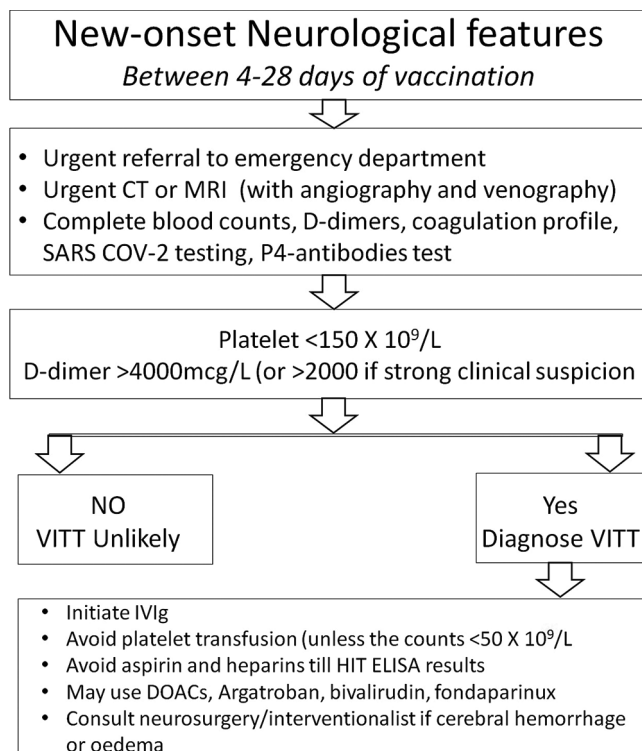


Figure 2: Management approach for VITT

emergency procedures, generalized or localized infections, and neoplasms.^[38] Of particular concern, would be the risk of dehydration (an important risk factor for CVST), especially in view of the vaccine rollout phase commencing during the peak of the summer season.^[39] Another important factor is the dietary preference as the majority of the Indian population is vegetarian and the resultant high prevalence (about 47%) of vitamin B-12 deficiency and acquired hyperhomocysteinemia, which are known risk factors for venous thrombosis.^[40] Thus, the at-risk population can be highlighted by screening and offering them an option to take vaccines other than COVISHIELD.

In a developing country like India, with limited access to health care system for the majority of the population, identification and reporting of the symptoms (especially when mild) of VITT by the general population are expected to be poor. This may be further exaggerated by the lack of availability and affordability for diagnostic tests.^[41] Thus, the epidemiologic information to calculate an accurate estimate of the incidence of the VITT syndrome and full spectrum of thrombotic complications would be difficult. However, steps towards improving our understanding of VITT, accelerated efforts to broaden the diversity of the available vaccines, increasing their production and supply to remote areas of the nation would play a more constructive role in taming the current pandemic.

Each 1-month delay in vaccination kills hundreds of thousands of people, reduces global gross domestic product by hundreds of billions of dollars, and generates large and cumulative losses to human capital by harming education and health.^[4] Thus, enhanced vaccination efforts can be used as a tool for promoting health equity and restoring the confidence of people in the vaccination drive. This will prevent an unprecedented medical crisis as observed during the 2nd wave of COVID-19 in India. It is of utmost importance that the national vaccination effort continues at full swing while adapting to the emerging evidence about the adverse effects.

CONCLUSIONS

There is a rapidly growing awareness of the urgency to better characterize the newly described TTS and VITT after the administration of viral vector-based vaccines against COVID-19. With increasing vaccination numbers as well as vaccine rollout for the younger population, there is a need for strengthening AEFI reporting and vigilance, both on the part of clinicians and vaccine recipients. Screening for potential risk factors and avoiding adenoviral vector-based vaccines may be an alternative strategy, at least for the time-being, to avoid an unprecedented medical crisis. While all efforts should be made towards achieving the target of vaccinating the entire population as quickly as possible, risk-benefit analysis should be done periodically on the basis of emerging reports, both internationally and locally to modify the vaccination strategy, if needed.

Financial support and sponsorship

Nil.

Conflicts of interest

There are no conflicts of interest.

REFERENCES

- Lai CC, Shih TP, Ko WC, Tang HJ, Hsueh PR. Severe acute respiratory syndrome coronavirus 2 (SARS-CoV-2) and coronavirus disease-2019 (COVID-19): The epidemic and the challenges. *Int J Antimicrob Agents* 2020;55:105924.
- Available from: <https://covid19.who.int>. [Last accessed on 2021 Aug 13].
- Available from: <https://www.cdc.gov/flu/about/burden/index.html#:~:text=While%20the%20impact%20of%20flu,61%2C000%20deaths%20annually%20since%202010>. [Last accessed on 2021 Jul 01].
- Brüssow H. COVID-19: Vaccination problems. *Environ Microbiol* 2021;23:2878-90.
- Ministry of Health and Family Welfare. Apr 2021. Available from: <https://www.mohfw.gov.in>. [Last accessed on 2021 Jul 01].
- Available from: https://www.seruminstitute.com/health_faqs_covishield.php. [Last accessed on 2021 Jul 01].
- Available from: <https://www.bharatbiotech.com/covaxin.html>. [Last accessed on 2021 Jul 01].
- Chatterjee P. Covid-19: India authorises Sputnik V vaccine as cases soar to more than 180 000 a day. *BMJ* 2021;373:n978.
- Moghadas SM, Vilches TN, Zhang K, Wells CR, Shoukat A, Singer BH, *et al.* The impact of vaccination on COVID-19 outbreaks in the United States. *medRxiv* 2020. doi: 10.1101/2020.11.27.20240051.
- Favaloro EJ. Laboratory testing for suspected COVID-19 vaccine-induced (immune) thrombotic thrombocytopenia. *Int J Lab Hematol* 2021;43:559-70.
- Hunter PR. Thrombosis after covid-19 vaccination. *BMJ* 2021;373:n958.
- See I, Su JR, Lale A, Woo EJ, Guh AY, Shimabukuro TT, *et al.* US case reports of cerebral venous sinus thrombosis with thrombocytopenia after Ad26.COV2.S vaccination, March 2 to April 21, 2021. *JAMA* 2021;325:2448-56.
- Available from: <https://dashboard.cowin.gov.in>. [Last accessed on 2021 Aug 13].
- Elalamy I, Gerotziafas G, Alamowitch S, Laroche JP, Van Dreden P, Ageno W, *et al.* SARS-CoV-2 vaccine and thrombosis: An expert consensus on vaccine-induced immune thrombotic thrombocytopenia. *Thromb Haemost* 2021;121:982-91.
- Long B, Bridwell R, Gottlieb M. Thrombosis with thrombocytopenia syndrome associated with COVID-19 vaccines. *Am J Emerg Med* 2021;49:58-61.
- Pai M, Grill A, Ivers N, Maltsev A, Miller KJ, Razak F, *et al.* Vaccine-induced prothrombotic immune thrombocytopenia (VIPIT) following AstraZeneca COVID-19 vaccination: Lay summary. *Science Table: Covid advisory for Ontario* 2021;1. doi: 10.47326/ocsat.2021.02.16.1.0.
- Mehta PR, Apap Mangion S, Bengier M, Stanton BR, Czuprynska J, Arya R, *et al.* Cerebral venous sinus thrombosis and thrombocytopenia after COVID-19 vaccination - A report of two UK cases. *Brain Behav Immun* 2021;95:514-7.
- MacNeil JR, Su JR, Broder KR, Guh AY, Gargano JW, Wallace M, *et al.* Updated Recommendations from the Advisory Committee on Immunization Practices for use of the Janssen (Johnson and Johnson) COVID-19 vaccine after reports of thrombosis with thrombocytopenia syndrome among vaccine recipients - United States, April 2021. *MMWR Morb Mortal Wkly Rep* 2021;70:651-6.
- Thakur KT, Tamborska A, Wood GK, McNeill E, Roh D, Akpan IJ, *et al.* Clinical review of cerebral venous thrombosis in the context of COVID-19 vaccinations: Evaluation, management, and scientific questions. *J Neurol Sci* 2021;427:117532.
- Bersinger S, Lagarde K, Marlu R, Pernod G, Payen JF. Using nonheparin anticoagulant to treat a near-fatal case with multiple venous thrombotic lesions during ChAdOx1 nCoV-19 vaccination-related vaccine-induced immune thrombotic thrombocytopenia. *Crit Care Med* 2021;49:e870-3.

21. Graf T, Thiele T, Klingebiel R, Greinacher A, Schäbitz WR, Greeve I. Immediate high-dose intravenous immunoglobulins followed by direct thrombin-inhibitor treatment is crucial for survival in Sars-Covid-19-adenoviral vector vaccine-induced immune thrombotic thrombocytopenia VITT with cerebral sinus venous and portal vein thrombosis. *J Neurol* 2021;1-3. doi: 10.1007/s00415-021-10599-2.
22. Available from: <https://main.mohfw.gov.in/sites/default/files/cassuliatyassessment11062021eng.pdf>. [Last accessed on 2021 Jul 01].
23. Rzymiski P, Perek B, Flisiak R. Thrombotic thrombocytopenia after COVID-19 vaccination: In search of the underlying mechanism. *Vaccines (Basel)* 2021;9:559.
24. Karron RA, Key NS, Sharfstein JM. Assessing a rare and serious adverse event following administration of the Ad26.COV2.S vaccine. *JAMA* 2021;325:2445-7.
25. Alvis-Miranda HR, Milena Castellar-Leones S, Alcalá-Cerra G, Rafael Moscote-Salazar L. Cerebral sinus venous thrombosis. *J Neurosci Rural Pract* 2013;4:427-38.
26. Furie KL, Cushman M, Elkind MSV, Lyden PD, Saposnik G; American Heart Association/American Stroke Association Stroke Council Leadership. Diagnosis and management of cerebral venous sinus thrombosis with vaccine-induced immune thrombotic thrombocytopenia. *Stroke* 2021;52:2478-82.
27. Chen RT. Proposed Brighton Collaboration process for developing a standard case definition for study of new clinical syndrome X, as applied to Thrombosis with Thrombocytopenia Syndrome (TTS). Brighton Collaboration Apr. 16, 2021 v9.0.
28. Soleimani B, Turaga S, Khan D, Davies C, Duodu Y, Botcherby E, *et al.* Syndrome of cerebral venous sinus thrombosis and thrombocytopenia after vaccination for COVID-19. *Res Squ* 2021. doi: 10.21203/rs.3.rs-439289/v1.
29. Taquet M, Husain M, Geddes JR, Luciano S, Harrison PJ. Cerebral venous thrombosis and portal vein thrombosis: A retrospective cohort study of 537,913 COVID-19 cases. *medRxiv* 2021. doi: 10.1101/2021.04.27.21256153.
30. Nazy I, Sachs UJ, Arnold DM, McKenzie SE, Choi P, Althaus K, *et al.* Recommendations for the clinical and laboratory diagnosis of VITT against COVID-19: Communication from the ISTH SSC Subcommittee on Platelet Immunology. *J Thromb Haemost* 2021;19:1585-8.
31. Lavin T, Punter M, Holland M. The clinical management of cerebral venous sinus thrombosis. A UK survey. *J Neurol Neurosurg Psychiatry* 2016;87:e1.
32. Available from: <https://www.hematology.org/covid-19/vaccine-induced-immune-thrombotic-thrombocytopenia>. [Last accessed on 2021 Jul 01].
33. Thaler J, Ay C, Gleixner KV, Hauswirth AW, Cacioppo F, Grafeneder J, *et al.* Successful treatment of vaccine-induced prothrombotic immune thrombocytopenia (VIPIT). *J Thromb Haemost* 2021;19:1819-22.
34. Bagcchi S. The world's largest COVID-19 vaccination campaign. *Lancet Infect Dis* 2021;21:323.
35. Available from: <https://timesofindia.indiatimes.com/>. [Las accessed on 2021 Aug 13].
36. Available from: https://main.mohfw.gov.in/sites/default/files/immunizationenglish30032021_0.pdf. [Last accessed on 2021 Jul 01].
37. Joshi J, Das MK, Polpakara D, Aneja S, Agarwal M, Arora NK. Vaccine safety and surveillance for adverse events following immunization (AEFI) in India. *Indian J Pediatr* 2018;85:139-48.
38. de Freitas GR, Bogousslavsky J. Risk factors of cerebral vein and sinus thrombosis. *Front Neurol Neurosci* 2008;23:23-54.
39. Jackson BF, Porcher FK, Zapton DT, Losek JD. Cerebral sinovenous thrombosis in children: Diagnosis and treatment. *Pediatr Emerg Care* 2011;27:874-80; quiz 881-3.
40. Singla R, Garg A, Surana V, Aggarwal S, Gupta G, Singla S. Vitamin B12 deficiency is endemic in Indian population: A perspective from North India. *Indian J Endocrinol Metab* 2019;23:211-4.
41. Younger DS. Health care in India. *Neurol Clin* 2016;34:1103-14.