

# Successful percutaneous management of bronchobiliary fistula after radiofrequency ablation of metastatic cholangiocarcinoma in a patient who has a postoperative stricture of hepaticojejunostomy site

Gum O Jung and Dong Eun Park

*Department of Surgery, Wonkwang University Hospital, Wonkwang University School of Medicine, Iksan, Korea*

Bronchobiliary fistula (BBF) is a rare condition that is defined as an abnormal communication between the biliary system and bronchial tree. Furthermore, a BBF is an extremely rare complication of radiofrequency ablation (RFA). A 54 year-old man with a history of extrahepatic biliary cancer had been suffering with a benign stricture of hepaticojejunostomy site and was treated with RFA for metastatic cholangiocarcinoma. In this report, we describe a patient with BBF complicated by an abscess which occurred after RFA. He was treated by placement of external drainage catheter into the liver abscess and percutaneous transhepatic biliary drainage (PTBD) into the right intrahepatic duct. After 6 weeks, a complete obliteration of the BBF was confirmed by a repeated follow-up of computed tomography scan and cholangiography through PTBD. ([Korean J Hepatobiliary Pancreat Surg 2012;16:110-114](#))

**Key Words:** Biliary fistula; Cholangiocarcinoma; Catheter ablation; Bronchial fistula

## INTRODUCTION

Bronchobiliary fistula (BBF) is a very rare condition defined as an abnormal communication between the biliary tree and bronchial tree. It was first reported by Peakcock in 1850.<sup>1</sup> The causes of acquired BBF are as follows: consequence of local infection such as hydatid or liver abscess, trauma, obstruction of biliary tract and neoplasm. In primary or metastatic liver tumor, the use of radiofrequency ablation (RFA) has been on the rise as an alternative or adjuvant treatment of surgical resection. Thus incidence of complications associated with RFA has also been increasing. Although BBF is an extremely rare condition as a complication of RFA, the number of reported cases of BBF has increasing in recent years. Here, we report a case regarding management of BBF with a review of literature.

## CASE

A 56 year-old man was diagnosed with metastatic chol-

angiocarcinoma in the liver. Four years ago, he had undergone radical resection of the common bile duct and hepatico-jejunostomy due to Bismuth type I perihilar cholangiocarcinoma. During follow up after laparotomy, he had been diagnosed with stricture of hepaticojejunostomy without jaundice. Three metastatic lesions in the liver were found in the segments 5, 6, and 8 (each 2.9 cm, 1.6 cm, and 3.3 cm in size). Preferentially, radiofrequency ablation (RFA) was performed under ultrasonographic guidance in lesions of the segments 5 and 6.

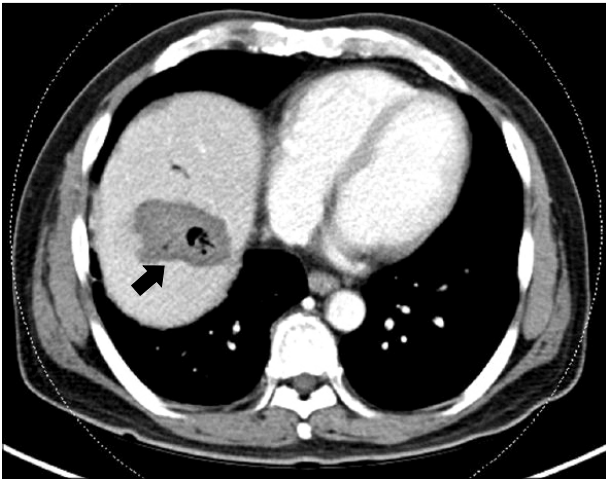
After the first RFA, he complained of severe pain in the right upper quadrant of the abdomen. The pain gradually improved over five days with the administration of analgesics. He refused additional RFA procedure of the remained metastatic lesion of the segment 8. So, combined chemotherapy of gemcitabine and cisplatin as a therapeutic strategy for the remained lesion proceeded over the following 18 weeks.

A follow-up computed tomography (CT) scan obtained after end of the chemotherapy showed partial response of metastatic cholangiocarcinoma in the segment 8 without

**Received:** July 2, 2012; **Revised:** July 30, 2012; **Accepted:** August 2, 2012

**Corresponding author:** Dong Eun Park

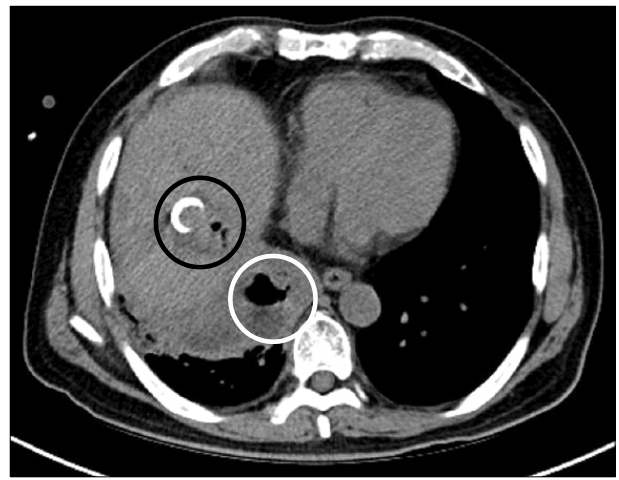
Department of Surgery, Wonkwang University Hospital, Wonkwang University School of Medicine, 344-1, Shinyong-dong, Iksan 570-711, Korea  
Tel: +82-63-859-1475, Fax: +82-63-855-2386, E-mail: Knife@wonkwang.ac.kr



**Fig. 1.** A computed tomography scan obtained two weeks after radiofrequency ablation shows that the previously ablated area has become hypodense with area formation, which was identified as a liver abscess (arrow).

recurrence of previous RFA site (segment 5 and 6). However, the patient's renal function was worsened by the chemotherapy and the patient refused further chemotherapy because of deteriorated general condition. So, RFA of the remained metastatic lesion of segment 8 was performed. A follow-up CT scan performed immediately after RFA showed complete ablation of the metastatic cholangiocarcinoma without direct evidence of diaphragmatic injury except for a small amount of reactive pleural effusion in right lung.

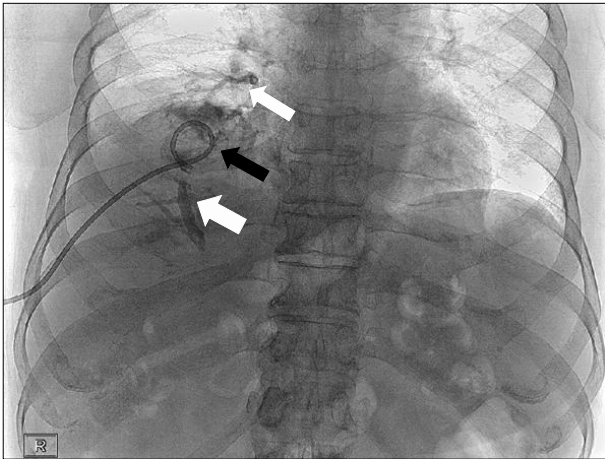
The patient developed a lower grade fever of less than 38.0°C during the 3 days after RFA. One week later, he revisited the hospital with intermittent fever and chill. A follow-up CT scan showed a liver abscess in the previous RFA site. Ultrasonography-guided percutaneous catheter drainage (PCD) of the liver abscess with a 10.2-Fr pigtail catheter was inserted, and antibiotics were administered for three weeks (Fig. 1). The patient showed new symptoms with complaints of productive cough with green-yellow sputum accompanied with more than 38.9°C fever with chills. The coughing worsened to the point of choking when the patient lay down and improved with sitting upright. In chest auscultation, breathing sounds decreased in the right chest with crackles. The laboratory test results revealed leucocyte  $15.54 \times 10^3/\mu\text{l}$  (normal range:  $4-10 \times 10^3/\mu\text{l}$ ), alkaline phosphatase of 718 IU/L (normal range: 104-338 IU/L), gamma-glutamyl transpeptidase (GGT) of 216 IU/L (normal range: 8-61 IU/L), blood urea nitrogen



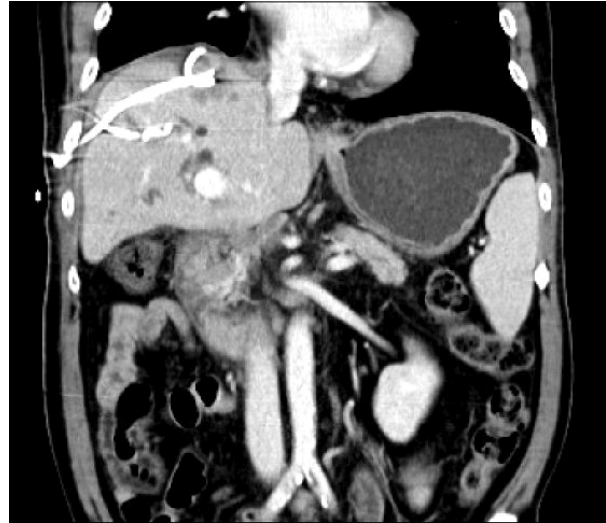**Fig. 2.** A follow-up computed tomography shows liver abscess with inserted pigtail catheter in the previous radiofrequency ablated site (black circle) and consolidation with air formation in the adjacent diaphragm, which was diagnosed as a lung abscess (white circle).

(BUN) of 54.4 mg/dl (normal range: 8-20 mg/dl), serum creatinine of 3.74 mg/dl (normal range: 0.5-1.3 mg/dl), and C-reactive protein of 214 mg/L (normal range: 0-5 mg/L). Serum albumin, bilirubin, prothrombin time, and activated partial thromboplastin time were within normal limits. Plain chest radiograph demonstrated the presence of ill-defined consolidation and infiltrative lesion with pleural effusion in the right lower lung field. In sputum culture, *E. coli* were isolated and an antibiotic was administered as appropriate to the susceptibility result. However, the coughing became worse and the amount of green-yellow sputum also increased. Follow-up abdomen and chest CT scans showed a persistent liver abscess (4 cm in size) at previous RFA site and abscess of the right lower lung (Fig. 2). Liver abscess in liver dome and lung abscess in right lower lung field were attached to the diaphragm. Ultrasonography-guided PCD of the liver abscess with a 10.2-Fr pigtail catheter was reinserted for catheter change. Contrast material injection showed the presence of cavities of the lung and the bronchial tree communicating with the biliary tree, which was consistent with BBF (Fig. 3). *E. coli* were isolated from a culture of the drainage material. Following the catheter insertion, antibiotics therapy was continued. Although the amount of sputum was reduced after the insertion of the drainage catheter, biliptysis and coughing were continued.

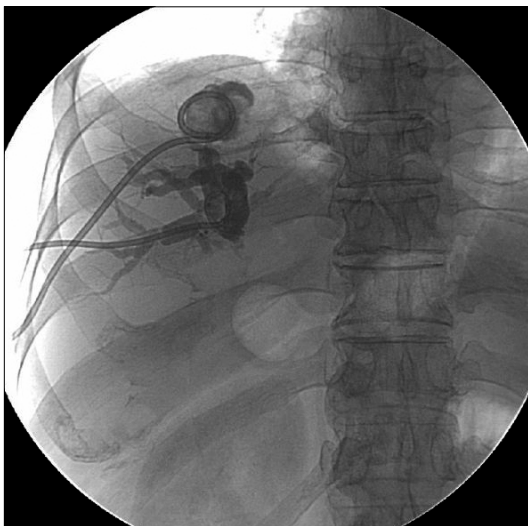
We performed percutaneous transhepatic biliary drain-



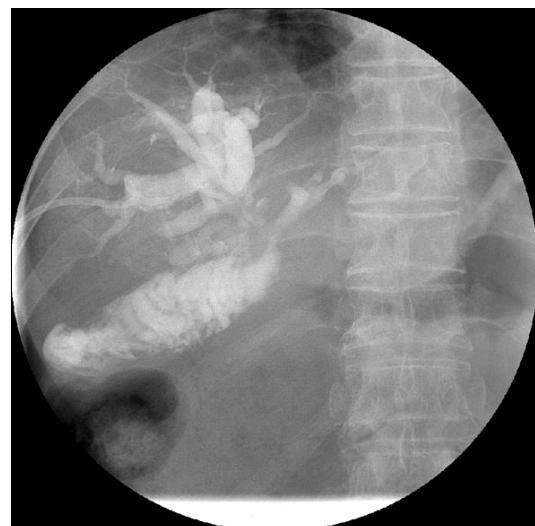**Fig. 3.** Contrast material was injected through the percutaneous abscess drainage catheter. This contrast material showed in the abscess cavity in liver (black arrow), bronchial tree (thin white arrow), and biliary tree (wide white arrow), confirming the presence of bronchobiliary fistula.



**Fig. 5.** One month later, the follow-up coronary computed tomography image shows improvement of liver abscess and no consolidation of lower lung field.



**Fig. 4.** Although the amount of sputum decreased after the insertion of the drainage catheter, biliptysis and coughing continued. We performed percutaneous transhepatic biliary drainage (PTBD) in the dilated right hepatic duct to reduce the intrahepatic biliary tree pressure which was increased due to the hepaticojejunostomy site stricture.



**Fig. 6.** After the percutaneous drainage catheter was removed, contrast material was injected through PTBD catheter. Cholangiography shows no communication between the bronchial system and biliary tree.

age (PTBD) in the dilated right hepatic duct to reduce intrahepatic pressure of biliary tree which was increased because of stricture of the hepatico-jejunostomy site (Fig. 4). After PTBD, coughing and biliptysis were markedly improved. Follow-up abdominal CT scans obtained four weeks after the catheter insertion showed a markedly reduced abscess cavity of the liver dome and improvement of the lung abscess in the right lower lobe. Thereafter, the

amount of percutaneous drainage decreased gradually. When the amount of drainage reached less than 5 ml per day, the abscess cavity of the liver dome and right-side lung did not show in the follow up CT scan (Fig. 5). After PCD catheter at the liver dome was removed, repeated cholangiography showed no communication between the intrahepatic biliary tree and bronchial tree (Fig. 6).

## DISCUSSION

Bronchobiliary fistula is defined as an abnormal interconnection between the biliary tree in the liver and the bronchial tree. In the past, local infection such as hydatid or amebic abscess in the liver has been considered as a classic cause of BBF. According to recently published reports, the main cause of BBT is now recognized to be primary or metastatic tumor.<sup>2</sup> The pathogenesis of BBF-associated tumor may involve iatrogenic damage, diaphragm invasion, and intrahepatic or extrahepatic biliary obstruction. Among these, bile duct obstruction is known as the most common cause, most often due to lithiasis, tumor, hydatid cyst, or postoperative stricture.<sup>1,3</sup> Our patient showed mild dilatation of the bile duct to the postoperative stricture on the CT scan and experienced intermittent cholangitis. Before occurrence of BBF, he had a liver abscess in previous RFA site for metastatic cholangiocarcinoma. In this circumstance, we had to consider for the possibility of occurrence of liver abscess or BBF when RFA had been performed at this site.

Pathogenesis of RFA-related BBF resulted from rupture of a growing biloma through a diaphragmatic defect caused by thermal injury. For this reason, the size and location of the tumor is an important risk factor for the development of BBF. In our patient, the tumor was located in the hepatic dome adjacent to the right diaphragm and was 5.5 cm on in size at the time of recurrence. The tumor was reduced to 3 cm after the combined chemotherapy of gemcitabine and cisplatin for 3 months.

The most pathognomonic finding of BBF is biliptysis defined productive cough of bile stained sputum. Biliptysis accounted for 67% of cases.<sup>2</sup> Sometimes, it is diagnosed as acute pneumonitis with cough-producing greenish sputum.<sup>4</sup> Other symptoms and signs include fever, jaundice, abdominal pain, and chest pain. Early diagnosis of BBF is very important because morbidity and mortality could be increasing by chemical pneumonitis, pneumonia or necrotizing bronchitis.<sup>5</sup> Diagnosis can be confirmed by imaging procedures such as hepatobiliary scan, percutaneous transhepatic cholangiogram (PTC), endoscopic retrograde cholangiography (ERCP), and magnetic resonance cholangio-pancreatography (MRCP). Our patient was diagnosed by fistulogram through percutaneous abscess drainage.

BBF requires a well-planned management strategy depending on the cause of each BBF. However, until now, there has been a consensus on the optimal treatment of BBF. Transitional therapeutic modality of BBF had been established as follows: surgical relief of biliary obstruction, subphrenic drainage, excision of the fistulous tract and appropriate supportive measures. However, as more studies have been conducted regarding BBF, the therapeutic method of BBF has shifted from surgical management to non-surgical approach including endoscopic management and percutaneous approach. Recently, in several cases, endoscopic interventions such as endoscopic nasogastric bile drainage (ENBD) with sphincterotomy of Oddi' sphincter and PTBD were effective in resolving distal biliary obstruction. Therefore, in these patients who have a restricted life span with malignant disease, conservative treatment with non-surgical interventions is more accepted than the surgical approach.<sup>6,7</sup> In the past years, direct embolization of fistula tract under bronchoscopic guidance was introduced as a new therapeutic method.<sup>8,9</sup> However, these methods should be proven by more clinical cases.

If non-surgical managements of BBF fail, surgical correction should be considered as the definitive therapeutic modality. Surgical procedures vary depending on the cause of BBF. The following procedures of literature were performed in BBF: drainage of the right subphrenic or hepatic abscess, closure of fistula, resection of hydatid cyst or tumor, biliary drainage using T-tube, and bilioenteric anastomosis (e.g., Roux-en-Y hepaticojejunostomy).

In conclusion, although RFA is a safe and effective modality for the treatment of primary or metastatic hepatic tumor, the possibility of BBF should be considered if the patient complains of biliptysis after RFA. Because the optimal management of BBF is controversial, individualized and multidisciplinary approach of BBF treatment should be applied depending on the cause of BBF.

## ACKNOWLEDGEMENTS

This paper was supported by Wonkwang University in 2011.

## REFERENCES

1. Peacock TB. Case in which hydatids were expectorated and one of suppuration of hydatid cyst of the liver communicating with the lungs. *Edinburgh Med J* 1850;74:33-46.
2. Liao GQ, Wang H, Zhu GY, et al. Management of acquired bronchobiliary fistula: A systematic literature review of 68 cases published in 30 years. *World J Gastroenterol* 2011;17:3842-3849.
3. Cropper LD Jr, Gold RE, Roberts LK. Bronchobiliary fistula: management with percutaneous catheter drainage of a subphrenic abscess. *J Trauma* 1982;22:68-70.
4. Sutherland RD, Reynolds J, Sugg WL. Bile ptyalism associated with chest trauma and sickle cell crisis simulating bronchobiliary fistula. *Ann Thorac Surg* 1972;13:537-542.
5. Moumen M, el Fares F. Bilio-bronchial fistula of hydatid origin. Apropos of 8 cases. *J Chir (Paris)* 1991;128:188-192.
6. Ong M, Moozar K, Cohen LB. Octreotide in bronchobiliary fistula management. *Ann Thorac Surg* 2004;78:1512-1513.
7. Gugenheim J, Ciardullo M, Traynor O, et al. Bronchobiliary fistulas in adults. *Ann Surg* 1988;207:90-94.
8. Kim JH, Kim MD, Lee YK, et al. Bronchobiliary fistula treated with histoacryl embolization under bronchoscopic guidance: A case report. *Respiratory Medicine CME* 2008;1:164-168.
9. Goldman SY, Greben CR, Setton A, et al. Bronchobiliary fistula successfully treated with n-butyl cyanoacrylate via a bronchial approach. *J Vasc Interv Radiol* 2007;18:151-155.