

## Lymphangiosarcoma with systemic metastases in a Japanese domestic cat

Atigan THONGTHARB<sup>1)</sup>, James K. CHAMBERS<sup>1)\*</sup>, Kazuyuki UCHIDA<sup>1)</sup>, Ken-ichi WATANABE<sup>1)</sup>, Ayaka TAKAHASHI<sup>2)</sup>, Manabu MOCHIZUKI<sup>3)</sup>, Ryohei NISHIMURA<sup>4)</sup> and Hiroyuki NAKAYAMA<sup>1)</sup>

<sup>1)</sup>Department of Veterinary Pathology, Graduate School of Agricultural and Life Sciences, The University of Tokyo, 1-1-1 Yayoi, Bunkyo-ku, Tokyo 113-8657, Japan

<sup>2)</sup>Veterinary Medical Center, Graduate School of Agricultural and Life Sciences, The University of Tokyo, 1-1-1 Yayoi, Bunkyo-ku, Tokyo 113-8657, Japan

<sup>3)</sup>Department of Veterinary Emergency Medicine, Graduate School of Agricultural and Life Sciences, The University of Tokyo, 1-1-1 Yayoi, Bunkyo-ku, Tokyo 113-8657, Japan

<sup>4)</sup>Department of Veterinary Surgery, Graduate School of Agricultural and Life Sciences, The University of Tokyo, 1-1-1 Yayoi, Bunkyo-ku, Tokyo 113-8657, Japan

(Received 28 September 2014/Accepted 22 November 2014/Published online in J-STAGE 6 December 2014)

**ABSTRACT.** A 4-year-2-month-old female Japanese domestic cat was diagnosed with lymphangiosarcoma through tissue biopsy of an amputated leg. Two months later, the cat was euthanized, and postmortem findings revealed edema, and bruising at the caudal region of the trunk, pulmonary hemorrhage, pulmonary nodules and mediastinal lymphadenopathy. Microscopically, neoplastic tissues were observed in the dermis and subcutis of the trunk, lung, mediastinal lymph nodes, diaphragm, omentum and mesentery. The tumor cells were spindle to polygonal-shaped with nuclear pleomorphism aligning along pre-existing collagen bundles and forming irregular vascular channels in which the erythrocytes were rarely observed. These cells were immunopositive for vimentin, von Willebrand factor and CD31. Based on the histopathological and immunohistochemical features, the neoplasia was diagnosed as lymphangiosarcoma with systemic metastases.

**KEY WORDS:** feline, lymphangiosarcoma, metastases

doi: 10.1292/jvms.14-0502; *J. Vet. Med. Sci.* 77(3): 371–374, 2015

Lymphangiosarcoma is an extremely rare malignant tumor in humans and domestic animals. This tumor arises from the lymphatic endothelial cells of the lymph vessel and occurs in any part of the body [4, 5, 7, 12, 16, 20]. In humans, most cases of lymphangiosarcoma are associated with secondary chronic lymphedema, particularly in women who have been treated for breast cancer with radical mastectomy together with axillary lymph node dissection. The clinical phenomenon is known as “Stewart-Treves syndrome” [3, 11, 13, 18]. Most cases of lymphangiosarcoma in domestic animals have been described in dogs and cats [2, 4, 7, 10, 12, 13, 20, 21, 23–25]. However, those in horses and cattle have also been reported [8, 9, 14, 15, 17]. In cats, lymphangiosarcoma is notably observed in the subcutaneous tissue of the limbs, ventral abdomen and caudal mammary regions [6, 7, 12, 20, 21]. To our knowledge, there has been only one feline case with distant metastases of lymphangiosarcoma [7]. In the present report, we describe clinical, macroscopic, microscopic and immunohistochemical features of a case of feline lymphangiosarcoma with systemic metastases in a Japanese domestic cat.

A 4-year-2-month-old female Japanese domestic cat was

presented to the Veterinary Medical Center, The University of Tokyo, with a history of hemorrhagic discharge at the left hindlimb and non-weight bearing. The results of a radiographic examination revealed an osteolytic lesion together with swelling of surrounding tissues throughout the affected leg, particularly at the calcaneus (Fig. 1a). During the period of medical treatment, the cat presented with open fracture of the same leg, and then, limb amputation was consequently performed. Tissue biopsy samples from the affected leg were taken, fixed in 10% neutral buffered formalin solution and then subjected to a histopathological examination. Microscopically, neoplastic foci consisting of proliferative spindle-shaped cells invading the adjacent muscle fibers were observed. Their nuclei were ovoid to elongate-shaped with prominent nucleoli. The tumor cells formed irregular vascular channels in which erythrocytes were rarely observed. Furthermore, lymphocytic infiltration to the adjacent tissues was noted (Fig. 1b). The lesion was diagnosed as lymphangiosarcoma. The tumor cell invasion was not detected in bone tissue. However, numerous inflammatory cells including neutrophils, macrophages and lymphocytes were notably observed within medullary cavity of the tibia, particularly in the fracture site. Two months after the surgical excision, the cat presented again with hemorrhage and lymphedema at the abdominal wall and right hindlimb. A hematological examination revealed anemia (pack cell volume 20.8%), macrocytosis (mean corpuscular volume 74.0 fl), hypochromasia (mean corpuscular hemoglobin concentration 27.9 g/dl) and leukocytosis (43,000/ $\mu$ l). A serum biochemistry examination showed hypokalemia (3.6 mEq/l), hypochloremia (111 mEq/l) and low blood urea nitrogen (9.2 mg/dl). The

\*CORRESPONDENCE TO: CHAMBERS, J. K., Department of Veterinary Pathology, Graduate School of Agricultural and Life Sciences, The University of Tokyo, 1-1-1 Yayoi, Bunkyo-ku, Tokyo 113-8657, Japan. e-mail: achamber@mail.ecc.u-tokyo.ac.jp

©2015 The Japanese Society of Veterinary Science

This is an open-access article distributed under the terms of the Creative Commons Attribution Non-Commercial No Derivatives (by-nc-nd) License <http://creativecommons.org/licenses/by-nc-nd/3.0/>.

Fig. 1

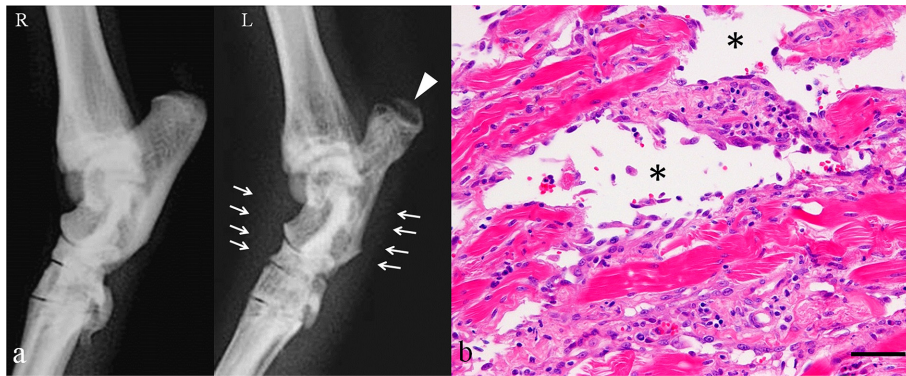

Fig. 2

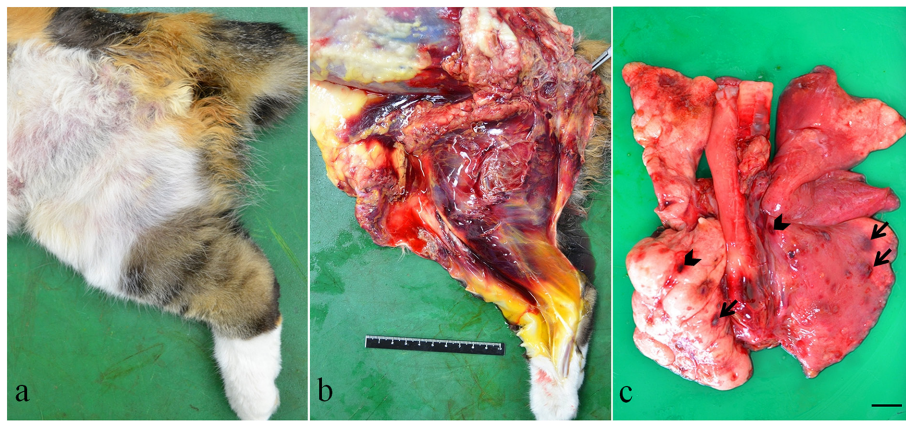
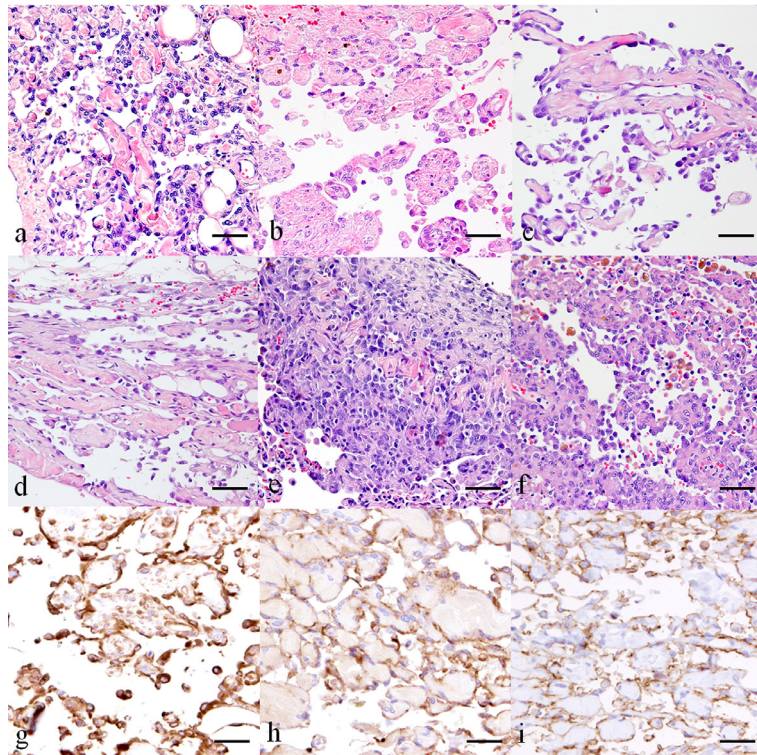


Fig. 3



clinical condition of the cat progressively deteriorated. The owner requested euthanization of the cat, and post-mortem examination was subsequently performed.

Gross examination revealed diffuse edema with bruising in the subcutaneous tissue of the abdomen and right hindlimb (Fig. 2a and 2b). A large quantity of serosanguineous fluid in the thoracic as well as abdominal cavity was observed. Nodules (approximately 1 mm in diameter) and hemorrhagic areas were scattered in the lung. Furthermore, mild enlargement of the mediastinal lymph nodes was also observed. In the abdominal cavity, lymphangiectasis was observed in the omentum and mesentery.

The tissues including skin in the affected area, omentum, mesentery, lung, mediastinal lymph nodes and diaphragm were fixed in 10% neutral buffered formalin solution and routinely embedded in paraffin. Paraffin sections, 2 to 4  $\mu\text{m}$  thick, were stained with hematoxylin and eosin (HE). An immunohistochemical examination was performed using mouse monoclonal antibodies against vimentin (1:200, DAKO Japan, Tokyo, Japan), cytokeratin (clone AE1/AE3, 1:50, DAKO Japan), CD31 (1:50, DAKO Japan) and Ki-67 (ready-to-use, DAKO Japan) and rabbit polyclonal antibody against von Willebrand factor (vWF, 1:500, DAKO Japan). Tissue sections for the detection of vimentin, cytokeratin, CD31 and Ki-67 were autoclaved at 121°C for 10 min for antigen retrieval. Those for the detection of vWF were incubated with proteinase K at room temperature for 15 min for antigen retrieval. Blocking of non-specific reactions was conducted by treatment with 10% hydrogen peroxide ( $\text{H}_2\text{O}_2$ ) and methanol at room temperature for 5 min and then with 8% skimmed milk in Tris-buffered saline (TBS). The primary antibodies were applied at 4°C overnight. After rinsing with TBS, the sections were incubated with the Envision<sup>+</sup> System-HRP Labeled Polymer reagent (DAKO Japan) at 37°C for 40 min and rinsed with TBS prior to treatment with 3-3'-diaminobenzidine solution containing 0.03%  $\text{H}_2\text{O}_2$ . All sections were then counterstained with hematoxylin.

Poorly differentiated tumor cells were invading the dermis and subcutis in the ventral abdomen and right hindlimb. The tumor cells were characterized by spindle-shaped eosinophilic to amphophilic cytoplasm with an indistinct border. Their nuclei were concentric and ovoid to elongate-shaped with prominent nucleoli. The tumor cells were aligned along pre-existing collagen bundles and formed irregular vascular channels in which erythrocytes were rarely observed (Fig. 3a and 3b). Mitotic figures were rarely observed. In addition, small numbers of lymphocytes and plasma cells in-

filtrating the adjacent tissues as well as necrotic and/or hemorrhagic areas were noted. Neoplastic foci were also found in the omentum, mesentery, lung, mediastinal lymph nodes and diaphragm (Fig. 3c–3f). Furthermore, solid growth pattern of the tumor cells was also observed, particularly in the lung and mediastinal lymph nodes. However, vascular clefts were observed in few areas. Tumor cells were also noted within normal blood vessels in the lung.

Immunohistochemical examinations revealed that the tumor cells were positive for vimentin, vWF and CD31, though they were negative for cytokeratin AE1/AE3 (Fig. 3g–3i). The proliferative index, namely the percentage of Ki-67-positive cells in five high-power fields (approximately 1,000 tumor cells) [17, 20], was 43.35%.

On the basis of all findings obtained in the present study, a diagnosis of lymphangiosarcoma with systemic metastasis was made. To date, several studies have described a plausible explanation regarding the etiology of lymphangiosarcoma associated with lymphedema. The condition is characterized by the accumulation of protein-rich fluid within the interstitial tissues resulting from impaired lymphatic drainage [1, 22, 24]. The causes of lymphedema include infection, trauma, foreign body, filarial infestation, arteriovenous fistula and radiation therapy [1, 20, 25]. In humans, chronic lymphedema has been absolutely ascribed as an important factor that results in the induction of lymphangiosarcoma. In domestic animals, similarly, prolonged lymphedema can be a cause of lymphangiosarcoma [14]. Moreover, there are a few case reports demonstrating lymphangiosarcoma in dogs caused by primary lymphedema induced by lymphatic dysplasia [24, 25].

A diagnosis of lymphangiosarcoma is commonly based on the history, clinical signs, histopathological lesions and biological behavior of the tumor [7, 8, 12, 17]. In the present case, the tumor cells showed moderate pleomorphism and high percentage of Ki-67 positivity, consistent with the characterization of malignant cells. The positive reactions of neoplastic cells to vimentin, vWF and CD31 suggest their endothelial origin [5, 12, 19]. However, in the present case, normal vascular endothelial cells were also positive for these antigens. To discriminate a tumor arising from lymphatic vessels from that arising from blood vessels, the absence of erythrocytes within the neoplastic channel, alignment of the tumor cells and infiltration of lymphocytes in the stroma should be considered [2, 6, 8, 12–14, 17, 23].

To our knowledge, there are few studies illustrating metastatic lymphangiosarcoma in a dog [2] or a horse [17].

Fig. 1. Hindlimbs. Cat. Lymphangiosarcoma. A radiological examination (a) revealed osteolytic changes (arrowhead) and soft tissue swelling (arrows) at the left (L) hindlimb when compared to the contralateral limb (R). Microscopically, the tumor cells formed irregular vascular channels (asterisks) in which erythrocytes were rarely observed. Mild infiltration of lymphocytes was also noted in the interstitium. HE (b). Scale bar=200  $\mu\text{m}$ .

Fig. 2. Gross findings. Cat. Metastatic lymphangiosarcoma. The right thigh was markedly edematous with bruising (a and b). Hemorrhagic areas (arrowhead) as well as multiple nodules (arrow) were scattered throughout the entire lobes of the lung (c). Scale bar=1 cm.

Fig. 3. Cat. Metastatic lymphangiosarcoma. Plump spindle-shaped tumor cells formed irregular vascular channels. Dermis and subcutis of skin from the right hindlimb (a), ventral abdomen (b), omentum (c), mesentery (d), lung (e) and mediastinal lymph nodes (f). HE. The tumor cells were immunopositive for vimentin (g), vWF (h) and CD31 (i). DAB chromogen, hematoxylin counterstain. Scale bar=100  $\mu\text{m}$ .

Hinrich *et al.* [7] reported lymphangiosarcoma in 12 domestic shorthair cats, and 4 of them had distant metastases to the lung, spleen and liver. However, the histopathological and immunohistochemical features of the tumors were not described in detail. In the present case, tumor recurrence was observed 2 months after limb amputation. Recurrence was histologically observed in the skin of the ventral abdomen and right hindlimb, lung, cranial mediastinal lymph nodes, diaphragm, omentum and mesentery, but not in the liver or spleen. The pathological features of the metastatic lesions were similar to those of the primary lesion, suggesting lymphangiosarcoma. In general, most cases of feline lymphangiosarcoma are described in aging cats. However, few studies as well as the present case have demonstrated lymphangiosarcoma in young and middle aged cats [12, 20]. In our knowledge, the present case represents the first report of lymphangiosarcoma in a Japanese domestic cat.

## REFERENCES

- Arslan, H., Uludağ, A., Kapukaya, A., Gezici, A., Bekler, H. I. and Ketani, A. 2007. Effect of lymphedema on the recovery of fractures. *J. Orthop. Sci.* **12**: 578–584. [Medline] [CrossRef]
- Barnes, J. C., Taylor, S. M., Clark, E. G., Haines, D. M. and Broughton, S. J. 1997. Disseminated lymphangiosarcoma in a dog. *Can. Vet. J.* **38**: 42–44. [Medline]
- Chung, K. C., Kim, H. J. E., Jeffers, L. L. C. and Arbor, A. 2000. Lymphangiosarcoma (Stewart-Treves Syndrome) in postmastectomy patients. *J. Hand. Surg. Am.* **25**: 1163–1168. [Medline] [CrossRef]
- Diessler, M. E., Castellano, M. C., Massone, A. R., Portiansky, E. L., Allende, M. G., Idiart, J. R. and Gimeno, E. J. 2003. Cutaneous lymphangiosarcoma in a young dog: Clinical, anatomopathological and lectin histochemical description. *J. Vet. Med. A Physiol. Pathol. Clin. Med.* **50**: 452–456. [Medline] [CrossRef]
- Fossum, T. W., Miller, M. W. and Mackle, J. T. 1998. Lymphangiosarcoma in a dog presenting with massive head and neck swelling. *J. Am. Anim. Hosp. Assoc.* **34**: 301–304. [Medline] [CrossRef]
- Galeotti, F., Barzagli, F., Vercelli, A., Millanta, F., Poli, A., Jackson, D. G. and Abramo, F. 2004. Feline lymphangiosarcoma – definitive identification using a lymphatic vascular marker. *Vet. Dermatol.* **15**: 13–18. [Medline] [CrossRef]
- Hinrichs, U., Puhl, S., Rutteman, G. R., Van Der Linde-Sipman, J. S. and Van Den Ingh, T. S. G. A. M. 1999. Lymphangiosarcoma in cats: A retrospective study of 12 cases. *Vet. Pathol.* **36**: 164–167. [Medline] [CrossRef]
- Ijzer, J. and Van Den Ingh, T. S. G. A. M. 2000. Lymphangiosarcoma in a horse. *J. Comp. Pathol.* **122**: 312–316. [Medline] [CrossRef]
- Junginger, J., Rötting, A., Staszuk, C., Kramer, K. and Hewicker-Trautwein, M. 2010. Identification of equine cutaneous lymphangioma by application of a lymphatic endothelial cell marker. *J. Comp. Pathol.* **143**: 57–60. [Medline] [CrossRef]
- Kelly, W. R., Wilkinson, T. and Allen, P. W. 1981. Canine angiosarcoma (lymphangiosarcoma): A case report. *Vet. Pathol.* **18**: 224–227. [Medline]
- Kopperman, M. and Antoine, J. E. 1974. Primary lymphangioma of the calvarium. *Am. J. Roentgenol. Radium Ther. Nucl. Med.* **121**: 118–120. [Medline] [CrossRef]
- Lenard, Z. M., Foster, S. F., Tebb, A. J., Russell, N. J., O'hara, A. J. and Lester, N. V. 2007. Lymphangiosarcoma in two cats. *J. Feline Med. Surg.* **9**: 161–167. [Medline] [CrossRef]
- Marcinowska, A., Warland, J., Brearley, M. and Dobson, J. 2013. A novel approach to treatment of lymphangiosarcoma in a boxer dog. *J. Small Anim. Pract.* **54**: 334–337. [Medline] [CrossRef]
- Puff, C., Herder, V., Philipp, A. and Baumgärtner, W. 2008. Lymphangiosarcoma in the nictitating membrane of a horse. *J. Vet. Diagn. Invest.* **20**: 108–110. [Medline] [CrossRef]
- Ruggles, A. J., Irby, N. L., Saik, J. E. and Orsini, P. G. 1992. Ocular lymphangiosarcoma in a cow. *J. Am. Vet. Med. Assoc.* **200**: 1987–1988. [Medline]
- Sánchez-Medina, M. T., Acosta, A., Vilar, J. and Fernández-Palacios, J. 2012. Angiosarcoma en linfedema crónico (síndrome de Stewart-Treves). *Actas Dermosifiliogr.* **103**: 545–547. [Medline] [CrossRef]
- Sanchez, B., Nieto, A., Ruiz De Leon, M. A., Rodríguez, J. and Flores, J. 2002. Metastatic lymphangiosarcoma in a horse. *Vet. Pathol.* **39**: 266–268. [Medline] [CrossRef]
- Sharma, A. and Schwartz, R. A. 2012. Stewart-Treves syndrome: Pathogenesis and management. *J. Am. Acad. Dermatol.* **67**: 1342–1348. [Medline] [CrossRef]
- Sleeckx, N., Van Brantegem, L., Fransen, E., Van Den Eynden, G., Casteleyn, C., Kroeze, E. V. and Van Ginneken, C. 2013. Evaluation of immunohistochemical markers of lymphatic and blood vessels in canine mammary tumors. *J. Comp. Pathol.* **148**: 307–317. [Medline] [CrossRef]
- Sugiyama, A., Takeuchi, T., Morita, T., Okamura, Y., Minami, S., Tsuka, T., Tabuchi, T. and Okamoto, Y. 2007. Lymphangiosarcoma in a Cat. *J. Comp. Pathol.* **137**: 174–178. [Medline] [CrossRef]
- Swayne, D. E., Mahaffey, E. A. and Haynes, S. G. 1989. Lymphangiosarcoma and haemangiosarcoma in a cat. *J. Comp. Pathol.* **100**: 91–96. [Medline] [CrossRef]
- Szuba, A. and Rockson, S. G. 1998. Lymphedema: classification, diagnosis and therapy. *Vasc. Med.* **3**: 145–156. [Medline] [CrossRef]
- Walsh, K. M. and Abbott, D. P. 1984. Lymphangiosarcoma in two cats. *J. Comp. Pathol.* **94**: 611–614. [Medline] [CrossRef]
- Webb, J. A., Boston, S. E., Armstrong, J. and Moens, N. M. M. 2004. Lymphangiosarcoma associated with primary lymphedema in a Bouvier des Flandres. *J. Vet. Intern. Med.* **18**: 122–124. [Medline] [CrossRef]
- Williams, J. H., Birrell, J. and Van Wilpec, E. 2005. Lymphangiosarcoma in a 3.5-year-old Bullmastiff bitch with vaginal prolapse, primary lymph node fibrosis and other congenital defects. *J. S. Afr. Vet. Assoc.* **76**: 165–171. [Medline] [CrossRef]