





## OPERATIVE TECHNIQUES

This article supplements the Operative Techniques video presentation, which can be viewed online on Head & Neck's home page at [http://onlinelibrary.wiley.com/journal/10.1002/\(ISSN\)1097-0347](http://onlinelibrary.wiley.com/journal/10.1002/(ISSN)1097-0347)

# Head and neck pedicled flap autonomization using a new high-resolution indocyanine green fluorescence video-angiography device

Leone Giordano MD  | Andrea Galli MD  | Marco Familiari MD  |  
Davide Canta MD | Ayhan Irem MD | Matteo Biafora MD |  
Rosa Alessia Battista MD  | Mario Bussi MD

Department of Otolaryngology – Head and Neck Surgery, Scientific Institutes of Hospitalization and Care San Raffaele Hospital, Vita-Salute University, Milan, Italy

## Correspondence

Marco Familiari, Department of Otolaryngology – Head and Neck Surgery, Scientific Institutes of Hospitalization and Care San Raffaele Hospital, Vita-Salute University, Via Olgettina 60, 20132 Milan, Italy.

Email: [familiari.marco@gmail.com](mailto:familiari.marco@gmail.com)

## Abstract

In head and neck oncologic surgery a reconstructive phase is often required and pedicled flaps are still a viable option, though they may need a pedicle division performed at a later stage. Several techniques are commonly used for perfusion assessment of the flaps, with indocyanine green (ICG) fluorescence video-angiography representing a promising tool. We used ICG video-angiography to evaluate the perfusion of two of the most commonly adopted pedicled flaps in the head and neck field (the supraclavicular and the paramedian forehead flap) before and after second-stage pedicle division, allowing a safer in-setting. Moreover, the new high-resolution device that we have employed added further accuracy to the traditional video-angiography, providing a real-time flap-to-normal skin ICG ratio. Indeed, ICG video-angiography proved to be a useful tool in head and neck reconstructive surgery and it may allow an earlier second-stage pedicle division.

## KEYWORDS

facial neoplasms, head and neck neoplasms, indocyanine green, reconstructive surgical procedure, surgical flaps

## 1 | INTRODUCTION

Head and neck tumors often need a reconstructive phase with pedicled or free flaps after the ablative surgery.<sup>1–6</sup> Some pedicled flaps, such as the supraclavicular flap or the paramedian forehead flap (PFF), may require a second-stage pedicle division and inset after the initial harvesting, a procedure consisting of pedicle division

generally performed at least 3 weeks after the former one to let flap inosculation occur.<sup>7</sup>

Several techniques are commonly used for perfusion assessment of the flaps, including simple visual observation, Doppler ultrasound, tissue oximetry, and indocyanine green (ICG) fluorescence video-angiography.<sup>8</sup> This latter is a promising tool recently introduced in general and plastic surgery which seems particularly useful for real-time

This is an open access article under the terms of the [Creative Commons Attribution-NonCommercial-NoDerivs](https://creativecommons.org/licenses/by-nc-nd/4.0/) License, which permits use and distribution in any medium, provided the original work is properly cited, the use is non-commercial and no modifications or adaptations are made.

© 2022 The Authors. *Head & Neck* published by Wiley Periodicals LLC.

evaluation of vascular perfusion of reconstructive flaps.<sup>1</sup> Nevertheless, to date it is not a widely employed technique for the assistance of second-stage pedicle division, especially in the field of head and neck surgery.

The aim of our work was to properly assess the perfusion of two of the most commonly used pedicled flap in the head and neck field (i.e., the supraclavicular flap and the PFF) through a new high-resolution ICG fluorescence video-angiography device in order to perform the expected second-stage pedicle division with a safe video-angiography feedback.

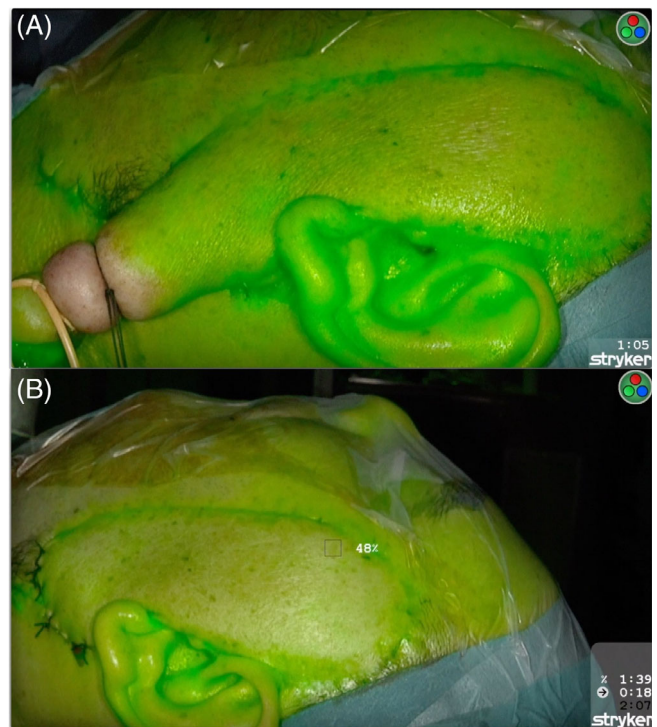
## 2 | OPERATIVE TECHNIQUE

We enrolled two patients affected by head and neck cancer treated at our Department of Otorhinolaryngology – Head and Neck Surgery in March 2021 with an ablative surgery followed by a concurrent reconstruction with a pedicled flap. ICG fluorescence video-angiography was used to assess the degree of flap vascularization during second-stage pedicle division to confirm its proper timing. Both the procedures were performed by the same senior surgeon (G.L.). A high-resolution ICG video-monitoring system (Stryker SPY Pinpoint, Kalamazoo, MI) was used in both cases for fluorescence video-angiography: it consists of a monitor, a dedicated software for perfusion assessment and flap-to-normal skin ICG ratio estimation and a high-resolution camera with a near-infrared laser. ICG contrast medium was used to perform angiography, injected intravenously during surgery: the dose was tailored according to patient weight and surgical needs. Flap vascularization was grossly documented by the visual intensity of ICG dye uptake throughout the flap surface. Moreover, the proper degree of flap vascularization was assessed point-by-point by software estimation of the relative ICG dye uptake in comparison with adjacent normal skin (flap-to-normal skin ICG ratio): we chose as “baseline” reference point for relative perfusion assessment the point of maximum signal intensity in the skin adjacent to the recipient site of the flap. A percentage was provided in real-time by moving the camera all along the flap surface.

The present protocol was evaluated and approved by our Institutional Review Board (protocol number: 181/INT/2021; approval date: 15/12/2021). An informed consent was obtained from each patient before surgical procedure.

### 2.1 | Case 1

A 53-year-old man suffering from recurrent dermatofibrosarcoma protuberans of the left preauricular region

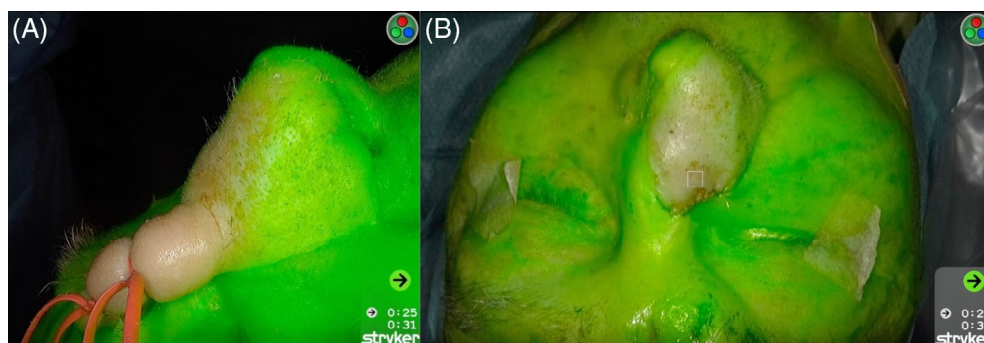


**FIGURE 1** ICG fluorescence video-angiography before (A) and after (B) supraclavicular flap second-stage pedicle division [Color figure can be viewed at [wileyonlinelibrary.com](http://wileyonlinelibrary.com)]

underwent a left total parotidectomy extended to the skin with concurrent ipsilateral neck dissection (levels IIA–IIB–III) and reconstruction with a supraclavicular flap. Second-stage pedicle division was planned 21 days later. Before dividing the pedicle, a tourniquet was put in place to atraumatically clamp it. The dose of ICG used before pedicle division was 0.20 mg/kg (total dose 15.0 mg). Subsequently, the pedicle was severed and a second ICG video-angiography was carried out to confirm the proper inosculature of the flap. The dose of ICG used was again 0.20 mg/kg (total dose 15.0 mg). The procedure was demonstrated on the Video S1, Supporting Information: fluorescence spreads all along the flap surface from the skin around it either before and after dividing the pedicle. Flap perfusion expressed as flap-to-normal skin ICG ratio was always greater than 25%–27% (threshold of tissue ischemia defined according to literature<sup>9</sup>), either before and after pedicle division (Figure 1A,B).

### 2.2 | Case 2

A 79-year-old man suffering from recurrent basocellular carcinoma of the tip of the nose underwent a partial rhinectomy and concurrent reconstruction with a PFF combined with a Mustardè cheek advancement flap. PFF



**FIGURE 2** ICG fluorescence video-angiography before (A) and after (B) paramedian forehead flap second-stage pedicle division [Color figure can be viewed at [wileyonlinelibrary.com](http://wileyonlinelibrary.com)]

second-stage pedicle division was planned 21 days later. As in the previous case, a tourniquet was put in place to clamp the flap pedicle before dividing it. The dose of ICG used before pedicle division was 0.10 mg/kg (total dose 10 mg). After severing the pedicle, the flap inosculation was confirmed with a second ICG video-angiography. The dose of ICG used was 0.075 mg/kg (total dose 7.5 mg). The procedure is described on the Video S1. Also in this case, ICG dye uptake throughout the flap surface was proven. Flap perfusion expressed as flap-to-normal skin ICG ratio was always greater than 25%–27%<sup>9</sup> either before and after dividing the pedicle (Figure 2A,B).

The ICG video-angiography was performed without adverse events in both cases. No flap failure were noted during outpatient follow-up.

### 3 | DISCUSSION

ICG fluorescence video-angiography is a widely employed tool in many medical specialties. Its potential fields of application are well-known: the demonstration of pedicled flap inosculation which allows a safe and earlier second-stage pedicle division is certainly one of these, especially in head and neck reconstructive surgery.<sup>9</sup>

ICG video-angiography represents a rapid and potentially repeatable procedure given the short half-life of the injected medium (150–180 s). A large consensus about ICG standard dosage is lacking: in the literature, doses may vary up to 3 mg/kg. Regardless of its dose, ICG showed a low risk of potential adverse effects (mainly allergic ones) and conditions such as iodine allergy, closed-angle glaucoma, allergic asthma, severe hypertension, pregnancy and renal or hepatic failure represent its main contraindications.<sup>10</sup>

As far as PFF is concerned, the pedicle division may be planned after 2–6 weeks from its harvesting, depending on patient comorbidities (e.g., diabetes mellitus), smoking status, previous radiotherapy, surgeon preferences, and defect size. In these circumstances, Surowitz et al. proposed the ICG video-angiography as a method for encouraging early pedicle division.<sup>9</sup> In the same work, they also used a flap-

to-normal skin ICG ratio to assess the relative perfusion of PFF similarly to what we did, although they provided it with a previous version of the SPY software, with a post-processing analysis toolkit: actually, this new device allowed us to have a real-time feedback of flap perfusion, with clear advantages. Obviously, the same concepts may be translated even to other pedicled flaps, as our experience with supraclavicular one demonstrated.

With regards to the few papers published on this topic, a value of relative perfusion beneath 25%–27% was reported as suggestive of flap ischemia<sup>9</sup>: whenever lower values are obtained after atraumatic clamping of the pedicle, it means that a safe pedicle division cannot be performed without a substantial risk of subsequent flap failure. Our values of relative perfusion largely exceeded those thresholds (range: 40%–93% for case 1, 47%–125% for case 2; see Video S1) and no flap failure was noted during outpatient follow-up, indeed. However, the choice of the “baseline” reference point for relative perfusion assessment is conventional: similarly to the work of Surowitz et al.,<sup>9</sup> we picked the point of maximum signal intensity in the skin adjacent to the recipient site of the flap, which may be considered as expression of the peripheral vascularization of the skin that will allow the flap to survive after second-stage pedicle division.

To date, no specific techniques are known to predict the perfusion of pedicled flaps in head and neck reconstructive surgery as properly as ICG video-angiography. Despite adding additional costs,<sup>8</sup> it may allow earlier second-stage pedicle division leading to reduction of costs (outpatient dressings and consultations, donor site morbidity) and duration of esthetic deformity for patients.<sup>7</sup> The new high-resolution device that we have employed adds further accuracy to the traditional ICG video-angiography, providing a real-time flap-to-normal skin ICG ratio which is easily understandable. Further controlled studies with larger samples are needed to confirm our findings.

### CONFLICT OF INTEREST

The authors declare that there is no conflict of interest that could be perceived as prejudicing the impartiality of the research reported.

## DATA AVAILABILITY STATEMENT

Data sharing is not applicable to this article as no new data were created or analyzed in this study.

## ORCID

Leone Giordano  <https://orcid.org/0000-0001-9094-4205>

Andrea Galli  <https://orcid.org/0000-0003-2677-8091>

Marco Familiari  <https://orcid.org/0000-0002-9763-3183>

Rosa Alessia Battista  <https://orcid.org/0000-0002-2391-2008>

## REFERENCES

1. Lee LN, Smith DF, Boahene KD, Byrne PJ. Intraoperative laser-assisted indocyanine green imaging for objective measurement of the vascular delay technique in locoregional head and neck flaps. *JAMA Facial Plast Surg*. 2014;16(5):343-347. doi:10.1001/jamafacial.2014.106
2. Battista RA, Giordano L, Giordano Resti A, et al. Combination of Mustardè cheek advancement flap and paramedian forehead flap as a reconstructive option in orbital exenteration. *Eur J Ophthalmol*. 2021;31(3):1463-1468. doi:10.1177/1120672120976550
3. Giordano L, Di Santo D, Occhini A, et al. Supraclavicular artery Island flap (SCAIF): a rising opportunity for head and neck reconstruction. *Eur Arch Otorhinolaryngol*. 2016;273(12):4403-4412. doi:10.1007/s00405-016-4092-4
4. Giordano L, Di Santo D, Bondi S, et al. The supraclavicular artery Island flap (SCAIF) in head and neck reconstruction: an Italian multi-institutional experience. *Acta Otorhinolaryngol Ital*. 2018;38(6):497-503. doi:10.14639/0392-100X-1794
5. Giordano L, Bondi S, Toma S, Biafora M. Versatility of the supraclavicular pedicle flap in head and neck reconstruction. *Acta Otorhinolaryngol Ital*. 2014;34(6):394-398.
6. Bramati C, Melegatti MN, Lalla F, Giordano L. Management of two rare cases of dermatofibrosarcoma protuberans arising in the parotid region. *BMJ Case Rep*. 2021;14(6):1-6. doi:10.1136/bcr-2021-243837
7. Rudy SF, Abdelwahab M, Kandathil CK, Most SP. Paramedian forehead flap pedicle division after 7 days using laser-assisted indocyanine green angiography. *J Plast Reconstr Aesthetic Surg*. 2021;74(1):116-122. doi:10.1016/j.bjps.2020.05.079
8. Mücke T, Hapfelmeier A, Schmidt LH, et al. A comparative analysis using flowmeter, laser-Doppler spectrophotometry, and indocyanine green-videoangiography for detection of vascular stenosis in free flaps. *Sci Rep*. 2020;10(1):1-12. doi:10.1038/s41598-020-57777-2
9. Surowitz JB, Most SP. Use of laser-assisted indocyanine green angiography for early division of the forehead flap pedicle. *JAMA Facial Plast Surg*. 2015;17(3):209-214. doi:10.1001/jamafacial.2015.0171
10. Li K, Zhang Z, Nicoli F, et al. Application of Indocyanine green in flap surgery: a systematic review. *J Reconstr Microsurg*. 2018;34(2):77-86. doi:10.1055/s-0037-1606536

## SUPPORTING INFORMATION

Additional supporting information may be found in the online version of the article at the publisher's website.

**How to cite this article:** Giordano L, Galli A, Familiari M, et al. Head and neck pedicled flap autonomization using a new high-resolution indocyanine green fluorescence video-angiography device. *Head & Neck*. 2022;44(6):1496-1499. doi:10.1002/hed.27051