



2020

Delayed Repair of Aortic Dissection in Sickle Cell Anaemia as a Combined Cardiac and Vascular Surgical Approach

Massimo Capoccia

Aortic and Cardiac Surgery Royal Brompton Hospital Sydney Street Chelsea London SW3 6NP United Kingdom

Maziar Mireskandari

Vascular Surgery, Royal Brompton Hospital, London, United Kingdom

Nicholas J. Cheshire

Vascular Surgery, Royal Brompton Hospital, London, United Kingdom

Ulrich P. Rosendahl

Aortic and Cardiac Surgery, Royal Brompton Hospital, London, United Kingdom

Follow this and additional works at: <https://www.j-saudi-heart.com/jsha>



Part of the [Cardiology Commons](#)



This work is licensed under a [Creative Commons Attribution-Noncommercial-No Derivative Works 4.0 License](#).

Recommended Citation

Capoccia, Massimo; Mireskandari, Maziar; Cheshire, Nicholas J.; and Rosendahl, Ulrich P. (2020) "Delayed Repair of Aortic Dissection in Sickle Cell Anaemia as a Combined Cardiac and Vascular Surgical Approach," *Journal of the Saudi Heart Association*: Vol. 32 : Iss. 2 , Article 6.

Available at: <https://doi.org/10.37616/2212-5043.1043>

This Case Report is brought to you for free and open access by Journal of the Saudi Heart Association. It has been accepted for inclusion in Journal of the Saudi Heart Association by an authorized editor of Journal of the Saudi Heart Association.

Delayed repair of aortic dissection in sickle cell anaemia as a combined cardiac and vascular surgical approach

Massimo Capoccia^{a,*}, Maziar Mireskandari^b,
Nicholas J. Cheshire^b, Ulrich P. Rosendahl^a

^a Aortic and Cardiac Surgery, Royal Brompton Hospital, London, United Kingdom

^b Vascular Surgery, Royal Brompton Hospital, London, United Kingdom

Abstract

We discuss a patient who presented with a type B aortic dissection with a retrograde progression in the context of sickle cell anaemia. Given the involvement of the superior mesenteric artery and concern for bowel ischaemia, a delayed approach was considered. Subsequently, a frozen elephant trunk was performed in the hybrid theatre with the back-up of the vascular surgeon for mesenteric protection. A technically demanding procedure followed by a prolonged and challenging postoperative course finally led to a successful outcome. We argue that the case presented is an example of how a close cooperation between professionals can offer additional options to treatment based on a mixture of skills and background to achieve the desired outcome.

Keywords: Aortic aneurysm, Aortic dissection, Frozen elephant trunk, Cardiac surgeons, Vascular surgeons

1. Introduction

Traditionally, aortic disease has been approached by cardiac and vascular surgeons individually where each professional has focused on a specific section of the vessel. Nevertheless, aortic disease frequently involves the whole vessel with particular reference to dissection and aneurysm. A close cooperation between cardiac and vascular surgeons for the treatment of aortic disease is currently being acknowledged as an effective approach although not completely accepted by many. Here we present a case of aortic dissection whose treatment has benefited from our established and well amalgamated aortic team.

2. Case presentation

A 60-year-old patient was referred to our hospital with features suggestive of type A aortic dissection on initial CT-scan assessment made by the radiology team of the referring Hospital (Fig. 1 and Fig. 2). Co-morbidities included arterial hypertension, sickle cell anaemia and chronic renal impairment requiring dialysis for which a left brachio-cephalic fistula had been created. Following transfer and further review of the available images, it was clear that the dissection extended to the superior mesenteric artery (SMA) giving matter of concern for potential bowel ischemia postoperatively (Fig. 3). Therefore, a decision was made to maintain blood pressure control with β -blocker intravenously and intervene 24 h later. The aim would be to perform a digital subtraction angiography (DSA) in our hybrid

Received 30 November 2019; revised 12 January 2020; accepted 12 January 2020.
Available online 20 May 2020

* Corresponding author. Aortic and Cardiac Surgery, Royal Brompton Hospital, Sydney Street, Chelsea, London, SW3 6NP, United Kingdom.

E-mail address: capoccia@doctors.org.uk (M. Capoccia).



theatre to further assess the visceral vessels and insert a wire in the SMA for stenting after the planned surgical procedure. Following contrast injection, it became evident that the features of the disease were more consistent with a type B dissection that had progressed in a retrograde manner with lower entry points in the descending thoracic aorta (Fig. 4). These findings allowed us to plan a definitive surgical strategy following a period of stabilisation. Aortic arch replacement with a frozen elephant trunk under hypothermic circulatory arrest with potential TEVAR extension and mesenteric protection should the need arise to address the SMA was considered an appropriate delayed course of action on this occasion^{1,2}. In the meanwhile, the patient would be nursed in the high dependency unit with strict blood pressure control using β -blocker and ACE-inhibitor. Initial medical management was relatively successful although serial CT-scan imaging showed further dilatation of the ascending aorta, which triggered the final timing for intervention.

Plasmapheresis was required to address the sickle cell anaemia preoperatively.

The patient was transferred once again to our hybrid theatre and prepped in the supine position. Invasive arterial and venous monitoring was obtained through the left and right radial artery, left femoral artery and right internal jugular vein. Cardiopulmonary bypass was established through right femoral and right atrial cannulation. Antegrade and retrograde cold blood cardioplegia was delivered for

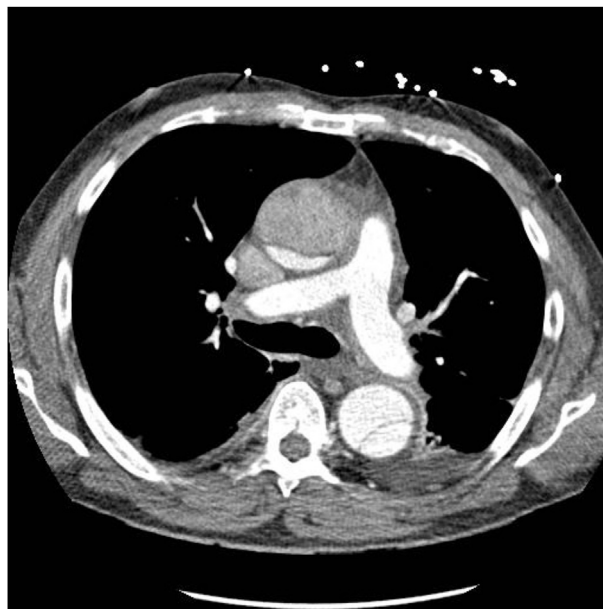

Fig. 2. Preoperative contrast CT-scan showing false and true lumen relationship in ascending and descending thoracic aorta.

myocardial protection. Body temperature at 24 °C was considered as a compromise in view of the sickle cell anaemia. Antegrade cerebral perfusion was achieved with cannulation of each epi-aortic vessel following longitudinal incision of the ascending aorta and arch. Continuous, non invasive monitoring of cerebral oxygen saturation was maintained with near infrared spectroscopy (NIRS)

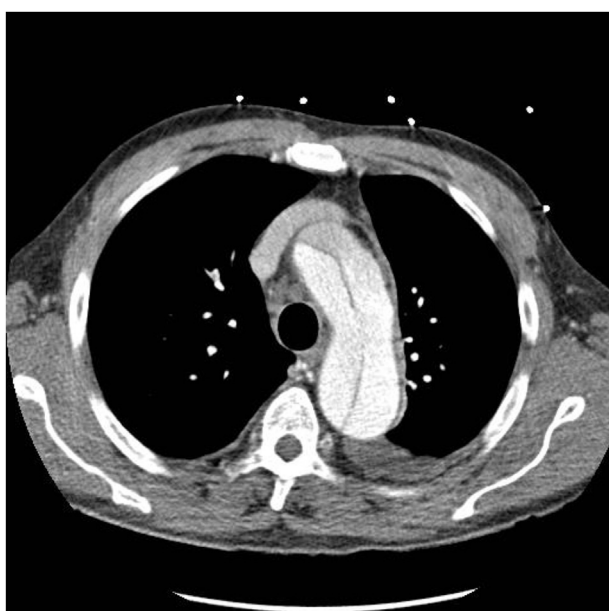

Fig. 1. Preoperative contrast CT-scan highlighting arch involvement.

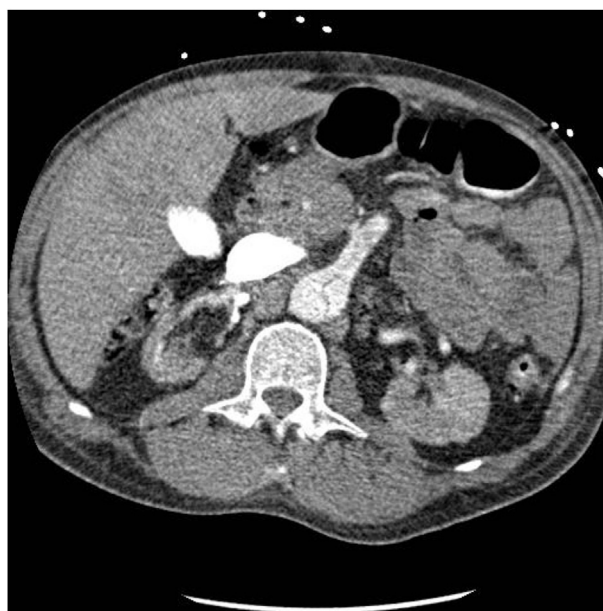

Fig. 3. Preoperative contrast CT-scan highlighting involvement of the superior mesenteric artery.

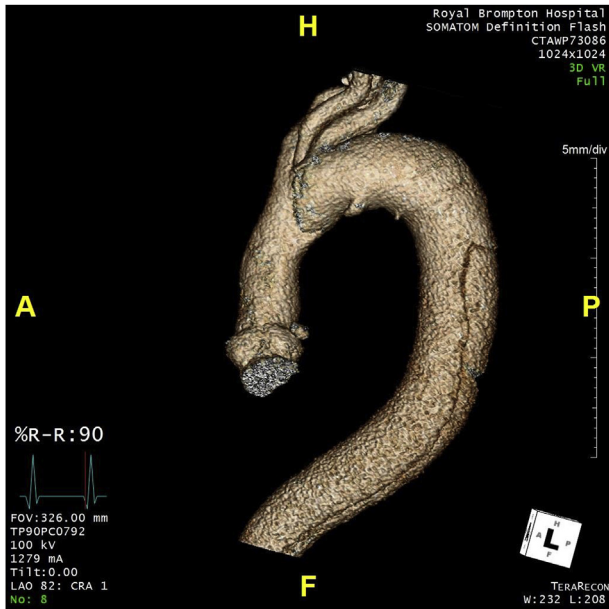


Fig. 4. Preoperative 3D reconstruction of the key areas of the dissection.

using INVOS™ 5100C Cerebral/Somatic Oximeter monitoring system. A frozen elephant trunk with a 28 mm Thoraflex™ Hybrid Plexus 4 device (Vascutek, TERUMO Aortic, Inchinnan, UK) was performed with distal anastomosis within zone 2 sparing the left subclavian artery under circulatory arrest. Subsequently, distal reperfusion was commenced through the side arm of the Thoraflex. The true lumen placement of the stent of the Thoraflex was guaranteed by the presence of a stiff wire previously inserted through the left femoral artery under image intensifier. Then, the proximal anastomosis was completed maintaining further myocardial protection. Finally, the innominate and left common carotid arteries were de-branched and anastomosed to the Thoraflex device. The patient was rewarmed and gradually weaned off cardiopulmonary bypass. Blood products, surgical sealants and additional suturing were required to achieve satisfactory haemostasis. Atrial and ventricular pacing wires were used for temporary pacing as required. Three chest drains inserted and the chest closed in layers. An on table angiogram was performed, which confirmed appropriate placement of the Thoraflex stented component in the descending thoracic aorta with satisfactory occlusion of the distal entry point. Therefore, further stenting as previously planned was not required at this stage. Also the SMA did not require further attention. The postoperative course was complicated by temporary impairment of gas exchanges requiring aggressive

physiotherapy and CPAP delivery. Regular filtration was used to address the renal impairment. Strict blood pressure control was addressed. Close liaison with haematology and intensivists colleagues was maintained as far as postoperative management of the sickle cell anaemia was concerned. Finally, the patient was discharged to the local hospital 19 days postoperatively for continuity of care. The histological findings were consistent with features of cystic medial necrosis and atherosclerosis in the absence of granuloma and vasculitis.

A postoperative echocardiographic and CT-scan assessment was considered extremely satisfactory (Fig. 5). The innominate and left common carotid arteries remained well perfused. The left subclavian artery still showed some residual dissection without obstruction. Residual degree of perfusion of the false lumen was observed with celiac axis and SMA appropriately perfused from both true and false lumen as preoperatively. Follow-up appointment was arranged at 3 months with further CT-aortic angiogram. Next step would be another CT-aortic angiogram at 6 months with the aim to keep yearly imaging surveillance according to our established routine.

3. Discussion

Traditionally, the treatment of acute type A aortic dissection has been immediate surgery whereas type B would be addressed more conservatively. Over the years the attitude has shifted towards a

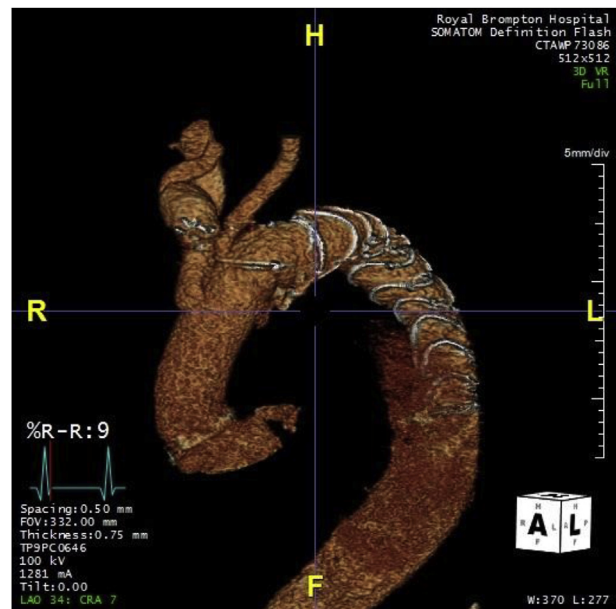


Fig. 5. Postoperative 3D reconstruction following deployment of the stented portion of the Thoraflex device.

more delayed and planned repair^{3,4}, which is currently our approach as reported in this case. The challenge related to the presence of sickle cell anaemia even more required a careful delayed and planned intervention. The role of the aortic team is being acknowledged⁵ but still not completely and widely accepted. A close cooperation between the two disciplines allows sharing of different skills settings with a real time joint operating by senior surgeons to shorten procedure time.

The Thoraflex™ is a multi-branched hybrid device with a high degree of versatility, which makes it suitable for the management of complex aortic disease involving the arch and the proximal descending thoracic aorta like the case here discussed. It is a short device with a malleable shaft which allows shaping of the stented component to adapt to the isthmus and the descending thoracic aorta reducing potential trauma to the aortic wall. The sewing collar between the Dacron tube and the stented component facilitates the distal anastomosis. The separate branches allow re-implantation of the epi-aortic vessels with better haemostatic control. Such a hybrid device allows single-stage completion of complex aortic procedures involving the proximal descending thoracic aorta⁶. We aimed at zone 2 to avoid unnecessary complications with the distal anastomosis. On this occasion, we managed to spare the left subclavian artery because it did not require attention. Ligation is appropriate if the vessel is severely affected with the option of an extra-anatomical by-pass between the left subclavian artery and the left common carotid artery if necessary. Re-implantation of the left subclavian artery remains the ideal procedure when feasible.

The back-up of the vascular colleagues was particularly important on this occasion should additional stenting be required to extend the frozen elephant trunk graft if it had not covered the large defect in the descending thoracic aorta. In addition, a real time intervention to detect and treat visceral ischaemia would be available if needed given the involvement of the SMA. Although treatment in the presence of visceral malperfusion remains controversial without a definitive agreement, our delayed approach has achieved the desired outcome and is supported by others^{7–9}. When working as individual specialists, we tend to have a limited approach without considering the aorta as a whole entity, which can be diffusely diseased. For this reason, an aortic aneurysm or a dissection may well benefit from a multidisciplinary approach where there is not competition for patients but on the contrary

every possible option is being offered. Although communication between teams takes time and may lead to treatment delay, it remains an important element when dealing with patients with complex background requiring the input of multiple specialists. The benefit of operating in the same room means that the original plan may evolve according to the difficulty of the procedure and patient's need. We can do things together that could not be done individually. Needless to say, this unique type of work requires the right support from anaesthetist, operating room technicians and intensive care unit staff intra-operatively and postoperatively. There are not just surgeon-based factors: the system has to be built around what can be done to achieve the desired outcome. The case here discussed is only an example of a different way of working towards successful outcome where a true team effort remains the key element.

4. Conclusion

Communication and willingness to cooperate remain an essential element towards progress and development. The case discussed in this context is an example of a different approach to treatment based on an established cooperation between professionals with a common aim.

Informed consent

The patient had been consented at the time of surgery for his anonymised information to be published in this article.

Funding

The authors did not receive any financial support.

Author contribution

M. Capoccia: Conception, Design, Supervision, Materials, Data collection and/or processing, Analysis and/or interpretation, Literature review, Writer, Critical review. **U Rosendahl:** Conception, Analysis and/or interpretation, Critical review. **N. Cheshire:** Conception, Analysis and/or interpretation, Critical review. **M. Mireskandari:** Conception, Analysis and/or interpretation, Critical review. All authors have approved the final version of the manuscript.

Declaration of Competing Interest

The authors declare no conflict of interest.

References

- 1 Girdauskas E, Kuntze T, Borger MA, Falk V, Mohr F-W. Surgical risk of preoperative malperfusion in acute type A aortic dissection. *J Thorac Cardiovasc Surg* 2009;138:1363–9.
- 2 Tsagakis K, Jánosi RA, Frey UH, Schlosser T, Chiesa R, Rassaf T, et al. True lumen stabilization to overcome malperfusion in acute type I aortic dissection. *Semin Thorac Cardiovasc Surg* 2019;31:740–8.
- 3 Estrera AL, Huynh TTT, Porat EE, Miller III CC, Smith JJ, Safi HJ. Is acute type A aortic dissection a true surgical emergency? *Semin Vasc Surg* 2002;15(2):75–82.
- 4 Fleck T, Hutschala D, Czerny M, Ehrlich MP, Kasimir M-T, Cejna M, et al. Combined surgical and endovascular treatment of acute aortic dissection type A: preliminary results. *Ann Thorac Surg* 2002;74:761–6.
- 5 Czerny M, Schmidli J, Adler S, van den Berg JC, Bertoglio L, Carrel T, et al. Current options and recommendations for the treatment of thoracic aortic pathologies involving the aortic arch: an expert consensus document of the European Association for Cardio-Thoracic Surgery (EACTS) and the European Society for Vascular Surgery (ESVS). *Eur J Cardio Thorac Surg* 2019;55:133–62.
- 6 Ruggieri VG, Vola M, Anselmi A, Verhoye JP. Multibranched hybrid device for frozen elephant trunk: what does it change? *J Thorac Cardiovasc Surg* 2015;150:253–5.
- 7 Di Eusano M, Trimarchi S, Patel HJ, Hutchison S, Suzuki T, Peterson MD, et al. Clinical presentation, management, and short-term outcome of patients with type A acute dissection complicated by mesenteric malperfusion: observations from the International Registry of Acute Aortic dissection. *J Thorac Cardiovasc Surg* 2013;145:385–90.
- 8 Yang B, Patel HJ, Williams DM, Dasika NL, Deeb GM. Management of type A dissection with malperfusion. *Ann Cardiothorac Surg* 2016;5(4):265–74.
- 9 Yang B, Norton EL, Rosati CM, Wu X, Kim KM, Khaja MS, et al. Managing patients with acute type A aortic dissection and mesenteric malperfusion syndrome: a 20-year experience. *J Thorac Cardiovasc Surg* 2019;158(3):675–87. e4.