

Unilateral sternoclavicular arthritis: inflammatory arthritis or septic arthritis, that is the question – a case report

Journal of International Medical Research

50(4) 1–6

© The Author(s) 2022

Article reuse guidelines:

sagepub.com/journals-permissions

DOI: 10.1177/03000605221089786

journals.sagepub.com/home/imr

Min Cheol Chang¹  and
Mathieu Boudier-Revéret² 

Abstract

Sternoclavicular (SC) joint inflammatory arthritis and septic arthritis can have very similar presentations and can be indistinguishable if a joint fluid aspiration sample cannot be obtained. Septic arthritis of the SC joint accounts for less than 1% of all joint infections. Diagnosis is usually made on the basis of the clinical history combined with elevated infection markers in the blood, specific imaging findings, and most importantly, a positive joint aspiration bacterial culture. To make a diagnosis of SC joint septic arthritis, a high index of suspicion is generally necessary. We herein present the case of a previously healthy 52-year-old man with a 10-day history of left SC pain who improved transiently with anti-inflammatory oral medication; however, the pain subsequently increased over the next 10 days. Follow-up magnetic resonance imaging of the left SC area revealed fluid in the joint with an abscess adjacent to the joint, which was aspirated, and the sample yielded a positive *Streptococcus agalactiae* culture. Septic arthritis of the left SC joint was diagnosed, and the patient was treated surgically. This case highlights the initial challenges of distinguishing inflammatory from septic arthritis in joints in which a sample for bacterial culture cannot be easily obtained.

¹Department of Physical Medicine and Rehabilitation, College of Medicine, Yeungnam University, Daegu, Republic of Korea

²Department of Physical Medicine and Rehabilitation, Centre hospitalier de l'Université de Montréal, Montreal, Canada

Corresponding author:

Mathieu Boudier-Revéret, Department of Physical Medicine and Rehabilitation, Centre hospitalier de l'Université de Montréal, Hotel-Dieu – Pavillon Jeanne-Mance, 3850, rue St-Urbain, Montreal, Quebec, Canada, H2W 1T8.

Email: mathieu.boudier-reveret@umontreal.ca



Keywords

Arthritis, septic arthritis, inflammatory arthritis, pain, magnetic resonance imaging, bacterial culture, joint fluid aspiration

Date received: 8 November 2021; accepted: 7 March 2022

Introduction

Septic arthritis of the sternoclavicular (SC) joint accounts for less than 1% of all joint infections.¹ Clinically, it is often difficult to distinguish between inflammatory arthritis and the early stages of septic arthritis.² Although there have been several studies on the laboratory and imaging findings differentiating inflammatory arthritis and septic arthritis, there is a lack of specific findings for each disorder.³⁻⁶ When bacterial culture cannot be performed, almost all evaluation findings for these two arthritis disorders overlap.³⁻⁶ Therefore, the differentiation of inflammatory vs septic arthritis requires the integration of all laboratory and imaging findings and clinical features.

Herein, we report a case of acute SC arthritis in which a differential diagnosis was obtained despite initial uncertainty. We aim to provide clinicians with information on how to approach similar cases. The reporting of this study conforms to the CARE guidelines.⁷

Case report

A 52-year-old man visited our university hospital with pain around the left SC joint. He had no history of trauma and was otherwise healthy. He denied any intravenous (IV) drug use. His pain developed suddenly 10 days prior to presentation. The degree of pain was 7 on a numeric rating scale (NRS) without any aggravating or relieving factors. He was admitted to our hospital for evaluation and treatment of his

pain. Tenderness was present around the left SC joint, and the skin and soft tissues over the joint were erythematous and hot without skin breakdown. On radiography, no specific abnormality was observed in or around the left SC joint. However, magnetic resonance imaging (MRI) revealed fluid accumulation within the left SC joint and edema of the pectoralis major, anterior to the joint (Figure 1). Bone marrow edema, bone erosion, capsular distension, and extracapsular fluid collection were not observed. However, axial fat-suppressed contrast-enhanced T1-weighted MRI showed bone marrow enhancement in the clavicle around the left SC joint and peri-SC joint enhancement (Figure 1) as well as enhancement of the left pectoralis major muscle around the joint. Blood tests showed increased C-reactive protein (CRP) level (454 nmol/L), erythrocyte sedimentation rate (ESR; 31 mm/h), and white blood cell (WBC) count (13.02×10^9 cells/L). The levels of rheumatoid factor (5 IU/mL), total complement activity (CH50; 54 U/mL), and complement 3 (C3; 178.4 mg/dL) were within their respective normal ranges. The level of complement 4 (C4) was slightly increased (40.1 mg/dL), and human leukocyte antigen B27 (HLA-B27) expression was negative. The results of blood and urine cultures and a urinalysis were also negative. SC joint aspiration was attempted, but no fluid was aspirated.

For pain control, we administered celecoxib (200 mg) once a day and acetaminophen/tramadol (325/37.5 mg) twice a day,

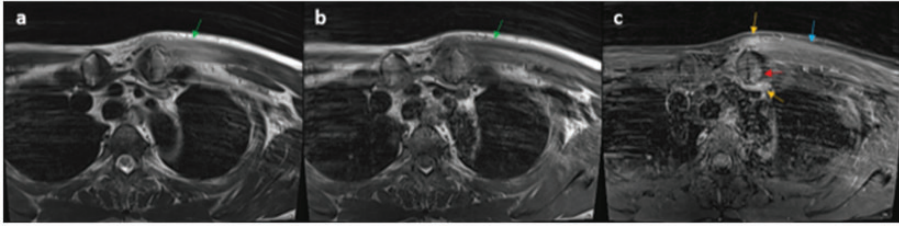


Figure 1. Imaging findings for a 52-year-old man with a 10-day history of left sternoclavicular joint pain (a) Axial T2-weighted and (b) T1-weighted magnetic resonance imaging (MRI) showing fluid accumulation within the left sternoclavicular (SC) joint and edema of the pectoralis major (green arrows) anterior to the left SC joint. (c) Axial fat-suppressed contrast-enhanced T1-weighted MRI showing bone marrow enhancement (red arrow) in the clavicle around the left SC joint and peri-SC joint enhancement (orange arrows). Enhancement of the left pectoralis major muscle (blue arrow) around the left SC joint is also visible.

after which, the patient's NRS pain score decreased from 7 to 2. The patient was informed that both inflammatory arthritis and septic arthritis were possible and that the diagnosis could not be confirmed. He was then advised to attend a follow-up evaluation of the left SC joint arthritis after a few days; however, he was discharged on his request. Seven days after the administration of the pain medication, pain reduction was sustained (NRS: 2). However, 10 days after the administration of the pain medication, the patient's pain worsened (NRS: 6), and he was readmitted.

On the follow-up radiograph 20 days after the pain onset, no specific findings were observed. Follow-up axial MRI showed fluid within the left SC joint and edema of the pectoralis major and sternocleidomastoid muscles (Figure 2). Axial fat-suppressed contrast-enhanced T1-weighted MRI revealed bone marrow enhancement of the manubrium and clavicle around the left SC joint (Figure 2). Enhancement was also found in the left pectoralis major, which extended to the supraclavicular area (to the left sternocleidomastoid muscle). In addition, a 1.5-cm × 0.8-cm × 1.5-cm rim-enhanced mass, indicative of an abscess, was found in the left sternocleidomastoid muscle. Blood tests revealed increased CRP levels (195 nmol/L), ESR (59 mm/h),

and WBC count (11.4×10^9 cells/L). Ultrasound-guided aspiration of the abscess near the SC joint was performed. In the fluid analysis, the WBC count was high, and *Streptococcus agalactiae* was cultured; therefore, SC septic arthritis was diagnosed. The orthopedic surgeon performed curettage and irrigation, and postoperatively, cefixime (100 mg) was administered orally twice daily for 1 month. At the 1-month post-operative follow-up, the patient's left SC pain was alleviated entirely. Laboratory findings related to septic arthritis, namely CRP, ESR, and WBC count, were within their respective normal ranges.

Discussion

We reported a case of left SC septic arthritis that initially could not be differentiated from inflammatory arthritis. Clinically, differentiating between inflammatory arthritis and early-stage septic arthritis is often difficult. In 2019, Kang et al.⁵ evaluated the differences between inflammatory and septic arthritis in the SC joint. The authors reported that MRI findings, including capsular distension (>5 mm), extracapsular fluid collection, periarticular muscle edema, and bony erosion (>5 mm), were observed more frequently in septic arthritis than in inflammatory arthritis.

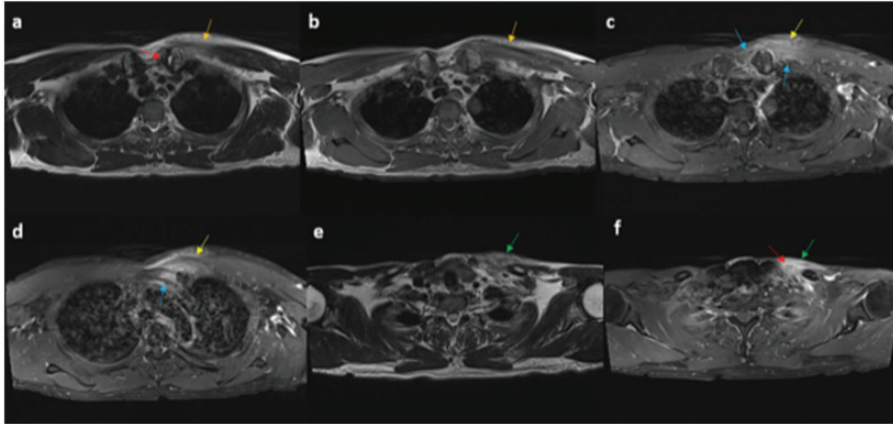


Figure 2. Follow-up images of the patient 20 days after the initial pain onset (a) Axial T2-weighted and (b) T1-weighted magnetic resonance imaging (MRI) showing fluid within the left sternoclavicular joint (red arrow) and edema of the pectoralis major and sternocleidomastoid muscles (orange arrows). (c and d) Axial fat-suppressed contrast-enhanced T1-weighted MRI showing bone marrow enhancement of the manubrium and clavicle around the left sternoclavicular joint (blue arrows). Enhancement was also seen in the left pectoralis major muscle (yellow arrow). (e and f) Axial T2-weighted and fat-suppressed contrast-enhanced T1-weighted MRI showing that the muscle edema (green) and enhancement extended to the supraclavicular area (left sternocleidomastoid muscle) (green arrows). Additionally, abscess formation (white arrow) is visible in the left sternocleidomastoid muscle.

Furthermore, the authors reported that the age of patients with septic arthritis (mean: 53.4 ± 9.8 years) was higher than that of patients with inflammatory arthritis (mean: 39.0 ± 10.8 years). Additionally, the CRP level, ESR, and WBC count were significantly higher in septic arthritis (means: 1124 ± 895 nmol/L, 66.2 ± 29.5 mm/h, and $12.25 \pm 5.02 \times 10^9$ cells/L, respectively) compared with the values in inflammatory arthritis (means: 124 ± 114 nmol/L, 23.0 ± 10.1 mm/h, and $8.34 \pm 2.50 \times 10^9$ cells/L, respectively). On first admission, the findings of periarticular muscle edema on MRI, and the elevated CRP level (454 nmol/L) and WBC count (13.02×10^9 cells/L) suggested the possibility of septic arthritis in the present case. Moreover, our patient's age (52 years) was close to the mean age (53.4 years) of that of septic arthritis patients in Kang et al.'s study.⁵ Although the initial findings in our

patient indicated the possibility of septic arthritis, similar findings can also be observed in inflammatory arthritis. Thus, we could not confirm our patient's diagnosis, and we performed a short-term follow-up for accurate differentiation. Another option sometimes used in our center if SC joint aspiration is initially negative but there is a high suspicion of septic arthritis, is to lavage the joint with a small (2–3 mL) volume of sterile normal saline and re-aspirate the fluid, which is then sent for bacterial culture. A similar technique has been described for suspected prosthetic joint infection, and the method improved the diagnostic rate for infection.⁸

In our patient, follow-up MRI revealed an abscess, and more broadly extended enhancement around the SC joint was found on fat-suppressed contrast-enhanced T1-weighted MRI. Septic arthritis due to *Streptococcus agalactiae* infection was

confirmed by culture of the abscess material. In a review of 180 cases of SC septic arthritis, Ross and Shamsuddin⁹ stated that 23% of the patients had no particular risk factors. In the study, the risk factors for SC joint septic arthritis in decreasing order of frequency were: IV drug use: 21%, distant site of infection: 15%, diabetes mellitus: 13%, trauma: 12%, and infected central venous line: 9%. In the case of septic arthritis, the delayed use of antibiotics results in extensive destruction of the joint, causing functional deterioration.¹⁰ In Ross and Shamsuddin's article, complications, such as a chest-wall abscess, as in our patient, were present in 25% of the cases, whereas osteomyelitis was present in 55% of the cases, and mediastinitis was present in 13%.⁹ Definitive surgical treatment for septic arthritis is recommended with irrigation and curettage, or with more aggressive sternoclavicular joint resection, especially if osteomyelitis is present in addition to septic arthritis.^{1,11} Clinicians should consider the possibility of septic arthritis when diagnosing inflammatory arthritis, and a high index of suspicion is required.^{6,12} When these two arthritis disorders are indistinguishable, follow-up evaluations should be performed at short-term intervals for accurate diagnosis and prompt application of appropriate treatment.

In conclusion, this report highlights the difficulty differentiating between inflammatory arthritis and early-stage septic arthritis by reporting a case of SC septic arthritis that was initially confused with inflammatory arthritis. We believe that our report raises awareness regarding the possibility of misdiagnosis between inflammatory arthritis and septic arthritis. For accurate differentiation, a short-term follow-up evaluation is necessary. In addition, our report and discussion provide information to help clinicians differentiate between the two arthritis disorders in clinical practice.

Ethics statement

The review board of Yeungnam University Hospital approved this study (number 2021-08-056). We received written informed consent from the patient for publication.

Declaration of conflicting interest

The authors declare that there is no conflict of interest.

Funding

The authors disclosed receipt of the following financial support for the research, authorship, and publication of this article: This study was supported by the National Research Foundation of Korea Grant funded by the Korean government (No. NRF2021R1A2C1013073).

ORCID iDs

Min Cheol Chang  <https://orcid.org/0000-0002-7629-7213>

Mathieu Boudier-Revéret  <https://orcid.org/0000-0003-0259-8520>

References

1. von Glinski A, Yilmaz E, Rausch V, et al. Surgical management of sternoclavicular joint septic arthritis. *J Clin Orthop Trauma* 2019; 10: 406–413.
2. Margaretten ME, Kohlwes J, Moore D, et al. Does this adult patient have septic arthritis? *JAMA* 2007; 297: 1478–1488.
3. Graif M, Schweitzer ME, Deely D, et al. The septic versus nonseptic inflamed joint: MRI characteristics. *Skeletal Radiol* 1999; 28: 616–620.
4. Kang Y, Hong SH, Kim JY, et al. Unilateral sacroiliitis: differential diagnosis between infectious sacroiliitis and spondyloarthritis based on MRI findings. *AJR Am J Roentgenol* 2015; 205: 1048–1055.
5. Kang BS, Shim HS, Kwon WJ, et al. MRI findings for unilateral sternoclavicular arthritis: differentiation between infectious arthritis and spondyloarthritis. *Skeletal Radiol* 2019; 48: 259–266.
6. Womack J. Septic arthritis of the sternoclavicular joint. *J Am Board Fam Med* 2012; 25: 908–912.

7. Gagnier JJ, Kienle G, Altman DG, et al. The CARE guidelines: consensus-based clinical case reporting guideline development. *Headache* 2013; 53: 1541–1547.
8. Nwawka OK, Tischler B, Lin B, et al. Utility of lavage in addition to native fluid collection during fluoroscopically guided joint aspiration in infection diagnosis. *J Orthop Res* 2021; 39: 1884–1888.
9. Ross JJ and Shamsuddin H. Sternoclavicular septic arthritis: review of 180 cases. *Medicine (Baltimore)* 2004; 83: 139–148.
10. Shirtliff ME and Mader JT. Acute septic arthritis. *Clin Microbiol Rev* 2002; 15: 527–544.
11. Song HK, Guy TS, Kaiser LR, et al. Current presentation and optimal surgical management of sternoclavicular joint infections. *Ann Thorac Surg* 2002; 73: 427–431.
12. Gillis S, Friedman B, Caraco Y et al. Septic arthritis of the sternoclavicular joint in healthy adults. *J Intern Med* 1990; 228: 275–278.