


Metastatic subretinal abscess in a patient with perinephric abscess

*Monika Kapoor, Preeti Singh, Nayana TK,
Siddharth Madan, Sarita Beri*

Access this article online	
Quick Response Code:	Website: www.ijo.in
	DOI: 10.4103/ijo.IJO_1369_20

Department of Ophthalmology, Lady Hardinge Medical College and Associated Hospitals, University of Delhi, New Delhi, India

Correspondence to: Dr. Siddharth Madan, Department of Ophthalmology, Lady Hardinge Medical College and Associated Hospitals, University of Delhi, New Delhi, India. E-mail: drsiddharthmadan@gmail.com

Received: 08-May-2020

Revision: 09-Jun-2020

Accepted: 26-Jul-2020

Published: 26-Oct-2020

An 80-year-old lady with uncontrolled type 2 diabetes developed fever and abdominal pain followed by a sudden diminution of vision in her left eye. Right infra-renal abscess accounted for abdominal pain. A metastatic left subretinal abscess was diagnosed subsequently. Medical management for her systemic condition initiated. Vitreous biopsy was performed along-with intravitreal antibiotic administration. Because of no clinical recovery, patient underwent pars plana vitrectomy. Prompt systemic stabilization and a timely surgical intervention in the left eye resulted in a satisfactory visual gain. Metastatic subretinal abscess following a perinephric abscess is rare phenomenon and only a few cases are reported to date.

Key words: Endogenous endophthalmitis, metastatic endophthalmitis, perinephric abscess, subretinal abscess, vitrectomy

This is an open access journal, and articles are distributed under the terms of the Creative Commons Attribution-NonCommercial-ShareAlike 4.0 License, which allows others to remix, tweak, and build upon the work non-commercially, as long as appropriate credit is given and the new creations are licensed under the identical terms.

For reprints contact: WKHLRPMedknow_reprints@wolterskluwer.com

Cite this article as: Kapoor M, Singh P, Nayana TK, Madan S, Beri S. Metastatic subretinal abscess in a patient with perinephric abscess. Indian J Ophthalmol 2020;68:2580-2.

Endogenous endophthalmitis (EE) is a rare yet potentially blinding ocular emergency, accounting for 2%–8% of all cases of endophthalmitis.^[1,2] This results from the hematogenous spread of microorganism via septic emboli that arise from a distant focus of pyogenic infection reaching choroid, eventually infiltrating the retina and spilling into the vitreous cavity.^[1,2] Recent work by Pillai GS and colleagues have suggested that approximately 90.24% of the patients with EE have at least one systemic co-morbid condition, of which the most common co-morbidity is diabetes mellitus.^[3] Development of a metastatic subretinal abscess is relatively rare but may become more common as the number of chronically debilitated patients and use of invasive procedures are in increasing trend. The diagnosis is mostly clinical while awaiting the results from intraocular and/or blood culture.

Case Report

An 80-year-old lady presented to medicine emergency with fever, chills, and generalized abdominal pain accompanied with increased frequency of painful micturition for 15 days duration. She noticed a sudden onset of defective vision in her left eye (OS) for the last 3 days before presentation. This eye was pseudophakic as cataract surgery was performed two years back with good postoperative visual gain [Fig. 1a]. She was a known diabetic and hypertensive, on irregular treatment for eight years. She suffered right-sided hemiparesis four years back though she recovered completely. In her current presentation, she was conscious, sick looking, febrile, and pale. Abdomen was tender in the right lumbar area. At presentation random blood sugar was 360 mg/dL, HbA1c-10.7%, Hemoglobin-6.8 gm%, serum triglycerides—370 mg/dL, blood urea—67 mg%, and serum creatinine—1.8 mg/dL. Peripheral blood smear showed microcytic hypochromic anemia with mild leucocytosis. Blood culture and urine culture revealed no growth. Ultrasound abdomen demonstrated infra-renal fluid collection [5 × 2.7 mm] below right kidney with right renal hydronephrosis; however, this minimal fluid was not amenable to aspiration. Empirical treatment with intravenous ceftriaxone along with insulin and fluids was started.

On ophthalmic evaluation, the patient could perceive hand movement close to face from her right eye (OD) and could only perceive light OS with accurate projection of rays in all quadrants in both eyes. On slit-lamp examination, a mature senile cataract was present OD [Fig. 1b]. LE had anterior chamber cells 2+. Intraocular pressure was 15 mm Hg OD and 11 mmHg OS. Fundus details were not visible OD. Media was hazy due to vitritis OS; however, the optic disc could be seen hazily along-with an ill-defined, yellowish, elevated subretinal lesion of size approximately two disc diameters just temporal to fovea [Fig. 1c]. Ultrasound B-scan OD was anechoic. Mild to moderate intensity spikes in mid vitreous were seen OS. Since the right eye had no acute visual complaint, the provisional diagnosis was subretinal abscess OS secondary to the perinephric abscess. After 7 days of systemic treatment, a vitreous biopsy was sent for microbiological analysis. Gram-positive cocci were identified on gram stain however no growth was obtained on culture. Intravitreal antibiotic (vancomycin 1 mg/0.1 mL, piperacillin 225 µg/0.1 mL, and amphotericin B 5 µg/0.1 mL) were administered empirically in the same sitting.

Patient's systemic condition improved and fever subsided along-with control of blood sugar levels. Persistent vitritis and no visual improvement prompted pars plana vitrectomy (PPV) with the removal of vitreous adjacent to the abscess, however, abscess drainage was deferred to limit more trauma in an already inflamed eye and to reduce future risk of retinal detachment [Fig. 2a]. Similar intravitreal antibiotics were repeated after PPV and were also injected over the abscess. On the first postoperative day, vision improved to finger count at one meter, fundus clarity increased, lesion became more defined and reduced in size [Fig. 2b]. On postoperative day 13, vision improved to 6/60, and size of lesion decreased further. Yellowish atrophic patches appeared around the lesion which pointed to a healing process [Fig. 2c]. Postoperative optical coherence tomography showed atrophy of all retinal layers corresponding to this lesion [Fig. 2d]. She is doing well.

Discussion

Subretinal abscess is a severe manifestation of EE.^[1,2] Major risk factors for the development of EE are immune-compromised states like malignancy, organ transplant, diabetes mellitus, end-stage liver/kidney disease, intravenous drug use, indwelling catheter, chronic steroid use or dental procedure.^[2] A retrospective review from a quaternary referral center in south India reported an even distribution of fungi and bacteria among the culture-positive cases of EE.^[3] 76.93% bacterial isolates were attributed to Gram-positive bacteria, of which *Staphylococcus aureus* was the most common and 23.07% were due to Gram-negative bacteria. *Aspergillus* species was the most common fungus that was isolated (53.8%) followed by *Candida albicans* (30.7%).^[3] Further, perinephric abscess is usually due to Gram-negative enteric bacilli or a polymicrobial infection due to *Escherichia coli*, *Staphylococcus aureus*, and *Klebsiella pneumoniae*.^[3-5] *Candida albicans* and *Aspergillus* are commonly seen fungi which account for 11.1% to 17.54% of total EE cases in the Asian population.^[6,7]

The treatment of subretinal abscess is controversial and no standard management or clear guidelines for performing vitrectomy have been described. Intravenous antibiotics alone, PPV, PPV with intravitreal antibiotics, PPV with retinectomy, or enucleation are possible management options.^[8] Tsai TH and Peng KL have suggested that if the size of the subretinal abscess was smaller than four disc areas, PPV with intravitreal antibiotic injection could be successful and in larger lesions, PPV with retinectomy to remove adequate abscess should be considered.^[9] Venkatesh *et al.* used a 41-G translocation needle to make a self-sealing small retinotomy to deliver drugs in subretinal lesion.^[10] One of the previous case reports described metastatic choroidal abscess in a diabetic patient with *Staphylococcal aureus* associated renal abscess which was managed with systemic antibiotics and showed improvement in the abscess, but later presented with choroidal neovascularisation, vitreous hemorrhage and pre retinal hemorrhage.^[11]

Conclusion

Case reports related to subretinal abscess following perinephric abscess are anecdotal. Uncontrolled diabetes apparently accounted for EE in this case. The management was challenging

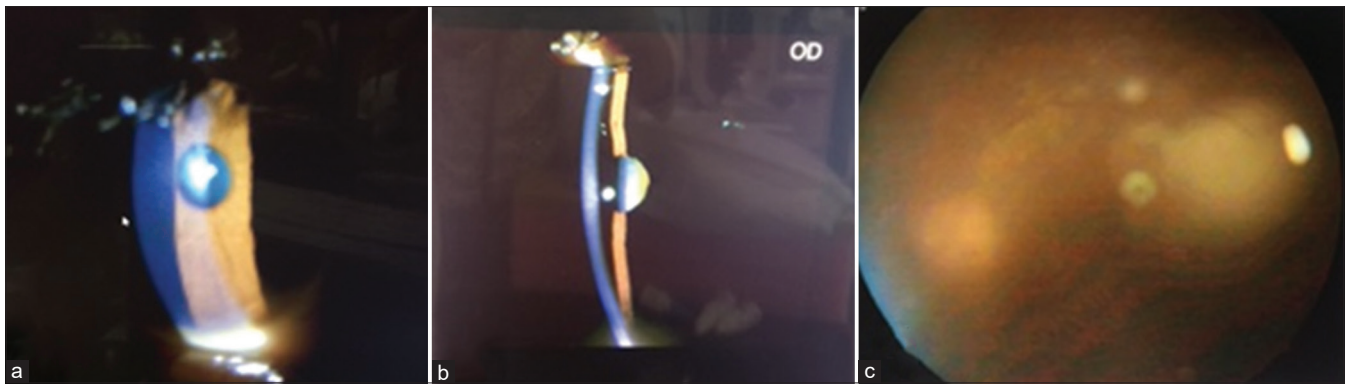


Figure 1: (a-c) Left eye was pseudophakic (a). Right eye had a mature senile cataract (b). Media was hazy due to vitritis OS, however optic disc could be seen hazily along-with an ill-defined, yellowish, elevated subretinal lesion of size approximately two disc diameters just temporal to fovea (c)

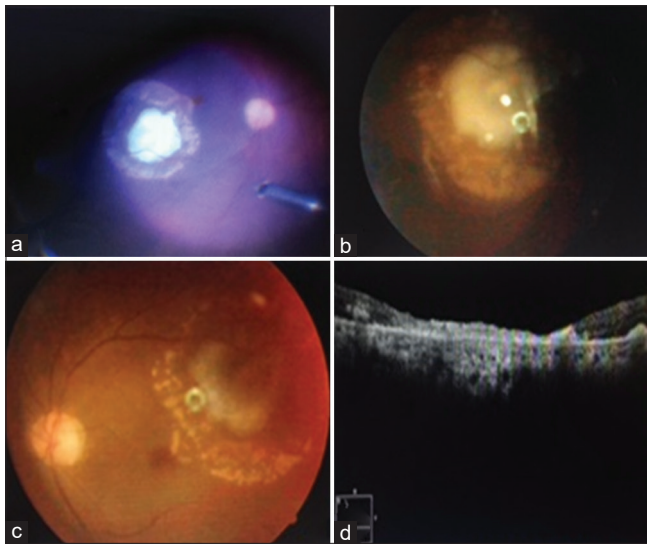


Figure 2: (a-d) Intraoperative appearance of the abscess (a). Abscess reduced in size on postoperative day 1 (b). On 13th postoperative day, media clarity improved and yellowish atrophic patches surrounding the resolving abscess pointed to a healing process (c). Postoperative OCT showed atrophy of all retinal layers corresponding to this lesion (d)

as vitreous biopsy did not reveal any growth of a microorganism on culture. This could be attributed to prior treatment with intravenous antibiotics for 7 days. However, prompt decision to perform PPV with broad-spectrum intravitreal antibiotic administration along with systemic stabilization leads to a good visual outcome in this patient.

Declaration of patient consent

The authors certify that they have obtained all appropriate patient consent forms. In the form the patient(s) has/have given his/her/their consent for his/her/their images and other clinical information to be reported in the journal. The patients understand that their names and initials will not be published and due efforts will be made to conceal their identity, but anonymity cannot be guaranteed.

Financial support and sponsorship

Nil.

Conflicts of interest

There are no conflicts of interest.

References

- Chee SP, Jap A. Endogenous endophthalmitis. *Curr Opin Ophthalmol* 2001;12:464-70.
- Shrader SK, Band JD, Lauter CB, Murphy P. The clinical spectrum of endophthalmitis: Incidence, predisposing factors, and features influencing outcome. *J Infect Dis* 1990;162:115-20.
- Pillai GS, Remadevi KK, Anilkumar V, Radhakrishnan N, Rasheed R, Ravindran GC. Clinical profile and outcome of endogenous endophthalmitis at a quaternary referral centre in south India. *Indian J Ophthalmol* 2020;68:827-33.
- Jackson TL, Paraskevopoulos T, Georgalas I. Systematic review of 342 cases of endogenous bacterial endophthalmitis. *Surv Ophthalmol* 2014;59:627-35.
- Saiki J, Vaziri ND, Barton C. Perinephric and intraneuritic abscesses: A review of the literature. *West J Med* 1982;136:95-102.
- Sharma S, Padhi TR, Basu S, Kar S, Roy A, Das T. Endophthalmitis patients seen in a tertiary eye care centre in Odisha: A clinico-microbiological analysis. *Indian J Med Res* 2014;139:91-8.
- Lim HW, Shin JW, Cho HY, Kim HK, Kang SW, Song SJ, *et al.* Endogenous endophthalmitis in the Korean population: A six-year retrospective study. *Retina* 2014;34:592-602.
- Xu H, Fu B, Lu C, Xu L, Sun J. Successful treatment of endogenous endophthalmitis with extensive subretinal abscess: A case report. *BMC Ophthalmol* 2018;18:238.
- Tsai TH, Peng KL. Metastatic endophthalmitis combined with subretinal abscess in a patient with diabetes mellitus--a case report. *BMC Ophthalmol* 2015;15:105.
- Venkatash P, Temkar S, Tripathy K, Chawla R. Intralesional antibiotic injection using 41G needle for the management of subretinal abscess in endogenous endophthalmitis. *Int J Retina Vitreous* 2016;2:17.
- Wu CW, Yang CS, Chang HM, Lee FL, Hsu WM. Metastatic choroidal abscess and choroidal neovascularization in a patient with *Staphylococcus aureus* renal abscess. *Eye (Lond)* 2006;20:265-8.