

Retroperitoneoscopic renal pelvis resection as treatment of the urothelial tumor in a solitary kidney

Mateusz Wojtarowicz, Marcin Słojewski, Adam Gołąb, Piotr Petrasz

Department of Urology and Urological Oncology, Pomeranian Medical University, Szczecin, Poland

Article history

Submitted: April 11, 2013

Accepted: May 16, 2013

Correspondence

Mateusz Wojtarowicz
Department of Urology
72, Powstańców Wielkopolskich
70–111 Szczecin, Poland
phone: +48 509 404 033
mateuszwojtarowicz@gmail.com

Urothelial carcinoma of the upper urinary tract is relatively rare. The standard treatment is invariably radical nephroureterectomy. In selected cases organ sparing surgery is justified. We present the case of the tumor of the kidney pelvis in a solitary organ where laparoscopic approach was successfully applied.

Key Words: transitional cell carcinoma ◊ organ sparing ◊ laparoscopy

INTRODUCTION

The proportion of cases of the kidney cancer in Poland in 2010 was about 3.3% of all new cases, while the upper urinary tract tumors are relatively rare and the rate of new cases is about 0.22% [1]. Among kidney cancers, three histological types are the most common: clear cell, papillary and chromophobe. Histopathologically, upper urinary tract tumors are in 95% of urothelial type (transitional cell cancer – TCC), but they still represent only about 5% of all renal tumors [2, 3]. TCC of the upper urinary tract is only 5% to 6% of all urothelial tumors, while the rest occurs in the urinary bladder [4]. According to current trends in treatment of T1 renal tumors, there should mainly be considered the nephron-sparing surgery [5]. This kind of approach should be also offered to the patients with solitary kidney whenever possible. Although open surgery is the method of choice, in experienced urological centers, and in selected patients the minimally invasive treatment eg classical, single incision or robot assisted laparoscopy may

be applied in that purpose [5]. In most of cases of more advanced lesions ($\geq T2$) the radical nephrectomy is considered a standard of care. The standard treatment of TCC of upper urinary tract consists of radical nephroureterectomy which can be performed either in open or laparoscopic way [3, 4]. Properly performed laparoscopic nephroureterectomy offers comparable oncological outcomes as open surgery with all the benefits of minimally invasive treatment including less blood loss, shorter hospital stay, less postoperative pain and shorter covalenscence time [4]. In selected cases of renal failure, solitary kidney, bilateral tumors, high risk of nephroureterectomy-related complications or low-grade/low-stage tumors more conservative treatment in the form of endoscopic resection or ablation can also be used [6].

CASE REPORT

A 60-year-old man with a history of a left sided nephrectomy performed in 2008 due to 5cm renal tumor is presented. Pathology report revealed pap-

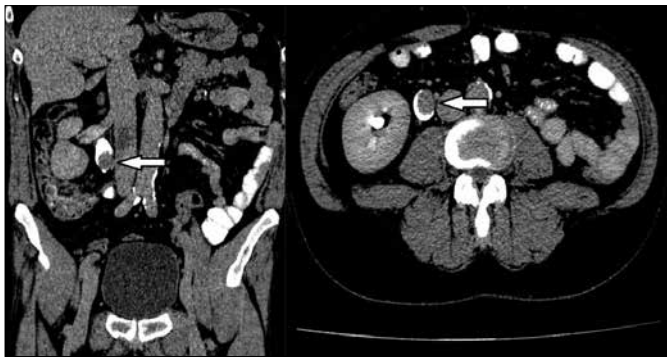


Figure 1. CT-scan in urographic phase. The arrow indicates a tumor.

illary carcinoma G2, lesion confined to the kidney, smaller than described in computer tomography (pT1aN0M0). The patient was regularly checked-up with ultrasound and computed tomography (CT) examination. However, no signs of recurrence or the presence of distal lesions were observed. In October 2012 the ultrasound examination revealed asymptomatic hydronephrosis of the solitary, right kidney caused by the lesion located near the ureteropelvic junction of this kidney. The size of the mass was 17 x 20 mm. The diuresis was preserved, the urinalysis, hematologic and biochemical parameters were correct. CT abdominal scan showed moderately enlarged pelveo-calyceal system with the extrarenal pelvis. There was a pathological lesion visible with dimensions of 22 x 15 x 22 mm, which enhanced from 30 up to 90 Hounsfield units after contrast injection (Figure 1). Urine cytology was negative. We considered the grade level of the tumor as low, so it was decided to perform conservative treatment.

Patient underwent ureterorenoscopy with the intention to confirm the presence of the papillary lesion of the right renal pelvis. During the procedure, the access to the upper part of the ureter and renal pelvis was impossible due to the kinking of the ureter. The ascending pyelogram was performed, the Double-J ureteral stent inserted, and the patient was scheduled for the operation. The risk of perioperative bleeding after a percutaneous access which may require nephrectomy of the solitary kidney was rated higher than after the laparoscopic surgery. Considerable experience in laparoscopy was an additional factor. The option of retroperitoneal laparoscopic approach was offered to the patient. After induction of the general anaesthesia, the patient was placed in the lateral position. Retroperitoneal approach, according to the previously described technique was used [7]. The ureter, renal pelvis and lower pole of the kidney were prepared typically. After the release of

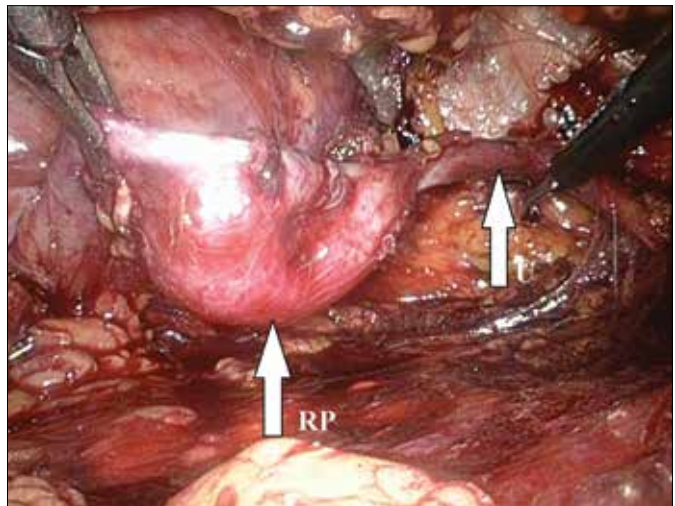


Figure 2. Intraoperative view of the retroperitoneal space (RP – renal pelvis, U – ureter).

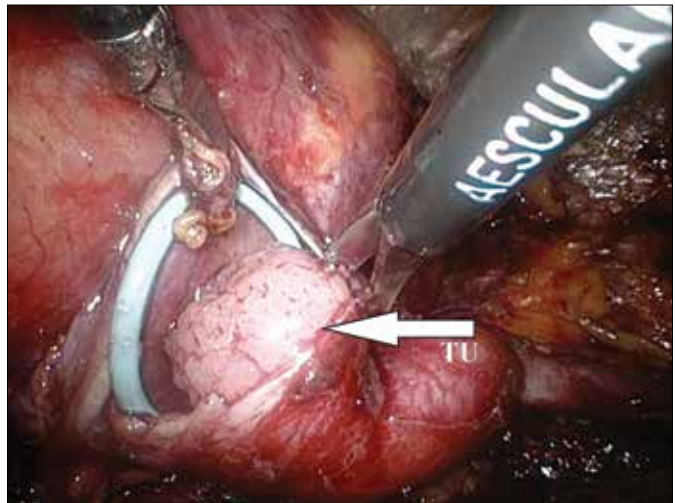


Figure 3. Same view (TU – tumor).

ureter (Figure 2), pelvis was open and the papillary tumor was visualized (Figure 3). The tumor was resected with as much wide as possible margin of healthy pelvic tissue (Figure 4). In order to avoid the spillage the specimen was placed in the plastic bag (Figure 5). The renal pelvis was reconstructed with a continuous suture (Figure 6). Postoperative course was uncomplicated. The patient was discharged home in a good condition on the 6th day after the surgery. Pathology report revealed TCC pTaG2. Two months after surgery the patient had taken ultrasound control. Examination revealed no hydronephrosis and no tumor recurrence, although a longer follow-up is needed to be certain the treatment strategy was safe and efficient.

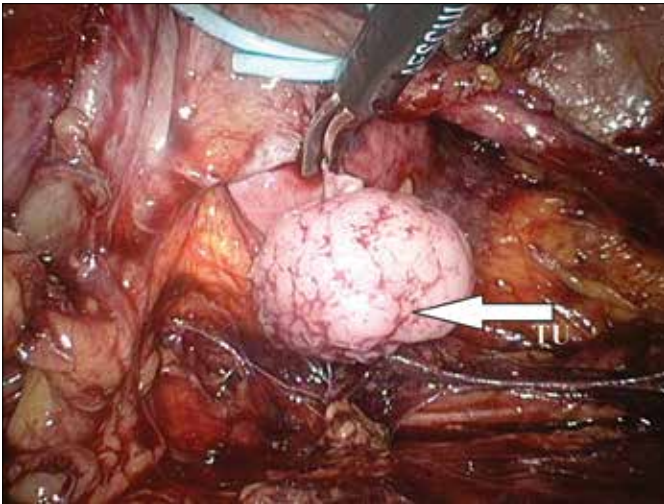


Figure 4. Excision of the tumor.

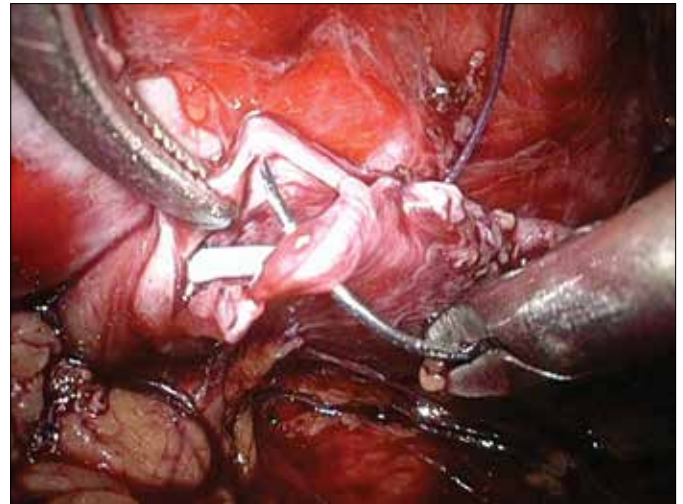


Figure 6. Reconstruction of renal pelvis.

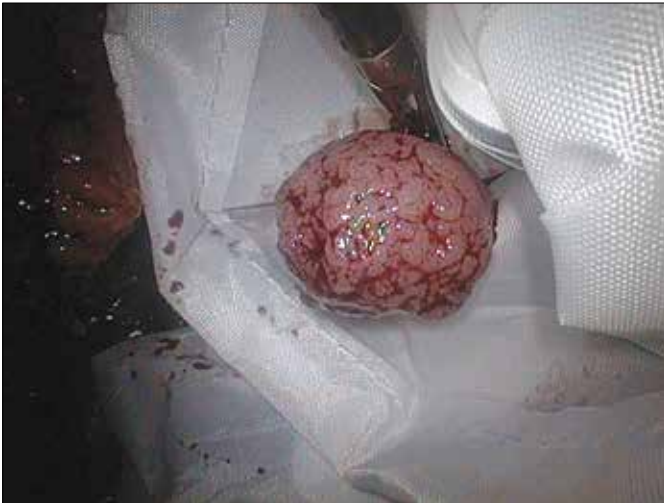

Figure 5. Tumor is placed in laparoscopic bag.

DISCUSSION

Nephroureterectomy with bladder cuff removal is the gold standard for treatment of TCC of upper urinary tract. The reduction of risk of local recurrence is the unquestionable advantage of nephroureterectomy over more conservative approach. On the other hand, kidney preservation is advantageous if adjuvant or salvage chemotherapy is required [8]. In the case of low grade/low-stage TCC of the renal pelvis, open surgery or laparoscopic surgery is being superseded by endoscopic surgery [9, 10]. With the development of endoscopic instruments, there appear more reports of conservative treatment of TCC of upper urinary tract. Endoscopic treatment is recommended for patients with low grade, su-

perforial cancer, in whom after the nephroureterectomy there is a large risk of developing renal failure (solitary kidney, low glomerular filtration, bilateral tumors) [9]. Endoscopy, however, is not always technically possible. There are some papers reporting comparable effectiveness of partial resection of the ureter and renal pelvis to nephroureterectomy [10, 11]. This procedure is less extensive for patients and is associated with lower mortality and less post-operative complications, especially kidney failure. It also eliminates the potential of over treatment [8]. However, this involves a need of rigorous follow-up of the patients after surgery. Regular endoscopic examinations are obligatory. Most upper tract recurrences are asymptomatic and are detected endourologically; by retrograde pyelography or cytology despite previously normal radiographic studies [11]. Risk factors for recurrence or progression of the greatest affinity are accompanying bladder tumor and the tumor located in the renal pelvis [9]. It seems, however, that in accordance with current trends in urology, upper urinary tract cancer treatments are also going toward minimally invasive procedures.

CONCLUSIONS

Laparoscopic resection of the renal pelvis tumor may be an effective and safe treatment for upper urinary tract tumors in selected patients.

ACKNOWLEDGEMENT

Acknowledgements for the Department of Urology and Urological Oncology for working together.

References

1. Wojciechowska U, Dikowska J, Zatoński W. Nowotwory złośliwe w Polsce w 2010 roku. Centrum Onkologii Instytut, Warszawa, 2012; Chapt 6, pp. 56–59.
2. Rouprêt M, Babjuk M, Compérat E, Zigeuner R, Sylvester R, Burger M, et al: European Guidelines on Upper Tract Urothelial Carcinomas: 2013 Update. *Eur Urol.* 2013; 63: 1059–1071.
3. Rassweiler JJ, Schulze M, Marrero R, Frede T, Palou Rederta J, Bassi P: Laparoscopic nephroureterectomy for upper urinary tract transitional cell carcinoma: is it better than open surgery? *Eur Urol.* 2004; 46: 690–697.
4. Margulis V, Shariat SF, Matin SF, Kamat AM, Zigeuner R, Kikuchi E, et al: Outcomes of radical nephroureterectomy: a series from the Upper Tract Urothelial Carcinoma Collaboration. *Cancer* 2009; 115: 1224–1233.
5. Schwentner C, Saladin SH, Radmayr, Colleselli D, Schilling D, Sievert K–D, Stenzl A: Contemporary minimal–invasive nephron–sparing surgery. *Cent Eur J Urol.* 2009; 62: 222–227.
6. Jabłonowski Z, Kędzierski R, Sosnowski M: Radical and sparing surgical treatment of patients with upper urinary tract transitional cell carcinomas (UUT–TCC) – preliminary results. *CEJU* 2011; 64: 71–74.
7. Słojewski M, Myślak M, Domański L, Pabisiak K, Jasiczek A, Sulikowski T, et al: Program of laparoscopic living–donor nephrectomy with retroperitoneoscopic access – a Polish single–center experience – success or disappointment? *Ann Transplant* 2013; 18: 82–87.
8. Giannarini G, Schumacher MC, Thalmann GN, Bitton A, Fleischmann A, Studer UE: Elective management of transitional cell carcinoma of the distal ureter: can kidney–sparing surgery be advised? *BJU Int.* 2007; 100: 264–268.
9. Iborra I, Solsona E, Casanova J, Ricós JV, Rubio J, Climent MA: Conservative elective treatment of upper urinary tract tumors: a multivariate analysis of prognostic factors for recurrence and progression. *J Urol.* 2003; 169: 82–85.
10. Thompson RH, Krambeck AE, Lohse CM, Elliott DS, Patterson DE, Blute ML: Elective endoscopic management of transitional cell carcinoma first diagnosed in the upper urinary tract. *BJU Int.* 2008; 102: 1107–1110.
11. Chen GL, El–Gabry EA, Bagley DH: Surveillance of upper urinary tract transitional cell carcinoma: the role of ureteroscopy, retrograde pyelography, cytology and urinalysis. *J Urol.* 2000; 164: 1901–1904. ■