



Fluorescence Image-Based Evaluation of Gastric Tube Perfusion during Esophagogastrostomy

Yu Hua Quan, Ph.D.^{1,2}, Kook Nam Han, M.D.¹, Hyun Koo Kim, M.D., Ph.D.^{1,2}

¹Department of Thoracic and Cardiovascular Surgery, Korea University Guro Hospital, Korea University College of Medicine; ²Department of Biomedical Science, Korea University College of Medicine, Seoul, Korea

ARTICLE INFO

Received May 11, 2020

Revised June 1, 2020

Accepted June 10, 2020

Corresponding author

Hyun Koo Kim

Tel 82-2-2626-1978

Fax 82-2-2626-1188

E-mail kimhyunkoo@korea.ac.kr

ORCID

<https://orcid.org/0000-0001-7604-4729>

¹This article was presented at the 6th Esophageal Cancer Symposium (lecture on November 16th, 2019, Samsung Medical Center, Seoul, Korea).

During esophagectomy and esophagogastrostomy, the prediction of anastomotic leakage relies on the operating surgeon's tactile or visual diagnosis. Therefore, anastomotic leaks are relatively unpredictable, and new intraoperative evaluation methods or tools are essential. A fluorescence imaging system enables visualization over a wide region of interest, and provides intuitive information on perfusion intraoperatively. Surgeons can choose the best anastomotic site of the gastric tube based on fluorescence images in real time during surgery. This technology provides better surgical outcomes when used with an optimal injection dose and timing of indocyanine green.

Keywords: Esophagectomy, Perfusion, Fluorescence, Indocyanine green

Introduction

Esophagogastrostomy is associated with high complication and mortality rates [1,2]. Anastomotic leaks are among the most significant complications following this surgical procedure, with incidence rates reported to range from 6.2% and 27% [3-5]. Further, leak-associated mortality rates range from 18% to 40%, compared to overall in-hospital mortality rates of 4%–6% [6].

One of the main causes of anastomotic leaks is poor perfusion of anastomotic sites during reconstruction following esophagectomy [7]. The anastomosis area is often weak because the gastroepiploic arterial supply rarely reaches the end of the graft. This may cause various complications such as tissue necrosis, edema, and subsequent anastomotic leakage [8-11]. Until recently, ischemia of the anastomosis area was accepted as inevitable in some patients. Therefore, predicting the risk of anastomotic leakage by determining the perfusion and viability of the gastric conduit is key to the success of the procedure. However, it is known that judgments made by operating clinicians tend

to be relatively non-sensitive and non-specific [8,12,13].

Several technologies are used to evaluate perfusion of the gastric conduit, such as single-photon emission computed tomography (SPECT), computed tomography (CT) angiography, and visible light spectroscopy [14]. However, SPECT and CT angiography are not available intraoperatively, and visible light spectroscopy provides a limited viewing area [15]. Alternatively, laser Doppler flowmetry has been used because of its ease of use and time efficiency [8,16]. However, it is limited to the microvasculature, and the region of interest is small [17].

Recently, indocyanine green (ICG) fluorescence imaging has been adopted for intraoperative assessment of the blood supply to various reconstructed organs [17]. Several studies have evaluated similar methods of intraoperative imaging of perfusion of the colon, muscle flaps, and even the gastric conduit [18]. Zehetner et al. [19] assessed gastric conduit perfusion in 150 patients who underwent esophagectomy using this technology and found that perfusion at the site of anastomosis was significantly associated with the presence of an anastomotic leak. Newer fluorescence



Table 1. Dosage of indocyanine green for intraoperative evaluation of the gastric tube

Dose	Year	Authors	Journals	References	
1.25 mg	2016	Koyanagi et al.	Medicine (Baltimore)	[23]	
	2019	Ishige et al.	J Surg Res	[24]	
2.5 mg	2011	Shimada et al.	Esophagus	[17]	
	2012	Ishiguro et al.	Int Surg	[25]	
	2014	Kumagai et al.	World J Surg	[26]	
	2014	Rino et al.	BMC Med Imaging	[27]	
	2014	Zehetner et al.	Ann Surg	[28]	
	2015	Fikfak et al.	Int J Surg Case Rep	[29]	
	2016	Hachey et al.	J Thorac Cardiovasc Surg	[30]	
	2016	Kazuo et al.	Medicine (Baltimore)	[23]	
	2017	Masaki et al.	Esophagus	[31]	
	2018	Koyanagi et al.	Dis Esophagus	[32]	
5 mg	2018	Nishikawa et al.	Ann Surg	[33]	
	2015	Campbell et al.	J Gastrointest Surg	[34]	
	2015	Kitagawa et al.	Anticancer Res	[35]	
	2015	Kamiya et al.	J Surg Res	[36]	
	2017	Schlottmann et al.	J Laparoendosc Adv Surg Tech A	[37]	
	7.5 mg	2016	DeLong et al.	J Vis Surg	[38]
		2017	Karampinis et al.	Int J Surg	[39]
12.5 mg	2018	Noma et al.	J Am Coll Surg	[40]	
	2019	Sugimura et al.	J Surg Res	[41]	
25 mg	2012	Saito et al.	J Surg Oncol	[42]	
	2018	Miyauchi et al.	Yonago Acta Med	[43]	
30 mg	2018	Van Daele et al.	Medicine (Baltimore)	[44]	
36 mg	2018	Quan et al.	J Thorac Dis	[14]	

imaging systems can provide a superimposed fluorescence image on top of the color image to make recognition more intuitive. Therefore, image-based, real-time evaluation of perfusion can reliably predict desirable clinical outcomes.

Since the first study of ICG fluorescence imaging for the evaluation of gastric conduit perfusion was conducted in 2011 [17], surgeons have tried to bring this technology into clinical practice. However, there are insufficient data on the dosage of ICG and how to interpret the fluorescence images.

Dosage of indocyanine green

ICG has been used to evaluate hepatic function and outline hepatectomy strategies for oncologic resections for more than 30 years, and 0.5 mg/kg of ICG is a routine dose for these measurements [20]. Up to 2 mg/kg is considered to be a safe dose, and 5 mg/kg is the maximum intravenous dose for humans [21].

In a previous study, we showed that 0.6 mg/kg of ICG was an optimal dose to define the intersegmental plane based on blood perfusion during lung segmentectomy [22]. The same dose of ICG enabled successful detection of a

fluorescence signal from the gastric tube in a preclinical study with pigs [14]. This dose is similar to the original dose used to evaluate hepatic function before hepatic segmentectomy and is hence familiar and easily adopted by surgeons.

ICG solution is made by dissolving 25 mg of ICG in powder form into 10 mL of distilled water just before usage, resulting in a concentration of 2.5 mg/mL. In real-world clinical situations, injection of a certain mass (in milligrams) of the solution is easier than calculating each dose of ICG according to the patient's body weight. Therefore, most studies have suggested using a certain amount of ICG solution for evaluating gastric tube perfusion, with a range of 1.25–36 mg [14,17,23-44] (Table 1). Recent studies have suggested that 7.5–12.5 mg is the optimal dose for ICG fluorescence image-based evaluation of gastric tube perfusion. Based on our experience, 7.5 mg (3 mL) of ICG when using the Pinpoint Thoracoscope (Novadaq Technologies Inc., Mississauga, ON, Canada) and 12.5 mg (5 mL) when using the Firefly fluorescence imaging system (da Vinci Si system; Intuitive Surgical Inc., Sunnyvale, CA, USA) are recommended because each near-infrared fluorescence imaging system has a different fluorescence intensity.

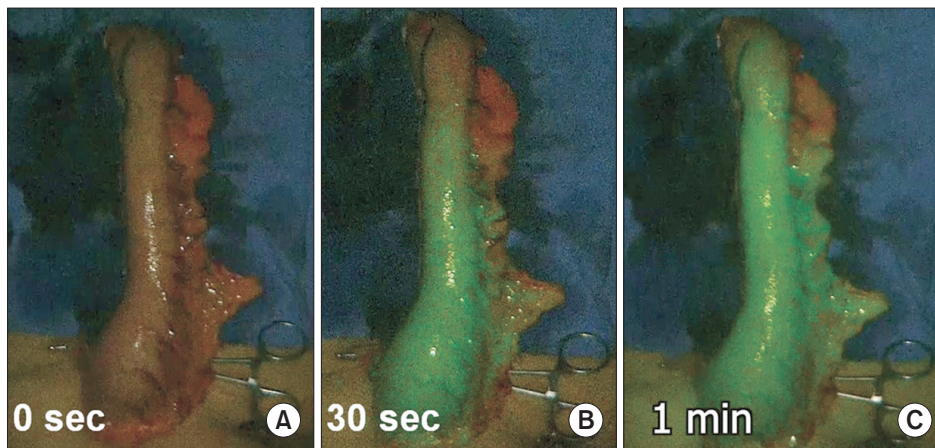


Fig. 1. (A–C) Intraoperative evaluation of gastric tube perfusion on indocyanine green fluorescence images over time.

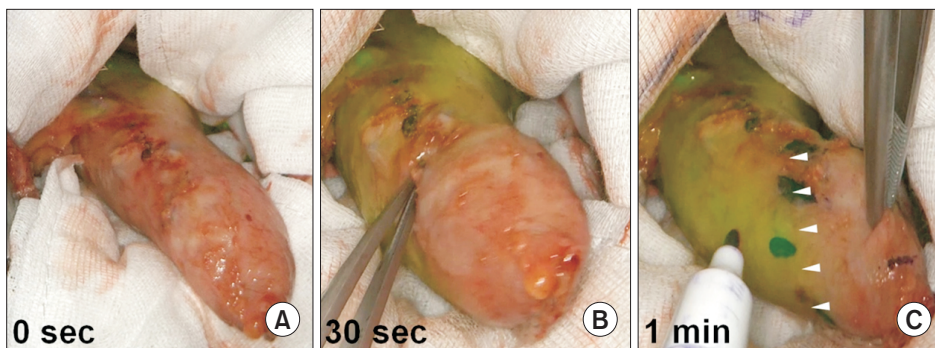


Fig. 2. (A–C) Fluorescence images showing a non-perfused area of the gastric tube 60 seconds after the injection of indocyanine green. The arrow shows the border line between the perfused and non-perfused area of the gastric tube.

Interpretation of indocyanine green fluorescence images for the measurement of gastric conduit perfusion

Zehetner et al. [19] reported that a leak was significantly less likely when the anastomosis was placed in an area of good perfusion than when it was placed in an area of less robust perfusion using ICG fluorescence imaging (2% versus 45%) in 144 patients who underwent esophagogastric anastomosis. They suggested that altering the surgical plan is necessary for some patients who show poor perfusion in the gastric tube on fluorescence images during esophagectomy with esophagogastrostomy to reduce anastomotic morbidity and promote better overall patient outcomes.

Murawa et al. [45] attempted to change the anastomotic site of the gastric tube based on perfusion status under real-time fluorescence imaging. Insufficient blood perfusion was shown in 4 of 15 patients on fluorescence images. In these 4 patients, the anastomotic site was switched to an area with good perfusion instead of the originally planned area. This surgical strategy showed better results, and an anastomotic leak was observed only in 1 patient (6.7%).

However, there was still an anastomotic leak despite good perfusion at the anastomosis under intraoperative fluorescence imaging guidance.

Kumagai et al. [32] also presented 2 cases of gastric tube necrosis among 36 cases despite selecting an area with good perfusion in the gastric tube based on fluorescence images. They did not consider the time taken until enhancement of the gastric tube tip when determining the site for esophagogastrostomy. However, a retrospective evaluation of the recorded video for these 2 cases revealed that gastric tube necrosis occurred in areas where more than 90 s was needed for ICG enhancement. Specifically, these 2 cases of gastric tube necrosis required 138 and 103 seconds for the gastric tube tip to become enhanced. Furthermore, when the enhancement time exceeded 60 seconds at the anastomosis site, minor anastomotic leaks developed in some cases. They hypothesized that the risk of anastomotic leakage might be minimized if anastomoses are created in areas that are enhanced within 60 seconds.

Our previous preclinical study also reported that 90 seconds was the optimal time for evaluating gastric tube perfusion status [14]. The clinical cases in our hospital showed

that fluorescence could be completely visualized by approximately 60 seconds in normal gastric tubes (Fig. 1, Supplementary Video 1). In our hospital, if a non-perfused area is observed in the gastric tube on fluorescence imaging 60 seconds after ICG injection, another area with good perfusion is selected as the anastomotic site instead of the original site (Fig. 2, Supplementary Video 2).

Conclusion

A fluorescence imaging system allows visualization over a wide region of interest and provides intuitive information on perfusion from the gastric tube during esophagectomy and esophagogastrectomy. Surgeons can determine, in real time, the best anastomotic site of the gastric tube based on intraoperative fluorescence images. This technology is associated with better surgical outcomes when used with an optimal injection dose and timing of ICG.

Conflict of interest

No potential conflict of interest relevant to this article was reported.

Funding

This study was supported by the Korean Health Technology R&D Project, Ministry of Health and Welfare, Republic of Korea (ID: HI19C0166).

ORCID

Yu Hua Quan: <https://orcid.org/0000-0002-6620-1388>
 Kook Nam Han: <https://orcid.org/0000-0002-1508-0125>
 Hyun Koo Kim: <https://orcid.org/0000-0001-7604-4729>

Supplementary materials

Supplementary materials can be found via <https://doi.org/10.5090/kjtcvs.2020.53.4.178>. **Supplementary Video 1.** The clinical cases in our hospital showed that fluorescence could be completely visualized by approximately 60 seconds in normal gastric tubes. **Supplementary Video 2.** Fluorescence images showing a non-perfused area of the gastric tube 60 seconds after the injection of indocyanine green.

References

- Bailey SH, Bull DA, Harpole DH, et al. *Outcomes after esophagectomy: a ten-year prospective cohort.* Ann Thorac Surg 2003;75:217-22.
- Ferguson MK, Martin TR, Reeder LB, Olak J. *Mortality after esophagectomy: risk factor analysis.* World J Surg 1997;21:599-604.
- Sarela AI, Tolan DJ, Harris K, Dexter SP, Sue-Ling HM. *Anastomotic leakage after esophagectomy for cancer: a mortality-free experience.* J Am Coll Surg 2008;206:516-23.
- Udagawa H, Akiyama H. *Surgical treatment of esophageal cancer: Tokyo experience of the three-field technique.* Dis Esophagus 2001; 14:110-4.
- Roh S, Iannettoni MD, Keech J, et al. *Timing of esophagectomy after neoadjuvant chemoradiation therapy affects the incidence of anastomotic leaks.* Korean J Thorac Cardiovasc Surg 2019;52:1-8.
- Van Daele E, van Nieuwenhove Y, Ceelen W, et al. *Near-infrared fluorescence guided esophageal reconstructive surgery: a systematic review.* World J Gastrointest Oncol 2019;11:250-63.
- Urschel JD. *Esophagogastrectomy anastomotic leaks complicating esophagectomy: a review.* Am J Surg 1995;169:634-40.
- Boyle NH, Pearce A, Hunter D, Owen WJ, Mason RC. *Intraoperative scanning laser Doppler flowmetry in the assessment of gastric tube perfusion during esophageal resection.* J Am Coll Surg 1999;188: 498-502.
- Dewar L, Gelfand G, Finley RJ, Evans K, Inculet R, Nelems B. *Factors affecting cervical anastomotic leak and stricture formation following esophagogastrectomy and gastric tube interposition.* Am J Surg 1992;163:484-9.
- Liebermann-Meffert DM, Meier R, Siewert JR. *Vascular anatomy of the gastric tube used for esophageal reconstruction.* Ann Thorac Surg 1992;54:1110-5.
- Meyerson SL, Mehta CK. *Managing complications II: conduit failure and conduit airway fistulas.* J Thorac Dis 2014;6(Suppl 3):S364-71.
- Karliczek A, Benaron DA, Baas PC, Zeebregts CJ, Wiggers T, van Dam GM. *Intraoperative assessment of microperfusion with visible light spectroscopy for prediction of anastomotic leakage in colorectal anastomoses.* Colorectal Dis 2010;12:1018-25.
- Karliczek A, Harlaar NJ, Zeebregts CJ, Wiggers T, Baas PC, van Dam GM. *Surgeons lack predictive accuracy for anastomotic leakage in gastrointestinal surgery.* Int J Colorectal Dis 2009;24:569-76.
- Quan YH, Kim M, Kim HK, Kim BM. *Fluorescent image-based evaluation of gastric conduit perfusion in a preclinical ischemia model.* J Thorac Dis 2018;10:5359-67.
- Pacheco PE, Hill SM, Henriques SM, Paulsen JK, Anderson RC. *The novel use of intraoperative laser-induced fluorescence of indocyanine green tissue angiography for evaluation of the gastric conduit in esophageal reconstructive surgery.* Am J Surg 2013;205:349-

- 53.
16. Pierie JP, de Graaf PW, Poen H, van der Tweel I, Obertop H. *Impaired healing of cervical oesophagogastrostomies can be predicted by estimation of gastric serosal blood perfusion by laser Doppler flowmetry.* Eur J Surg 1994;160:599-603.
17. Shimada Y, Okumura T, Nagata T, Sawada S, Matsui K, Hori R, et al. *Usefulness of blood supply visualization by indocyanine green fluorescence for reconstruction during esophagectomy.* Esophagus 2011;8:259-66.
18. Kawada K, Hasegawa S, Wada T, et al. *Evaluation of intestinal perfusion by ICG fluorescence imaging in laparoscopic colorectal surgery with DST anastomosis.* Surg Endosc 2017;31:1061-9.
19. Zehetner J, DeMeester SR, Alicuben ET, et al. *Intraoperative assessment of perfusion of the gastric graft and correlation with anastomotic leaks after esophagectomy.* Ann Surg 2015;262:74-8.
20. Seyama Y, Kubota K, Sano K, et al. *Long-term outcome of extended hemihepatectomy for hilar bile duct cancer with no mortality and high survival rate.* Ann Surg 2003;238:73-83.
21. Alford R, Simpson HM, Duberman J, et al. *Toxicity of organic fluorophores used in molecular imaging: literature review.* Mol Imaging 2009;8:341-54.
22. Oh Y, Quan YH, Kim M, Kim BM, Kim HK. *Intraoperative fluorescence image-guided pulmonary segmentectomy.* J Surg Res 2015;199:287-93.
23. Koyanagi K, Ozawa S, Oguma J, et al. *Blood flow speed of the gastric conduit assessed by indocyanine green fluorescence: new predictive evaluation of anastomotic leakage after esophagectomy.* Medicine (Baltimore) 2016;95:e4386.
24. Ishige F, Nabeya Y, Hoshino I, et al. *Quantitative assessment of the blood perfusion of the gastric conduit by indocyanine green imaging.* J Surg Res 2019;234:303-10.
25. Ishiguro T, Kumagai Y, Ono T, et al. *Usefulness of indocyanine green angiography for evaluation of blood supply in a reconstructed gastric tube during esophagectomy.* Int Surg 2012;97:340-4.
26. Kumagai Y, Ishiguro T, Haga N, Kuwabara K, Kawano T, Ishida H. *Hemodynamics of the reconstructed gastric tube during esophagectomy: assessment of outcomes with indocyanine green fluorescence.* World J Surg 2014;38:138-43.
27. Rino Y, Yukawa N, Sato T, et al. *Visualization of blood supply route to the reconstructed stomach by indocyanine green fluorescence imaging during esophagectomy.* BMC Med Imaging 2014;14:18.
28. Zehetner J, DeMeester SR, Ayazi S, Kilday P, Alicuben ET, DeMeester TR. *Laparoscopic wedge fundectomy for collis gastroplasty creation in patients with a foreshortened esophagus.* Ann Surg 2014;260:1030-3.
29. Fikfak V, Gaur P, Kim MP. *Endoscopic evaluation of gastric conduit perfusion in minimally invasive Ivor Lewis esophagectomy.* Int J Surg Case Rep 2016;19:112-4.
30. Hachey KJ, Gilmore DM, Armstrong KW, et al. *Safety and feasibility of near-infrared image-guided lymphatic mapping of regional lymph nodes in esophageal cancer.* J Thorac Cardiovasc Surg 2016;152:546-54.
31. Ohi M, Toiyama Y, Mohri Y, et al. *Prevalence of anastomotic leak and the impact of indocyanine green fluorescein imaging for evaluating blood flow in the gastric conduit following esophageal cancer surgery.* Esophagus 2017;14:351-9.
32. Kumagai Y, Hatano S, Sobajima J, et al. *Indocyanine green fluorescence angiography of the reconstructed gastric tube during esophagectomy: efficacy of the 90-second rule.* Dis Esophagus 2018;31:doiy052.
33. Nishikawa K, Fujita T, Yuda M, et al. *Quantitative assessment of blood flow in the gastric conduit with thermal imaging for esophageal reconstruction.* Ann Surg 2020;271:1087-94.
34. Campbell C, Reames MK, Robinson M, Symanowski J, Salo JC. *Conduit vascular evaluation is associated with reduction in anastomotic leak after esophagectomy.* J Gastrointest Surg 2015;19:806-12.
35. Kitagawa H, Namikawa T, Muneke M, Akimori T, Kobayashi M, Hanazaki K. *Visualization of the Stomach's arterial networks during esophageal surgery using the HyperEye Medical System.* Anticancer Res 2015;35:6201-5.
36. Kamiya K, Unno N, Miyazaki S, et al. *Quantitative assessment of the free jejunal graft perfusion.* J Surg Res 2015;194:394-9.
37. Schlottmann F, Barbeta A, Mungo B, Lidor AO, Molena D. *Identification of the lymphatic drainage pattern of esophageal cancer with near-infrared fluorescent imaging.* J Laparoendosc Adv Surg Tech A 2017;27:268-71.
38. DeLong JC, Kelly KJ, Jacobsen GR, Sandler BJ, Horgan S, Bouvet M. *The benefits and limitations of robotic assisted transhiatal esophagectomy for esophageal cancer.* J Vis Surg 2016;2:156.
39. Karampinis I, Ronellenfitch U, Mertens C, et al. *Indocyanine green tissue angiography affects anastomotic leakage after esophagectomy: a retrospective, case-control study.* Int J Surg 2017;48:210-4.
40. Noma K, Shirakawa Y, Kanaya N, et al. *Visualized evaluation of blood flow to the gastric conduit and complications in esophageal reconstruction.* J Am Coll Surg 2018;226:241-51.
41. Sugimura K, Miyata H, Shinno N, et al. *Indocyanine green fluorescence imaging of the tracheal blood flow during esophagectomy.* J Surg Res 2019;241:1-7.
42. Saito T, Yano M, Motoori M, et al. *Subtotal gastrectomy for gastric tube cancer after esophagectomy: a safe procedure preserving the proximal part of gastric tube based on intraoperative ICG blood flow evaluation.* J Surg Oncol 2012;106:107-10.
43. Miyauchi W, Shishido Y, Kono Y, et al. *Less invasive surgery for remnant stomach cancer after esophago-proximal gastrectomy with ICG-guided blood flow evaluation: a case report.* Yonago Acta Med 2018;61:187-91.
44. Van Daele E, van Nieuwenhove Y, Ceelen W, et al. *Assessment of*

graft perfusion and oxygenation for improved outcome in esophageal cancer surgery: protocol for a single-center prospective observational study. Medicine (Baltimore) 2018;97:e12073.

45. Murawa D, Hunerbein M, Spychała A, Nowaczyk P, Połom K, Mu-

rawa P. *Indocyanine green angiography for evaluation of gastric conduit perfusion during esophagectomy: first experience.* Acta Chir Belg 2012;112:275-80.