



ELSEVIER

Contents lists available at ScienceDirect

JSES Open Access

journal homepage: www.elsevier.com/locate/jses

Compressive osseointegration endoprosthesis for massive bone loss in the upper extremity: surgical technique



Steven J. Hattrup, MD ^{a,*}, Krista A. Goulding, MD ^b, Christopher P. Beauchamp, MD ^a

^a Department of Orthopedic Surgery, Mayo Clinic Arizona, Phoenix, AZ, USA

^b Division of Orthopaedic Surgery, McGill University Health Centre, Montreal, QC, Canada

ARTICLE INFO

Keywords:

Compressive osseointegration
Upper extremity
Bone loss
Revision arthroplasty
Limb salvage
Upper extremity tumor

Level of evidence: Level 5, Surgical Technique

Background: Reconstruction of large segments of bone loss can be very difficult. The use of a prestressed ingrowth implant can offer an attractive surgical option in these challenging cases.

Methods: This report describes the surgical technique in depth, combining the experience of the authors. Nuances of the technique are emphasized.

Results: Although published reports are uncommon, long-term restoration of extremity function is possible with this technology.

Conclusions: The use of compressive osseointegration endoprostheses is not yet widespread in the upper extremity, but this technology adds to the host of surgical options for managing massive bone loss and difficult revision surgery.

© 2018 The Author(s). Published by Elsevier Inc. on behalf of American Shoulder and Elbow Surgeons. This is an open access article under the CC BY-NC-ND license (<http://creativecommons.org/licenses/by-nc-nd/4.0/>).

The need to reconstruct the humerus after segmental bone loss is, fortunately, relatively uncommon. It can present, however, from such conditions as resection for an extremity neoplasm, traumatic injury to the extremity, and as a sequelae of aseptic or septic loosening of prosthetic implants. Options for management include use of an allograft prosthetic composite, osteoarticular graft, and modular or custom devices.^{3,4,18,21,22,24} A short remaining segment of native bone presents additional challenges in satisfactory implant fixation in the near and far time frames. In such circumstances, a prestressed ingrowth implant (Compress; Zimmer Biomet, Warsaw, IN, USA) has been successfully used to reconstruct massive segments of bone loss in the lower extremity and more recently has been described in the upper extremity.^{10,13,14} This report describes the nuances of the use of such a device in the upper extremity.

Materials and methods

Indications

The indication for the use of this technology is the existence of limited remaining bone stock. As noted, this could be from traumatic bone loss, resection of tumor, or after prior arthroplasty. If the remaining bone from these conditions jeopardizes the secure placement of a new implant, then a compressive osseointegration

implant offers an attractive option for reconstruction (Figs. 1 and 2). The technology is contraindicated if the remaining bone is too short in length (generally <5 cm of remaining bone) or of such poor quality that it cannot withstand the application of the compressive load (residual cortex thinner than 2.5 mm). These devices are also inappropriate in the presence of infection or an uncooperative patient.

Set up

The procedure is typically performed with a combination of general anesthesia and a preoperatively administered interscalene block to aid in postoperative analgesia. The patient is placed in the beach chair position, with the head and trunk elevated approximately 45°. The patient's head is secured in the neutral position to minimize traction on the brachial plexus during the procedure. Preserving the ability to extend the shoulder intraoperatively is critical because this is necessary to instrument the humeral canal. Shoulder extension can be maintained by translating the patient's trunk laterally to the side of the operative table or by using a table break-away attachment, as is our preference (Skytron Beach Chair, Grand Rapids, MI, USA).

Exposure

Surgical exposure of the humerus revolves around 2 standard approaches. A crucial concept in exposure is the need to circumferentially control the remaining portion of the humeral shaft for safe insertion of the locking pins. This length depends on the spindle chosen. Our experience is with the short spindle

The Mayo Clinic Institutional Review Board exempted this study from review.

* Corresponding author: Steven J. Hattrup, MD, Department of Orthopedic Surgery, Mayo Clinic Arizona, 5777 E Mayo Blvd, Phoenix, AZ 85054, USA.

E-mail address: hattrup.steven@mayo.edu (S.J. Hattrup).

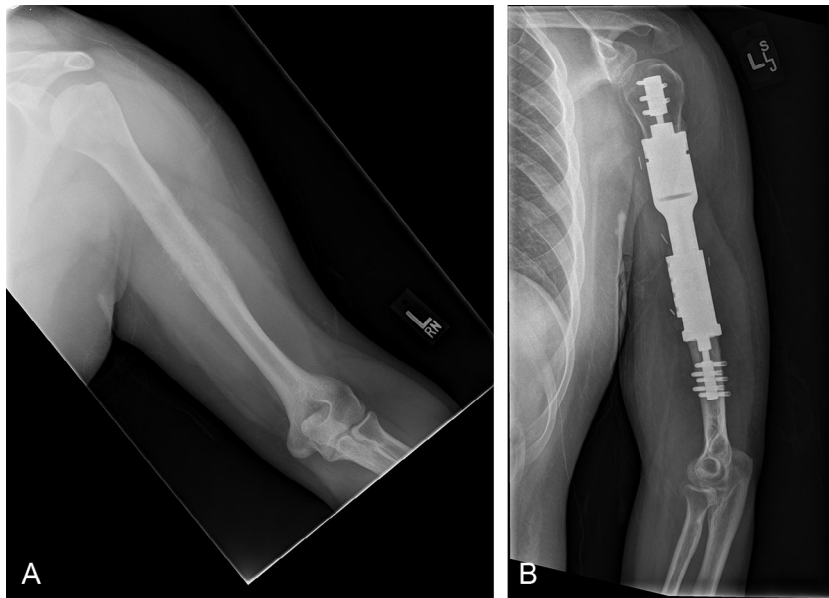


Figure 1 (A) A 22-year-old man with stage IIB Ewing sarcoma of his humerus underwent radical resection. Because of the limited remaining bone stock, an intercalary prosthesis with Compress (Zimmer Biomet, Warsaw, IN, USA) was implanted. (B) Postoperative radiographs at 41 months reveal a stable reconstruction.

necessitating approximately 5 cm of access; the standard spindle is approximately twice that length. Subperiosteal exposure of the bone for that length is not necessary but rather exposure and control of any neurovascular structures to avoid injury during bicortical pin insertion. For proximal humeral or long distal humeral resections, an extended deltopectoral approach is used. This approach will com-

fortably expose the proximal two-thirds of the humeral shaft. Given that this implant is designed for use in circumstances with short to very short bone segments, further distal exposure is commonly necessary.

In this circumstance, a second posterior approach is used, splitting the raphe between the long and lateral heads of the triceps. Because both this incision and the anterior incision with the anterolateral approach are longitudinal and separated by a wide skin bridge, both approaches can be safely used in the same procedure. As the long and lateral heads are split, the radial nerve can and should be identified in the spiral groove. Mobilization of the neurovascular bundle allows safe instrumentation of the humerus distally. After the distal humeral segment is reamed and the anchor spindle applied, the spindle-humeral shaft construct is passed forward to the anterior incision for completion of the implant assembly.

Humeral canal preparation

Identifying an area of the humeral shaft where the implant will have circumferential or near circumferential bony support is essential. The shaft should also be of sufficient thickness to support the compressive loads across the implant. This is generally considered to be a minimum of 2.5 mm, although a long 13-hole anchor plug is made for cortical thickness down to 1.0 mm. A small area of circumferential bone loss or thinning can be accepted; however, we will accept bone deficiency over no more than 10% of the shaft circumference.

The humerus is then transversely cut at this level. The level of the cut should also be made taking into consideration the implant options for eventual reconstruction (Figs. 3 and 4). A spindle trial can be used in conjunction with other implant trials to approximate the length of the final construct. The Compress system is designed to link with the Comprehensive Segmental Revision System (Zimmer Biomet), allowing creation of a proximal humeral replacement or total elbow arthroplasty. Alternatively, custom adaptors can be fashioned to couple with other endoprosthetic implants. If the available implant options do not allow a satisfactory final prosthetic length, then adjustment of the osteotomy level should be done before placement of the anchor plug. Once the plug is secured with

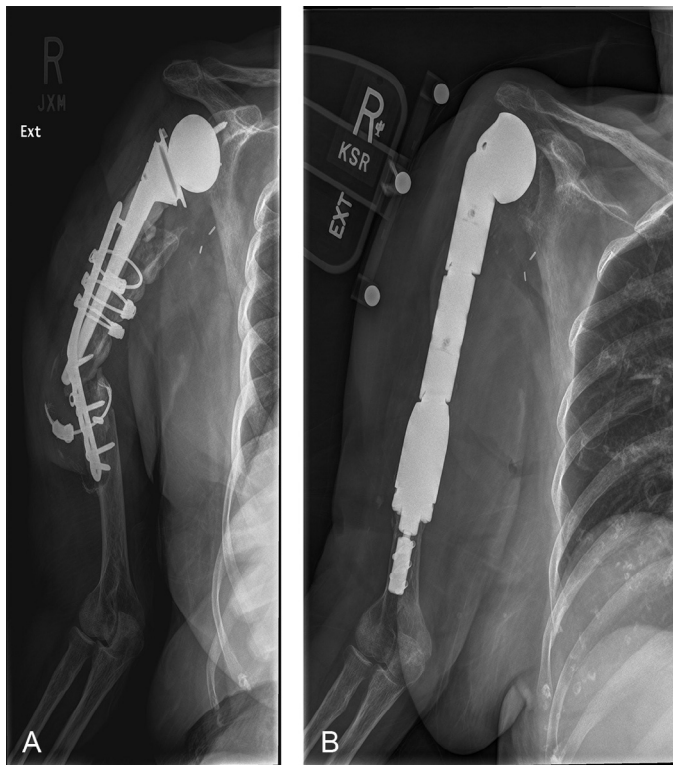


Figure 2 (A) A 73-year-old woman had an infected periprosthetic fracture non-union with a loose humeral component of her reverse shoulder arthroplasty. (B) This led to a 2-stage revision arthroplasty. At 36 months she remained infection and pain free.



Figure 3 The level of resection must take into account not only the amount necessary for treatment of the patient's disease (eg, sarcoma resection) but also the potential reconstructive options generated by assembly of the lengths. A guide, shown here, can then help determine the osteotomy site.

the transverse pins, further adjustment in length is extremely difficult. In addition, it is useful to mark the rotation of the shaft anteriorly before spindle application.

If, as is often the case, this system is being used in a revision joint arthroplasty setting, any remaining cement along the bone surface should be removed to ensure bony apposition with the ingrowth




Figure 5 The triple reamers come in 2 lengths and in serially increasing diameters. Shown are the reamers for the 45-mm and 90-mm long anchors. As indicated on their shafts, these particular reamers will ream 10 mm wide distally and 12 mm over the proximal 2 cm of the canal. The removable blades to flatten the osteotomy are also attached, completing the triple reaming function of these devices.

surface. Conversely, cement further down the canal does not need to be removed as long as the cement does not misalign the new implant or interfere with placement of the anchor plug. This marks an important benefit of the system, because removal of the entire cement mantle for placement of a stemmed endoprosthesis can be timely and carries with it the additional risk of canal perforation or fracture of the remaining bone stock.

Initial reaming of the humeral canal is performed with the Triple Reamer (Zimmer Biomet, Warsaw, IN, USA) (Fig. 5). This device will ream the canal for placement of the 45-mm or 90-mm anchor plug, determine the diameter of the centering plug at the canal opening, and provide final contouring of the osteotomy site. Reaming is sequentially done just until cortical contact is achieved; more aggressive reaming is dangerous and may unduly thin the humeral cortex. Anchor plugs are available in even increments from 10 mm to 28 mm in diameter. The triple reamers themselves increase in 1-mm increments and remove an additional 2 mm of bone from the most proximal 2 cm of the humeral shaft for the centering sleeve. Centering sleeves are available beginning at 13 mm in diameter and are not used below that size.

Anchor plug insertion

During assembly of the anchor plug instrumentation, it is essential to ensure smooth and accurate alignment of the drill guide with the anchor plug for successful pin insertion before use. The small drill guide is used with 10-mm to 12-mm anchor plugs and the large drill guide for the remaining sizes. Alignment is established by passing the included short drill bits through the most proximal and distal holes in the guide through to the plug (Fig. 6) and the long drill bit in any of the remaining holes. The assembly is then carefully tightened to hold this position. The anchor plug, attached to the assembly, can now be inserted completely into the humeral canal. The rotation of the assembly is chosen for the easiest insertion of the drill bits. The 2 short drill bits are again inserted to secure the assembly. The long drill bit can then be used to sequentially drill the remaining holes, measure the bicortical distance, and insert the transverse pins. The pin length is typically 4 mm more than the measured distance to allow slight overhang of both cortices. Overinsertion of the pin can result in unicortical purchase and, potentially, implant failure. Ideally, pin insertion is directly observed and depth confirmed. The 2 short drill bits can then be removed and transverse pins similarly inserted (Fig. 7).

Spindle insertion

The choice of the spindle size is determined by measuring the diameter of the humeral canal. The spindles are available in 25 mm

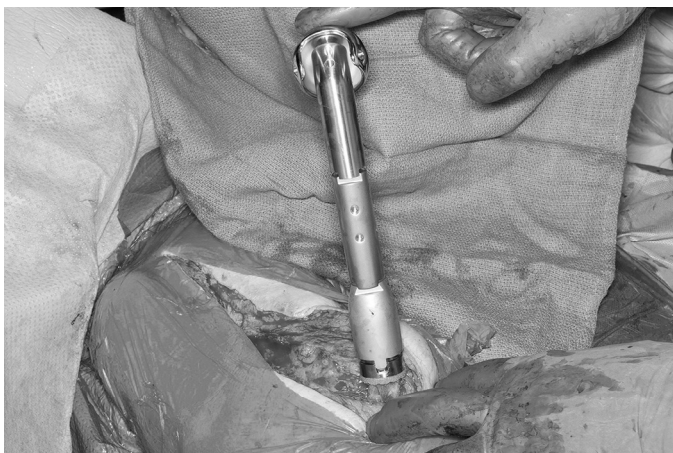

Figure 4 This patient underwent 2-stage reconstruction of an infected reverse shoulder replacement with failed internal fixation of a periprosthetic humeral nonunion. Implant assembly allowed replacement of nearly the entire humerus.

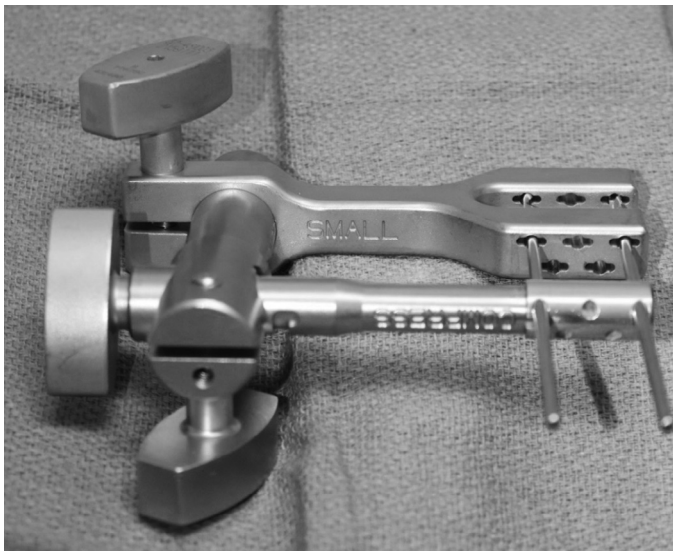


Figure 6 It is critical the drill guide be carefully aligned with the anchor plug to ensure subsequent smooth insertion of the anchor pins. The construct in this photograph uses the small drill guide for the narrower anchor plugs. The 2 shorter supplied drill bits are placed through the most proximal and distal holes, with the third and longer drill generally through either of the 2 more central holes. The clamps are carefully tightened, and smooth passage of the drill bits through all the holes is confirmed.

and 30 mm sizes; the correct choice just overhangs the cut end of the humerus. Importantly, the spindle should not be smaller than the diameter of the humeral osteotomy, and the thickness of the humeral cortex should be measured at its thinnest point. The system does supply force level options at 400, 600, and 800 pound-force (lbf) depending on the measured thickness of the cortex. The 600 and 800 lbf options are for cortical thicknesses of 4.0 and 5.5 mm, respectively. In practicality though, we typically have been limited to the 400 lbf option.¹³

Final preparation of the end surface of the humerus is performed with the small reamer blade, which works for both the 25-mm and 30-mm spindles. The reamer blade is used with the Reamer Pilot (Zimmer Biomet, Warsaw, IN, USA) and, depending on the canal diameter, potentially a centering sleeve trial. (Fig. 8) This will keep the reamer blade centered in the canal and allows the reamer to bevel the cut end of the humerus to fit the chosen spindle.

The chosen 25-mm or 30-mm spindle is matched with the correct centering sleeve. Again, the sleeves ensure the spindle is centered on the anchor plug in the humeral canal. The spindle is then passed over the traction bar of the anchor plug to rest on the prepared bony surface.

The rotation of the anchor plug is universal and requires no special attention, but this is not true for the spindle. Careful matching of the spindle rotation mark or one of the female spindle slots with




Figure 7 The pins in this Sawbones (Sawbones, Vashon Island, WA, USA) can be seen transversing the humerus to secure the anchor plug.




Figure 8 The small reamer is used with the mini-Compress (Zimmer Biomet, Warsaw, IN, USA) system over the anchor plug traction bar. A centering sleeve trial is necessary when the proximal canal diameter is 13 mm or larger. This reamer will bevel the exposed osteotomy surface to allow apposition of the ingrowth spindle surface.

the humeral reference mark allows maintenance of appropriate rotation.

Spindle application

The compressive force is now applied across the spindle-bone junction. The spindle is held with the provided antitorque wrench for counterforce and compression applied by insertion of the spindle nut down into the spindle and over the anchor plug bar (Fig. 9). The Compress nut is tightened clockwise until initial resistance is met, which indicates that the nut is in contact with the spindle washers. The nut is continually tightened until the compression cap can be unscrewed by hand in a counter-clockwise direction (Fig. 10) This should occur within a complete turn of the nut. If it does not, then the cap can be removed with a wrench, but it is prudent to double check the security of the transverse pins first to ensure fixation has not been lost.

The adaptor trial and other trial implants are now used to determine the final makeup of the prosthesis (Fig. 11).



Figure 9 After the spindle with the appropriately sized centering sleeve is placed over the anchor plug traction bar, compression must be applied. This is achieved by tightening the nut over the washers inside the spindle. (The compression cap is not shown.)

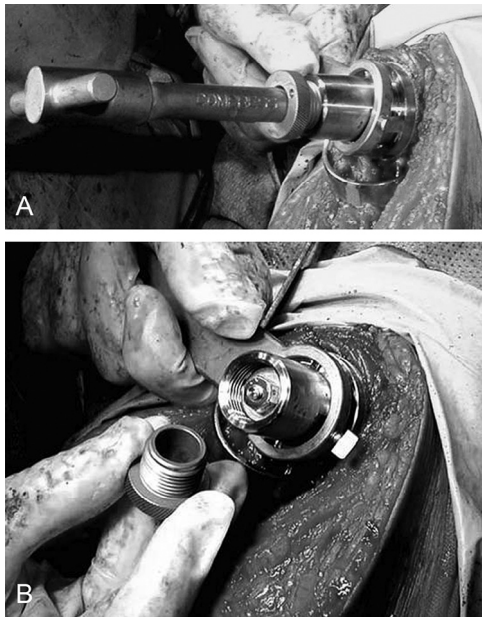


Figure 10 (A) The spindle is secured with an antitorque wrench to allow safe insertion of the nut over the traction bar. (B) After initial resistance from hitting the spindle washers, the nut continues to be tightened until the compression cap can be removed by hand. This should occur within one complete turn of the nut.

Postoperative management

For a proximal humeral reconstruction, shoulder range of motion is deferred for 6 weeks to allow scar tissue to form around the humeral head for improved stability. Elbow range of motion is performed to avoid an elbow flexion contracture due to the dissection through the brachialis. Similarly, in a distal humeral reconstruction, early range of motion helps achieve a functional elbow range. For either reconstruction, active range of motion is allowed at 6 weeks.

Results

To the best of our knowledge, Davis et al¹⁰ reported the first example of compressive osseointegrative technology use in the upper

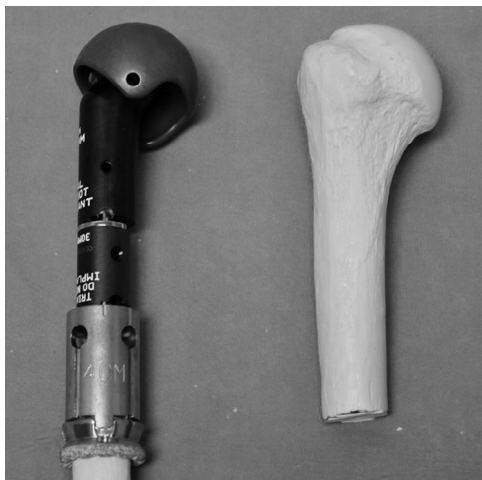

Figure 11 This Sawbones model (Sawbones, Vashon Island, WA, USA) demonstrates how the modular implant options can be used to reconstruct the appropriate length for the final prosthetic construct.

extremity in 2010. They reported a single case of distal humeral reconstruction in a post-traumatic situation. The implant was still intact at the 2-year follow-up, with the patient reporting mild to moderate pain. Range of motion was 35° to 120° of flexion with 90° of pronation and supination. We described 3 further cases of distal humeral reconstruction in 2012.¹⁴ The indication for all 3 reconstructions were for sequelae of prior oncologic resections. At a median of 26 months, the implants were intact in all patients. The median visual analog scale pain score was 1 (range, 0-3) and range of motion was -32° to 122° of flexion arc.

These 3 patients were included in a multicenter report published this year by Goulding et al.¹³ A total of 13 patients were identified, 1 of whom was lost to follow-up after 14 months of follow-up with the prosthesis intact. A variety of reconstructions were performed, including 2 proximal humeri, 2 humeral diaphyses, 7 distal humeri, and 2 proximal ulna. Because of the number of different reconstructions, the authors' assessment focused on prosthetic survival. Two of the 12 patients required revision surgery to address failure of ingrowth at the spindle surface. One of these 2 patients also had a periprosthetic bony and implant fracture. An additional 4 patients required revision surgery for other reasons, including aseptic loosening of the cemented ulnar stem (2 patients), bushing exchange for polyethylene wear (1 patient), and sepsis (1 patient).

Discussion

The etiology of bone loss in the humerus is variable, with tumor excision, osteolysis, and fracture as typical causes. The surgeon is ultimately left with less bone to support reconstruction compared with other routinely described techniques. With relatively minor bone loss, the adaption of primary techniques and prostheses usually suffice. In the distal humerus, up to 2 cm of bone loss can be accepted without changing function, and implants designed for greater bone loss can be seated proud.^{8,9,16,19} Similarly, a proximal humeral implant can be placed proud when necessary.⁷ With more significant amounts of bone loss, use of allograft prosthetic composites or oncologic endoprostheses are viable options for management of the osseous deficiency. A challenge with the use of allograft material is union of the allograft to the native bone.^{1,2,18,21,25} Stress shielding with resorption of the allograft in a long construct can occur as well. The use of a long oncologic prosthesis avoids the concerns of an allograft but is still subject to poor fixation in short bone segments and mechanical loosening.^{6,12,23}

The rationale for use of a compressive osseointegration implant is to address these concerns when faced with significant bone loss. This implant generates compressive forces across the implant-to-bone interface, thus achieving secure initial fixation and reproducible bone ingrowth by eliminating micromotion.⁵ The stress transmission additionally prevents bone resorption by transmission of physiologic load to the bone.

Although still a relatively unknown technique, compressive osseointegration surgery has been performed for many years. Published results are sparse, but there is evidence for successful bone ingrowth into the spindle surface. As early as 1993, Bini et al⁵ described excellent bone ingrowth in a retrieved specimen obtained when amputation was necessary for nonimplant reasons. Similarly, Kramer¹⁷ found new woven bone present in 12 consecutive cases of implant retrieval for infection, periprosthetic fracture, or tumor recurrence. Implant loosening was noted in only 2 infected specimens.

Clinical results in the upper extremity are limited to the 3 articles by Davis et al,¹⁰ Hatstrup and Beauchamp,¹⁴ and Goulding et al,¹³ as noted above. Published follow-up for the lower extremity is also limited but somewhat longer.^{4,11,15,20} Pedke et al²⁰ reported a 5-year prosthetic survival of 83.5% in the compressive

osseointegration with distal femoral replacement. Farfalli et al¹⁵ similarly found with 10 years of follow-up that compressive osseointegration implants had 80% survival.

Conclusion

The use of compressive osseointegration is not yet widespread in the upper extremity. However this technology broadens the armamentarium of surgical options when dealing with massive bone loss and difficult revision surgery. Of particular benefit is the ability to preserve juxtaarticular bone and the adjacent joint in long resections with short remaining end segments. Bone preservation is also valuable in young patients who may require future revision surgery during their lifetime. This surgery is highly technique dependent for success, and meticulous adherence to the surgical steps is critical for success.

Disclaimer

Steven J. Hatstrup is a paid consultant for Zimmer Biomet. The other authors, their immediate families, and any research foundations with which they are affiliated have not received any financial payments or other benefits from any commercial entity related to the subject of this article.

References

1. Abdeen A, Hoang BH, Athanasian EA, Morris CD, Boland PJ, Healey JH. Allograft-prosthesis composite reconstruction of the proximal part of the humerus: functional outcome and survivorship. *J Bone Joint Surg Am* 2009;91-A:2406-15. <http://dx.doi.org/10.2106/JBJS.H.00815>
2. Athwal GS, Chin PY, Adams RA, Morrey BF. Coonrad-Morrey total elbow arthroplasty for tumors of the distal humerus and elbow. *J Bone Joint Surg Br* 2005;87-B:1369-74. <http://dx.doi.org/10.1302/0301-620X.87B10.16569>
3. Ayoub KS, Fiorenza F, Grimer RJ, Tillman RM, Carter SR. Extensible endoprostheses of the humerus after resection of bone tumors. *J Bone Joint Surg Br* 1999;81-B:495-500.
4. Bhangu AA, Kramer MJ, Grimer RJ, O'Donnell RJ. Early distal femoral endoprosthetic survival: cemented stems versus the Compress® implant. *Int Orthop* 2006;30:465-72. <http://dx.doi.org/10.1007/s00264-006-0186-8>
5. Bini SA, Johnston JO, Martin DL. Compliant prestress fixation in tumor prostheses: interface retrieval data. *Orthopedics* 2000;23:707-11.
6. Black AW, Szabo RM, Titelman RM. Treatment of malignant tumors of the proximal humerus with allograft-prosthesis composite reconstruction. *J Shoulder Elbow Surg* 2007;16:525-33. <http://dx.doi.org/10.1016/j.jse.2006.12.006>
7. Boileau P, Walch G, Krishnan SG. Tuberosity osteosynthesis and hemiarthroplasty for four-part fractures of the proximal humerus. *Tech Shoulder Elbow Surg* 2000;1:96-109.
8. Cil A, Veillette CJ, Sanchez-Sotelo J, Morrey BF. Linked elbow replacement: a salvage procedure for distal humeral nonunion. *J Bone Joint Surg Am* 2008;90-A:1939-50. <http://dx.doi.org/10.2106/JBJS.G.00690>
9. Cobb TK, Morrey BF. Total elbow arthroplasty as primary treatment for distal humeral fractures in elderly patients. *J Bone Joint Surg Am* 1997;79-A:826-32.
10. Davis JM, Robins RJ, Frink SJ, Rispoli DM. Use of a compression tumor implant with total elbow arthroplasty for traumatic distal humeral bone loss in a young woman. *J Shoulder Elbow Surg* 2010;19:e24-8. <http://dx.doi.org/10.1016/j.jse.2010.04.008>
11. Farfalli GL, Boland PJ, Morris CD, Athanasian EA, Healey JH. Early equivalence of uncemented press-fit and Compress femoral fixation. *Clin Orthop Relat Res* 2009;467:2792-9. <http://dx.doi.org/10.1007/s11999-009-0912-9>
12. Funovics PT, Schuh R, Adams SB, Sabeti-Aschraf M, Dominkus M, Kotz RI. Modular prosthetic reconstruction of major bone defects of the distal end of the humerus. *J Bone Joint Surg Am* 2011;93-A:1064-74. <http://dx.doi.org/10.2106/JBJSJ.00239>
13. Goulding KA, Schwartz A, Hatstrup SJ, Randall RL, Lee D, Rispoli DM, et al. Use of compressive osseointegration endoprostheses for massive bone loss from tumor and failed arthroplasty: a viable option in the upper extremity. *Clin Orthop Relat Res* 2017;475:1702-11. <http://dx.doi.org/10.1007/s11999-017-5258-0>
14. Hatstrup SJ, Beauchamp CP. Custom reconstruction of the distal part of the humerus using compressive osseointegration: a report of three cases. *JBJS Case Connect* 2012;2:e54. <http://dx.doi.org/10.2106/JBJS.CC.K.00060>
15. Healey JH, Morris CD, Athanasian EA, Boland PJ. Compress knee arthroplasty has 80% 10-year survivorship and novel forms of bone failure. *Clin Orthop Relat Res* 2013;471:774-83. <http://dx.doi.org/10.1007/s11999-012-2635-6>
16. Kamineni S, Morrey BF. Distal humeral fractures treated with noncustom total elbow replacement. *J Bone Joint Surg Am* 2004;86-A:940-7.
17. Kramer MJ, Tanner BJ, Horval AE, O'Donnell RJ. Compressive osseointegration promotes viable bone at the endoprosthetic interface: retrieval study of Compress® implants. *Int Orthop* 2008;32:567-71. <http://dx.doi.org/10.1007/s00264-007-0392-z>
18. Mansat P, Adams RA, Morey BF. Allograft-Prosthesis composite for revision of catastrophic failure of total elbow arthroplasty. *J Bone Joint Surg* 2004;86-A:724-35.
19. Morrey BF, An KN, Chao EY. Functional evaluation of the elbow. In: Morrey BF, editor. *The elbow and its disorders*. 2nd ed. Philadelphia: W.B. Saunders; 1993. p. 86-9.
20. Pedtke A, Wustrack R, Fang S, Grimer R, O'Donnell RJ. Aseptic failure: how does the Compress® Implant compare to cemented stems? *Clin Orthop Relat Res* 2012;470:735-42. <http://dx.doi.org/10.1007/s11999-011-2159-5>
21. Renfree KJ, Dell PC, Kozin SH, Wright TW. Total elbow arthroplasty with massive composite allografts. *J Shoulder Elbow Surg* 2004;13:13-21. <http://dx.doi.org/10.1016/j.jse.2004.01.010>
22. Tang X, Guo W, Yang R, Tang S, Yang Y. Custom-made prosthesis replacement for reconstruction of elbow after tumor resection. *J Shoulder Elbow Surg* 2009;18:796-803. <http://dx.doi.org/10.1016/j.jse.2009.01.022>
23. Teunis T, Nota SP, Hornicek FJ, Schwab JH, Lozano-Calderón SA. Outcome after reconstruction of the proximal humerus for tumor resection: a systematic review. *Clin Orthop Relat Res* 2014;472:2245-53. <http://dx.doi.org/10.1007/s11999-014-3474-4>
24. Wang ML, Ballard BL, Kulidjian AA, Abrams RA. Upper extremity reconstruction with a humeral tumor endoprosthesis: a novel salvage procedure after multiple revisions of total shoulder and elbow replacements. *J Shoulder Elbow Surg* 2011;20:e1-8. <http://dx.doi.org/10.1016/j.jse.2010.07.018>
25. Weber KL, Lin PP, Yasko AW. Complex segmental elbow resection after tumor resection. *Clin Orthop Relat Res* 2003;(415):31-44.