



Received: 2014.07.07
Accepted: 2014.08.14
Published: 2015.01.04

Authors' Contribution:

- A** Study Design
- B** Data Collection
- C** Statistical Analysis
- D** Data Interpretation
- E** Manuscript Preparation
- F** Literature Search
- G** Funds Collection

Endovascular Treatment of an Adolescent Patient with a Ruptured Intracranial Aneurysm – Case Report and Review of Literature

Robert Juszkat^{1ABCD}, Katarzyna Jończyk-Potoczna^{1CE}, Katarzyna Stanisławska^{1ABDE}, Alicja Bartkowska-Śniatkowska^{2CE}, Jowita Rosada-Kurasińska^{2ABG}, Włodzisław Liebert^{3ADE}, Jakub Moskal^{3CE}

¹ Department of General and Interventional Radiology, Poznań University of Medical Sciences, Poznań, Poland

² Department of Pediatric Anesthesiology and Intensive Therapy, Poznań University of Medical Sciences, Poznań, Poland

³ Department of Neurosurgery and Neurotraumatology, Poznań University of Medical Sciences, Poznań, Poland

Author's address: Robert Juszkat, Department of General and Interventional Radiology, Poznań University of Medical Sciences, Poznań, Poland, e-mail: robertju@wp.pl

Summary

Background:

The occurrence of aneurysms in young patients, under 18 years of age, is estimated at 0.5–2% of all diagnosed aneurysms.

Case Report:

We reported on a case of a 16-year-old patient with subarachnoid hemorrhage diagnosed due to a ruptured cerebral vessel aneurysm. The angio-CT revealed an aneurysm of the middle cerebral artery, in its distal branch. An ad hoc coil embolization was performed with angiographic success.

After 6 months following the ictus, the patient underwent a control angiography which confirmed total occlusion of the aneurysm with no residual inflow. Clinical examination revealed no neurological deficits and the patient was rated 0 in mRS (modified Rankin Scale).

Conclusions:

In experienced departments of interventional neuroradiology the endovascular treatment should be the treatment of choice.

MeSH Keywords:

Embolization, Therapeutic • Intracranial Aneurysm • Pediatrics • Subarachnoid Hemorrhage

PDF file:

<http://www.polradiol.com/abstract/index/idArt/891344>

Background

Cerebral vessel aneurysms are reported to occur with a frequency of 5–10 cases per 100,000 population a year [1]. Aneurysms are the most common among adult patients, over 50 years old [1]. In most cases the first symptom of an aneurysm is SAH (subarachnoid hemorrhage) [1]. Treatment of intracranial aneurysms in adults is a well known issue, which resulted in numerous reports and more importantly, randomized trials performed on significant groups of patients [2]. Consequently, new guidelines have been formulated on how to treat adults with SAH.

Neuroradiologists and neurosurgeons have to confront a completely different problem when a pediatric patient is diagnosed with an aneurysm. The occurrence of aneurysms

in young patients, under 18 years of age, is estimated at 0.5–2% of all diagnosed aneurysms. [1]. Such a rare occurrence of aneurysms in this group results in a scarcity of literature concerning this issue, which makes the treatment of pediatric patients with SAH an exceptional challenge. There is a lack of publications based on a large number of patients, and the available ones are based on the analysis of several, up to 12, cases [1]. The most comprehensive study on this topic relates to 58 cases of patients under 18, but it was published in 1971. Therefore, it is difficult to apply it to contemporary treatment options [3].

Aneurysms in young patients usually occur in the posterior part of the cerebral circulation, as compared to adults, who are diagnosed with aneurysms of the anterior part [1,3]. This location of pediatric aneurysms often makes them

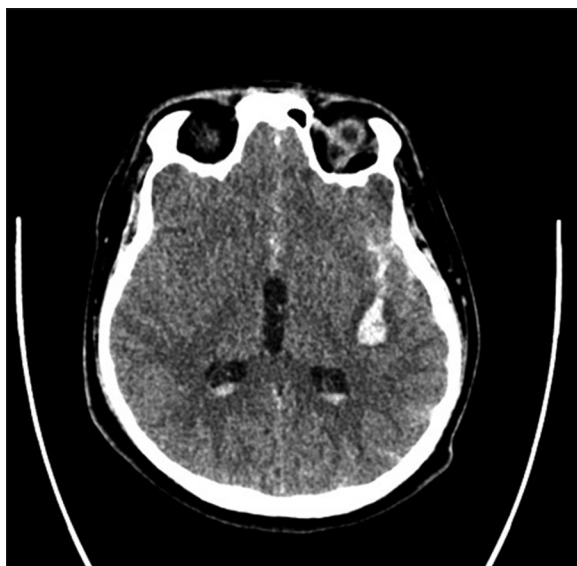

Figure 1. Computed Tomography revealed subarachnoid hemorrhage, intraventricular hemorrhage and hematoma of the left temporal lobe.

inaccessible for neurosurgeons or makes surgeries too risky [1]. Usually, aneurysms in pediatric patients occur in distal portions of cerebral arteries or in the anterior artery [4]. With no guidelines, an interdisciplinary approach to each child with SAH is of crucial importance. The choice of the therapeutic method must result from the cooperation of a neuroradiologist, neurosurgeon and anesthesiologist.

We reported on a case of a 16-year-old boy with a ruptured aneurysm of the distal segment of the middle cerebral artery (MCA), treated with coil embolization. It was the only pediatric case in our data on 838 bleeding aneurysms treated endovascularly.

Case Report

A 16-year-old patient was admitted to hospital due to the loss of consciousness with aberrations in the neurological examination. According to the history, the patient was not affected before the incidence.

In the conducted CT there was subarachnoid hemorrhage around the left hemisphere of the brain, intraventricular hemorrhage, and left temporal lobe hematoma surrounded by edema (Figure 1).

The aneurysm of the left middle cerebral artery, 8×5 mm in size, was shown during angio-CT (Figure 2).

The patient hospitalized at an intensive care unit was transferred to the Department of Neurosurgery and Neurotraumatology of the University of Medical Sciences in Poznań. After angiography, the diagnosis of the aneurysm of the middle cerebral artery was made (Figure 3). The aneurysm was localized in the distal part of the middle cerebral artery (M3 segment). The decision on ad hoc embolization was made. The patient was put under general anesthesia. With vascular access being the right femoral artery, a guiding catheter (Casasco, Balt, Montmorency, France) was

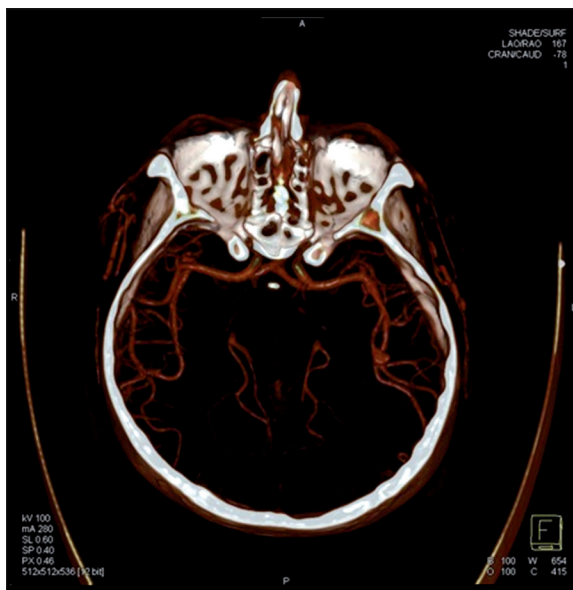

Figure 2. Middle cerebral artery aneurysm in angio-CT.

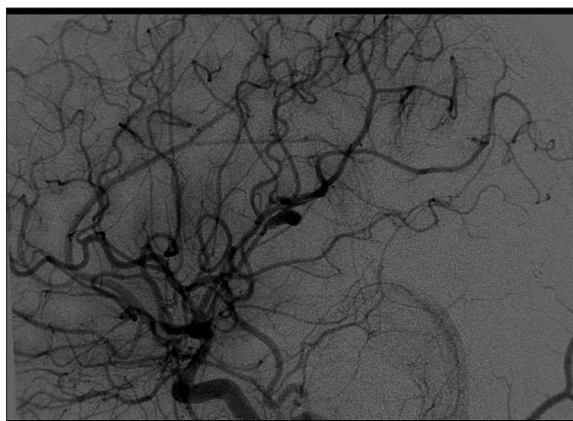


Figure 3. DSA of the left common carotid artery showed an MCA aneurysm.

introduced in the left internal carotid artery. The patient received 5000 IU of heparin i.v. Then a microcatheter Vasco 10 (Balt, Montmorency, France) with a microguidewire Sor 0,009 (Balt, Montmorency, France) was located in the aneurysmal sack. Coil embolization with 4 hydrogel coils (Microvention, Terumo) was performed with angiographic success (Figure 4). In a follow-up angiography at 6 months, total occlusion of the aneurysm was observed (Figure 5). The patient was graded 0 in mRS (modified Rankin Scale).

Discussion

The lack of literature on pediatric patients with intracranial aneurysms makes this discussion difficult. Many differences between adults and pediatric patients as regards the risk factors, location of aneurysms, follow-up schedules make it impossible to base any conclusions on randomization trials of adults patients [2]. In adults, the risk factors are well known – hypertension, smoking habit, alcohol abuse [5]. In the pediatric population, the risk factors are different – mainly connective tissue disorders such as type IV collagenopathy, type IV Ehlers-Danlos syndrome [3,4,6,7]. The

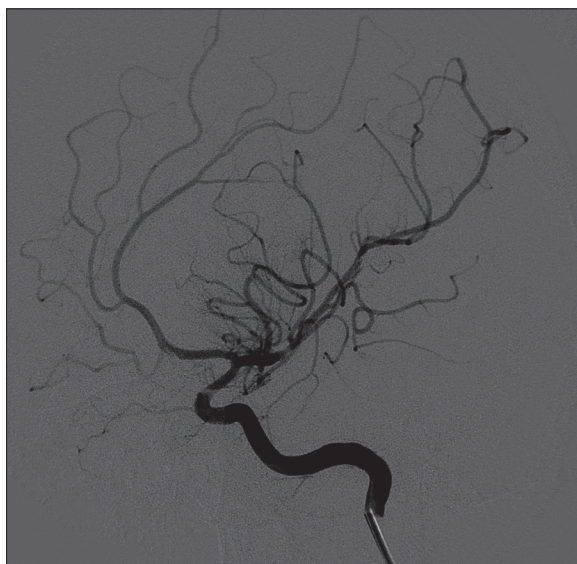


Figure 4. Control angiography of the left internal carotid artery directly after embolization – no inflow to the aneurysmal sack.

second group included traumatic and infectious aneurysms – a higher percentage than in adults [4]. Also, locations of aneurysms differed between young patients and adults. As in the presented case, a majority of aneurysms in pediatric patients are located in the peripheral segments of cerebral arteries and there is a predilection to terminal bifurcation of the internal carotid artery [4]. Moreover, among pediatric patients, a relatively higher number of aneurysms occur in the posterior part of the circle of Willis [3]. Giant aneurysms are more frequent in pediatric patients than in adults [5,8,9]. We presented a case of 16-year-old boy, the youngest patient in our data on 838 bleeding aneurysms. In the published data, the predilection to male gender is underlined (it is well known that in adults females suffer from intracranial aneurysms more often than males) [4]. These differences should make pediatricians and emergency unit staff remember that intracranial aneurysms may be the cause of neurological symptoms even in the group of young patients.

The next issue we would like to focus on is treatment strategy and follow-up schedule. As in adult patients, there are two treatment strategies – neurosurgery or endovascular

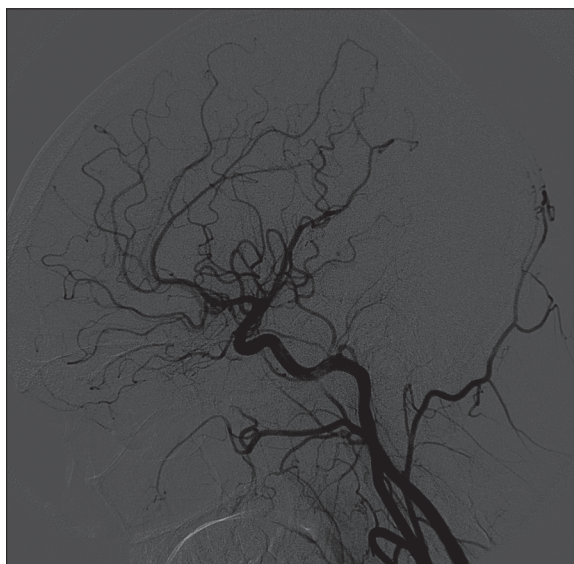


Figure 5. A 6-month follow-up angiography of the left common carotid artery – complete embolization of the aneurysm.

approach. There is no data on the efficacy of both methods in young patients. A paper from 2013 published in *Stroke* by Päivi Koroknay-Pál et al. included 58 patients after treatment of intracranial aneurysms [7]. The authors underlined the need for a strict follow-up of such patients, even many years after the ictus. The rupture, development of a new aneurysm or recanalization of the treated one was observed. Due to an increased risk of intracranial aneurysm rupture, the authors pointed to the problem of young patients who started to smoke cigarettes in their adult life [7].

Conclusions

In conclusion, intracranial aneurysms are very rare in pediatric patients but they do occur. The lack of randomized trials resulted in no recommendations on which strategy of treatment should be used in such a situation. In experienced departments of interventional neuroradiology the endovascular treatment should be the treatment of choice. In cooperation with neurosurgeons, pediatricians and anesthesiologists it is necessary to design the follow-up schedule after successful treatment and the best method of radiological monitoring.

References:

1. Stiefel MF, Heuer GG, Basil AK: Endovascular and surgical treatment of ruptured cerebral aneurysms in pediatric patients. *Neurosurgery*, 2008; 63: 859–66
2. Molyneux A, Kerr R, Stratton I et al: International Subarachnoid Aneurysm Trial (ISAT) Collaborative Group: International Subarachnoid Aneurysm Trial (ISAT) of neurosurgical clipping versus endovascular coiling in 2143 patients with ruptured intracranial aneurysms: A randomised trial. *Lancet*, 2002; 360: 1267–74
3. Patel A, Richardson A: Ruptured intracranial aneurysms in the first two decades of life. A study of 58 patients. *J. Neurosurgery*, 1971; 35: 571–76
4. Huang J, McGirt MJ, Gailloud P, Tamargo R: Intracranial aneurysms in the pediatric population: case series and literature review. *Surgical Neurology*, 2005; 63: 424–32
5. Koroknay-Pál P, Laakso A, Letho H et al: Long – term excess mortality in pediatric patients with cerebral aneurysms. *Stroke*, 2012; 43: 2091–96
6. Meljnikov I, Vulekovic P, Cigic T et al: Treatment of pediatric patient with ruptured intracranial aneurysm – case report. *Medicinski Pregled*, 2012; 65: 331–36
7. Koroknay-Pál P, Niemelä M, Lehto H et al: *De novo* and recurrent aneurysms in pediatric patients with cerebral aneurysms. *Stroke*, 2013; 44: 1436–39
8. Meyer F, Sundt T, Fode N et al: Cerebral aneurysms in childhood and adolescence. *Neurosurgery*, 1989; 70: 4204–25
9. Rashimi S, Manish S, Wuppapalapati S, Usay L: Intracranial pediatric aneurysms: endovascular treatment and its outcome. *Clinical article. Neurosurgery Pediatrics*, 2012; 10: 2302–40