

# Transient Occlusion of Uterine Arteries in Laparoscopic Uterine Surgery

Yong-Soon Kwon, MD, Hyun Jin Roh, MD, Jun Woo Ahn, MD, Sang-Hun Lee, MD, Kyong Shil Im, MD

## ABSTRACT

**Background and Objectives:** This study was conducted to determine the feasibility and effectiveness of transient occlusion of the uterine arteries (TOUA) during laparoscopic surgery for benign uterine tumors, with preservation of fertility.

**Methods:** Patients with uterine myoma or adenomyoma underwent laparoscopic uterine surgery, with or without TOUA, performed by a single surgeon (Y.-S.K.). Surgical outcomes included operative time; occurrence of intraoperative injury of blood vessels, nerves, and pelvic organs; and intraoperative blood loss.

**Results:** Of the 168 surgical patients included in this study, 144 were enrolled consecutively during the study period, and 24 had undergone adenomectomy before the study period. A total of 104 women (70 with myoma; 34 with adenomyoma) seeking uterine preservation underwent laparoscopic surgery with TOUA for benign uterine tumors. Sixty-four women (40 with myoma; 24 with adenomyoma) underwent surgery without TOUA. The mean total surgical time of the TOUA groups was 74.85 minutes for uterine myoma and 84.09 minutes for uterine adenomyoma. The mean estimated blood loss during laparoscopic myomectomy and adenomyomectomy was less in the TOUA groups than in the non-TOUA groups (109 vs. 203.4 mL in myomectomy,  $P < .05$ ; 148.1 vs. 158.9 mL in adenomyomectomy;  $P < .05$ ). Time to perform TOUA was 13.9 minutes in laparoscopic myomectomy and 7.33 minutes in laparoscopic adenomyomectomy. The hospital stay of the TOUA groups was 3.32 days for uterine myoma

and 3.82 days for uterine adenomyoma. No intraoperative conversion to laparotomy was necessary, and no major complications occurred during any of the procedures.

**Conclusion:** Laparoscopic uterine surgery with TOUA could be a safe and effective surgical method for women with symptomatic benign uterine tumors who wish to preserve fertility.

**Key Words:** Benign uterine tumor, Laparoscopic uterine surgery, Uterus preservation, Transient occlusion of uterine arteries.

## INTRODUCTION

Benign uterine tumors including myoma and adenomyoma are common in women. Uterine leiomyomas are the most common of the pelvic tumors. Lifetime incidence of benign uterine tumors among white women is 40% by the age of 35 and >70% by the age of 50.<sup>1</sup>

Adenomyosis is a benign gynecologic condition characterized by ectopic endometrial gland invasion of the myometrium associated with hyperplasia of the adjacent smooth muscle.<sup>2</sup> The therapeutic strategy for these benign uterine tumors has recently shifted toward conservative surgical treatment, to preserve the uterus and fertility. This strategy has had widespread use in women who have had children but still want to preserve the uterus.

Conservative surgical therapeutic methods for removal of these tumors include laparotomic and laparoscopic approaches, with laparoscopy being the procedure more commonly used for most benign gynecologic tumors. However, some of the operative procedures, particularly those for laparoscopic myomectomy and adenomyomectomy, present challenges for surgeons, including complete excision of the tumor, firm suturing, reduction of dead space at the site of defects, and limitation of intraoperative blood loss. A few reports have introduced techniques for laparoscopic myomectomy or adenomyomectomy.<sup>3-6</sup> The most serious and frequent complication is pronounced and uncontrollable bleeding,<sup>7,8</sup> but few studies have reported techniques to reduce blood loss during

Department of Obstetrics and Gynecology, College of Medicine, University of Ulsan, Ulsan University Hospital, Ulsan, Republic of Korea (Drs. Kwon, Roh, Ahn, Lee).

Department of Anesthesiology and Pain Medicine, College of Medicine, Catholic University of Korea, Uijeongbu St Mary's Hospital, Uijeongbu-City, Republic of Korea (Dr. Im).

Address correspondence to: Kyong Shil Im, MD, Department of Anesthesiology and Pain Medicine, Uijeongbu St Mary's Hospital, College of Medicine, The Catholic University of Korea, 222 Banpo-daero, Seocho-gu, Seoul 137-701, Republic of Korea. Telephone: 82-31-820-3087, Fax: 82-31- 821-8449, E-mail: idonga@catholic.ac.kr

DOI: 10.4293/JSLS.2014.00189

© 2015 by JSLS, Journal of the Society of Laparoendoscopic Surgeons. Published by the Society of Laparoendoscopic Surgeons, Inc.

surgery.<sup>9–12</sup> In addition, the use of endoscopic vascular clips to limit blood loss during laparoscopic adenomyomectomy has not yet been thoroughly investigated.

Safe conditions, such as controlled bleeding and a clean operative field, must be guaranteed for laparoscopic operations, regardless of operative time, to ensure fewer adverse events during laparoscopic myomectomy and adenomyomectomy, particularly during the learning curve necessary for novice surgeons to gain proficiency.

In this study, we present data for the use of transient occlusion of uterine arteries (TOUA) during laparoscopic myomectomy and adenomyomectomy. We introduce a technique for TOUA and describe its effectiveness for the excision of benign uterine tumors with preservation of fertility.

## METHODS

From February 1, 2011 through March 31, 2013, 104 patients undergoing laparoscopic myomectomy (n = 70) and adenomyomectomy (n = 34) with TOUA were enrolled. Comparison of data from the non-TOUA groups—laparoscopic myomectomy without TOUA (n = 40) during the study period and laparoscopic adenomyomectomy without TOUA (n = 24) reported in a prior publication—and the TOUA groups<sup>5</sup> are presented herein. All operations were performed in consecutive patients by a single surgeon (Y.-S. K.). Inclusion criteria were a symptomatic intramural uterine myoma or adenomyoma, diagnosed by ultrasonography, that was refractory to conservative medical treatment and the desire of the patient for uterine preservation. Patients with submucosal or subserosal uterine myomas and diffuse adenomyosis were excluded. Conservative laparoscopic operations with TOUA were suggested to all patients who fulfilled the inclusion criteria. All patients provided informed consent before the operation. The operating time was considered the period from skin incision to skin closure; the size of the tumor was the maximum diameter of the tumor on ultrasonography; TOUA time was the period from initial serosal incision of the triangular area (defined by the round, ovarian, and infundibulopelvic [IP] ligaments and the psoas muscle) to the occlusion of the opposite uterine artery; and operative blood loss was estimated by subtracting the rinse volume from the blood volume that was collected in the suction apparatus. The Ulsan University Hospital Institutional Review Board approved the study.

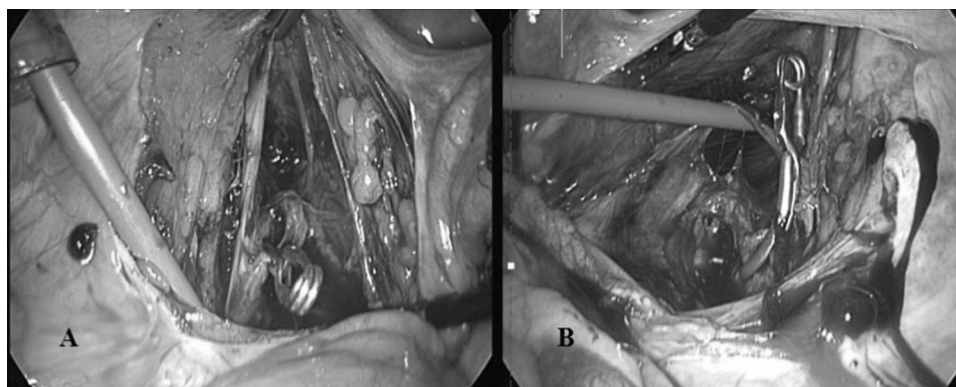
## Surgical Technique

Surgical excision of benign uterine tumors, with TOUA to limit blood loss, is performed as follows. General anesthesia is induced, and the patient is placed in a dorsal lithotomy position with endotracheal intubation. A uterine manipulator (Hangzhou Shikonghou Medical Equipment Co. Ltd., Beijing, China) is placed in the uterine cavity, to facilitate moving the uterus into the optimal position during excision and suturing. Intra-abdominal pressure is maintained at 13 mm Hg with carbon dioxide gas. Once pneumoperitoneum is achieved, video laparoscopy (Storz, Tuttlingen, Germany) is performed with a 10-mm trocar that has been introduced through the umbilicus. For the introduction of the surgical instruments, a 12-mm trocar for the endoscopic vascular clip is placed through an incision on the left side, a 5-mm trocar through an incision on the right side of the lower abdomen, and another 5-mm trocar for both clips through a median line incision just above the mons pubis. The peritoneum is incised with a cutting monopolar electrode through the triangular area (round, ovarian, and IP ligaments, and the psoas muscle) and along the IP ligament. The umbilical artery is isolated by blunt-tip suction, and the assistant moves the artery upward and in a lateral direction. It is possible to isolate the branching uterine artery along the umbilical artery using blunt-tip suction. The isolated uterine artery is occluded with an endoscopic vascular clip (Temporary Atraumatic Endo-Vessel-Clips; B. Braun Korea Co., Ltd., Seoul, Korea). Occlusion of the artery on the opposite side of the uterus is performed by the same method (**Figure 1**). About 3 minutes is spent expelling the arterial blood immediately after completion of both transient occlusions.

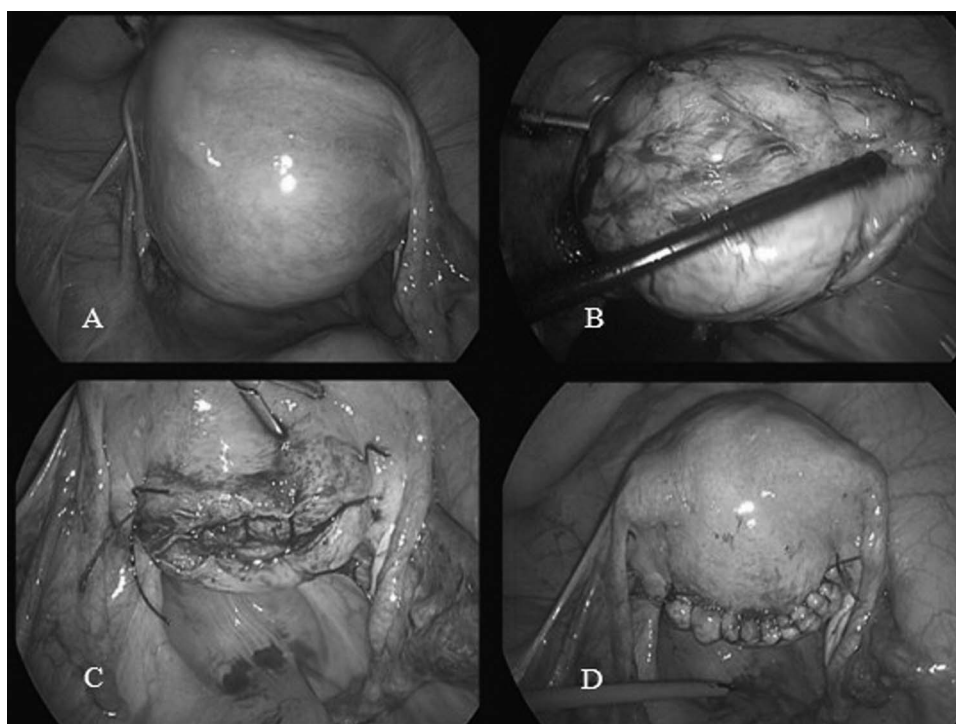
## Laparoscopic Myomectomy and Adenomyomectomy

In myomectomy, the myometrium covering the myoma is deeply incised with a monopolar cutting electrode until the underlying myoma is visualized. Enucleation of the myoma is completed with endoscopic scissors and a dissector.<sup>4</sup>

In adenomyomectomy, the uterine serosa covering the adenomyoma is deeply incised with a monopolar cutting electrode until the underlying endometrium is visualized. The adenomyoma is excised with endoscopic scissors. The adenomyoma is distinguished from normal myometrium by tactile and visual means for complete cytoreductive excision. The serosa covering the adenomyoma is maintained at a 5-mm depth, to facilitate the suturing of excisional defects,



**Figure 1.** Transient occlusion of uterine arteries (TOUA) with endoscopic vascular clips. A, Left side. B, Right side.



**Figure 2.** Serial steps of laparoscopic excision of a uterine myoma A, A 6.0-cm posterior uterine myoma compressing the endometrium. B, Excised myoma with transient occlusion of uterine arteries (TOUA). C, Excision bed of myoma showing limited bleeding. D, Sutured uterus after removal of both vascular clips from the uterine arteries.

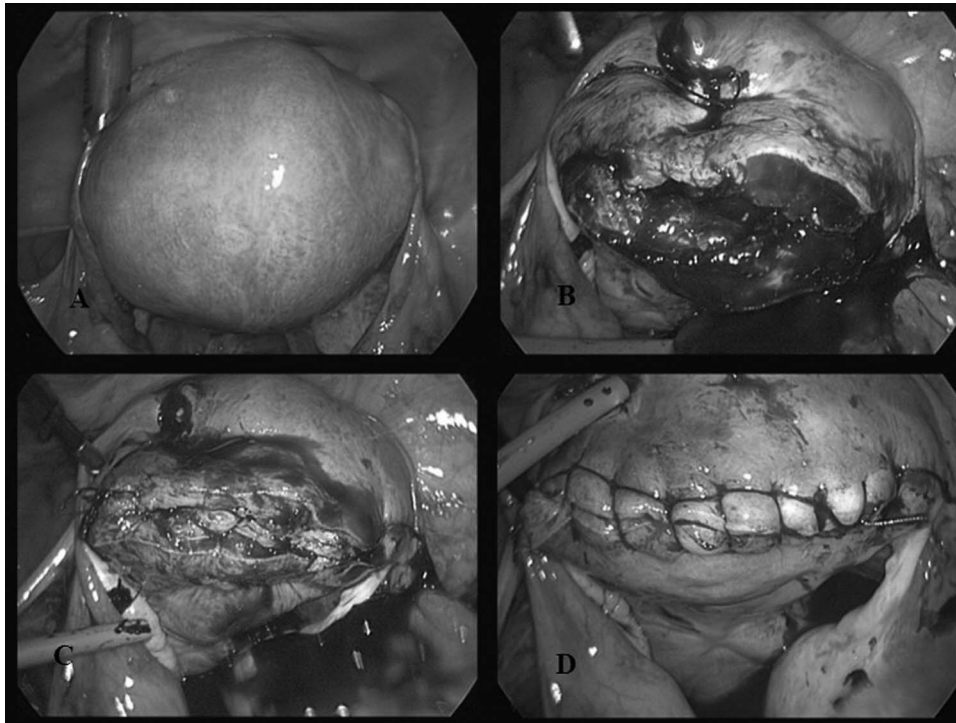
and the involved endometrium is spared as much as possible to preserve fertility.

Three layers of sutures are used in the defect area after excision of the myoma or adenomyoma: a wide, deep, single interrupted suture in the first layer; a continuous, nonlocking, running suture in the second layer; and a continuous interlocking suture in the third layer. The first assistant holds the stitch to maintain suture tension throughout the repair (**Figures 2** and **3**). Finally, both

endoscopic vascular clips are removed safely, and the excised tumor is removed with an electric morcellator (Ethicon, Inc., Somerville, NJ, USA). A drainage tube is inserted through the suprapubic incision.

### Statistical Analysis

The Statistical Package for the Social Sciences (SPSS, Inc., Chicago IL, USA) was used for statistical analysis. Data are expressed as the mean  $\pm$  SD or the absolute number (with



**Figure 3.** Three-layer suturing method for laparoscopic adenomyomectomy.

A, A 5.0 × 6.0-cm posterior uterine adenomyoma. B, First layer with a wide, deep, single interrupted suture. C, Second layer with a continuous, nonlocking, running suture. D, Third layer with a continuous interlocking suture.

percentage of total group). Differences were significant at  $P < .05$ .

## RESULTS

From February 1, 2011 through March 31, 2013, 144 patients with a diagnosis of symptomatic benign uterine tumors and a desire for uterine preservation were enrolled. In addition, 24 patients with symptomatic adenomyoma who had undergone laparoscopic adenomyomectomy without TOUA before this study<sup>5</sup> were enrolled. Of the 168 patients, 110 underwent laparoscopic myomectomy with ( $n = 70$ ) or without ( $n = 40$ ) TOUA, and 58 underwent laparoscopic adenomyomectomy with ( $n = 34$ ) or without ( $n = 24$ ) TOUA. All procedures were performed by a single surgeon (Y.-S.K.) using the aforementioned procedures. The mean age in the laparoscopic myomectomy group with TOUA was  $42.15 \pm 5.24$  years and that in the non-TOUA group was  $41.96 \pm 6.56$  years. The mean ages in the laparoscopic adenomyomectomy groups with or without TOUA were  $43.79 \pm 4.94$  and  $42.89 \pm 3.98$  years, respectively. The mean maximum diameters of the uterine myomas in the TOUA and non-TOUA groups were  $5.87 \pm 1.68$  and  $6.19 \pm 1.93$  cm,

respectively. The mean maximum diameters of the uterine adenomyomas in the TOUA and non-TOUA groups were  $5.29 \pm 1.82$  and  $3.9 \pm 1.48$  cm, respectively. The operative outcomes compared between the 2 groups included operation time, estimated blood loss (EBL), and number of conversions to laparotomy (Table 1). The mean operative time was longer in the TOUA groups than in the groups without TOUA. The mean time needed to perform TOUA was significantly longer in the myoma ( $13.9 \pm 5.61$  min) group than in the adenomyoma ( $7.33 \pm 4.12$  min) group ( $P < .05$ ).

The mean EBL during laparoscopic myomectomy was significantly less in the TOUA group than that in the non-TOUA group (mean EBL:  $109 \pm 73.28$  mL in the TOUA group;  $203.4 \pm 152.39$  mL in the non-TOUA group;  $P < .05$ ).

Although the mean maximum diameters of the adenomyomas were significantly different between the 2 laparoscopic adenomyomectomy groups ( $5.29 \pm 1.82$  cm with TOUA;  $3.9 \pm 1.48$  cm without TOUA), EBL in the TOUA group was less than that in the non-TOUA group (mean



**Table 1.**  
Comparison Between the TOUA and non-TOUA Groups for Laparoscopic Myomectomy and Adenomyomectomy

	Uterine myoma		Uterine adenomyoma	
	TOUA (n = 70)	Without TOUA (n = 40)	TOUA (n = 34)	Without TOUA <sup>5</sup> (n = 24)
Age (y)	42.15 ± 5.24	41.96 ± 6.56	43.79 ± 4.94	42.89 ± 3.98
Max. diameter (cm)	5.87 ± 1.68	6.19 ± 1.93	5.29 ± 1.82 <sup>a</sup>	3.9 ± 1.48
Operation time (min)	74.85 ± 28.04 <sup>a</sup>	58.13 ± 21.02	84.09 ± 31.48 <sup>a</sup>	60.5 ± 29.56
TOUA time (min)	13.9 ± 5.61 <sup>b</sup>	—	7.33 ± 4.12	—
Vascular injury	0	0	0	0
EBL (mL)	109 ± 73.28 <sup>a</sup>	203.4 ± 152.39	148.1 ± 93.99 <sup>a</sup>	158.9 ± 103.56
Conversion to laparotomy	0	0	0	0
Hospital stay (d)	3.32 ± 0.81	3.09 ± 0.79	3.82 ± 1.24	3.4 ± 0.97

Data are expressed as the mean ± SD, or number. Max. diameter: maximum diameter of the uterine myoma or uterine adenomyoma. TOUA time: from the time of incision of the serosa of the right adnexa to the time of occlusion of the left uterine artery. Vascular injury: any injury during TOUA to such vascular structures as the adnexal and pelvic side retroperitoneal vessels.

Abbreviations: EBL, estimated blood loss; TOUA, transient occlusion of uterine arteries.

<sup>a</sup>*P* < 0.05. Comparative data were analyzed between groups with the same tumor type, with or without TOUA.

<sup>b</sup>*P* < 0.05. Comparative data were analyzed between the TOUA group with uterine myoma and the TOUA group with uterine adenomyoma.

EBL: 148.1 ± 93.99 mL in the TOUA group; 158.9 ± 103.56 mL in the non-TOUA group; *P* < .05).

No conversion to laparotomy or vascular injury occurred in either of the TOUA groups. None of the patients had fever during the hospital stay.

## DISCUSSION

Less bleeding during laparoscopic operations can make the surgery easier and help keep the patient stable. Therefore, the development of methods to lessen bleeding in the operative field is important. Several reports have described different techniques for limiting intraoperative blood loss during laparotomic myomectomy or adenomyomectomy,<sup>12–15</sup> 2 for laparoscopic myomectomy,<sup>11,16</sup> but none for laparoscopic adenomyomectomy. At our center, we have a great deal of experience with laparoscopic myomectomy and adenomyomectomy, with or without TOUA. In our department, conservative surgical therapy is preferred rather than hysterectomy for benign uterine tumors, and laparoscopy is the main approach, rather than laparotomy.

Additional methods of limiting blood loss are available. An injection of vasopressin<sup>17</sup> is widely used to reduce intraoperative blood loss,<sup>18</sup> but it has some disadvantages, including uncontrolled duration of effectiveness, delayed

bleeding due to exhaustion of effectiveness during or after surgery, and systemic side effects due to incorrect injection into vessels. Another method is ligation of uterine arteries, in which both arteries are occluded permanently. Unlike these methods, TOUA with endoscopic vascular clips controls the duration of action, but has no systemic side effects, and its effect is transient, returning blood flow to the uterine arteries when the clips are unlocked. Injuries to the nerves, vessels, and ureters are possible during TOUA procedures that use endoscopic vascular clips; however, such injuries can be avoided by an experienced surgeon using blunt dissection to isolate the uterine arteries. No injuries to nerves, vessels, or the ureters occurred in the operations involving TOUA in this study.

TOUA with endoscopic vascular clips can be a challenge in procedures in which clips must be applied to both uterine arteries. First, it is difficult to approach both uterine arteries in the presence of a large myoma because of the narrow pelvic space, in which an 8-cm-diameter tumor is the upper limit. Second, when the operator stands to the left of the patient with a large myoma, the uterus can be an obstacle to applying the clip to the uterine artery on the opposite (right) side. There could be some differences in time required to perform TOUA and in the feasibility of its application on both sides. The time is dependent on the

experience of the surgeon, and feasibility can be determined in the surgical planning.

Vercellino et al.<sup>11</sup> reported that resistance and pulsatility indices remained unchanged postoperatively in their study groups. They found no signs of negative effects linked to the use of clips, as both groups showed no difference in the pre- and postoperative Doppler values of the uterine vessels. In the present study, the postoperative follow-up of all cases showed no signs of insufficient uterine blood supply. Therefore, a routine examination to determine uterine arterial flow may not be needed because of additional collateral blood flow to the uterus.

Our data show a difference in performance time for TOUA between laparoscopic myomectomy and laparoscopic adenomyomectomy. However, there was a definite difference in tumor size between uterine myomas and adenomyomas (myomas have a larger diameter) and a large benign tumor causing the uterus to be enlarged can be an obstacle during TOUA procedures.

In the present cases of laparoscopic adenomyomectomy, we did not have control data for procedures without TOUA during the study period. Because it involves a much more difficult technique and heavy bleeding in the operative field, we had few cases. Thus, we used data for laparoscopic adenomyomectomy without TOUA taken from a previously published report by the same surgeon. In the comparative analysis, significantly different mean size of uterine adenomyoma was observed between the 2 groups ( $5.29 \pm 1.82$  cm in the TOUA group;  $3.9 \pm 1.48$  cm in the non-TOUA group;  $P < .05$ ). Despite the larger size of the adenomyomas in the TOUA group, laparoscopic adenomyomectomy with TOUA had significantly less EBL ( $148.1 \pm 93.99$  mL with TOUA;  $158.9 \pm 103.56$  mL without TOUA;  $P < .05$ ). We therefore suggest that TOUA can help ensure patient safety during laparoscopic adenomyomectomy by limiting blood loss and can enable removal of large uterine adenomyomas.

Operative time is dependent on the surgeon's skill. A definite difference in operative time can be observed between novice and expert surgeons, and prolonged laparoscopic procedures can cause serious intra- and postoperative complications. Thus, in our study, a single surgeon performed all operations. For surgeons inexperienced in laparoscopic myomectomy or adenomyomectomy, TOUA can provide stable conditions with limited blood loss during the operation, regardless of operative time.

We suggest that TOUA is much more helpful during laparoscopic adenomyomectomy than during laparoscopic

myomectomy, because the basic principle in myomectomy is pseudocapsulectomy, which is a procedure with less bleeding than occurs with an initial incision of the myometrium; therefore, myomectomy may involve less blood loss than adenomyomectomy. In adenomyomectomy, the tumor is not surrounded by a pseudocapsule and is obscure from normal surrounding myometrium, which could cause heavy bleeding during the operation. Therefore, TOUA may be more helpful during adenomyomectomy. For the performance of safe TOUA in benign gynecologic surgeries, an adequate learning curve should be required, and careful attention should be given during the operation to the risk of injury to the pelvic organs.

## CONCLUSIONS

No intraoperative or postoperative complications or injuries to nerves, vessels, or the ureters occurred. With the increasing trend toward conservative surgery for benign myomas and adenomyomas, we favor laparoscopy rather than laparotomy. TOUA with endoscopic vascular clips could be a useful technique for both experts and novices in laparoscopic myomectomy or adenomyomectomy.

## References:

1. Downes E, Sikirica V, Gilabert-Estelles J, et al. The burden of fibroids in five European countries. *Eur J Obstet Gynecol Reprod Biol.* 2010;152:96–102.
2. Ferenczy A. Pathophysiology of adenomyosis. *Hum Reprod Update.* 1998;4:312–322.
3. Hackethal A, Brüggmann D, Leis A, Langde S, Stillger R, Müntstedt K. Surgical management of uterine fibroids in Hesse, Germany, between 1998 and 2004. *Fertil Steril.* 2009;91:862–868.
4. Koo YJ, Song HS, Im KS, Jung HJ, Kwon YS. Multimedia article. Highly effective method for myoma excision and suturing in laparoscopic myomectomy. *Surg Endosc.* 2011;25:2362.
5. Im KS, Song HS, Kwon YS. Laparoscopic adenomectomy: A highly effective method of adenomyoma excision and Suturing (video). *J Laparoendosc Adv Surg Tech, Part B: Videosc.* 2011;21.
6. Sun AJ, Luo M, Wang W, Chen R, Lang JH. Characteristics and efficacy of modified adenomyomectomy in the treatment of uterine adenomyoma. *Chin Med J (Engl).* 2011;124:1322–1326.
7. Fletcher H, Frederick J, Hardie M, Simeon D. A randomized comparison of vasopressin and tourniquet as hemostatic agents during myomectomy. *Obstet Gynecol.* 1996;87:1014–1018.

8. Walid MS, Heaton RL. Laparoscopic myomectomy: an intent-to-treat study. *Arch Gynecol Obstet.* 2010;281:645–649.
9. Koehler C, Hasenbein K, Klemm P, Tozzi R, Schneider A. Laparoscopic-assisted vaginal hysterectomy with lateral transection of the uterine vessels. *Surg Endosc.* 2003;17:485–490.
10. Köhler C, Hasenbein K, Klemm P, Tozzi R, Michels W, Schneider A. Laparoscopic coagulation of the uterine blood supply in laparoscopic-assisted vaginal hysterectomy is associated with less blood loss. *Eur J Gynaecol Oncol.* 2004;25:453–456.
11. Vercellino G, Erdemoglu E, Joe A, et al. Laparoscopic temporary clipping of uterine artery during laparoscopic myomectomy. *Arch Gynecol Obstet.* 2012;286:1181–1186.
12. Bonney V. The technique and results of myomectomy. *Lancet.* 1931;220:171–177.
13. Lock FR. Multiple myomectomy. *Am J Obstet Gynecol.* 1969;104:642–650.
14. Liu WM. Laparoscopic bipolar coagulation of uterine vessels to treat symptomatic leiomyomas. *J Am Assoc Gynecol Laparosc.* 2000;7:125–129.
15. Osada H, Silber S, Kakinuma T, Nagaishi M, Kato K, Kato O. Surgical procedure to conserve the uterus for future pregnancy in patients suffering from massive adenomyosis. *Reprod Biomed Online.* 2011;22:94–99.
16. Alborzi S, Ghannadan E, Alborzi S, Alborzi M. A comparison of combined laparoscopic uterine artery ligation and myomectomy versus laparoscopic myomectomy in treatment of symptomatic myoma. *Fertil Steril.* 2009;92:742–747.
17. Kongnyuy EJ, van den Broek N, Wiysonge CS. A systematic review of randomized controlled trials to reduce hemorrhage during myomectomy for uterine fibroids. *Int J Gynaecol Obstet.* 2008;100(1):4–9.
18. Park KH, Kim JY, Shin JS, Kwon JY, Koo JS, Jeong KA, Cho NH, Bai SW, Lee BS. Treatment outcomes of uterine artery embolization and laparoscopic uterine artery ligation for uterine myoma. *Yonsei Med J.* 2003;44(4):694–702.