

## **Avian poxvirus infection in Polish great tits (*Parus major*)**

Wojciech Kozdruń<sup>1</sup>, Natalia Styś-Fijoł<sup>1</sup>, Hanna Czekaj<sup>1</sup>,  
Piotr Indykiewicz<sup>2</sup>, Rafał Sandecki<sup>3</sup>, Jowita Samanta Niczyporuk<sup>1</sup>

<sup>1</sup>Department of Poultry Diseases  
National Veterinary Research Institute, 24-100 Pulawy, Poland  
<sup>2</sup>Faculty of Animal Breeding and Biology  
University of Sciences and Technology, 85-039 Bydgoszcz, Poland  
<sup>3</sup>Veterinary Practice, 88-100 Inowrocław, Poland  
wkozdrun@piwet.pulawy.pl

Received: July 10, 2018

Accepted: November 9, 2018

### **Abstract**

**Introduction:** Avian poxvirus infections are widespread in the domestic poultry population but are also reported in wild birds. In poultry, these infections cause significant economic losses, while wild birds may be a reservoir for poxvirus which affects breeding poultry. However, wild birds may also exhibit characteristic anatomopathological changes. This study concerns the infection of wild-living great tits (*Parus major*) with the avian poxvirus in Poland. **Material and Methods:** Samples of internal organs and skin collected from great tits were homogenised and total cellular DNA was isolated. In PCR, the primers complementary to gene encoding the core protein 4b of the HP44 strain of fowl poxvirus (FPV) were used. **Results:** After electrophoresis in 2% agarose gel, the PCR product of 578 bp characteristic for FPV was obtained in DNA samples isolated from skin lesions and the heart. The analysis of the nucleotide sequence of the virus strain showed 99% similarity to many poxviruses previously isolated from great tits and other free birds at various sites in the world. **Conclusions:** This paper is the first clinically documented evidence obtained in laboratory conditions of avian poxvirus cases in great tits in Poland.

**Keywords:** great tits, avian poxvirus, PCR, phylogenetic analysis.

### **Introduction**

Avian pox is caused by a virus belonging to the genus *Avipoxvirus*, within the subfamily *Chordopoxviridae*. This virus is very common in the breeding poultry population (2, 12), but has also been reported in 278 species of wild birds from 70 families and 20 orders (3, 6, 10, 15), both in North America (4) and in Europe (5, 8, 11, 14).

The first cases of viral infection in Europe were recorded in the early 1970s in wild birds in Norway (15). However, the virus was found in Central European countries in 2005. In the years 2005–2009, infections with the virus were recorded in great tits in Austria, Hungary, the Czech Republic, Slovakia, Germany, and Hungary, as well as beyond the continental mainland, *i.e.* in the UK (9, 13).

Although symptoms of a probable pox case in a great tit were reported in 2009 in Poland (data not published), our report is the first evidence, documented clinically and provided in laboratory conditions, of avian pox cases in great tits (*Parus major*) in Poland.

### **Material and Methods**

**Bird samples.** The study material was composed of the bodies of 10 great tits, obtained in the winter (December 2015–February 2016) in Inowrocław and Grodztwo (near Kruszwica), North-Central Poland. Dead birds were provided for diagnostic tests to the Department of Poultry Diseases, National Veterinary Research Institute, Puławy, Poland.

**Sample preparation.** During the necropsy, samples of skin lesions, heart, trachea, lung, stomach,


and intestines were taken for laboratory examination. These samples were homogenised and then total cellular DNA was isolated by commercial kit (MiniKit DNA, Qiagen, Germany).

**PCR.** Primers complementary to the gene encoding the core protein 4b of the HP44 strain previously described in the literature were used to detect the genetic material of avian poxvirus (7). The negative control was the total cellular DNA isolated from non-infected chicken embryo fibroblast (CEF) culture. As a positive control, DNA of the modified DCEP25 strain of avian poxvirus isolated from Diftosec CT (Merial, France) was used. The PCR was carried out in a gradient thermocycler (Biometra, Germany) in a 25 µl volume containing: 2.5 µl of PCR buffer (Eurx, Poland), 1 µl of 25 mM magnesium chloride, 1 µl of dNTP mixture (0.2 mM), 0.5 µl of each of the primers, 0.5 µl of DNA polymerase (2.5 U), 2 µl of DNA, and 17 µl of deionised water. Amplification conditions were as follows: 95°C for 5 min, 35 cycles at 94°C for 1 min, 61°C for 1 min, and 72°C for 1 min, and final extension at 72°C for 10 min. PCR products were separated in 2% agarose gel with GelRed (Biotium, USA) for 50 min at 120 V. After electrophoretic separation, the amplification product was compared to the mass standard (Thermo-Scientific, USA). The results were visualised using a UV transilluminator and photographed.

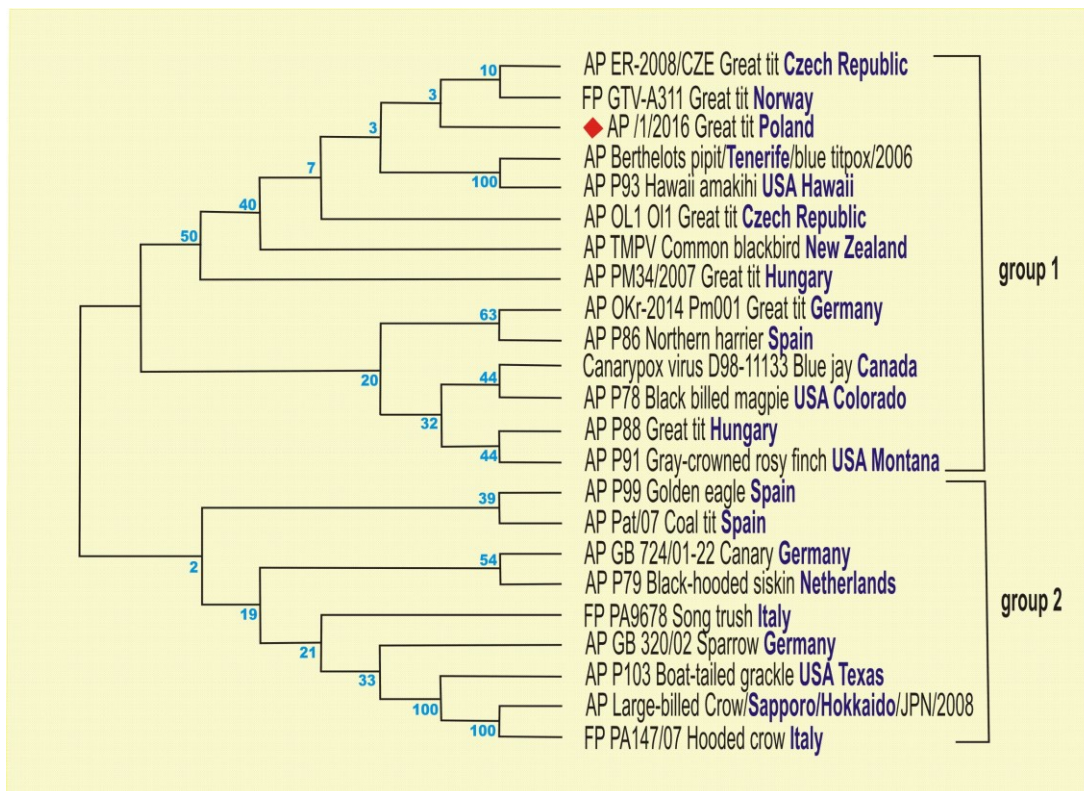
**Sequencing and phylogenetic analysis.** The amplicon obtained for the DNA sample isolated from skin lesions was sequenced twice by Genomed, (Poland) using an FLX/Titanium sequencer (Roche, USA). The forward and reverse starter sequences were matched and manually edited in the freely distributed computer programme Bioedit 7.0.9.0 (Tom Hall, USA). The resulting consensus sequence was compared with other sequences available in the GenBank NCBI database, using BLAST software. The phylogenetic tree was constructed using the MEGA programme in version 6 (Koichiro Tamura, Joel Dudley, Masatoshi Nei, and Sudhir Kumar, USA).

## Results

During necropsy, brown lesions were found located in the scalp area around the eyes, bow cavity, and neck, and deeply rooted in the underlying structures (Fig.1). The lesions spotted in the corners of the beak as well as those in the mucous membrane of the beak cavity presented themselves as greyish yellow diphtheroid-like deposits strongly integrated into the underlying structures. Removal of the diphtheroid-like membranes from the surface of the mucous membrane revealed erosion and ulceration. No pathological lesions were found in internal organs.



**Fig. 1.** Pox-like lesions on the scalp area of the beak, bow cavity, and neck of great tits (phot. P. Indykiewicz)



**Fig. 2.** Phylogenetic relationships between nucleotide sequences of the 4b gene of APV detected in great tits sampled in Poland (red square) and other APV isolates from the GenBank database. The evolutionary history was inferred using the neighbour-joining method. The percentage of replicate trees in which the associated taxa clustered together in the bootstrap test (2,000 replicates) are shown next to the branches

The PCR product of 578 bp characteristic for avian poxvirus was obtained in a DNA sample isolated from skin lesions and the heart.

The sequence of Polish strain AP/1/2016 was placed in the GenBank database under the accession number KY569404. The analysis of the nucleotide sequence showed 99% similarity to many poxviruses previously isolated from great tits and other free birds in the world. The nucleotide sequences of isolates used to construct the phylogenetic tree fell within two major genetic groups. The Polish isolate AP/2016 belongs to group 1 together with six more European strains isolated from tits. Comparison of the nucleotide sequence of the region encoding core protein 4b revealed that it was most akin to the Czech strain ER-2009 and the Norwegian strain GTV-A311 isolated from tits (Fig. 2).

## Discussion

Infection with avian poxvirus has been confirmed at least in 278 species of wild birds from 70 families and 20 orders (3, 6, 10, 15), both in North America (4) and in Europe (5, 11, 14).

Although symptoms of a probable case of pox in a great tit were reported in 2009 in Poland (Krzysztof

Ostrowski, in information conveyed verbally and photo), our report is the first laboratory-gleaned evidence of avian pox cases in great tits in Poland documented clinically.

A total of 1,819 great tits were investigated in 2007 in the Pilis Mountains in Hungary (11). In some birds, nodular proliferative lesions on the head and eyes were observed. Avian poxvirus infection was confirmed by histopathology, electron microscopy (EM), and PCR. The phylogenetic analysis revealed 100% identity between Hungarian and Norwegian isolates of avian poxvirus. These results were practically convergent with the results of our research.

Six avian poxvirus isolates obtained from various bird species in Egypt were investigated (1). Viral strains were propagated on the chorioallantoic membrane of embryonated chicken eggs and the presence of avian poxvirus genetic material was subsequently confirmed in PCR. Phylogenetic studies have confirmed that avian poxvirus circulates constantly in the bird population of Egypt.

All of the results presented above are indicative of the persistent occurrence of avian poxvirus in the environment. The confirmed case of avian poxvirus infection in great tits in our country suggests the risk of virus transmission to other species of free-living birds, granted its very high resistance to unfavourable

environmental conditions. In a contaminated environment, dried scabs containing poxvirus particles may be a source of infection for other susceptible species of birds.

**Conflict of Interest Statement:** The authors declare that there is no conflict of interests regarding the publication of this article.

**Financial Disclosure Statement:** This work was supported by the National Veterinary Research Institute in Pulawy.

**Animal Rights Statement:** None required.

## References

1. Abdallah F.M., Hassanin O.: Detection and molecular characterization of avipoxviruses isolated from different avian species in Egypt. *Virus Genes* 2013, 46, 63–70.
2. Bithi R., Siddhartha N.J., Idranil S., Pradup K.D., Arkendu H., Sudip N.: Molecular characterization of fowl pox virus isolated from backyard. *Adv Anim Vet Sci* 2013, 1, 54–58.
3. Bolte A.L., Meurer J., Kaleta E.F.: Avian host spectrum of avipoxviruses. *Avian Pathol* 1999, 28, 415–432.
4. Goodpasture E.W., Anderson K.: Isolation of wild avian pox virus including both cytoplasmic and nuclear inclusions. *Am J Pathol* 1962, 40, 437–453.
5. Gruber A., Grabensteiner E., Kolodziejek J., Nowotny N., Loupal G.: Poxvirus infection in a great tit (*Parus major*). *Avian Dis* 2007, 51, 623–625.
6. Hansen W.R.: Avian pox. In: *Field Manual of Wildlife Diseases. General Field Procedures and Diseases of Birds*. Biological Resources Division Information and Technology Report 1999–2001. Edited by Friend M., Franson J.Ch., U.S. Geological Survey, Washington, D.C., 1999, pp. 163–170.
7. Huw Lee L., Hwa Lee K.: Application of the polymerase chain reaction for the diagnosis of fowl poxvirus infection. *J Virol Methods* 1997, 63, 113–119.
8. Lawson B., Lachish S., Colvile K.M., Durrant C., Peck K.M., Toms M.P., Sheldon B.C., Cunningham A.A.: Emergence of a novel avian pox disease in British tit species. *PLoS One*, doi: 10.1371/journal.pone.0040176.
9. Literak J., Kulich P., Robesova B., Adamik P., Roubalova E.: Avipoxvirus in great tits (*Parus major*). *Eur J Wild Res* 2010, 56, 529–534.
10. McFerran J.B., McNulty M.S.: Poxviridae. In: *Virus infections of Birds*. Edited by McFerran J.B., McNulty M.S., Horzinek M.C., Elsevier Scientific Publishing, Amsterdam, 1993, pp. 1–15.
11. Palade E.A., Biro N., Dobos-Kovacs M., Demeter Z., Mandoki M., Rusvai M.: Poxvirus infection in Hungarian Great tits (*Parus major*): case report. *Acta Vet Hung* 2008, 56, 539–546.
12. Simon C., Morten T.: Avipoxviruses: infection biology and their use as vaccine vectors. *Virol J* 2011, doi: 10.1186/1743-422X-8-49.
13. Stastny K., Bejček V., Hudec K.: The atlas of breeding birds in the Czech Republic. 2001–2003, Aventinum, Prague, 2006, p. 463.
14. Tripathy D.N., Schnitzlein W.M., Morris P.J., Janssen D.L., Zuba J.K., Massey G., Atkinson C.T.: Characterization of poxvirus from forest birds in Hawaii. *J Wildlife Dis* 2000, 36, 225–230.
15. Van Riper C., Forrester D.J.: Avian pox. In: *Infectious Diseases of Wild Birds*. Edited by Thomas N.J., Hunter D.B., Atkinson C.T., Wiley-Blackwell Publishing, Oxford, UK, 2007, pp. 131–176.