

Available online at www.sciencedirect.com

ScienceDirect

journal homepage: www.elsevier.com/locate/radcr

Case Report

Primary pulmonary artery sarcoma in the pediatric patient: Review of literature and a case report

Yong Yean Kim, MD, PhD^{a,*}, Tung Thanh Wynn, MD^b, John David Reith, MD^c,
William B. Slayton, MD^b, Joanne Lagmay, MD^b, John Fort, MD^b,
Dhanashree Abhijit Rajderkar, MD^d

^a National Cancer Institute, Pediatric Oncology Branch, 37 Convent Dr, Bethesda, MD 20892, USA

^b University of Florida, Department of Pediatric Hematology/Oncology, Gainesville, FL 32610, USA

^c Cleveland Clinic, Department of Pathology, Cleveland, OH 44195, USA

^d University of Florida, Department of Pediatric Radiology, Gainesville, FL 32610, USA

ARTICLE INFO

Article history:

Received 27 March 2020

Revised 7 May 2020

Accepted 8 May 2020

Key Words:

Primary pulmonary artery sarcoma

Pediatric

Pulmonary Embolism

ABSTRACT

Primary pulmonary artery sarcoma (PAS) is extremely rare in children. Nevertheless, distinguishing primary PAS from pulmonary embolism is critical to a child's survival. Primary PAS is commonly misdiagnosed as a pulmonary embolism due to similar presenting symptoms and radiographic findings. However, compared to adults, pulmonary embolism is rare in children, especially in patients who do not have predisposing factors or hypercoagulable state. We present a child with primary PAS which mimicked pulmonary embolism on presentation but eventually was resected and is doing well 5 years after resection. In the absence of predisposing factors or hypercoagulable state, solid tumors such as primary PAS should be considered when assessing a pediatric patient with presumed pulmonary embolism.

Published by Elsevier Inc. on behalf of University of Washington.

This is an open access article under the CC BY-NC-ND license.

(<http://creativecommons.org/licenses/by-nc-nd/4.0/>)

Introduction

Primary pulmonary artery sarcoma (PAS) is among one of the rare malignancies with only a few hundred cases having been reported [1,2]. PAS is commonly diagnosed as pulmonary embolism (PE) given similar constellation of symptoms including shortness of breath, chest pain, and cough. Additionally, computed tomography angiography (CTA) findings are similar to that of PE [1,3]. Unfortunately, diagnosis is most often made at the time of post mortem assessment, although diagnosis by

biopsy or surgical resection has been made in stable patients. Prognosis is poor and in a review of 93 cases in 1990, median survival was only 1.5 months from the date of diagnosis [4]. However, a more recent study in 2015 showed improved median survival of 17 months [5]. The treatment of choice is total surgical resection and is key to prolonged survival. Therefore, differentiating PAS from PE is crucial for optimal care of these patients. In the pediatric population, incidence of PE is significantly lower (0.14-0.9 in 100,000) compared to adults

* Corresponding author.

E-mail address: yong.kim@nih.gov (Y.Y. Kim).

<https://doi.org/10.1016/j.radcr.2020.05.016>

1930-0433/Published by Elsevier Inc. on behalf of University of Washington. This is an open access article under the CC BY-NC-ND license. (<http://creativecommons.org/licenses/by-nc-nd/4.0/>)

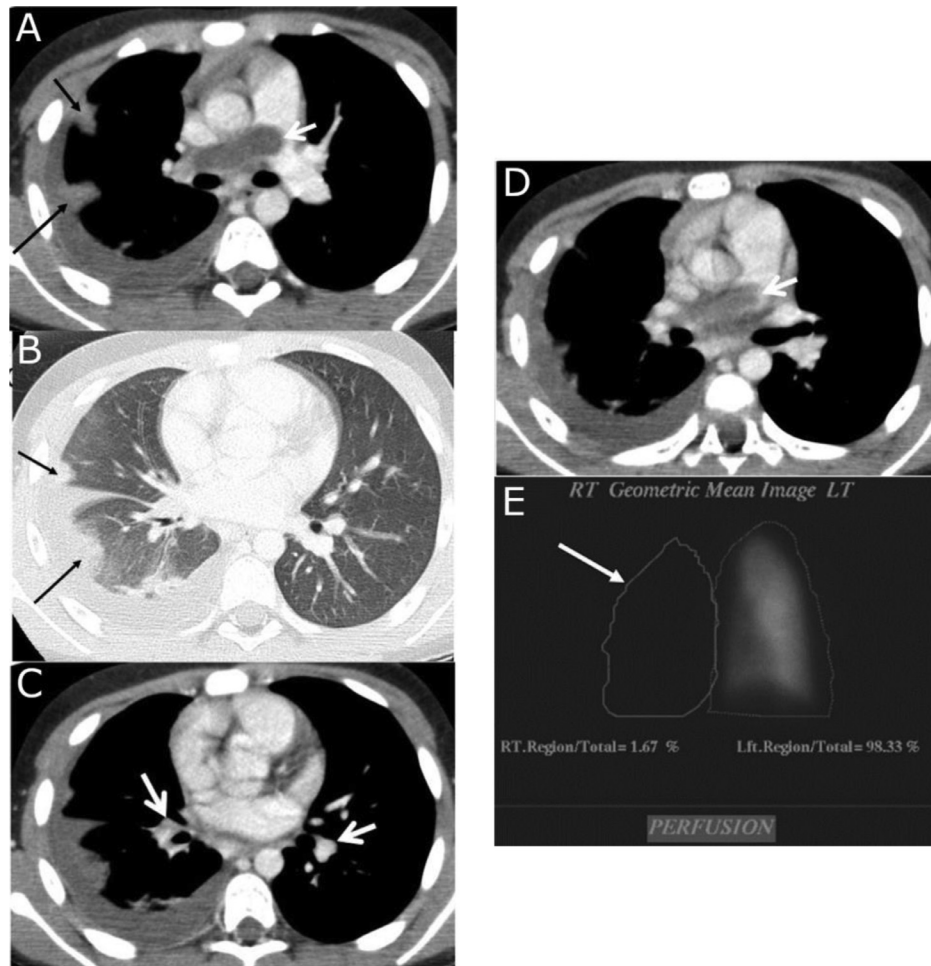


Fig. 1 – Preoperative image findings. (A) CTA with soft tissue window showing a large non-enhancing filling defect in the right pulmonary artery (white open arrow). Peripheral wedge shaped pulmonary opacities suggesting developing infarcts (black solid arrows). There is associated reactive pleural effusion. **(B)** CTA with lung window showing wedge shaped pulmonary infarcts. **(C)** CTA with soft tissue window showing non-enhancing filling defect in the interlobar pulmonary artery on the right (white arrow on the right) and no filling defects on the left (white arrow on the left). **(D)** CTA with soft tissue window showing non-enhancing filling defect in the right pulmonary artery leading to mild expansion of the RPA with mild extension into the main pulmonary artery. There is normal opacification of the rest of the main pulmonary artery. **(E)** 99mTc-MAA scan showing lack of perfusion to the right lung.

(302 in 100,000) and almost always associated with predisposing condition or an underlying hypercoagulable state [6,7]. Hence, an expanded differential with additional imaging such as MRI or PET should be considered in a stable pediatric patient presenting with symptoms of PE. Here, we present a rare case of PAS in a pediatric patient and discuss the imaging options.

Case report

A 10-year-old female with history of asthma presented with a 5-month history of cough, 2 weeks of fever, and a 7 kg weight loss over the past month. Chest x-ray showed a right middle lobe consolidation with pleural effusion. She was diagnosed

with pneumonia and treated with cefdinir and sulfamethoxazole/trimethoprim.

Follow up chest x-ray showed persistent pleural effusion and clinically, her symptoms continued. Patient subsequently underwent a CT angiogram which was interpreted as a large thromboembolism in the right main pulmonary artery (Fig. 1A) with evidence of extension into the right interlobar artery (Fig. 1C) resulting in multiple parenchymal infarcts (Fig. 1A-B). Echocardiogram showed the same mass in the right pulmonary artery with complete obstruction of flow. Baseline technetium 99m macro aggregated albumin (^{99m}Tc -MAA) perfusion scan was performed to quantify the perfusion of the lungs which showed essentially no perfusion to the right lung suggestive of complete obstruction of the right pulmonary artery (Fig. 1E). Doppler ultrasound of the lower extremities was negative. Her D-dimer was elevated at 12.6 ug/ml. She had a negative family history for underlying hypercoagulable state.

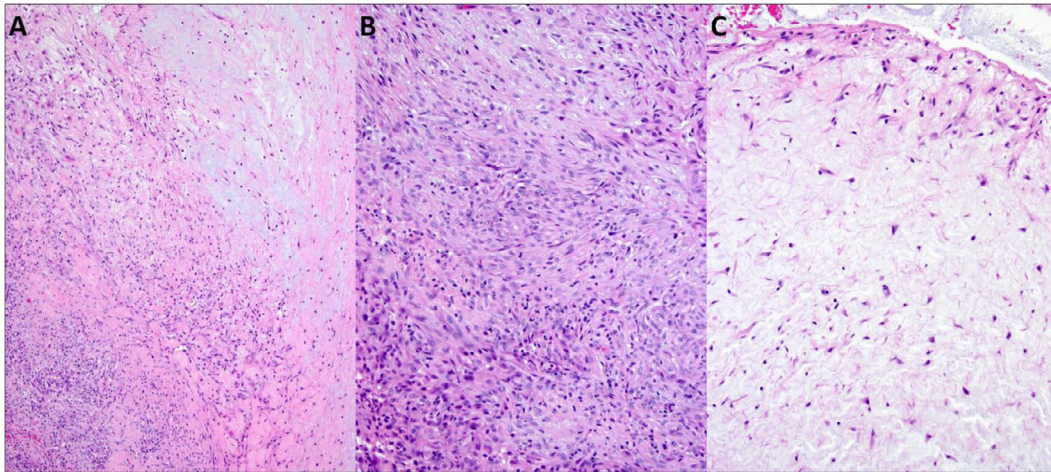


Fig. 2 – Hematoxylin and eosin stain of tumor. (A) The tumor was composed of alternating myxoid and cellular foci (magnification x100). (B) The more cellular zones of the tumor were composed of plump spindled cells deposited in a fibrous stroma containing chronic inflammation (magnification x200). (C) The myxoid zones of the tumor were extensively necrotic, but tumor cells located at the intraluminal aspect were viable and displayed moderate pleomorphism (magnification x200).

Additional laboratory studies for hypercoagulability work up were negative, including assays for Factor VIII, Protein S, Protein C, Factor V Leiden, Prothrombin Mutation, Cardiolipin Ab, Homocysteine, β 2-Glycoprotein-1 Ab.

She was admitted and started on heparin drip to treat the presumed thrombus. She did not have tachypnea, chest pain, or hypoxia, and hence was discharged home on therapeutic treatment dose of low molecular weight heparin. However, the following day, she was readmitted due to development of shortness of breath and fever. In review of the previous CT angiogram, the appearance of the PE was atypical. The filling defect was predominantly located in the right main pulmonary artery, with minimal central extension into the main pulmonary artery and without extension into the left main pulmonary artery (Fig. 1A). There was mild expansion of the right main pulmonary artery suggesting a mass and concerning for a possible tumor (Fig. 1D). There was no appreciable contrast enhancement and there were no areas of calcification or necrosis.

Given lack of improvement with anticoagulation, a negative hypercoagulable workup, negative family history, atypical CT angiogram for PE, and rarity of PE in children, this was concerning for a nonthrombus mass. Additional imaging was not considered at this time due to worsening symptoms and decision was made to proceed with surgical resection.

A total surgical resection was performed and tolerated well. Majority of the tumor was composed of cytologically bland, stellate cells deposited in myxoid stroma (Fig. 2). Tumor cells showed significant pleomorphism near the apparent luminal edge. Small foci within the tumor were more cellular and composed of spindled cells with a loose fibrous stroma rich in chronic inflammation. These cells were immunoreactive for smooth muscle actin; immunostains for ALK-1 and MDM2 were negative. Based on the morphologic and immunohistochemical findings, a final histologic diagnosis of a “low grade intimal sarcoma” was rendered [8].

Immediate postoperative CTA showed residual filling defect in the right interlobar artery. There was a complete resolution of the infarcts and the reactive pleural effusion. On the ^{99m}Tc -MAA perfusion scan, there was marked improvement in the right lung perfusion. A subsequent MRI and CTA 3 months after surgery showed resolution of the filling defect. Given the low grade nature of the tumor and resolution of the mass, she did not receive adjuvant chemotherapy or radiation. At the most recent 5-year visit, she continues to be disease free.

Discussion

PAS is extremely rare in children with only 5 reported cases [9–12]. Presenting symptoms included shortness of breath in 3 cases, poor feeding, edema and syncope each in one case, and one case that was asymptomatic. Imaging studies performed before surgical intervention were echocardiogram in 4 cases, cardiac MRI in 1 case, and 1 patient died before imaging could be obtained. Documented survival including our own case reported above, ranged from death on the day of admission to 5 years with 2 patients lost to follow up (Table 1).

Interestingly, in the limited pediatric cases, echocardiogram was the only imaging study performed in 3 of 5 cases. One report in pediatrics used MRI for diagnosis of PAS and could visualize the attachment of the mass to the intima of the pulmonary artery [9]. None of the pediatric cases used PET and hence its utility in diagnosis of children with PAS is unclear. In our case report, additional imaging was considered. However, due to worsening symptoms, decision was made to proceed with surgical intervention without additional imaging.

PAS is rare in adults although higher compared to pediatrics. Radiological experience in adults with PAS provides

Table 1 – Summary of pediatric primary pulmonary artery sarcoma.

	Age	Sex	Presenting symptom	Imaging	Treatment	Patient status
1 [9]	2 mo	M	Tachypnea, poor feeding, and murmur	Echocardiography Severe Pulmonary stenosis	Surgical Resection Chemotherapy with Cytosin, doxycycline, vincristine alternating with etoposide and ifosfamide	3 mo follow up.
2 [10]	17 y	M	Syncope	Echocardiography Cardiac MRI	Surgical Resection	Alive after surgery. No follow up.
3 [11]	11 y	M	Worsening Dyspnea on exertion. Murmur. Hypoxia of 84%	Echo	Surgical Resection	15 days post op. Lost to follow up.
4 [12]	14 y	M	Murmur	Echo followed by Angiography	Surgical Resection	14 mo follow up. Lost to follow up.
5 [12]	13 y	M	Worsening dyspnea with exertion. Worsening Edema	None	None	Died of disease before treatment
6	10 y	F	Cough, weight loss, and fever	CTA and Echocardiography	Surgical Resection	5 y follow up.

some guidance. CTA findings are similar to that of PE although there are features which point to PAS. Abrupt vascular narrowing and cutoff is more common in PE while vascular distension and unilateral involvement is more common in PAS [13,14]. Also, heterogeneous filling defect with heterogeneous enhancement suggests neoplastic process. Extravascular extension can be present in some cases and be detected on CTA. On conventional angiography, irregular and bulky polypoid or lobulated masses are highly suggestive of sarcomas. In one recent report, "Pseudo clot" sign was described as variable contrast enhancement of the filling defect on CTA which is more characteristic of PAS [15]. However, many case reports have reported filling defects without significant enhancement and hence a negative finding should not automatically exclude PAS [14]. MRI with contrast has also been reported to show enhancement in PAS compared to PE. Also, features of vascular distension or invasive extravascular spread were easier to visualize on MRI [14]. MRI has also been used for postoperative assessment for residual disease and used for follow up surveillance imaging in adults [16]. PET has also been used in making the diagnoses. Although the role of PET is still under investigation [17,18], one study showed an average standard uptake value (SUVmax) of 7.63 for PAS compared to 2.31 for PE indicating possible use of SUVmax for differentiating PAS from PE [19].

In conclusion, timely recognition and early surgical intervention in PAS is critical to patient survival. A high index of suspicion should be raised for diagnosis of PAS in pediatric patients presenting with symptoms of PE since PE is extremely rare in the pediatric population without a predisposing factor. Given that early surgical intervention is key to survival, proceeding to surgical resection is crucial. However, surgical intervention is highly invasive with significant risks for morbidity and mortality. Hence, decision to pursue surgical resection is difficult and requires an experienced multidisciplinary team to determine the risks and benefits. Radiological imaging options to aid in the decision making should be considered

carefully in the stable patient. First, a careful review of the already obtained CTA for characteristics of malignant process should be performed. Namely, differentiating features for PE being abrupt vascular narrowing and cutoff while for PAS, vascular distension and unilateral involvement is more common. In the stable patient, additional imaging with MRI or PET could be explored and may provide guidance when making the difficult decision to proceed with surgical resection.

REFERENCE

- [1] Nonomura A, Kurumaya H, Kono N, Nakanuma Y, Ohta G, Terahata S. Primary pulmonary artery sarcoma. Report of two autopsy cases studied by immunohistochemistry and electron microscopy, and review of 110 cases reported in the literature. *Acta Pathol Jpn* 1988;38(7):883–96.
- [2] Baker PB, Goodwin RA. Pulmonary artery sarcomas. A review and report of a case. *Arch Pathol Lab Med* 1985;109(1):35–9.
- [3] Delaney SG, Doyle TCA, Burton RW, Hung NA, Joblin LU, Taylor DR. Pulmonary artery sarcoma mimicking pulmonary embolism. *Chest*. 1993;103(3):1631–3.
- [4] Krüger I, Borowski A, Horst M, de Vivie ER, Theissen P, Gross-Fengels W. Symptoms, diagnosis, and therapy of primary sarcomas of the pulmonary artery. *Thorac Cardiovasc Surg*. 1990;38(2):91–5.
- [5] Wong HH, Gounaris I, McCormack A, Berman M, Davidson D, Horan G, et al. Presentation and management of pulmonary artery sarcoma. *Clin Sarcoma Res*. 2015;5(1):3–10.
- [6] Zaidi AU, Hutchins KK, Rajpurkar M. Pulmonary Embolism in children. *Font Pediatr*. 2017;5:170.
- [7] Minges KE, Bikdeli B, Wang Y, Kim N, Curtis JP, Desai MM, et al. National trends in pulmonary embolism hospitalization rates and outcomes for adults aged ≥ 65 years in the United States (1999 to 2010). *Am J Cardiol*. 2015;116(9):1436–42.
- [8] Tavora F, Miettinen M, Fanburg-Smith J, Franks TJ, Burke A. Pulmonary artery sarcoma: a histologic and follow-up study with emphasis on a subset of low-grade myofibroblastic

- sarcomas with a good long-term follow-up. *Am J Surg Pathol*. 2008;32(12):1751–61.
- [9] Chappell T, Creech CB, Parra D, Strauss A, Scholl F, Whitney G. Presentation of pulmonary artery intimal sarcoma in an infant with a history of neonatal valvular pulmonic stenosis. *Ann Thorac Surg*. 2008;85(3):1092–4.
- [10] Sun J, Tang H, Lu C, Chen Y. Syncope caused by pulmonary artery intima sarcoma: a cardiac magnetic resonance imaging-based differentiating diagnosis. *Eur J Cardiothorac Surg*. 2014;46(3):503.
- [11] Garg A, Mooney J, Amado Escañuela MG, Mathur A, Goyal V, Nanda NC. Transthoracic echocardiographic assessment of spindle cell sarcoma of the pulmonary artery in a child. *Echocardiography* 2014;31(3):385–7.
- [12] Farooki ZQ, Chang CH, Jackson WL, Clapp SK, Hakimi M, Arciniegas E, et al. Primary pulmonary artery sarcoma in two children. *Pediatr Cardiol*. 1988;9(4):243–51.
- [13] Cox JE, Chiles C, Aquino SL, Savage P, Oaks T. Pulmonary artery sarcomas: a review of clinical and radiologic features. *J Comput Assist Tomogr*. 1997;21(5):750–5.
- [14] Kauczor HU, Schwickert HC, Mayer E, Kersjes W, Moll R, Schweden F. Pulmonary artery sarcoma mimicking chronic thromboembolic disease: computed tomography and magnetic resonance imaging findings. *Cardiovasc Intervent Radiol*. 1994;17(4):185–9.
- [15] Ebner L, Huber A, Ott D, Christe A. Pulmonary intimal sarcoma: a rare differential diagnosis for arterial filling defects on a chest CT. *Acta Radiol Short Rep* 2014;3:1–4.
- [16] Rafal RB, Nichols JN, Markisz JA. Pulmonary artery sarcoma: diagnosis and postoperative follow-up with gadolinium-diethylenetriamine pentaacetic acid-enhanced magnetic resonance imaging. *Mayo Clin Proc*. 1995;70(2):173–6.
- [17] Lee EJ, Moon SH, Choi JY, Lee KS, Choi YS, Choe YS, Lee KH, Kim BT. Usefulness of fluorodeoxyglucose positron emission tomography in malignancy of pulmonary artery mimicking pulmonary embolism. *ANZ J Surg*. 2013;83(5):342–7.
- [18] Lee DH, Jung TE, Lee JH, Shin DG, Park WJ, Choi JH. Pulmonary artery intimal sarcoma: poor 18F-fluorodeoxyglucose uptake in positron emission computed tomography. *J Cardiothorac Surg*. 2013;8:40–3.
- [19] Ito K, Kubota K, Morooka M, Shida Y, Hasuo K, Endo H, Matsuda H. Diagnostic usefulness of 18F-FDG PET/CT in the differentiation of pulmonary artery sarcoma and pulmonary embolism. *Ann Nucl Med*. 2009;23(7):671–6.