

The left atrium in cardiac amyloidosis: a valuable but still underused observation window on the overall disease process

Claudio Rapezzi^{1,2*}, Rita Pavasini¹, and Matteo Serenelli¹

¹Cardiological Centre, University of Ferrara, Ferrara, Italy; and ²Maria Cecilia Hospital, GVM Care & Research, Cotignola, Italy

This article refers to ‘Left atrial structure and function of the amyloidogenic V122I transthyretin variant in elderly African Americans’ by M. Minamisawa *et al.*, published in this issue on pages 1290–1295.

Strain and strain rate imaging have now gained an established role in characterizing the different components of atrial function, e.g. the ability to expand during ventricular systole (reservoir function), early diastolic emptying (conduit function), atrial shortening (contraction), and, when associated with the estimation of left ventricular (LV) pressures, the resistance to deformation of the left atrium [left atrial (LA) stiffness]¹ (Figure 1).

In this issue of the Journal, Minamisawa *et al.*,² from the Brigham and Women’s Hospital, Boston, USA, report the results of a detailed echocardiographic exploration of the left atrium in African-American carriers of the transthyretin (TTR) valine-to-isoleucine substitution (V122I) participating in the Atherosclerosis Risk in Communities study.³ This is the most frequent amyloidogenic TTR mutation, present in 3–4% of Black Americans and generally associated with a cardiac phenotype.⁴ The main finding of this analysis was that the LA minimum volume index was significantly greater, LA longitudinal strain was worse and multiple atrial abnormalities were more frequent in carriers compared to non-carriers, suggesting that LA dysfunction may be a useful echocardiographic marker of subclinical disease in V122I carriers, before overt late-onset amyloid cardiomyopathy develops.

Despite many methodological limitations also admitted by the authors, the study is undoubtedly stimulating and raises, directly or indirectly, some relevant questions.

To what extent are the abnormalities of the left atrium simply a consequence of ventricular dysfunction as opposed to reflecting a real ‘infiltrative atrial myopathy’?

Abnormalities of LA structure and function may be the result of abnormalities of LV systolic and diastolic function and elevated filling pressure or they may be due to intrinsic abnormalities of the left atrium. Notably, none of the cases studied by Minamisawa *et al.* had a definite diagnosis of cardiomyopathy. In particular, LV wall thicknesses, ventricular mass, and LV ejection fraction were normal.² Among the carriers, however, the mean values of N-terminal pro-B-type natriuretic peptide (NT-proBNP), E wave and lateral E/e’ ratio were significantly higher than in non-carriers. These are modest but statistically significant differences. The authors, however, tend to interpret the anatomical and functional anomalies found as an expression of an initial atrial amyloidotic infiltration due to the fact that these anomalies concerned the minimum (not maximum) LA volume and contractile longitudinal strain, and that the differences persisted after adjustment for body mass index and LV global longitudinal strain. This interpretation is reasonable but far from certain and warrants confirmation from other studies. Furthermore, in none of the subjects studied did the authors search for signs of cardiac amyloidosis by scintigraphy or biopsy (apart from the presence of the V122I mutation). Nevertheless, the existence of atrial dysfunction correlated to an amyloidotic infiltration of the wall has already been documented in other patients by magnetic resonance, particularly in cases of AL amyloidosis.⁵

The opinions expressed in this article are not necessarily those of the Editors of the *European Journal of Heart Failure* or of the European Society of Cardiology. doi: 10.1002/ejhf.2200

*Corresponding author: Cardiology, Azienda Ospedaliero-Universitaria di Ferrara, Ospedale di Cona, Via Aldo Moro 8, 44124 Cona (FE), Italy. Tel: +39 0532 239882, Email: claudio.rapezzi@unife.it

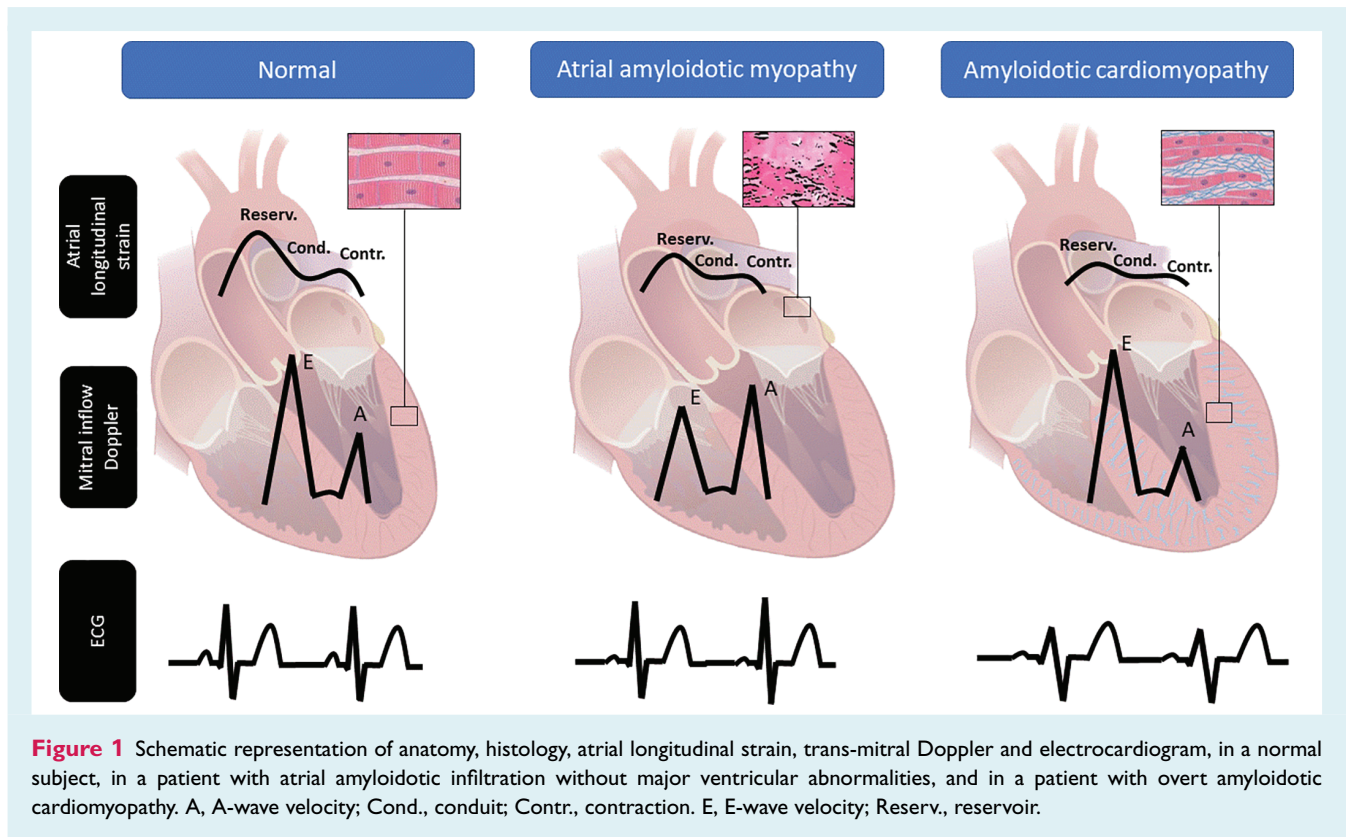


Figure 1 Schematic representation of anatomy, histology, atrial longitudinal strain, trans-mitral Doppler and electrocardiogram, in a normal subject, in a patient with atrial amyloidotic infiltration without major ventricular abnormalities, and in a patient with overt amyloidotic cardiomyopathy. A, A-wave velocity; Cond., conduit; Contr., contraction. E, E-wave velocity; Reserv., reservoir.

When and where does ‘amyloid cardiomyopathy’ begin?

The authors’ hypothesis that atrial anomalies may precede the development of more overt late-onset amyloid cardiomyopathy² is intriguing but not documented (Figure 1). This cross-sectional study does not permit to speculate on the natural history of amyloid infiltration in the heart. Patients were not followed over time, or at least their clinical and echocardiographic follow-up was not reported. Moreover, considering the few other studies available on the atrium in cardiac amyloidosis,^{1,6–8} the observations were also cross-sectional and based on cases with already overt forms of amyloidotic cardiomyopathy. The rationale behind the hypothesis that myocardial infiltration begins in the atria and then extends to the ventricles is not convincing. It is more likely that there is a widespread myocardial infiltration from the outset, which becomes functionally manifest first in the thinner chambers (precisely the atria).

In any case, being able to identify the presence of cardiac amyloidosis at a very early stage is clinically important. Apart from the study of atrial strain, until now only scintigraphy with diphosphonates has been able to identify carriers of amyloidogenic mutations with myocardial infiltration already present even in the absence of obvious echocardiographic and electrocardiographic morphological alterations.⁹ Whether it is reasonable to start disease-modifying therapy at such an early stage of the disease is a completely open question!

By what mechanism does the mere presence of a V122I mutation increase the risk of atrial dysfunction, heart failure, atrial fibrillation and stroke?

The ARIC study database has been widely used to investigate the functional and prognostic implications of a V122I mutation among Black Americans and the association of this mutation with an increased risk of chronic heart failure,³ atrial fibrillation and stroke.¹⁰ Atrial fibrillation and stroke have already been documented in subjects without overt amyloidotic cardiomyopathy.¹⁰

On the other hand, development of a ‘classic’ myocardial infiltration may not be the only mechanism by which a V122I mutation leads to functional alterations of the atrium and an increased risk of heart failure, atrial fibrillation and stroke. This issue was extensively discussed already back in the first ARIC papers on V122I.¹¹ The authors speculated that there may be mechanisms other than extensive amyloid infiltration of the myocardium by which V122I contributes to heart failure, including a synergistic effect with other risk factors such as hypertension. Thus, carriers with little or no infiltration and minimal coexisting disease might remain asymptomatic, while those with other risk factors would manifest disease. The same reasoning and doubts also apply to atrial dysfunction in the study by Minamisawa *et al.*²

To what extent can 'atrial myopathy' explain an incremental thromboembolic risk of cardiac amyloidosis independently of atrial fibrillation, and which patients are candidate for anticoagulants despite sinus rhythm?

Even if the authors do not address this question, it is clear that an atrial myopathy with consequences on the contractile function of the atrium could lead to the formation of local thrombosis even without atrial fibrillation. Supporting this hypothesis are some epidemiological data and anatomopathological and echocardiographic findings.

A retrospective case series of the Mayo Clinic reported that intracardiac thrombi were present in 42 out of 156 patients (27%) undergoing a transoesophageal echocardiogram for any reason.¹² Most thrombi were found in the LA appendage (32/58, 55%). The risk of intracardiac thrombosis was particularly high in patients with AL-cardiac amyloidosis and in those with atrial fibrillation, but LV diastolic dysfunction emerged as a predictor of intracardiac thrombosis independently of atrial fibrillation.¹² In a more recent series of 324 patients with cardiac amyloidosis (CA) from two European centres [79% male, 51% with transthyretin cardiac amyloidosis (ATTR-CA), 31% with atrial fibrillation or flutter], the prevalence of intracardiac thrombi was 6.2% [95% confidence interval (CI) 3.5–8.8] in the overall sample, 5.2% (95% CI 1.6–8.7) in AL, and 7.2% (95% CI 3.3–11.2) in ATTR ($P = 0.45$).¹³ Of the patients with intracardiac thrombi ($n = 20$), 13 were in atrial fibrillation and 7 in sinus rhythm.

A multicentre retrospective study evaluated 406 patients with cardiac amyloidosis (134 AL, 73 ATTRv and 199 ATTRwt), followed up for a median of 19 months. Thirty-one patients (7.6%) had an event (ischaemic stroke, transient ischaemic attack, or peripheral embolism): 10 events represented the first manifestation of cardiac amyloidosis, while the other 21 occurred during the follow-up, with an estimated incidence of 2.2% per year (95% CI 1.4–3.3). Ten patients experiencing an event (32.2%) were in sinus rhythm and had no history of atrial fibrillation. Across different cardiac amyloidosis aetiologies, a consistent proportion of events occurred in the absence of documented atrial fibrillation (33.3% AL, 16.7% ATTRv, 37.5% ATTRwt).¹⁴

Is the study of the left atrium in cardiac amyloidosis ready for routine clinical use or still just a research tool?

The evaluation of atrial strain with speckle tracking is feasible in most cases without excessive technical problems and can assess the

three phases of LA dimension (Figure 1). Cameli *et al.*¹⁵ reported that one of the possible measures – global LA strain during the reservoir phase with QRS as starting point – can be calculated in the vast majority of patients (in 90% of cases by junior readers, 95% by senior readers). It does not prolong acquisition times, can be calculated off-line in a median time of 110 s (by both junior and senior readers), and is highly reproducible (inter-correlation coefficient = 0.93).

In the largest study to date published on the evaluation of the left atrium with speckle tracking, the three phases of atrial function were evaluated in all enrolled patients, showing measurable differences between different aetiologies and precise relationships with LV function.¹

In conclusion, Minamisawa *et al.*'s study² has the capacity to raise, explicitly or implicitly, a series of extremely challenging clinical and pathophysiological questions. A functional study of the left atrium is possible with speckle tracking and this undoubtedly extends our ability to understand a disease that, despite the advances made, still remains a mystery.

Conflict of interest: none declared.

References

- Nochioka K, Quarta CC, Claggett B, Roca GQ, Rapezzi C, Falk RH, Solomon SD. Left atrial structure and function in cardiac amyloidosis. *Eur Heart J Cardiovasc Imaging* 2017;**18**:1128–1137.
- Minamisawa M, Inciardi RM, Claggett B, Cuddy SA, Quarta CC, Shah AM, Dorbala S, Falk RH, Matsushita K, Kitzman DV, Chen LY, Solomon SD. Left atrial structure and function of the amyloidogenic V122I transthyretin variant in elderly African Americans. *Eur J Heart Fail* 2021;**23**:1290–1295.
- The Atherosclerosis Risk in Communities (ARIC) study: design and objectives. The ARIC Investigators. *Am J Epidemiol* 1989;**129**:687–702.
- Damrauer SM, Chaudhary K, Cho JH, Liang LW, Argulian E, Chan L, Dobbyn A, Guerraty MA, Judy R, Kay J, Kember RL, Levin MG, Saha A, Van Vleck T, Verma SS, Weaver J, Abul-Husn NS, Baras A, Chirinos JA, Drachman B, Kenny EE, Loos RJF, Narula J, Overton J, Reid J, Ritchie M, Sirugo G, Nadkarni G, Rader DJ, Do R. Association of the V122I hereditary transthyretin amyloidosis genetic variant with heart failure among individuals of African or Hispanic/Latino ancestry. *JAMA* 2019;**322**:2191–2202.
- Di Bella G, Minutoli F, Madaffari A, Mazzeo A, Russo M, Donato R, Zito C, Aquaro GD, Piccione MC, Pedri S, Vita G, Pingitore A, Carerj S. Left atrial function in cardiac amyloidosis. *J Cardiovasc Med* 2016;**17**:113–121.
- Kurt M, Wang J, Torre-Amione G, Nagueh SF. Left atrial function in diastolic heart failure. *Circ Cardiovasc Imaging* 2009;**2**:10–15.
- Aquaro GD, Morini S, Grigoratos C, Taborchi G, Di Bella G, Martone R, Vignini E, Emdin M, Olivetto I, Perfetto F, Cappelli F. Electromechanical dissociation of left atrium in patients with cardiac amyloidosis by magnetic resonance: prognostic and clinical correlates. *Int J Cardiol Heart Vasc* 2020;**31**:100633.
- Mohty D, Boulogne C, Magne J, Varroud-Vial N, Martin S, Ettaif H, Fadel BM, Bridoux F, Aboyans V, Damy T, Jaccard A. Prognostic value of left atrial function in systemic light-chain amyloidosis: a cardiac magnetic resonance study. *Eur Heart J Cardiovasc Imaging* 2016;**17**:961–969.
- Rapezzi C, Quarta CC, Guidalotti PL, Pettinato C, Fanti S, Leone O, Ferlini A, Longhi S, Lorenzini M, Reggiani LB, Gagliardi C, Gallo P, Villani C, Salvi F. Role of ^{99m}Tc-DPD scintigraphy in diagnosis and prognosis of hereditary transthyretin-related cardiac amyloidosis. *JACC Cardiovasc Imaging* 2011;**4**:659–670.
- Selvaraj S, Claggett B, Minamisawa M, Windham BG, Chen LY, Inciardi RM, Buxbaum JN, Mosley TH, Shah AM, Solomon SD. Atrial fibrillation and ischemic stroke with the amyloidogenic V122I transthyretin variant among Black Americans. *J Am Coll Cardiol* 2021;**78**:89–91.
- Buxbaum J, Alexander A, Koziol J, Tague C, Fox E, Kitzman D. Significance of the amyloidogenic transthyretin Val 122 Ile allele in African Americans in the Arteriosclerosis Risk in Communities (ARIC) and Cardiovascular Health (CHS) studies. *Am Heart J* 2010;**159**:864–870.
- Feng D, Syed IS, Martinez M, Oh JK, Jaffe AS, Grogan M, Edwards WD, Gertz MA, Klarich KW. Intracardiac thrombosis and anticoagulation therapy in cardiac amyloidosis. *Circulation* 2009;**119**:2490–2497.

13. Martinez-Naharro A, Gonzalez-Lopez E, Corovic A, Mirelis JG, Baksi AJ, Moon JC, Garcia-Pavia P, Gillmore JD, Hawkins PN, Fontana M. High prevalence of intracardiac thrombi in cardiac amyloidosis. *J Am Coll Cardiol* 2019;**73**: 1733–1734.
14. Cappelli F, Tini G, Russo D, Emdin M, Del Franco A, Vergaro G, Di Bella G, Mazzeo A, Canepa M, Volpe M, Peretto F, Autore C, Di Mario C, Rapezzi C, Musumeci MB. Arterial thrombo-embolic events in cardiac amyloidosis: a look beyond atrial fibrillation. *Amyloid* 2021;**28**:12–18.
15. Cameli M, Miglioranza MH, Magne J, Mandoli GE, Benfari G, Ancona R, Sibilio G, Reskovic Luksic V, Dejan D, Griseli L, van de Heyning CM, Mortelmans P, Michalski B, Kupczynska K, di Giannuario G, Devito F, Dulgheru R, Ilardi F, Salustri A, Abushahba G, Morrone D, Fabiani I, Penicka M, Katbeh A, Sammarco G, Esposito R, Santoro C, Pastore MC, Comenale Pinto S, Kalinin A, Pičkure Ž, Ažman Juvan K, Zupan Mežnar A, Coisne A, Coppin A, Opris MM, Nistor DO, Paakkanen R, Biering-Sørensen T, Olsen FJ, Lapinskas T, Vaškelytė JJ, Galian-Gay L, Casas G, Motoc AI, Papadopoulos CH, Loizos S, Agoston G, Szabó I, Hristova K, Tsonev SN, Galli E, Vinereanu D, Mihaila Baldea S, Muraru D, Mondillo S, Donal E, Galderisi M, Cosyns B, Edvardsen T, Popescu BA. Multicentric Atrial Strain COmparison between Two Different Modalities: MASCOT HIT study. *Diagnostics* 2020;**10**:946.