Human Reproduction, Vol.35, No.7, pp. 1601–1611, 2020
doi:10.1093/humrep/deaa131

human reproduction

ORIGINAL ARTICLE *Gynaecology*

Risk of bowel fistula following surgical management of deep endometriosis of the rectosigmoid: a series of 1102 cases

Horace Roman[1,2,*], Valérie Bridoux[3], Benjamin Merlot[1], Benoit Resch[4,5], Rachid Chati[3], Julien Coget[3], Damien Forestier[1], and Jean-Jacques Tuech[3]

[1]Endometriosis Center, Clinique Tivoli-Ducos, Bordeaux, France [2]Department of Gynecology and Obstetrics, Aarhus University Hospital, Aarhus, Denmark [3]Department of Digestive Surgery, Rouen University Hospital, Rouen, France [4]Department of Gynecology and Obstetrics, Rouen University Hospital, Rouen, France [5]Clinique Mathilde, Rouen, France

*Correspondence address. Center of Endometriosis, Clinique Tivoli-Ducos, 91 rue de Rivière, 33000 Bordeaux, France. Tel: +33-556-116-092; E-mail: horace.roman@gmail.com

Submitted on January 11, 2020; resubmitted on May 6, 2020; editorial decision on May 11, 2020

STUDY QUESTION: What are the risk factors and prevalence of bowel fistula following surgical management of deep endometriosis infiltrating the rectosigmoid and how can it be managed?

SUMMARY ANSWER: In patients managed for deep endometriosis of the rectosigmoid, risk of fistula is increased by bowel opening during both segmental colorectal resection and disc excision and rectovaginal fistula repair is more challenging than for bowel leakage.

WHAT IS KNOWN ALREADY: Bowel fistula is known to be a severe complication of colorectal endometriosis surgery; however, there is little available data on its prevalence in large series or on specific management.

STUDY DESIGN, SIZE, DURATION: A retrospective study employing data prospectively recorded in the North-West Inter Regional Female Cohort for Patients with Endometriosis (CIRENDO) from June 2009 to May 2019, in three tertiary referral centres.

PARTICIPANTS/MATERIALS, SETTING, METHODS: One thousand one hundred and two patients presenting with deep endometriosis infiltrating the rectosigmoid, who were managed by shaving, disc excision or colorectal resection. The prevalence of bowel fistula was assessed, and factors related to the complication and its surgical management.

MAIN RESULTS AND THE ROLE OF CHANCE: Of 1102 patients enrolled in the study, 52.5% had a past history of gynaecological surgery and 52.7% had unsuccessfully attempted to conceive for over 12 months. Digestive tract subocclusion/occlusion was recorded in 12.7%, hydronephrosis in 4.5% and baseline severe bladder dysfunction in 1.5%. An exclusive laparoscopic approach was carried out in 96.8% of patients. Rectal shaving was performed in 31.9%, disc excision in 23.1%, colorectal resection in 35.8% and combined disc excision and sigmoid colon resection in 2.9%. For various reasons, the nodule was not completely removed in 6.4%, while in 7.2% of cases complementary procedures on the ileum, caecum and right colon were required. Parametrium excision was performed in 7.8%, dissection and excision of sacral roots in 4%, and surgery for ureteral endometriosis in 11.9%. Diverting stoma was performed in 21.8%. Thirty-seven patients presented with bowel fistulae (3.4%) of whom23 (62.2%) were found to have rectovaginal fistulae and 14 (37.8%) leakage. Logistic regression model showed rectal lumen opening to increase risk of fistula when compared with shaving, regardless of nodule size: adjusted odds ratio (95% CI) for disc excision, colorectal resection and association of disc excision + segmental resection was 6.8 (1.9–23.8), 4.8 (1.4–16.9) and 11 (2.1–58.6), respectively. Repair of 23 rectovaginal fistulae required 1, 2, 3 or 4 additional surgical procedures in 12 (52.2%), 8 (34.8%), 2 (8.7%) and 1 patient (4.3%), respectively. Repair of leakage in 14 patients required 1 procedure (stoma) in 12 cases (85.7%) and a second procedure (colorectal resection) in 2 cases (14.3%). All patients, excepted five women managed by delayed coloanal anastomosis, underwent a supplementary surgical procedure for stoma repair. The period of time required for diverting stoma following repair of rectovaginal fistulae was significantly longer than for repair of leakages (median values 10 and 5 months, respectively, $P = 0.008$)

© The Author(s) 2020. Published by Oxford University Press on behalf of European Society of Human Reproduction and Embryology.
This is an Open Access article distributed under the terms of the Creative Commons Attribution Non-Commercial License (http://creativecommons.org/licenses/by-nc/4.0/), which permits non-commercial re-use, distribution, and reproduction in any medium, provided the original work is properly cited. For commercial re-use, please contact journals.permissions@oup.com

LIMITATIONS, REASONS FOR CAUTION: The main limits relate to the heterogeneity of techniques used in removal of rectosigmoid nodules and repairing fistulae, the lack of accurate information about the level of nodules, the small number of centres and that a majority of patients were managed by one surgeon.

WIDER IMPLICATIONS OF THE FINDINGS: Deep endometriosis infiltrating the rectosigmoid can be managed laparoscopically with a relatively low risk of bowel fistula. When the type of bowel procedure can be chosen, performance of shaving instead of disc excision or colorectal resection is suggested considering the lower risk of bowel fistula. Rectovaginal fistula repair is more challenging than for bowel leakage and may require up to four additional surgical procedures.

STUDY FUNDING/COMPETING INTEREST(S): CIRENDO is financed by the G4 Group (The University Hospitals of Rouen, Lille, Amiens and Caen) and the ROUENDOMETRIOSE Association. No financial support was received for this study. H.R. reports personal fees from ETHICON, Plasma Surgical, Olympus and Nordic Pharma outside the submitted work. The other authors declare no conflict of interests related to this topic.

Key words: deep endometriosis / rectum / sigmoid colon / disc excision / full-thickness excision / fistula / rectovaginal fistula / bowel suture

Introduction

Deep rectovaginal endometriosis nodules in young women may infiltrate the rectum and sigmoid colon, with or without adjacent vagina, leading to various specific complaints, such as major dyschesia, catamenial diarrhoea, tenesmus, anal continence troubles, bloating, along with deep dyspareunia. Medical treatment mainly involves hormonal therapies (combined oral contraceptives, progestins or GnRH analogues) and can relieve digestive complaints in the majority of cases. However, medical therapy should be taken continuously is contraceptive and may have side effects (Vercellini *et al.*, 2011). Expectant management may be followed by an increase in nodule size in 39% of cases after as little as 3 years (Netter *et al.*, 2019). For these reasons, surgical management may be considered to allow removal of endometriosis lesions and provide relief from symptoms.

Two surgical approaches are used in the management of deep endometriosis infiltrating the rectum and the sigmoid colon: a radical approach based on segmental colorectal resection, and a more conservative approach based on nodule removal using shaving or disc excision (Roman *et al.*, 2018). Bowel shaving allows removal of the endometriosis nodule without opening the lumen; however, this technique may not be suitable in large nodules due to the risk of incomplete excision and subsequent persistence of endometriosis foci and post-operative recurrences on the bowel (Meuleman *et al.*, 2011; Roman *et al.*, 2016a). Full-thickness disc excision allows removing the bowel shaving area with the bowel opening sutured transversally in order to avoid stenosis of the lumen (Roman *et al.*, 2017). Segmental colorectal resection provides a macroscopically complete removal of endometriosis nodules along with a segment of macroscopically normal bowel surrounding the nodule; however, it may lead to stenosis of the colorectal lumen (Roman *et al.*, 2018) and an increase in various post-operative complications (Donnez and Roman, 2017; Abo *et al.*, 2018). Patients undergoing surgical removal of deep endometriosis of the rectum and sigmoid should be informed that this can lead to functional troubles, of which the most serious is the low anterior resection syndrome (LARS) (Emmertsen and Laurberg, 2012; Riiskjaer *et al.*, 2016). Bowel fistula is one of the most feared complications, occurring in around 3% of cases depending on patient characteristics, as shown in various series (Meuleman *et al.*, 2011; Donnez and Roman, 2017).

Management of bowel fistula is considered to be challenging, leading to numerous surgical strategies being advocated including abdominal, transvaginal, transanal and perineal approaches (Corte *et al.*, 2015). Available data, however, on management of fistulae after colorectal endometriosis surgery, remain sparse.

The aim of this study was focus on bowel fistula following surgery of deep endometriosis infiltrating the rectum and sigmoid colon, by assessing the prevalence, risk factors, and the management of this severe post-operative complication.

Materials and methods

We enrolled in this retrospective study all patients with deep endometriosis infiltrating the muscular layer or deeper of the rectum and sigmoid colon, who had benefitted from surgical management from October 2009 to May 2019 at the Rouen University Hospital, the Clinique Mathilde, Rouen and the Endometriosis Center, Clinique Tivoli-Ducos, Bordeaux, France. All patients were pre-operatively examined by experienced gynaecologists (H.R., B.R. and B.M.). Preoperative assessment was performed by radiologists with considerable experience in deep endometriosis and included pelvic MRI, endorectal/transvaginal ultrasound and if required, computed tomography-based virtual colonoscopy. This allowed assessment of colorectal nodules' characteristics and identification of associated localizations involving the vagina, uterosacral ligaments, ovaries, fallopian tubes, diaphragm, urinary tract, pelvic nerves, etc. To define the level of the deep endometriosis nodule localization, we used the following thresholds: low rectum—up to 5 cm above the anal verge; mid rectum—5–10 cm; upper rectum—10–15 cm; sigmoid colon—over 15 cm. To remove colorectal nodules, shaving, disc excision or colorectal segmental resection were proposed. Disc excisions were carried out using a combined laparoscopic-transanal approach, by employing either circular stapler (the technique is used by numerous teams worldwide) or a semi-circular stapler (the Rouen technique, which is original and used by a small number of teams in Europe) (Roman *et al.*, 2017). For multiple bowel nodules, the aforementioned techniques could be associated with sparing healthy bowel located between consecutive nodules (Millochau *et al.*, 2018). In rare cases (6.4%), patients requested

partial removal of bowel nodules, including adhesiolysis and rectal release or incomplete shaving, thus the goal of surgery was to treat only other localizations of the disease. This choice was justified by the presence of minor digestive complaints, associated with other localizations responsible for example infertility, hydronephrosis, pelvic nerve pain and deep dyspareunia. The choice of surgical approach was made preoperatively and patients were fully informed of the aims, risks and expected benefits of our approach. The possibility of performing diverting stoma at the end of the procedure was also discussed with patients. Surgical procedure on the bowel involved one gynaecological surgeon and an experienced colorectal surgeon. The decision to create a primary stoma by ileostomy or colostomy was made by both surgeons and based on intraoperative findings such as the close proximity of vaginal and rectal sutures following both vaginal and rectal excision and unsatisfactory colorectal anastomosis bubble test results (Bonin *et al.*, 2019). Positive bubble test required reinforcement of stapled line using stitches; however, it was an argument to perform a stoma. Omental flap was systematically placed between rectal and vaginal repair sutures in patients managed in Rouen prior to 2018, but not used in Bordeaux from 2018 to 2019, this change in strategy being in accordance with French guidelines for the management of endometriosis which highlighted the lack of evidence to support this procedure (Loriau *et al.*, 2018). It is for this reason that our use of omental flap is now limited to procedures involving repair of fistulae.

Post-operative hospitalization varied from 4 to 6 days. Clinical symptoms and body temperature were recorded three times/day, and the assessment of blood values of C-reactive protein (CRP) and white blood cells (WBCs) was routinely performed at Day 4, 5 and 6 (Scattarelli *et al.*, 2019). When patients presented intrarectal temperature >38.2°C, or progressive increase in either CRP or WBC for 2 consecutive days, emergency clinical examination and computed tomography with barium enema were performed to rule out anastomotic leakage, rectovaginal fistula, pelvic abscess or infected pelvic haematoma. Patients with bowel fistula underwent emergency secondary surgery with diverting stoma. In patients with haematoma or abscess but without obvious bowel leakage, emergency laparoscopy was performed to drain the liquid followed by a rectal bubble air test, and when the test was abnormal or equivocal, a secondary stoma was created prophylactically (Bonin *et al.*, 2019).

A post-operative visit was scheduled 8 weeks post-operatively. When a stoma was performed, rectal enema was planned 8 weeks after the procedure to rule out rectovaginal fistula or bowel leakage, then stoma closure was performed 3 months after surgery. In cases of incomplete fistula healing, additional procedures were performed, depended on the patient and fistula characteristics, and included vaginal or/and rectal flap, bowel suture, colorectal resection and delayed coloanal anastomosis (DCAA). Procedure choice usually favoured first line less aggressive procedures (vaginal and rectal flap) over abdominal procedures, i.e. bowel suture, DCAA and colorectal resection. DCAA has been proposed as an alternative to direct coloanal anastomosis with a protective stoma. This two-step technique consists of externalizing the colon in the first stage by the transanal route, without creating a stoma (in patients with stoma, it is repaired during the DCAA procedure), followed by the creation of the coloanal anastomosis 2 weeks later. The advantage of this technique is to efficiently repair rectovaginal fistula, because intact colon is placed on contact with the vaginal wound. Several studies have shown encouraging results in the short and midterm, and it is listed among the technical options in the French recommendations for the management of rectal cancer (Corte *et al.*, 2015).

Prospective recording of data concerning antecedents, clinical symptoms, findings of clinical and imagery examinations, surgical procedures and post-operative outcomes was performed through the CIRENDO (North-West Inter Regional Female Cohort for Patients with Endometriosis) database (NCT02294825). This prospective cohort is financed by the G4 Group (The University Hospitals of Rouen, Lille, Amiens and Caen) and coordinated by one of the authors (H.R.). Information was obtained using self-questionnaires and surgical and histological records, while data recording, contact and follow-up were carried out by two clinical research technicians. Prospective recording of data was approved by the French authority CCTIRS (Advisory Committee on information processing in healthcare research).

Statistical analysis was performed using Stata 11.0 software (StatCorp). Patient characteristics, surgical procedures, post-operative outcomes and score values were presented as numbers and percentages (qualitative variables) or mean and SD (continuous variables). Women with and without bowel fistulae were compared using either the Kruskal–Wallis test (continuous variables) or Fischer's exact test (qualitative variables). A logistic regression model was used to identify factors independently related to the risk of bowel fistula and included those factors of clinical interest or for which relationship with fistula was shown to be <0.2 in univariate analysis. A *P*-value of <0.05 was considered statistically significant. The study was approved by the Rouen University Hospital Institutional Ethics Committee for Non-Interventional Research.

Results

From June 2009 to May 2019, 1102 patients met inclusion criteria and were enrolled in the study, of whom 37 had bowel fistulae (3.4%). Eight hundred and thirty-one patients were enrolled at Rouen University Hospital from June 2009, 39 at the Clinique Mathilde in Rouen from March 2012, and 232 at the Clinique Tivoli-Ducos in Bordeaux from September 2018. The majority of patients were managed by three experienced gynaecological surgeons (Table I). Among 37 patients with bowel fistula, we recorded 23 rectovaginal fistulae (62.2%)and 14 bowel leakages and no vaginal opening (37.8%).

Table I presents patient characteristics. Patients with fistula were younger, had impaired baseline constipation and anal continence scores, and more frequent pre-operative bladder dysfunction, corresponding to more severe diseases. Past history of infertility was recorded in over half the patients. Four patients out of five were nullipara.

Table II presents intraoperative findings, surgical procedures and main post-operative complications. Women presenting with post-operative fistulae had larger rectal nodules. They underwent more complex procedures, with more frequent parametrium and vaginal excision, ureter reimplantation into the bladder and more frequent sacral roots involvement, resulting in longer operative time. Diverting stoma was more frequently performed at the end of the procedure in women who had post-operative fistulae. Follow-up ranged from 4 to 124 months. As the study concerned only immediate outcomes (occurrence of the fistula) and information about fistula repair, we did not record missing data due to the loss of follow-up.

Table I Patient characteristics.

	Whole population* (n = 1102 (%))	No fistula** (n = 1065 (96.6%))	Fistula** (n = 37 (3.4%))	*P*
Age (years)				0.044
<25	86 (7.8)	82 (95.4)	4 (4.6)	
25–35	643 (58.4)	616 (95.8)	27 (4.2)	
>35	373 (33.8)	367 (98.4)	6 (1.6)	
Body mass index (kg/m^2)				0.19
<18.5	59 (5.7)	56 (94.9)	3 (5.1)	
18.5–25	665 (63.7)	646 (97.1)	19 (2.9)	
25.1–30	204 (19.5)	193 (94.6)	11 (5.4)	
>30	116 (11.1)	114 (98.3)	2 (1.7)	
Smoking	313 (28.4)	300 (95.9)	13 (4.2)	0.36
Past history of surgical procedures				
Abdominal surgery (no gynaecological)	111 (10.1)	109 (98.2)	2 (1.8)	0.57
Bowel resection (no endometriosis)	5 (0.5)	5 (100)	0	1
Gynaecological surgery (no endometriosis)	254 (23)	249 (98)	5 (2)	0.23
Endometriosis surgery (no bowel resection)	308 (27.9)	294 (95.5)	14 (4.5)	0.19
Bowel resection for endometriosis	10 (0.9)	10 (100)	0	1
Right oophorectomy	18 (1.7)	18 (100)	0	1
Left oophorectomy	21 (2)	19 (90.5)	2 (9.5)	0.14
Nephrectomy	3 (0.3)	3 (100)	0	1
Myomectomy	44 (4.1)	44 4.1)	0	0.40
Obstetric history				
Nulligravida	622 (56.4)	600 (96.5)	22 (3.5)	0.17
Nullipara	902 (81.9)	871 (96.6)	31 (3.4)	0.66
Infertility				
Unsuccessful natural conception >12 months	567 (52.7)	545 (96.3)	22 (3.7)	0.22
Past assisted reproductive techniques	247 (22.4)	237 (95.9)	10 (4.1)	0.55
Endometriosis-related pain				
Dysmenorrhoea	1029 (97.7)	994 (96.6)	35 (3.4)	1
Deep dyspareunia	798 (75.9)	769 (96.4)	29 (3.6)	0.23
Non-cyclic pain	849 (80.9)	821 (96.7)	28 (3.3	0.83
Digestive complaints				
Defecation pain	723 (65.6)	697 (96.4)	26 (3.6)	0.48
Cyclic constipation	546 (49.6)	529 (96.9)	17 (3.1)	0.74
Cyclic rectorrhage	186 (16.9)	176 (96.4)	10 (3.6)	0.12
Cyclic diarrhoea	557 (50.5)	537 (96.4)	20 (3.6)	0.74
Cyclic bloating	635 (57.6)	613 (96.5)	22 (3.5)	0.87
Digestive function assessment				
KESS constipation score (mean ± SD)	13 ± 6.8	12.9 ± 6.8	14.9 ± 6.9	0.09
GIQLI (mean ± SD)	85.5 ± 21.3	85.3 ± 21.3	81 ± 22.8	0.26
Wexner score for anal continence	1.8 ± 1.2	1.8 ± 1.2	1.3 ± 1.3	0.04
Other baseline complaints				
Hydronephrosis	50 (4.5)	47 (94)	3 (6)	0.23
Digestive tract subocclusion/occlusion	140 (12.7)	132 (94.3)	8 (5.7)	0.12
Kidney atrophy <10% residual activity on DMSA scintigraphy	12 (0.6)	12 (100)	0	1
Severe bladder dysfunction	16 (1.5)	12 (75)	4 (25)	0.001

DMSA, dimercaptosuccinic acid; GIQLI, gastrointestinal quality of life index; KESS, Knowles–Eccersley–Scott–Symptom questionnaire.
*Column 1 provides percentages that relate to the whole population.
**Columns 2 and 3 provide percentages by row, which, therefore, relate to the number of cases given in the first column of the row.

Table II Intraoperative findings, surgical procedures and main immediate complications.

	Whole population* (n = 1102 (100%))	No fistula** (n = 1065 (96.6%))	Fistula** (n = 37 (3.4%))	*P*
Gynaecologist surgeon				0.29
H.R.	863 (78.3)	831 (96.3)	32 (3.7)	
B.M.	83 (7.5)	80 (96.4)	3 (3.6)	
B.R.	73 (6.6)	73 (100)	0	
Young surgeons assisted by one of above-mentioned senior surgeons	83 (7.5)	82 (98.8)	1 (1.2)	
Surgical route				0.55
Open surgery	8 (0.7)	8 (100)	0	
Laparoscopic surgery	1040 (94.4)	1005 (96.6)	35 (3.4)	
Robotic-assisted laparoscopy	27 (2.5)	27 (100)	0	
Laparoscopy followed by open route	27 (2.5)	25 (92.6)	2 (7.4)	
Operative time (min, mean ± SD)	167 ± 88	165 ± 86	229 ± 112	<0.001
Combined vaginal–laparoscopic approach	59 (5.4)	55 (93.2)	4 (6.8)	0.13
Intraoperative findings				
Deep endometriosis nodule localization				
Right USL	98 (8.9)	96 (98)	2 (2)	0.76
Left USL	162 (14.7)	157 (96.9)	5 (3.1)	1
Both USL	40 (3.6)	39 (97.5)	1 (2.5)	1
Rectovaginal space	330 (30)	323 (97.9)	7 (2.1)	0.20
Both USL and rectovaginal space	661 (60)	634 (95.9)	27 (4.1)	0.12
AFSr score (mean ± SD)	70 ± 39	71 ± 38	67 ± 41	0.65
Endometriosis stage				0.68
Stage 1	3 (0.3)	3 (100)	0	
Stage 2	130 (11.8)	124 (95.4)	6 (4.6)	
Stage 3	99 (9)	96 (97)	3 (3)	
Stage 4	870 (78.9)	842 (96.8)	28 (3.2)	
Endometriomas of the right ovary				0.18
No	656 (59.7)	630 (96)	26 (4)	
<1 cm	95 (8.6)	95 (100)	0	
1–3 cm	163 (14.8)	159 (97.6)	4 (2.4)	
>3 cm	185 (16.8)	178 (96.2)	7 (3.8)	
Endometriomas of the left ovary				0.91
No	581 (52.9)	559 (96.2)	22 (3.8)	
<1 cm	92 (8.4)	90 (97.8)	2 (2.2)	
1–3 cm	212 (19.3)	206 (97.2)	6 (2.8)	
>3 cm	214 (19.5)	207 (96.7)	7 (3.3)	
Douglas obliteration				0.84
No	67 (6.1)	66 (98.5)	1 (1.5)	
Partial	270 (24.5)	260 (96.3)	10 (3.7)	
Complete	765 (69.4)	739 (96.6)	26 (3.4)	
Fallopian tube obliteration or adhesions >2/3				
Right	160 (14.5)	153 (95.6)	7 (4.4)	0.87
Left	272 (24.7)	263 (96.7)	9 (3.3)	0.47
Digestive tract infiltration				
Sigmoid colon	432 (39.2)	417 (96.5)	15 (3.5)	0.87
Rectum	1032 (93.7)	997 (96.6)	35 (3.4)	1
Ileum	95 (8.6)	90 (94.7)	5 (5.3)	0.23
Appendix	106 (9.6)	100 (94.3)	6 (5.7)	0.15

(continued)

Table II Continued

	Whole population* (n = 1102 (100%))	No fistula** (n = 1065 (96.6%))	Fistula** (n = 37 (3.4%))	P
Rectal nodule size				0.001
<1 cm	219 (19.9)	216 (98.6)	3 (1.4)	
1–3 cm	288 (26.1)	285 (99)	3 (1)	
>3 cm	595 (54)	564 (94.8)	31 (5.2)	
Multiples colorectal localizations	362 (32.8)	349 (96.4)	13 (3.6)	0.73
Vaginal infiltration				0.039
No	567 (51.5)	555 (97.9)	12 (2.1)	
<1 cm	72 (6.5)	68 (94.4)	4 (5.6)	
1–3 cm	170 (15.4)	165 (97.1)	5 (2.9)	
>3 cm	293 (26.6)	277 (94.5)	16 (5.5)	
Bladder infiltration	85 (7.7)	84 (98.8)	1 (1.2)	0.35
Diaphragmatic localizations	174 (15.8)	171 (98.3)	3 (1.7)	0.25
Surgical procedures on digestive tract				
Procedures on the rectosigmoid				<0.001
Not done	71 (6.4)	71 (100)	0	
Shaving	351 (31.9)	348 (99.2)	3 (0.8)	
Disc excision	254 (23.1)	238 (93.7)	16 (6.3)	
Segmental resection	394 (35.8)	379 (96.2)	15 (3.8)	
Rectal disc excision + sigmoid resection	32 (2.9)	29 (90.6)	3 (9.4)	
Diverting stoma				0.001
No	862 (78.2)	843 (97.8)	19 (2.2)	
Colostoma	188 (17.6)	174 (92.6)	14 (7.4)	
Ileostoma	52 (4.7)	48 (92.3)	4 (7.7)	
Ileocolic resection	37 (3.4)	35 (94.6)	2 (5.4)	0.36
Resection of the caecum	16 (1.5)	16 (100)	0	1
Segmental resection of the ileum	25 (2.3)	24 (96)	1 (4)	0.57
Other surgical procedures				
Hysterectomy				0.28
No	932 (84.6)	897 (96.2)	35 (3.8)	
Total hysterectomy	44 (4)	44 (100)	0	
Total hysterectomy and large colpectomy	126 (11.4)	124 (88.4)	2 (1.6)	
Excision of parametriums	86 (7.8)	78 (90.7)	8 (9.3)	0.006
Including dissection/excision of sacral roots/sciatic nerve's endometriosis lesions	44 (4)	38 (86.4)	6 (13.6)	0.003
Endometrioma management				0.24
No cyst	406 (36.8)	389 (95.8)	17 (4.2)	
Cyst not treated	16 (1.5)	15 (93.8)	1 (6.2)	
Endometrioma treatment	680 (61.7)	661 (97.2)	19 (2.8)	
Surgical procedures on urinary tract				
Bladder resection	82 (7.4)	81 (98.8)	1 (1.2)	0.52
Ureterolysis for stenosis of the ureter	106 (9.6)	105 (99.1)	1 (0.9)	0.25
Resection of the ureter and reimplantation	15 (1.4)	12 (80)	3 (20)	0.01
Resection of the ureter and anastomosis	10 (0.9)	10 (100)	0	1
Intraoperative JJ stent insertion	34 (3.1)	34 (100)	0	0.63
Use of antiadhesion agents	187 (17.4)	186 (99.5)	1 (0.5)	0.02
Surgery of diaphragmatic nodules	10 (0.9)	10 (100)	0	1
Transfusion	6 (0.5)	5 (83.3)	1 (16.6)	0.19

(continued)

Table II Continued

	Whole population* (n = 1102 (100%))	No fistula** (n = 1065 (96.6%))	Fistula** (n = 37 (3.4%))	P
Immediate post-operative complications (excepted bowel fistula)				
Clavien Dindo 2	94 (8.5)	90 (95.7)	4 (4.3)	0.55
Urinary infection	16 (1.5)	16 (100)	0	1
Rectorrhage	8 (0.7)	7 (87.5)	1 (12.5)	0.24
Bladder dysfunction requiring self-catheterization over post-operative Day 7	49 (4.5)	47 (95.9)	2 (4.1)	0.68
Pelvic abscess managed by antibiotics	16 (1.5)	15 (93.8)	1 (6.2)	0.42
Clavien Dindo 3 (excepted bowel fistula)	76 (6.9)	69 (90.8)	7 (9.2)	0.01
Vaginal suture leakage	3 (0.3)	2 (66.6)	1 (33.3)	0.10
Occlusion	6 (0.5)	6 (100)	0	1
Bladder suture leakage	2 (0.2)	1 (50)	1 (50)	0.07
Stoma prolapse	7 (0.6)	6 (85.7)	1 (14.3)	0.21
Haematoma of pelvis/abdomen	6 (0.5)	6 (100)	0	1
Pelvic abscess requiring second surgery	33 (3)	30 (90.9)	3 (9.1)	0.09
Ureteral fistula	4 (0.4)	4 (100)	0	1
Other ureteral surgical procedures	4 (0.4)	4 (100)	0	1
Other abscesses (subcutaneous, ovarian, tubal)	7 (0.6)	7 (100)	0	1

USL, utero sacral ligaments.
*Column 1 provides percentages that relate to the whole population.
**Columns 2 and 3 provide percentages by row, which therefore relate to the number of cases given in the first column of the row.

Table III Independent factors related to the probability of bowel fistula (logistic regression model).

	Total (n = 1102 (100%)) n° (% of whole population)	Fistula (n = 37 (3.4%)) n° (%)	OR	95% CI	P
Procedure on the rectum*					
Shaving	351 (31.9)	3 (0.9)	1		
Disc excision	254 (23.1)	16 (6.3)	6.8	1.9–23.8	0.003
Segmental resection	394 (35.8)	15 (3.8)	4.8	1.4–16.9	0.01
Rectal disc excision + sigmoid colon resection	32 (2.9)	3 (9.3)	11	2.1–58.6	0.005
Vaginal excision					0.08
No	567 (51.5)	12 (2.1)	1		
Yes	535 (48.6)	25 (4.7)	1.9	0.92–3.9	
Excision of parametrium					0.11
No	1016 (92.2)	29 (2.9)	1		
Yes	86 (7.8)	8 (9.3)	2.1	0.8–5.2	
Ureteral reimplantation					0.09
No	1087 (98.6)	34 (3.1)	1		
Yes	15 (1.4)	3 (20)	3.5	0.8–15	

OR, odds ratio.
*OR cannot be estimated for the patient group without procedures on the digestive tract due to a lack of fistula in this group.

Regression logistic model revealed that bowel opening alone was independently related to the risk of bowel fistulae, after adjustment for vaginal excision, ureteral reimplantation into the bladder and excision of the parametrium (Table III). The incidence of post-operative fistula formation was 0.9% (3/351) when the bowel was not opened (i.e. shaving), and 5% (34/680) when it was (i.e. disc excision and/or segmental resection). Introduction into the logistic regression model of a new composite variable taking into account both vaginal excision and hysterectomy did not change the results (adjusted odds ratio of composite variable was 1.4, 95% CI 0.8–3.4, $P = 0.18$).

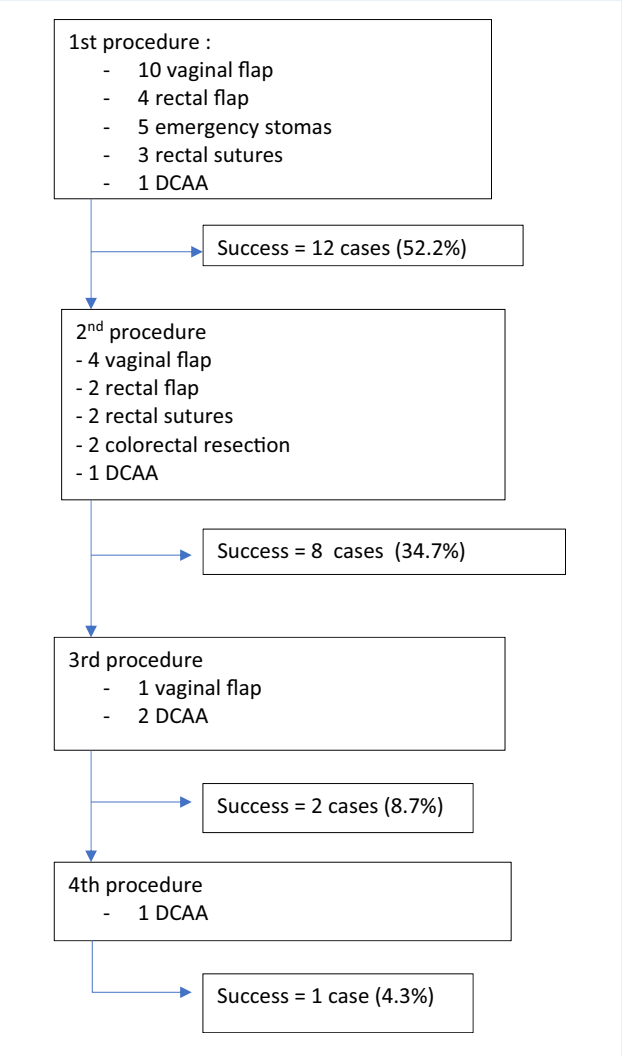

Figure 1 Management of rectovaginal fistulae (n = 23 patients). DCAA, delayed coloanal anastomosis.

Surgical approach used to treat rectovaginal fistulae is presented in Fig. 1. Stoma was preventively performed either during planned surgery (preventively in 18/23 patients or 78.3%) or during emergency surgery (5/23 patients or 21.7%), but it allowed complete healing of rectovaginal fistulae in only 2 cases out of 23 (8.7%). Vaginal and rectal flaps were carried out in 15 and 4 cases, respectively; vaginal flap was successful in only 7 cases out of 15 (46.7%) and rectal flap in no cases. Repair of bowel fistulae by suturing of edges using the abdominal route, segmental colorectal resection or DCAA were carried out in three, two and five patients, respectively and were successful in all cases. Stoma was maintained for a period varying from 6 to 25 months (median 10 months, quartiles 8 and 13 months, respectively). All patients, excepted five women managed by DCAA, underwent one supplementary surgical procedure for stoma repair.

Diverting stoma was carried out during emergency surgery in all 14 patients with bowel leakage and allowed complete healing of the fistula in 12 cases (85.7%). Two patients required additional surgery by colorectal resection (14.3%). Stoma was maintained for a period varying from 3 to 26 months (median 5 months, quartiles 3 and 6 months, respectively). All patients underwent one supplementary surgical procedure for stoma repair.

The period of time required for diverting stoma following repair of rectovaginal fistulae was significantly longer, when compared with that of leakages ($P = 0.008$).

Discussion

Our retrospective study based on the prospective collection of data in a large series of patients managed for deep endometriosis infiltrating the rectum and sigmoid colon shows that the risk of post-operative bowel fistula is relatively low. Nodule excision without bowel opening rarely leads to fistulae. Rectovaginal fistulae are perceived as more challenging to repair and require a longer period of diverting stoma, while a majority of bowel leakages are simply solved by the creation of temporary diverting stoma.

The major limit of our study relates to the heterogeneity of techniques used to remove colorectal nodules and repair fistulae. This weakness results from the design of our study which is observational and employs data prospectively recorded in a cohort of patients managed for endometriosis. Deep endometriosis is a complex disease with multiple localizations; when rectum and sigmoid colon are involved, there is a large variation in length, width, depth and height of bowel infiltration, which require an individual surgical approach using various procedures, such as shaving, full-thickness disc excision or colorectal resection (Donnez and Roman, 2017). This individual approach not only takes into account nodule features but also patient characteristics (age, parity, association with effective medical treatment for some symptoms) and specific procedure-related risks, such as risk of LARS following low segmental colorectal resection or risk of rectovaginal fistulae following vaginal excision. Rectovaginal fistulae and leakages are severe complications and their characteristics may vary requiring several surgical approaches to repair them (Corte *et al.*, 2015).

The second limit is related to the involvement of a small number of centres, and that a majority of patients were managed by one surgeon. Young surgeons performed surgery in 83 patients (7.5%) with one recorded case of fistula, but as they were supervised by two of the three aforementioned senior surgeons, their involvement is unlikely to jeopardize our results. Furthermore, bowel sutures were carried out by general surgeons with extensive experience in management of benign or malignant colorectal diseases. Thus, the generalizability of our findings is limited because all procedures were performed or strictly supervised by very expert surgeons.

The third limit concerns the lack of accurate information on colorectal nodule levels and the height of the nodule or the suture or anastomosis in relation to the anal verge, which may have a considerable influence on the incidence of anastomotic leakage (Ret Davalos *et al.* 2007, Trencheva *et al.*, 2013). Our cohort numbers have been increasing since 2009 and new items added to questionnaires. One such item concerns rectal nodule height, which has been recorded since 2014 and is only available in 762 patients (69.1%). We have not been able to include these data in our study, as by applying the regression model it would exclude the remaining 30.9% of patients with missing data.

The fourth limit is related to patients' selection criteria. Patients with incomplete bowel surgery were mentioned in the study, because the goal was to assess the risk of bowel fistula in patients surgically managed for endometriosis infiltrating the rectum and the sigmoid colon. These patients with incomplete procedures on the bowel had, however, bowel adhesiolysis and releasing, in various degrees required by the main procedure performed on localizations responsible for infertility, hydronephrosis, pelvic nerve pain or deep dyspareunia, which could, in theory, lead to bowel fistula. The rate of patients with incomplete bowel surgery was low (6.4%) and they were not considered in the logistic regression model which assessed independent risk factors for fistula. Excluding the 71 women with incomplete bowel surgery from the denominator would increase the incidence of post-operative fistula formation from 3.4% to 3.9%. On the other hand, the presence of this group showed that our surgical approach in bowel endometriosis was individualized and symptom-guided.

Our population is provided by a large prospective cohort, which started enrolment in 2009. Patients' enrolment has been prospective, and data management was rigorous, carried out by dedicated clinical researchers. This cohort has served to numerous clinical researches which led to the publication of several scientific papers, focussing on various strategies of management and outcomes of ovarian, colorectal, deep or superficial endometriosis, however, may have somewhat higher possibility of each study had specific endpoints. As the cohort's population has continuously increased from 2009 to 2020, consecutive studies have provided progressively larger samples, and potential overlap between studies was logical.

Our study presents several strengths. Patients were prospectively enrolled in a cohort and benefitted from rigorous follow-up and detailed recording of pre-, intra- and post-operative data. Data were managed by dedicated research technicians, avoiding patient lost to follow-up and lending support to the accuracy of the data and the validity of our results. Surgeons involved in the management of both colorectal nodules and fistulae had extensive experience which would have favoured good post-operative outcomes.

The external validity of our study is supported by comparison with data in the literature. Fistula prevalence in our series is comparable to that reported in the review of Meuleman *et al.* (2011): in 2036 patients managed by bowel resection, there were recorded 55 (2.7%) rectovaginal fistulae and 30 (1.5%) anastomotic leakages, resulting in a total of 4.2% bowel fistula. In 1799 patients in majority managed by shaving, there were recorded 12 (0.7%) rectovaginal fistulae and 12 (0.7%) anastomotic leakages, leading to an overall rate of 1.4%. The authors noted that bowel fistulae were treated with colostomy/loop ileostomy, Hartmann surgery or resuture (Meuleman *et al.*, 2011). In a large monocentric series of 750 patients managed for deep endometriosis infiltrating the rectum up to 10 cm above the anal verge, overall rate of bowel fistula was 5% (Ruffo *et al.*, 2010). The review of Abrao *et al.* (2015) pooled together 122 articles reporting a wide variation in fistula prevalence, from 0 to 14%.

In our opinion, rectovaginal fistula and bowel leakage would ultimately be different clinical presentations of bowel fistula; in the first case the vagina has also been excised, thus bowel and vaginal sutures become communicant and thus stools are exteriorized through the vagina; in the second case the vagina is intact and stools are exteriorized into the abdominal cavity. For this reason, we think it is logical to consider them together, as the ratio rectovaginal fistula: bowel leakage depends on the frequency of vaginal excision in various series.

It is very likely that our results apply, in priority, to surgical teams reporting a balanced use of the three techniques: shaving, disc excision and segmental resection. In these circumstances, disc excision and segmental resection are probably employed in patients with larger nodules, in which the surgeon feels that shaving would be less suitable or less complete. Conversely, different team which may be pushing the limits of shaving to reduce the number of resections may have somewhat higher possibility of fistula following shaving. This theory should, however, be demonstrated, because other surgeons reported low rate of fistula despite a large use of shaving (Donnez and Squifflet, 2010).

We found that performing rectal excision with bowel opening was the only factor independently related to risk of fistula. Although fistulae may occur in patients managed by shaving, the probability of presenting post-operative fistulae increases almost five-fold when colorectal resection is carried out and seven-fold following disc excision. A high risk of rectal fistula after disc excision is not astonishing, as it included 80 patients with deep endometriosis infiltrating the low rectum, who required disc excision using the Rouen technique (Roman *et al.*, 2017), where the infiltration of adjacent vagina routinely required concomitant large vaginal excision.

Cumulative risks related to performing sutures twice, for patients undergoing both low rectal disc excision and short segmental resection of the sigmoid colon, logically increases the risk of fistula 11-fold when compared to shaving. In our opinion, the decision to perform combined disc excision on low rectum with segmental resection on the sigmoid colon could provide a way to avoid long segmental resection, including of the mid and low rectum, and thus could reduce the risk of LARS (Millochau *et al.*, 2018). Although our randomized trial did not reveal differences in outcomes between disc excision and colorectal resection, it should be mentioned that it reported women undergoing short segmental resections, averaging 10 cm (Roman *et al.*, 2018). Consequently, our trial's conclusions should not be extrapolated to extensive segmental resections (over 20 cm), particularly when the colorectal anastomosis is located on low or mid rectum. For this reason, we believe that a combined disc excision and short segmental resection of sigmoid colon may be proposed in women with multiple nodules, in order to avoid a LARS. Our data show that this choice is linked to a probability of fistula double that associated with *en bloc* segmental resection; information that should be provided to women undergoing surgery for multiple rectosigmoid nodules.

A logical tendency towards a higher risk of fistulae related to vaginal excision was noted. Statistical significance was however not attained due to the occurrence of fistulae in women free of vaginal excision and to related leakage of bowel sutures. Performing vaginal excision results in rectovaginal fistulae which are perceived as more challenging to repair. Notably, vaginal excision is required in women with deep endometriosis infiltrating the vagina, which is usually responsible for deep dyspareunia. Smoking was not related to the risk of fistula, despite existing evidence of its negative impact on post-operative healing and fistula occurrence (Sørensen, 2012). Similarly, antecedents of pelvic and abdominal surgery were not related to risk of fistula, despite a logical increase in difficulty of dissection and operative time in women with extensive fibrosis or adhesions due to previous surgeries (Zarzavadjian le Bian *et al.*, 2019). Univariate analysis revealed other

factors such as severe pre-operative bladder dysfunction, rectal nodule size over 3 cm, excision of parametria, associated reimplantation of ureters and operative time, to be significantly associated with the risk of fistula; however, multivariate analysis did not confirm a statistically significant independent relationship. As these are markers of more severe disease, they logically render surgery more challenging.

Lower risk of fistula found in women aged over 35 may be explained by our approach. We propose first-line shaving to a majority of older women for whom the risk of recurrence is expected to be low, as they usually do not intend to conceive and agree to a continuous intake of contraceptive pill or progestins until menopause (Roman *et al.*, 2016b). This approach allows a decrease in both the rate of post-operative complications and recurrences (Donnez and Roman, 2017).

Fistula repair involves prompt diversion of stools through diverting stoma, in those women who did not receive diverting stoma during the first surgery. Our study, therefore, demonstrates that a stoma was sufficient to allow fistula repair in a majority of patients with leakage, and only incidentally in women with rectovaginal fistulae. The repair of rectovaginal fistulae was much more challenging, required multiple additional procedures in almost half the cases and a longer period until stoma closure. The presence of vaginal opening in contact with bowel fistulae appears to be an obstacle to the natural healing of a digestive tract opening. This information should not, however, provide an argument in support of incomplete vaginal endometriosis excision, as such a strategy could lead to worse results in terms of dyspareunia improvement and a higher rate of recurrences.

In patients with large rectovaginal nodules, complete removal of disease requires both anterior low rectal resection and concomitant excision of the posterior vaginal fornix. There is an increase of the risk of rectovaginal fistula when bowel and vaginal sutures are juxtaposed, thus several teams routinely employ the diverting stoma in such circumstances (Belghiti *et al.*, 2014). It has been suggested that preventive stoma in patients with concomitant suture of the rectum and vagina may reduce the frequency and the severity of rectovaginal fistulae (Belghiti *et al.*, 2014), as has been demonstrated in low rectal cancer surgery (Matthiessen *et al.*, 2007; Choude *et al.*, 2008; Shiomi *et al.*, 2015). However, when preventive stoma is employed, a second surgery should be planned to close the stoma and restore the digestive tract. Specific morbidity is associated with preventive stoma, including residual pain, incisional hernias, subcutaneous infections, aesthetic harm. Furthermore, preventive temporary stoma in patients with endometriosis is responsible for specific complications requiring surgical management in 8% of cases (Bonin *et al.*, 2019). For these reasons, its benefit in patients with deep endometriosis is still debated (Loriau *et al.*, 2018). A definitive answer can be provided only by a further randomized trial including patients managed for deep endometriosis infiltrating the rectum.

The management of rectovaginal fistulae has been shown to be challenging (Corte *et al.*, 2015). There is a lack of data in the literature focussing on the management of rectovaginal fistulae following surgery for rectovaginal endometriosis. In large series of 79 patients managed for rectovaginal fistulae for various aetiologies, Corte *et al.* reported an overall success rate of 72%. The overall procedure success in our series was of 100% and is most likely explained by patient characteristics (young women, lack of associated morbidity, control of endometriosis-related inflammation by continuous hormonal treatment). Our results are concordant with those reported by Corte *et al.* and revealed higher success rates associated to techniques using the abdominal approaches vaginal than that related to vaginal or rectal flaps using transvaginal or transrectal approaches. Although vaginal and rectal advancement flaps are considered to have a low success rate, they have low intra- and post-operative morbidity and involve natural orifice approaches. Consequently, they can be considered as first-line surgical procedures to repair rectovaginal fistulae (Corte *et al.*, 2015). Conversely, abdominal procedures though efficient, require a laparoscopic or open approach, leading to a risk of intraoperative or immediate post-operative complications, followed by a longer period of recovery, and should be reserved to women with unsuccessful first-line procedures.

Conclusion

Our series shows that, in experienced hands, deep endometriosis infiltrating the rectum and sigmoid colon can be managed laparoscopically with a relatively low risk of bowel fistula. Performing colorectal disc excision or segmental resection increases the risk of fistula when compared to excision with no opening of bowel lumen. Thus, when the type of bowel procedure can be chosen, performance of shaving instead of disc excision or colorectal resection is suggested considering the lower risk of bowel fistula. However, such a choice may not always be feasible unless one would accept incomplete nodule removal in an important proportion of patients. The repair of rectovaginal fistula is more challenging than that for bowel leakage and may require up to four additional surgical procedures.

Acknowledgements

The authors are grateful to Amélie Bréant and Sophie Marinette for the management of data and Helene Braund for her help in editing the manuscript.

Authors' roles

H.R. designed the trial, performed the surgery and wrote the first draft of the manuscript. B.M., B.R., D.F., V.B., R.C., J.C. and J.-J.T. performed the surgery. H.R. and V.B. performed data collection. All the authors contributed to the final manuscript.

Funding

The North-West Inter Regional Female Cohort for Patients with Endometriosis (CIRENDO) is financed by the G4 Group (The University Hospitals of Rouen, Lille, Amiens and Caen) and ROUENDOMETRIOSE Association. No financial support was received for this study.

Conflict of interest

H.R. reports personal fees from ETHICON, Plasma Surgical, Olympus and Nordic Pharma outside the submitted work. The other authors declare no conflict of interests related to this topic.

References

Abo C, Moatassim S, Marty N, Saint Ghislain M, Huet E, Bridoux V, Tuech JJ, Roman H. Postoperative complications after bowel endometriosis surgery by shaving, disc excision, or segmental resection: a three-arm comparative analysis of 364 consecutive cases. *Fertil Steril* 2018;**109**:172–178.

Abrao MS, Petraglia F, Falcone T, Keckstein J, Osuga Y, Chapron C. Deep endometriosis infiltrating the recto-sigmoid: critical factors to consider before management. *Hum Reprod Update* 2015;**21**:329–339.

Belghiti J, Ballester M, Zilberman S, Thomin A, Zacharopoulou C, Bazot M, Thomassin-Naggara I, Daraï E. Role of protective defunctioning stoma in colorectal resection for endometriosis. *J Minim Invasive Gynecol* 2014;**21**:472–479.

Bonin E, Bridoux V, Chati R, Kermiche S, Coget J, Tuech JJ, Roman H. Diverting stoma-related complications following colorectal endometriosis surgery: a 163-patient cohort. *Eur J Obstet Gynecol Reprod Biol* 2019;**232**:46–53.

Choude GG, Rayate NV, Patris V, Koshariya M, Jagad R, Kawamoto J, LygidakisNJ. Defunctioning loop ileostomy with low anterior resection for distal rectal cancer: should we make an ileostomy as a routine procedure? A prospective randomized study. *Hepatogastroenterology* 2008;**55**:1562–1567.

Corte H, Maggiori L, Treton X, Lefevre JH, Ferron M, Panis Y. Rectovaginal fistula: what is the optimal strategy?: An analysis of 79 patients undergoing 286 procedures. *Ann Surg*. 2015;**262**:855–860.

Donnez O., Roman H. Choosing the right surgical technique for deep endometriosis: shaving, disc excision, or bowel resection? *Fertil Steril* 2017;**108**:931–942.

Donnez J, Squifflet J. Complications, pregnancy and recurrence in a prospective series of 500 patients operated on by the shaving technique for deep rectovaginal endometriotic nodules. *Hum Reprod* 2010;**25**:1949–1958.

Emmertsen KJ, Laurberg S. Low anterior resection syndrome score: development and validation of a symptom-based scoring system for bowel dysfunction after low anterior resection for rectal cancer. *Ann Surg* 2012;**255**:922–928.

Loriau J, Petit E, Mephon A, Angliviel B, Sauvanet E. Evidence-based ways of colorectal anastomotic complications prevention in the setting of digestive deep endometriosis resection: CNGOF-HAS Endometriosis Guidelines. *Gynecol Obstet Fertil Senol* 2018;**46**: 296–300.

Matthiessen P, Hallböök O, Rutegård J, Simert G, Sjödahl R. Defunctioning stoma reduces symptomatic anastomotic leakage after low anterior resection of the rectum for cancer: a randomized multicenter trial. *Ann Surg* 2007;**246**:207–214.

Meuleman C, Tomassetti C, D'Hoore A, Van Cleynenbreugel B, Penninckx F, Vergote I, D'Hooghe T. Surgical treatment of deeply infiltrating endometriosis with colorectal involvement. *Hum Reprod Update* 2011;**17**:311–326.

Millochau JC, Stochino-Loi E, Darwish B, Abo C, Coget J, Chati R, Tuech JJ, Roman H. Multiple nodule removal by disc excision and segmental resection in multifocal colorectal endometriosis. *J Minim Invasive Gynecol* 2018;**2**:139–146.

Netter A, D'Avout-Fourdinier P, Agostini A, Chanavaz-Lacheray I, Lampika M, Farella M, Hennetier C, Roman H. Progression of deep infiltrating rectosigmoid endometriotic nodules. *Hum Reprod* 2019;**34**:2144–2152

Ret Davalos ML, De Cicco C, D'Hoore A, De Decker B, Koninckx PR. Outcomes after rectum or sigmoid resection: A review for gynecologists. *J Minim Invasive Gynecol* 2007;**14**:33–38.

Riiskjaer M, Greisen S, Glavind-Kristensen M, Kesmodel US, Forman A, Seyer-Hansen M. Pelvic organ function before and after laparoscopic bowel resection for rectosigmoid endometriosis: a prospective, observational study. *BJOG* 2016;**123**:1360–1367.

Roman H, Milles M, Vassilieff M, Resch B, Tuech J-J, Huet E, Darwish B, Abo C. Long-term functional outcomes following colorectal resection versus shaving for rectal endometriosis. *Am J Obstet Gynecol* 2016a;**215**:762.e1–762.e9.

Roman H, Moatassim-Drissa S, Marty N, Milles M, Vallée A, Desnyder E, Stochino Loi E, Abo C. Rectal shaving for deep endometriosis infiltrating the rectum: a 5-year continuous retrospective series. *Fertil Steril* 2016b;**106**:1438–1445.

Roman H, Darwish B, Bridoux V, Chati R, Kermiche S, Coget J, Huet E, Tuech JJ. Functional outcomes after disc excision in deep endometriosis of the rectum using transanal staplers: a series of 111 consecutive patients. *Fertil Steril* 2017;**107**:977–986.

Roman H, Bubenheim M, Huet E, Bridoux V, Zacharopoulou C, Daraï E, Collinet P, Tuech JJ. Conservative surgery versus colorectal resection in deep endometriosis infiltrating the rectum: a randomized trial. *Hum Reprod* 2018;**33**:47–57.

Ruffo G, Scopelliti F, Scioscia M, Ceccaroni M, Mainardi P, Minelli L. Laparoscopic colorectal resection for deep infiltrating endometriosis: analysis of 436 cases. *Surg Endosc* 2010;**24**:63–67.

Scattarelli A, Carriou M, Boulet L, Chati R, Coget J, Bridoux V, Tuech JJ, Roman H. C-reactive protein assessment to predict early septic complications after laparoscopic bowel resection for endometriosis: a diagnostic study. *BJOG* 2019;**126**:1176–1182.

Shiomi A, Ito M, Maeda K, Kinugasa Y, Ota M, Yamaue H, Shiozawa M, Horie H, Kuriu Y, Saito N. Effects of a diverting stoma on symptomatic anastomotic leakage after low anterior resection for rectal cancer: a propensity score matching analysis of 1,014 consecutive patients. *J Am Coll Surg* 2015;**220**:186–194.

Sørensen LT. Wound healing and infection in surgery. The clinical impact of smoking and smoking cessation: a systematic review and meta-analysis. *Arch Surg* 2012;**147**:373–383.

Trencheva K, Morrissey KP, Wells M. Identifying important predictors for anastomotic leak after colon and rectal resection: prospective study on 616 patients. *Ann Surg* 2013;**257**:108–113.

Vercellini P, Eskenazi B, Consonni D, Somigliana E, Parazzini F, Abbiati A, Fedele L. Oral contraceptives and risk of endometriosis: a systematic review and meta-analysis. *Hum Reprod Update* 2011; **17**:159–170.

Zarzavadjian le Bian A, Genser L, Denet C, Ferretti C, Laforest A, Ferraz JM, Tubbax C, Wind P, Gayet B, Fuks D. Safety and feasibility of repeat laparoscopic colorectal resection: a matched case-control study. *Surg Endosc* 2020;**34**:2120–2126.