

A Systematic Review of Cutaneous Dog Ear Deformity: A Management Algorithm

Ajaipal S. Kang, MD, FACS*
Kevin S. Kang, BS†

Background: Dog ear, a characteristic bunching up of excess tissue formed during wound closure, is a common unsightly problem in cutaneous surgery. It may present as a cosmetic concern or a source of physical discomfort. Several management techniques have been reported, but it is unclear which approach is the most effective or whether outcomes vary with surgical situations. This report assesses the best practices for dog ear management.

Methods: A systematic literature search was performed. All relevant articles written in English and involving human subjects were included.

Results: There were 2028 potentially relevant articles, but only 36 articles met the inclusion criteria. These articles were published in multispecialty journals. They included 23 techniques or case report articles, 6 retrospective and prospective studies, but no clinical trial or randomized control trial. Ten major techniques were identified in the literature. No single technique was proved to be superior in the literature. There was no recommended algorithm in the literature.

Conclusions: Despite there being no single recommended technique to manage dog ear deformities, there is ample evidence to suggest surgeons avoid a pre-planned elliptical design, use a proper skin-conserving design for excision, and carry out a meticulous suture closure as the first steps to prevent dog ears. We discuss the indications for each of the ten techniques and propose an algorithm for dog ear management. Until further research is performed, multispecialty cutaneous surgeons should familiarize themselves with the discussed techniques to provide patients with the best functional and aesthetic results. (*Plast Reconstr Surg Glob Open* 2020;8:e3102; doi: [10.1097/GOX.00000000000003102](https://doi.org/10.1097/GOX.00000000000003102); Published online 23 September 2020.)

INTRODUCTION

Although dog ear sounds like a slang term, it is deeply entrenched in the literature.¹ Limberg² first described the dog ear as a conical tissue deformation. Dog ears are always idiopathic with the extent of the deformity influenced by defect shape, lesion location, and skin elasticity.¹ Despite strict adherence to wound geometry, it is not always possible to prevent dog-ear formation.³

Patients often find dog ears aesthetically objectionable^{3,4} and sometimes report pain and discomfort.⁵⁻⁷ For example, a lateral breast dog ear is frequently seen in breast surgery patients with a high body mass index

(>30).^{6,8} Such dog ears may cause chafing, a sensation of fullness or heaviness, interference with arm movement, and difficulty fitting a brassiere or clothing.^{7,9} This issue may also be a source of litigation by disappointed patients.¹ As functionality and a good cosmetic outcome contribute to the quality of the operation, mastering surgical techniques that limit dog ear deformity is essential for cutaneous surgeons.¹⁰

The basic problem underlying dog ear formation is unequal lengths of the wound. The goal is to “adjust” the longer side to match the shorter side. In most instances, this involves removal of some tissue to improve contour at the expense of increased scar length.

While it is not always possible to prevent dog ear deformity, over the past five decades, various surgical techniques have been reported. We reviewed the literature to determine whether there is a “best” standardized surgical technique that functionally and aesthetically corrects dog ear without significantly extending the length of the original wound. No optimal technique is recommended for all cases. However, existing techniques are appropriate in specific contexts. We review the indications for each

From the *Department of Surgery and Chief of Plastic Surgery, UPMC Hamot, Erie, Pa.; and †Geisel Dartmouth Medical School, Hanover, N.H.

Received for publication May 14, 2020; accepted July 21, 2020.

Copyright © 2020 The Authors. Published by Wolters Kluwer Health, Inc. on behalf of The American Society of Plastic Surgeons. This is an open-access article distributed under the terms of the [Creative Commons Attribution-Non Commercial-No Derivatives License 4.0 \(CCBY-NC-ND\)](https://creativecommons.org/licenses/by-nc-nd/4.0/), where it is permissible to download and share the work provided it is properly cited. The work cannot be changed in any way or used commercially without permission from the journal.

DOI: [10.1097/GOX.00000000000003102](https://doi.org/10.1097/GOX.00000000000003102)

Disclosure: The authors have no financial interest to declare in relation to the content of this article.

technique and propose an algorithm to guide surgeons based on the clinical situation.

MATERIALS AND METHODS

A systematic literature search was conducted with Pubmed and CINHAL databases on May 7, 2020, using the search terms, “dog ear,” “dog ear correction,” “dog ear deformity,” “dog ear management,” “lateral breast dog ear,” and “breast dog ear” by two reviewers independently. We also used the ‘related articles’ search function to review more articles. All abstracts, studies, and citations were reviewed. There were no limits on the years of publication. We excluded articles involving non-cutaneous dog ears, videos only, and conference abstracts. We also excluded articles in which dog ear management and treatment were not the focus of the study. If there was disagreement about the suitability of the article, the two reviewers discussed and reached a consensus.

Only relevant peer-reviewed English language articles involving human subjects were included in our final analysis. We evaluated literature for techniques and the

pros, cons, and applicability of those techniques. The results were summarized and evaluated to determine if there is any standardized surgical technique that is consistently superior than others. The data were analyzed in a descriptive manner in accordance with the best practice as described by the Preferred Reporting Items for Systematic Reviews and Meta- Analyses (PRISMA) statement.¹¹

RESULTS

The literature search with our selected terms for dog ear management returned 2028 potential articles published between 1969¹² and 2019.⁶ After excluding those that clearly did not involve human subjects, 561 remained. Of these, 481 articles were in the English language. We then excluded an additional 327 articles focused on animal, non-clinical, or basic science studies or non-cutaneous dog ears. Of the 154 remaining articles, we excluded those that were video only, without abstracts, and/or without dog ear management as the primary focus. This left 36 English language, human subject clinical articles that primarily addressed cutaneous dog ears (Fig. 1). Of

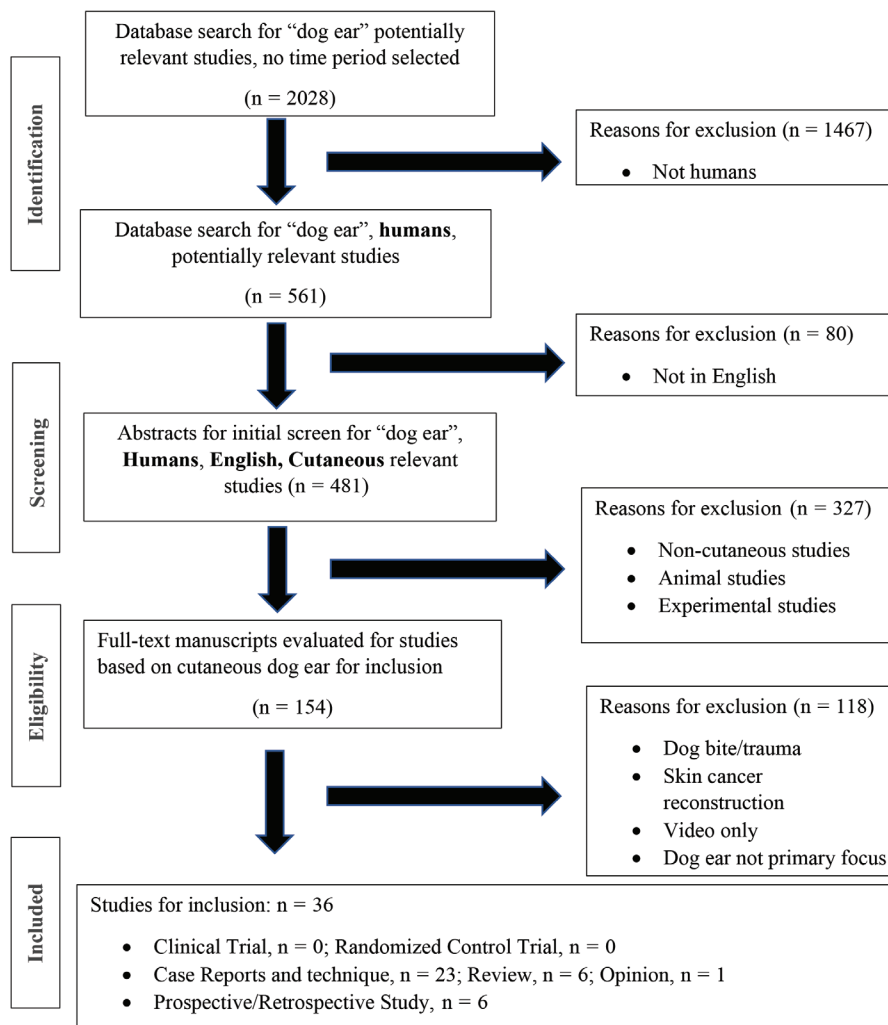


Fig. 1. PRISMA flow diagram of included studies.



these articles, 8 were published in Plastic Surgery,¹⁻¹⁸ 9 in Breast Surgery,^{5-8,10,19-22} 18 in Dermatology,^{3,23-38} and 1 in Otolaryngology³⁹ specialty journals (Fig. 2). The data revealed 23 case reports and articles related to surgical techniques, 6 review articles, and 1 opinion article (Fig. 3). The surgical techniques discussed included various suture methods,^{4,13,24,26,27,30} designs to prevent dog ears,^{14,20} triangular flaps,¹⁰ Y-shaped closures,^{8,21,22} de-epithelization,¹⁵ and oncoplastic closure.¹⁹

We found six retrospective and prospective articles in the literature^{5,7,22,29,35,39} summarized in Table 1. Levels of evidence for all identified articles were 4 and 5. We did not find any clinical trial or randomized control trials in the literature. Review of the 36 articles did not provide any evidence that one technique to address dog ear was superior to any other technique. Furthermore, there were no published algorithms for management of dog ears. Given the lack of data in the literature, meta-analysis was not possible.

DISCUSSION

Cause

A well-known surgical principle states that wounds sutured without tension give the best cosmetic and functional scarring. Conversely, a wound closed under excessive tension may cause central depression and vertical displacement of the corners, resulting in a dog ear deformity.⁴⁰ The closure of any circular or asymmetric wound results in an outward and upward protrusion of tissue. As the wound is closed, the central portion moves closer under tension, while the corners experience rotational and compression forces that act against wound closure. Tissue rotation and compression produce some degree of apical redundancy, and once this redundancy exceeds the skin's ability to "absorb," the outward and upward protrusion of tissue causes a dog ear deformity.^{34,37} Borges describes the corners of such wounds as "tension in reverse," which hinders closure and leads to dog ear formation.¹⁸

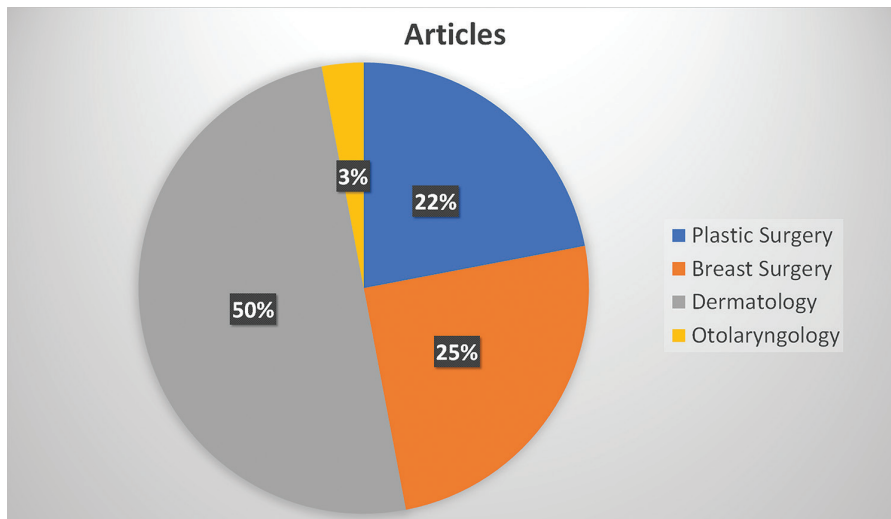


Fig. 2. The distribution of the published dog ear articles based on specialty.

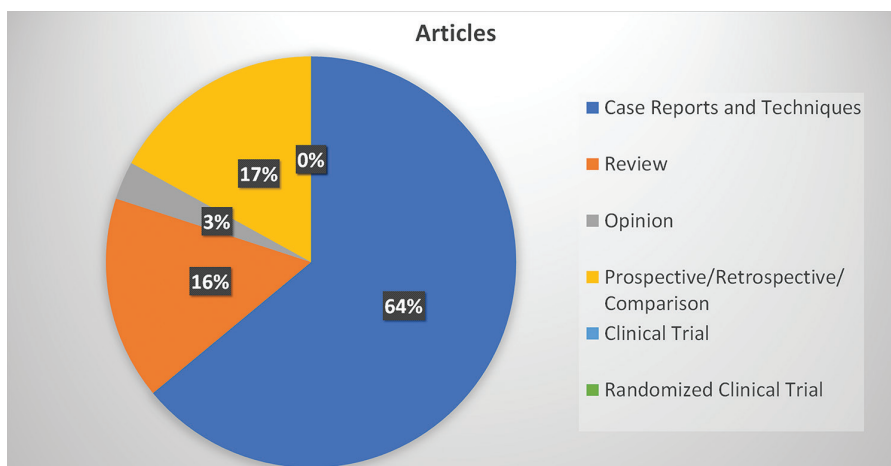


Fig. 3. The distribution of the published dog ear articles based on study type.

Table 1. Summary of the Prospective/Retrospective Studies on Dog Ears

Author	No. Subjects	Methods	Results	Conclusions	Was One Best Technique Proved?
Hudson-Peacock et al ³⁵	51 patients	Prospective Comparison of elliptical excision versus excision and dog ear removal	For excision and dog ear removal, sutured wound length was 21% shorter and wound direction was different in 45% of cases	Excision and dog ear removal results in shorter and better-oriented scars than elliptical excision.	No
Lee et al ²⁹	26 patients, 43 dog ears	Prospective Uncorrected dog ears were observed for 6 mo	Younger and female patients had most regression of dog ear	For dog ears less than 8 mm, recommend observation	No
Szynglarewicz et al ⁷	117 patients	Prospective Y-shaped incision to eliminate lateral breast dog ear	Skin flap necrosis 2, hematoma 1, surgical site infection 1	Yincision eliminates dog ear	No
Lee et al ³⁹	7 fresh cadavers	Prospective Comparison of fusiform excision versus CDDE	Final length was shorter with CDDE	CDDE minimized tissue excision and decreased final length	No
Jennings et al ²³	77 patients, 140 dog ears	Prospective Uncorrected dog ears were observed for 6 mo	81% dog ears showed complete resolution	Dog ears smaller than 4 mm on the trunk and hands may be observed	No
Hill et al ⁶	112 patients	Retrospective AWI technique for lateral breast dog ear	No arm restrictions or pain	AWI results in smooth contour	No

AWI, Angel Wing Incision; CDDE, circular defect/dog ear excision.

Dog ears may form whenever the wound has a length–width ratio of less than 3–4:1, unequal opposite side lengths, or large apical angles.⁴¹ Dog ears are classified as standing cones or lying cones.² Standing cones, the more common type, typically occur during the closure of symmetric wounds and form at right angles to the skin surface. Correction of a standing cone may require a symmetric excision of a fusiform segment of skin.¹ In contrast, closure of an asymmetric wound results in a lying cone along the longer side, which is parallel to the skin surface. Correction may require an asymmetric maneuver such as excision of a triangular piece of skin.⁴² Common locations for dog ear formation include the face, due to the tendency to limit the size of excision; the trunk and breast (where long scars are closed under tension); and along convex surfaces such as the extremities and mandible (where a simple linear closure is likely to buckle and shorten with time).⁴¹

Dog ear formation is further affected by skin elasticity and tension, surgical technique, tissue dynamics, wound geometry, anatomical location, and surface contour, as well as individual patient characteristics.^{3,37,43} Even with identical excision design, patient age, skin quality, and skin damage will dictate the presence or absence of dog ears.³⁷

Management

Prevention: Planning and Intraoperative Maneuvers

Prevention is the one element that can be standardized in any operation. Proper planning of the surgical wound can reduce the likelihood of a dog ear formation. Elliptical excision is widely used for benign and malignant skin lesion excision.⁴⁴ The ellipse is pre-marked and designed 3–4 times longer than the width with vertex

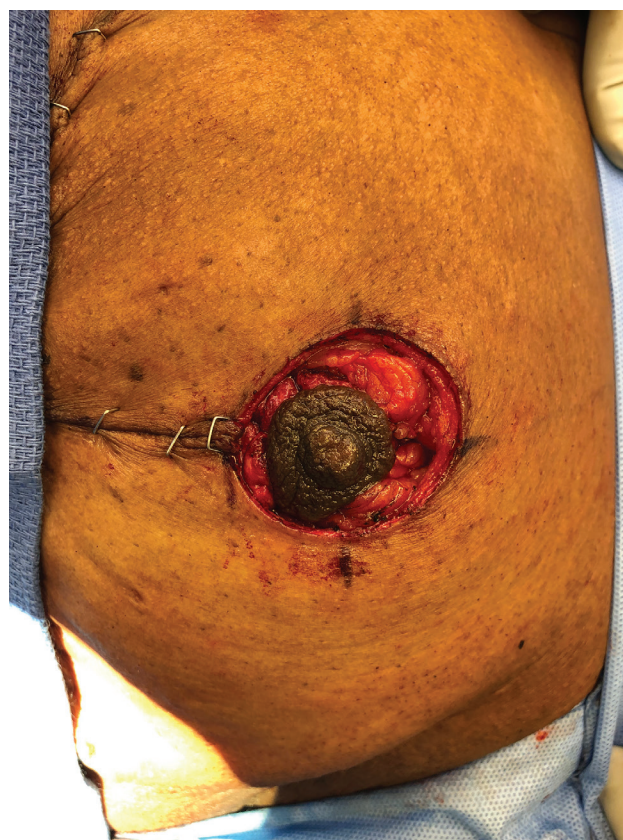

Fig. 4. Rule of halves. Intra-operative anterior view of the left breast, with pre-closure nipple–areola inset. Note the unequal wound lengths with a shorter areola side length and a longer breast side length. For orientation, the patient’s head is at the top and feet are at the bottom of the photograph.

angles less than 30 degrees. This presets the length and orientation of the scar. But as is evident, this needlessly creates a 3-4 times longer and wastes healthy skin.^{18,45} Waste of healthy skin is uneconomical and at the expense of any future need for reconstruction.⁴⁵

The area of wasted healthy skin in an elliptical excision is well studied. A report of 26 excisional biopsy specimens showed that the mean skin waste was 130%.⁴⁵ Furthermore, in a study comparing skin waste, in common pattern of excisions, the smallest skin waste occurred with rhomboid and mosque patterns, whereas the largest skin waste occurred with fusiform ellipse and fusiform circle excisions.⁴⁶

Some authors proposed a circular excision instead of a preplanned fusiform excision.^{47,48} A study of 51 patients showed that the excision and dog ear repair scar lengths were shorter with circular excisions than elliptical excisions. Circular excisions were also better oriented and preserved more healthy normal skin.^{3,35} Lee et al came to a similar conclusion in their cadaver study comparing circular excision and dog ear excision with fusiform excision. Circular excision and dog ear excision resulted in a shorter incision and a greater tissue preservation.³⁹ (Table 1).

In addition to excision design, intraoperative maneuvers may help reduce dog ear formation. These include

maintaining the scalpel blade at 90° angle with respect to the skin,⁴⁹ properly undermining a shallow wound, and precise closure.^{3,40,49} However, if despite these maneuvers, a dog ear is formed, the best time to deal with it at the time of initial surgery.¹

Management: Techniques and Common Indications

Major approaches for dog ear management and their common indications are described below in increasing complexity. Specific techniques applicable to the unique characteristics of the lateral breast dog ear are also highlighted.

Observation/Spontaneous Regression

Some dog ears, termed false dog ears, resolve spontaneously. Spontaneous regression is generally achieved in the setting of good skin recruitment capacity and mobility over firm surfaces such as the skull and hand.³⁴ The height of the dog ear also impacts the likelihood of spontaneous resolution; those below 8mm more likely to resolve over time.²⁹ A recent study of 140 dog-ears observed over 6 months concluded that observation resulted in good cosmetic outcomes for dog ears on the one hand and for small dog ears on the trunk (≤ 4 mm).²³ However, dog ears on the head, neck, chest, or breast were less likely to

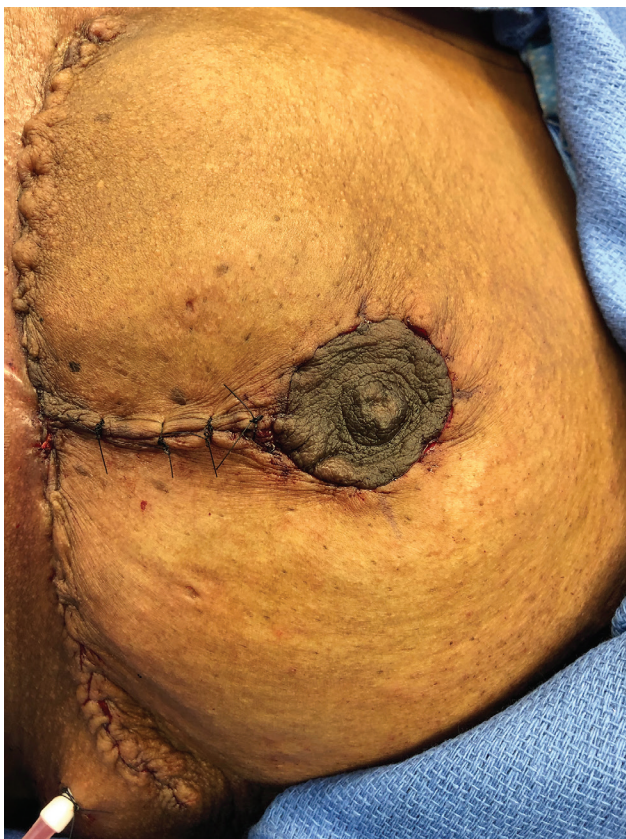

Fig. 5. Rule of halves. Intra-operative anterior view of the left breast, with post-closure nipple-areola inset. For orientation, the patient's head is at the top and feet are at the bottom of the photograph.

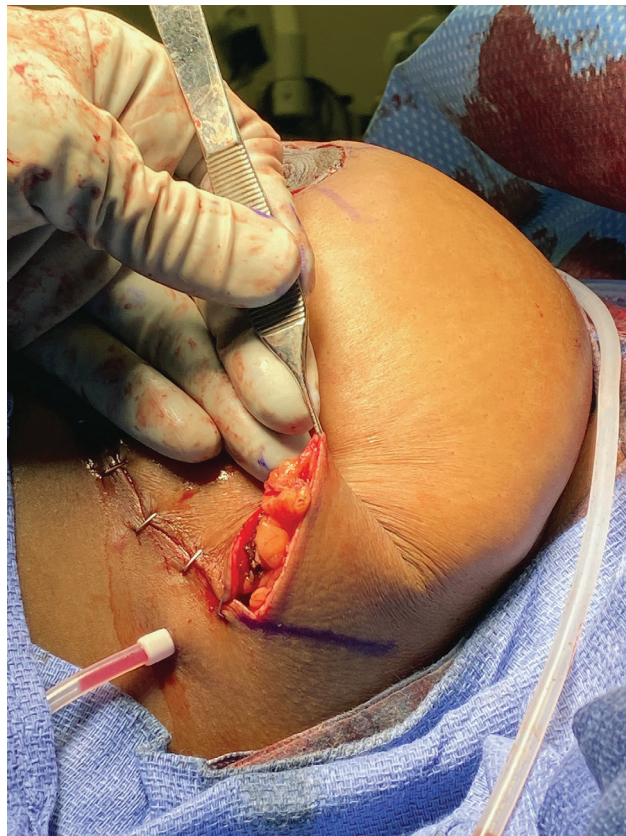

Fig. 6. Hockey stick extension. Intra-operative, lateral view of the left lateral breast dog ear. Marking in blue shows 120-degree hockey stick line extension. For orientation, the patient's head is at the right and feet are at the left of the photograph.

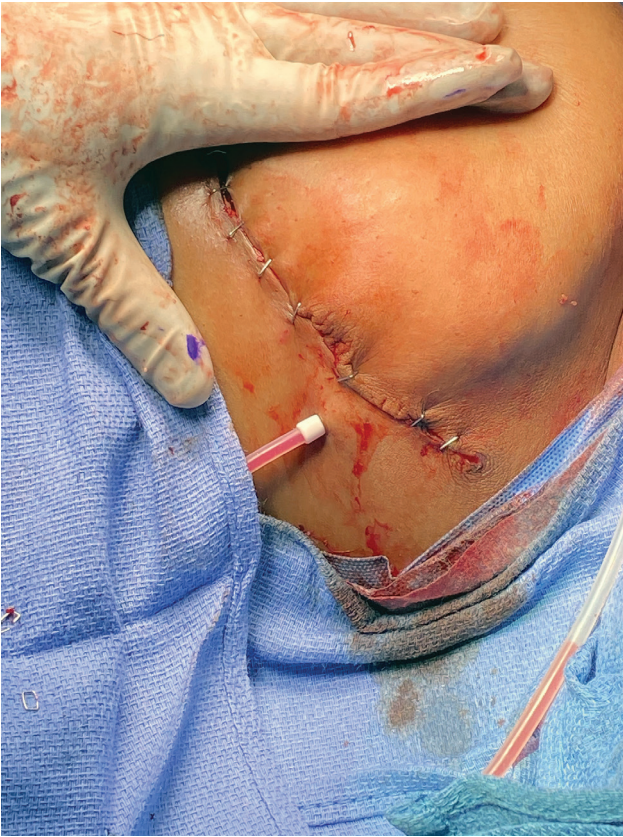

Fig. 7. Hockey stick extension. Intra-operative lateral view of the left breast, showing post-dog ear correction with the hockey stick extension technique. For orientation, the patient's head is at the right and feet are at the left of the photograph.

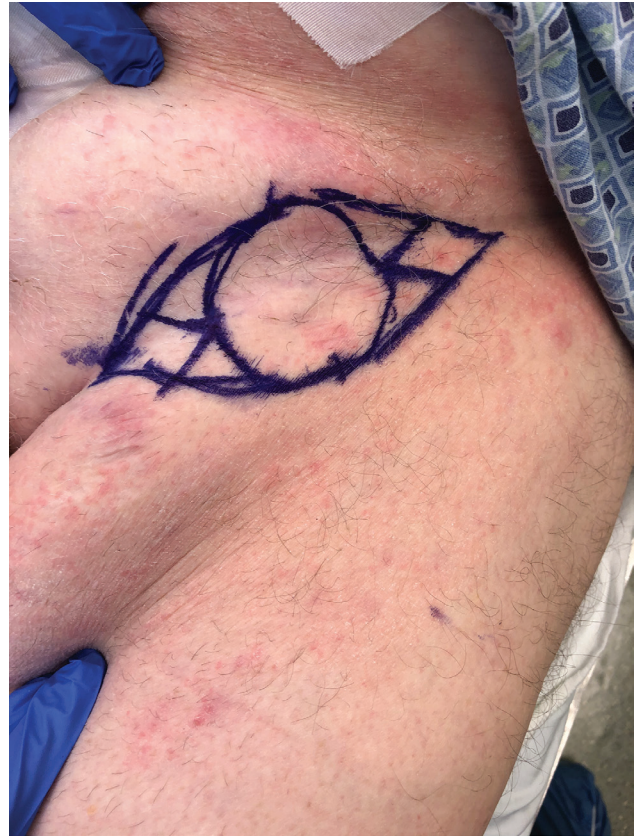

Fig. 8. M-plasty. Intra-operative anterior view of the left groin, showing donor site marking for full-thickness skin graft. M-plasty marking in blue on each corner is an indication to conserve skin that otherwise would be wasted by ellipse. For orientation, the patient's head is at the top and feet are at the bottom of the photograph.

experience complete regression over the 6-month study period (Table 1).

Defat

Removing underlying fat can occasionally correct dog-ears.³⁴ The premise is that excess fat removal allows skin redundancies to retract. This principle is sometimes used in abdominoplasty and breast reduction, where the length of scar is a concern for the patient. Alternatively, liposuction may be utilized.⁵

Suture

A three-bite technique that sequentially goes through the deep fascial plane and then each dog ear margin has been described. The proposed advantage is no additional tissue excision or increased scar length.⁴ However, this technique is recommended only for dog ears with a height <15 mm.⁴ Other authors describe successful use of a diagonal mattress suture,²⁶ dog ear tacking suture,²⁷ or subcutaneous suture to correct dog ears.³⁰

Application of the Rule of Halves

To redistribute unequal tissue evenly along the entire length of the wound and limit areas of dog ear protrusion,

suture placement can be used to divide the wound by halves.⁴² This is exemplified by circumferential areolar reduction during mastopexy or breast reduction (Figs. 4, 5). Recently, a modified rule of halves was described to limit scar length extension. With this technique, lateral suture placement is performed, and then excess tissue is moved medially, which is followed by traditional halving sutures.²⁴

Straight Line Extension

Straight line extension is perhaps the most common dog-ear repair technique. It involves increasing the length-width ratio, to limit wound tension and reduce apical angles.^{18,37,40,50} The tradeoff for the better contour is a longer scar.

Hockey Stick Extension

Extending the shorter side of the wound at an approximately 120 degrees from the original axis creates a wound resembling a hockey stick. The extra tissue is excised, wound is closed with a better but longer scar at an angle to original axis³ (Figs. 6, 7).

Right Angle Excision/T-shaped Scar

In some instances, straight line or angled extension may lead to distortion of key anatomic structures.³ In

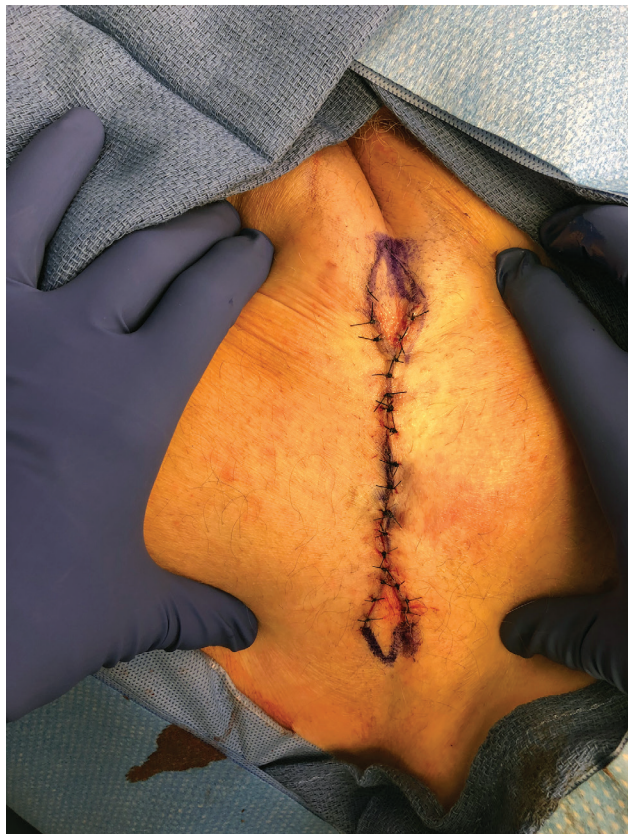

Fig. 9. M-plasty. Intra-operative anterior view of the left groin, showing post-M-plasty dog ear correction. Blue markings demonstrate skin that would have otherwise wasted. For orientation, the patient's head is at the top and feet are at the bottom of the photograph.

such cases, the excess tissue may be removed with a right-angle excision from anywhere along the longer side of the wound. It is critical to respect anatomic landmarks and place the extension along existing lines and wrinkles. The result is typically “T-shaped” final scar with better contour. Excess tissue removed in a V-shaped form is sometimes referred as Burow’s triangle. One or more such triangles may be removed from the longer side.⁵¹

M-plasty

M-plasty is a tissue-sparing technique where the direction of closure is unchanged but a portion of skin that would have been wasted by fusiform excision is preserved. The final scar is placed to accommodate key anatomic structures.³ Proper alignment of the V portion of the M-plasty often requires experience⁵² (Figs. 8, 9). Common anatomic areas for application include the lateral canthus, back, and jawline.⁵³

S-plasty

S-plasty involves the removal of a crescent-shaped piece of tissue along the corners of the wound. This technique is especially helpful over convex surfaces as it moves the corners of the wound away from the areas of maximal convexity and decreases the central scar depression.³ S-plasty is often used along extremities, the mandible, and chin.³

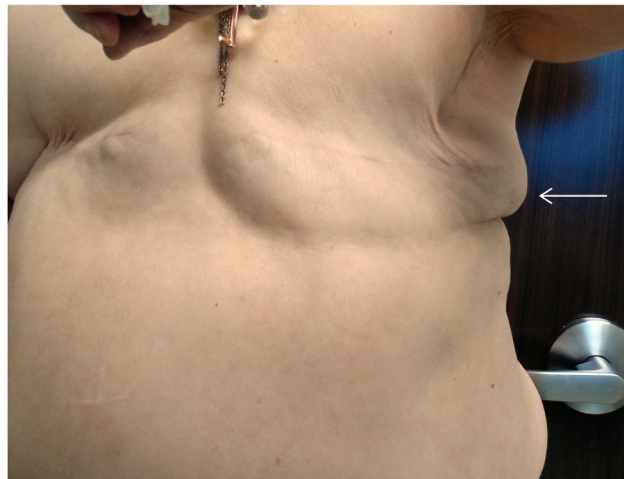

Fig. 10. Advancement flap. Patient status is post bilateral mastectomy with prominent left lateral dog ear (white arrow) treatment. Preoperative anterior, standing view. For orientation, patient's head is at the top and feet are at the bottom of the photograph.

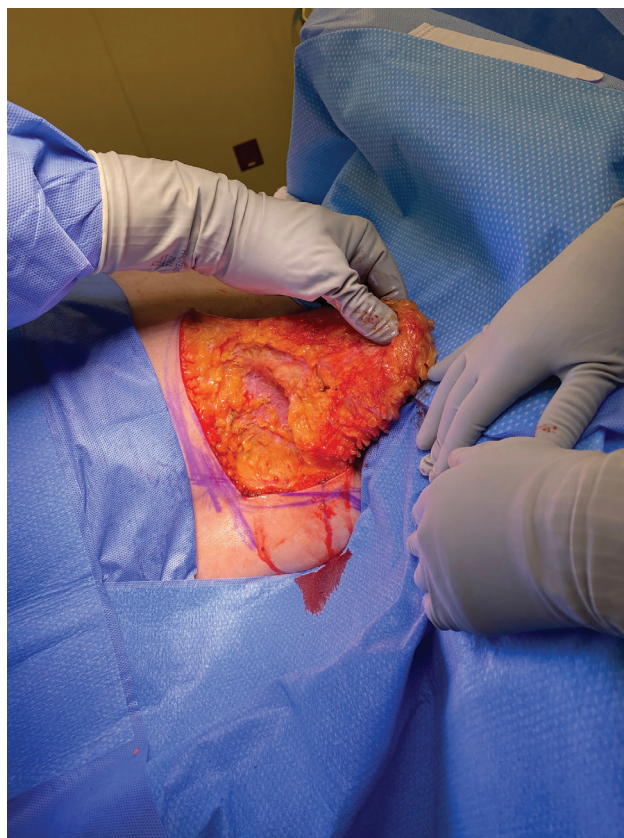


Fig. 11. Advancement flap. Intra-operative, supine, lateral view of the left lateral breast. Incision is extended at a 90 degree angle from the lateral corner of the original incision. A triangular advancement flap is raised at the level of fascia and held by the surgeon's hand. For orientation, the patient's head is at the right and feet are at the left of the photograph.

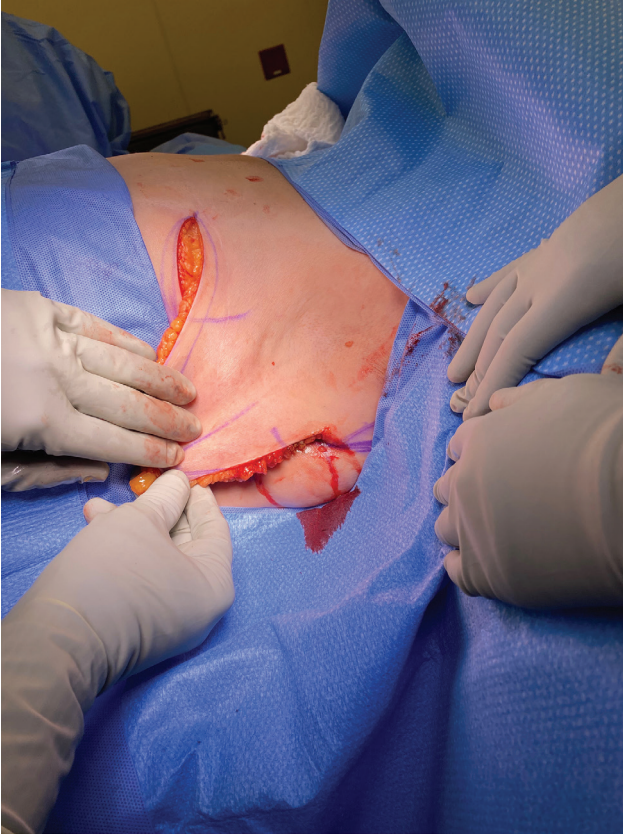

Fig. 12. Advancement flap. Intra-operative, supine, lateral view of the left lateral breast. The skin flap is advanced inferiorly across the original incision and held by the surgeon's hand. For orientation, the patient's head is at the right and feet are at the left of the photograph.

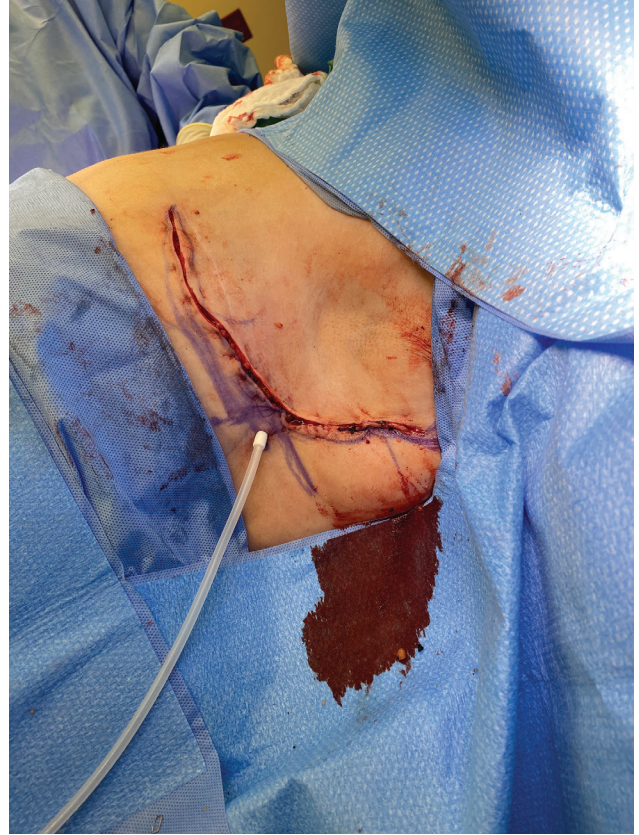


Fig. 13. Advancement flap. Intra-operative, supine, lateral view of the left lateral breast. The distal end of skin flap has been excised and tailored to fit the incision. Please note the additional scar is no longer at 90 degrees but conforms to the lateral breast contour. For orientation, patient's head is at the right and feet are at the left of the photograph.

V-Y Advancement Flap

Skin subcutaneous flaps can transpose the excess dog-ear tissue from a wound to a more desirable location and in the process correct the deformity. The premise is that excess triangular pieces of tissue that would have been excised are instead maintained on a subcutaneous pedicle and advanced into the defect. This technique, popularized by Herbert, is referred to as the V-Y advancement flap and is often used on the lips, eyelids, cheeks, nose, and forehead.^{3,54}

Lateral Breast Dog Ear: Additional Surgical Techniques

A common acquired surgical deformity requiring special consideration is the lateral breast dog ear, often discussed in the Breast and Plastic Surgery literature.^{5,6,8-10,14,17,19-22} The first articles on this topic were published in 1988^{8,21} and the majority focus on surgical management in post-mastectomy and post-mammoplasty, obese or large-breasted patients.⁵

Among the various techniques, variations of the "Y"-closure or "fish-shaped" closure^{5,7,8,21,22} are described most often. Surgically, the lateral edge of the wound is sutured medially at the level of anterior axillary line, creating 2 dog ears along the lateral limbs. The excess skin is removed, and incision is closed in "Y"-shape.⁵

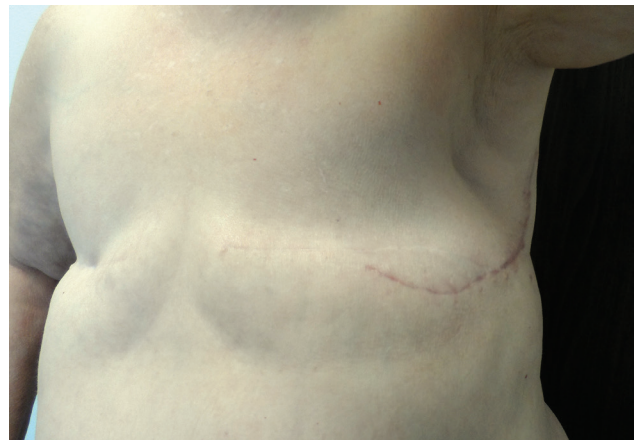

Fig. 14. Advancement flap. Postoperative anterior standing view showing post-dog ear correction with advancement flap/adjacent tissue transfer technique. The new scar is along the lateral breast contour. For orientation, patient's head is at the top and feet are at the bottom of the photograph.

Szynglarewicz et al published a prospective study of 117 lateral breast dog ear patients successfully treated with minimal complications⁷ (Table 1). Their technique adds

two oblique lateral incisions to the traditional mastectomy scar, and then medially advances a flap to reduce dog ear formation, creating a Y-shaped scar.⁷

Recently, Hill et al published a retrospective series of 112 mastectomy patients with lateral dog ears treated by angel wings incision.⁶ Paired curvilinear incisions, “angel wings” are added lateral to the traditional mastectomy markings. The excision of lateral redundant tissue is performed first, followed by mastectomy. The limitation of this technique is a longer operative time and an additional scar. The authors specify that operative note should dictate separate incision and tissue rearrangement.⁶

Bennett described a skin flap advancement technique involving excision of a modified Burow’s triangle skin from the lateral inferior base of mastectomy scar. The lateral tissue flap is advanced medially and inferiorly to eliminate the dog ear.¹⁰ However, this lengthens the scar in an inferior, lateral direction. An “L”-technique has also been described, where a lateral skin flap is advanced superomedially onto the chest wall, creating an L-shaped scar that corrects the dog ear.⁵

Finally, in a triangular advancement flap technique, an approximately 90-degree new incision is made at the lateral end of the horizontal incision and extended until the dog ear disappears. A skin-subcutaneous tissue

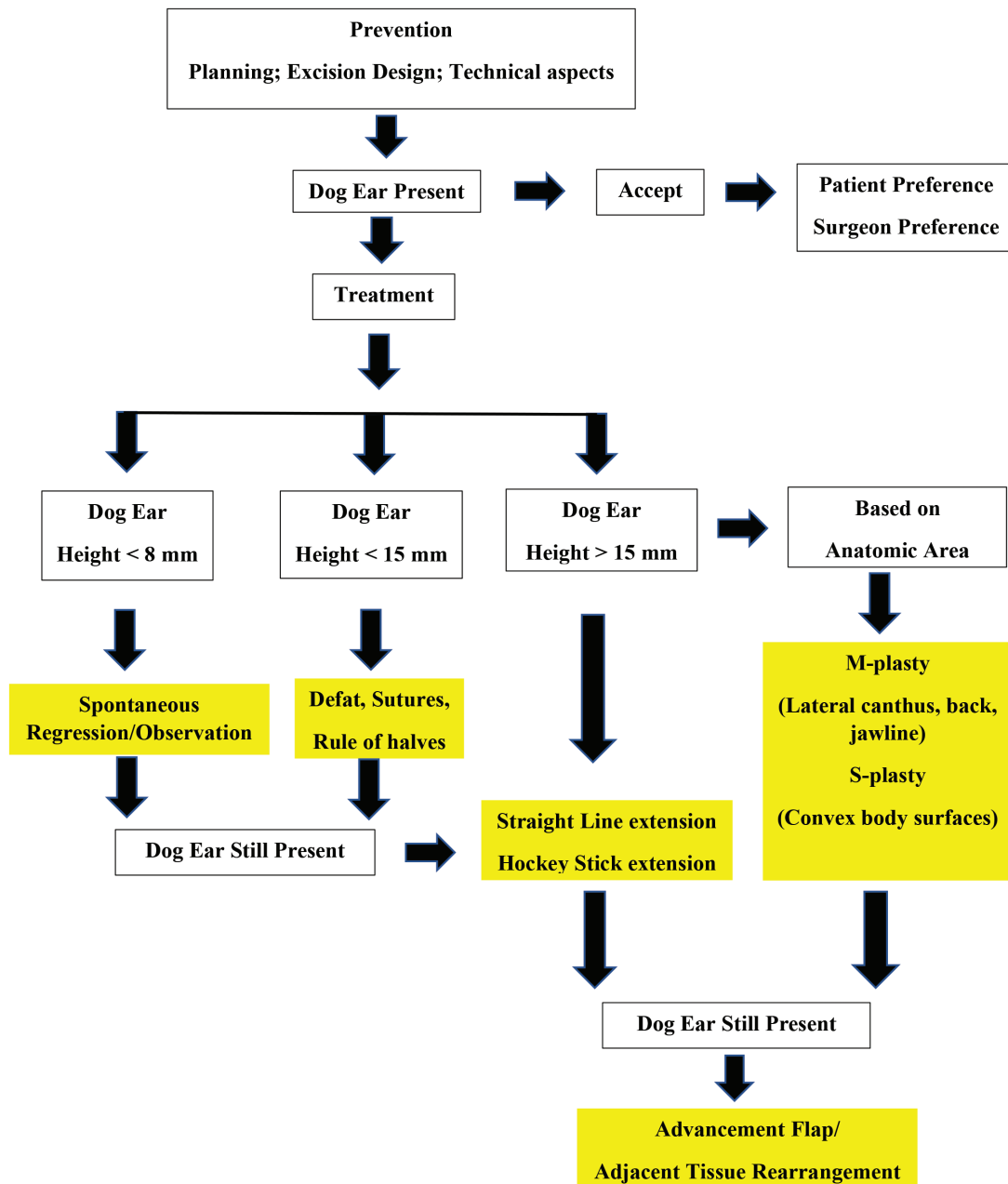


Fig. 15. Proposed algorithm for dog ear management.

flap is raised to create a triangular advancement skin flap. This flap is advanced inferiorly or superiorly, across the long axis. The distal excess portion of the triangular raised flap is excised and tailored to fit exactly. This technique removes the excess tissue without significantly lengthening the scar and improves the contour⁴³ (Figs. 10–14). Another advantage is that the additional scar is placed along the lateral border of the breast (the anterior axillary line).

Proposed Algorithm

As no other algorithm is presented in the literature, we propose using a stepwise, escalating complexity algorithm to select among the reported techniques. For optimal treatment, an individual approach is important.⁷ Final decisions must consider patient and surgeon preferences, complexity of each situation, as well as the anticipated height and location of the dog ear.

The first step should be preventative, as a proper plan of excision and closure can often avoid a dog ear. Sometimes, despite planning, a dog ear will result. In certain instances, based on patient preferences, scar concerns and surgeon proclivity, a decision may be made to accept the dog ear. Other times, a management strategy is needed, and, in those instances, the size and location of the dog ear are important.

If the height is less than 8mm, spontaneous regression should be considered as the initial management strategy. When spontaneous regression is unlikely, but the height is less than 15mm, suture techniques starting in the corners and pleating excess tissue towards the middle of the wound is recommended. If the above techniques are unsuccessful or the height of dog ear is greater than 15mm, surgeons should plan on removing a triangular portion of the extra skin from the longer side. Options include straight line and hockey stick extensions. The direction of removal of extra skin should be based on surrounding lines, wrinkles, and key anatomic structures such that “extra” scar is camouflaged.

For dog ears greater than 15mm height and for certain anatomic locations, we recommend S-plasty and M-plasty. S-plasty is beneficial for convex surfaces, such as extremities, mandible, and chin. M-plasty is helpful in accommodating key anatomic structures, such as lateral canthus, back and jawline. If the dog ear persists despite the above techniques or in instances of a larger size of dog ear, skin flap and tissue rearrangement solutions may be needed (Fig. 15).

The limitations of this review are that most of the studies are case reports or techniques articles, and that most of them do not report patient outcomes or directly compare different techniques. Further research will be helpful to identify “best” standardized management techniques.

CONCLUSIONS

A systematic review of English literature revealed several successful techniques to correct dog ear deformity. We did not find any single best technique to be superior than others, but we have identified specific indications for the major techniques. We recommend the multispecialty cutaneous surgeon become familiar with the etiology, tissue dynamics,

prevention, preoperative planning, and intraoperative techniques available to address the presentation of dog ears in different surgical situations. We hope that our proposed algorithm for dog ear management is a helpful guide.

Ajaijal S. Kang, MD, FACS

Department of Surgery

UPMC Hamot

201 State Street

Erie, PA 16507

E-mail: kangas@upmc.edu

ACKNOWLEDGMENTS

The authors thank Lynne M. Bianchi, PhD, and Margaret Pett for assistance in preparation of the article and in literature search.

REFERENCES

1. Jaibaji M, Morton JD, Green AR. Dog ear: an overview of causes and treatment. *Ann R Coll Surg Engl.* 2001;83:136–138.
2. Limberg AA. Design of local flaps. In: T Gibson, ed. *Modern Trends in Plastic Surgery.* London, United Kingdom: Butterworth; 1966.
3. Weisberg NK, Nehal KS, Zide BM. Dog-ears: a review. *Dermatol Surg.* 2000;26:363–370.
4. Jaber O, Vischio M, Faga A, et al. The three-bite technique: a novel method of dog ear correction. *Arch Plast Surg.* 2015;42:223–225.
5. Lim GH, Tan HF. Surgical techniques to avoid lateral dog ear of the mastectomy scar: a systematic review. *Int J Surg.* 2016;26:73–78.
6. Hill EL, Ochoa D, Denham F, et al. The angel wings incision: a novel solution for mastectomy patients with increased lateral adiposity. *Breast J.* 2019;25:687–690.
7. Szynglarewicz B, Matkowski R, Kasprzak P, et al. Mastectomy approach with Y-shaped incision: a technique designed for women with obesity. *Int J Gynecol Cancer.* 2009;19:1454–1458.
8. Farrar WB, Fanning WJ. Eliminating the dog-ear in modified radical mastectomy. *Am J Surg.* 1988;156:401–402.
9. Vitug AF, Newman LA. Complications in breast surgery. *Surg Clin North Am.* 2007;87:431–451, x.
10. Bennett IC, Biggar MA. A triangular advancement technique to avoid the dog-ear deformity following mastectomy in large breasted women. *Ann R Coll Surg Engl.* 2011;93:554–555.
11. Moher D, Liberati A, Tetzlaff J, et al.; PRISMA Group. Preferred reporting items for systematic reviews and meta-analyses: the PRISMA statement. *Int J Surg.* 2010;8:336–341.
12. Fischl RA. A flap for naso-labial defects, or, “save the dog-ear”. *Br J Plast Surg.* 1969;22:351–356.
13. Loh CY, Loh AY, Mashhadi SA. A novel method for repairing the dog ear. *J Plast Reconstr Aesthet Surg.* 2013;66:e341–e342.
14. Thomas R, Mouat C, King B. Mastectomy flap design: the “waisted teardrop” and a method to reduce the lateral fold. *ANZ J Surg.* 2012;82:329–333.
15. Kishi K, Nakajima H, Imanishi N. A new dog ear correction technique. *J Plast Reconstr Aesthet Surg.* 2008;61:423–424.
16. Lo SJ, Khoo C. Improving the cosmetic acceptability of punch biopsies: a simple method to reduce dog-ear formation. *Plast Reconstr Surg.* 2006;118:295–296.
17. Green RA, Bodjanac WG. Elimination of dog ear during reduction mammoplasty. *Plast Reconstr Surg.* 1998;101:868–869.
18. Borges AF. Dog-ear repair. *Plast Reconstr Surg.* 1982;69:707–713.
19. Clough KB, Massey EJ, Mahadev GK, et al. Oncoplastic technique for the elimination of the lateral “dog ear” during mastectomy. *Breast J.* 2012;18:588–590.

20. Mirza M, Sinha KS, Fortes-Mayer K. Tear-drop incision for mastectomy to avoid dog-ear deformity. *Ann R Coll Surg Engl*. 2003;85:131.
21. Nowacki MP, Towpik E, Tchórzewska H. Early experience with “fish-shaped” incision for mastectomy. *Eur J Surg Oncol*. 1991;17:615–617.
22. Nowacki MP, Towpik E. A fish shaped incision for mastectomy. *Surg Gynecol Obstet*. 1988;167:251–252.
23. Jennings TA, Keane JC, Varma R, et al. Observation of dog-ear regression by anatomical location. *Dermatol Surg*. 2017;43:1367–1370.
24. Croley JA, Malone CH, Subrt AP, et al. The modified rule of halves for prevention of dog-ears. *J Am Acad Dermatol*. 2017;76:e99–e100.
25. Millán-Parrilla F, Molés-Poveda P, Barrado-Solis N, et al. Counterweight method for dog ear correction. *J Am Acad Dermatol*. 2015;73:e181–e182.
26. Dhandha MM, Mishra T, Whitney DH. Use of the diagonal mattress suture to prevent dog-ear formation. *J Am Acad Dermatol*. 2015;73:e27–e28.
27. Kantor J. The dog-ear tacking suture technique. *J Am Acad Dermatol*. 2015;73:e25–e26.
28. Ishihara T, Masuguchi S, Ihn H. Using the smallest skin excision without dog-ear formations: utilizing histopathology on the face. *Dermatol Surg*. 2008;34:1404–1406.
29. Lee KS, Kim NG, Jang PY, et al. Statistical analysis of surgical dog-ear regression. *Dermatol Surg*. 2008;34:1070–1076.
30. Vinciullo C. Useful subcutaneous suture technique to optimize wound edge apposition and avoid “dog ears”. *Australas J Dermatol*. 2006;47:139–142.
31. Khachemoune A, Krejci-Papa N, Lee D, et al. Surgical pearl: “Leashing the dog ear”. *J Am Acad Dermatol*. 2005;52(3 pt 1):514–516.
32. Schmidt DK, Mellette JR Jr. The dog-ear rotation flap for the repair of large surgical defects on the head and neck. *Dermatol Surg*. 2001;27:908–910.
33. Krishnan R, Hwang L, Orengo I. Dog-ear graft technique. *Dermatol Surg*. 2001;27:312–314.
34. Chrétien-Marquet B, Bennaceur S. Dog ear: true and false. A simple surgical management. *Dermatol Surg*. 1997;23:547–550; discussion 551.
35. Hudson-Peacock MJ, Lawrence CM. Comparison of wound closure by means of dog ear repair and elliptical excision. *J Am Acad Dermatol*. 1995;32:627–630.
36. Vaughan TK, Samlaska CP, Mulvaney MJ. Hello tricorne; good-bye “dog-ear”. *Arch Dermatol*. 1990;126:1366.
37. Dzubow LM. The dynamics of dog-ear formation and correction. *J Dermatol Surg Oncol*. 1985;11:722–728.
38. Salasche SJ, Roberts LC. Dog-ear correction by M-plasty. *J Dermatol Surg Oncol*. 1984;10:478–482.
39. Lee TS, Murakami CS, Suryadevara AC. Tissue conservation using circular defect with dog-ear deformities excision technique. *Laryngoscope*. 2011;121:2299–2304.
40. Gormley DE. The dogear: causes, prevention and correction. *J Dermatol Surg Oncol*. 1977;3:194–198.
41. Gormley DE. Management of excess tissue: dogears, cones, and protrusions. In: GP Lask, RL Moy, eds. *Principles and Techniques of Cutaneous Surgery*. New York, N.Y.: McGraw-Hill, 1996:187–199.
42. Goldwyn RM. Carl August Burrow. *Plast Reconstr Surg*. 1984;73:687–690.
43. Grasseti L, Lazzeri D, Torresetti M, et al. Aesthetic refinement of the dog ear correction: the 90° incision technique and review of the literature. *Arch Plast Surg*. 2013;40:268–269.
44. Bennett RG. *Fundamentals of Cutaneous Surgery*. St. Louis, Mo.: CV Mosby, 1988:370–372.
45. Tilleman TR, Neumann MH, Smeets NW, et al. Waste of skin in elliptical excision biopsy of non-melanomatous skin cancer. *Scand J Plast Reconstr Surg Hand Surg*. 2006;40:352–356.
46. Raveh Tilleman T, Tilleman MM, Krekels GA, et al. Skin waste, vertex angle, and scar length in excisional biopsies: comparing five excision patterns—fusiform ellipse, fusiform circle, rhomboid, mosque, and S-shaped. *Plast Reconstr Surg*. 2004;113:857–861.
47. Davis TS, Graham WP III, Miller SH. The circular excision. *Ann Plast Surg*. 1980;4:21–24.
48. Spicer TE. Techniques of facial lesion excision and closure. *J Dermatol Surg Oncol*. 1982;8:551–556.
49. Zitelli JA. Tips for wound closure. Pearls for minimizing dog-ears and applications of periosteal sutures. *Dermatol Clin*. 1989;7:123–128.
50. Toomey JM. “Practical suggestions on facial plastic surgery—how I do it”. Management of the dog ear deformity. *Laryngoscope*. 1977;87(9 pt 1):1585–1587.
51. Burrow A. *Beschreibung einer neuen Transplantationsmethode (Methode der seitlichen Dreiecke) zum Wiedersatz verlorenen Theile des Gesichtes*. Berlin: Albert Nauck, 1855.
52. Abdulkarim FA, Louri NA, Mukandan P. Post-auricular full thickness skin graft by m-plasty technique: an alternative to classical elliptical technique. *Bahrain Med Bull*. 2017;39:66–68.
53. Prohaska J, Crane JS. M-plasty. In: *StatPearls* [Internet]. Treasure Island, Fla.: StatPearls Publishing; 2020. Available at <https://www.ncbi.nlm.nih.gov/books/NBK482275/>. Updated February 11, 2020. Accessed May 30, 2020.
54. Herbert DC. A subcutaneous pedicled cheek flap for reconstruction of alar defects. *Br J Plast Surg*. 1978;31:79–92.