

# Resection of deep-infiltrating endometriosis could be a risk factor for uterine rupture: a case series with review of the literature

Hanane Ziadeh, M.D.,<sup>a</sup> Pierre Panel, M.D.,<sup>a</sup> Arnaud Letohic, M.D.,<sup>a</sup> Michel Canis, M.D., Ph.D.,<sup>c</sup> Sarah Amari, M.D.,<sup>a</sup> Tristan Gauthier, M.D., Ph.D.,<sup>b</sup> and Julien Niro, M.D.<sup>a</sup>

<sup>a</sup> Department of Obstetrics and Gynecology, Versailles Hospital Center, Versailles; <sup>b</sup> Department of Obstetrics and Gynecology, Limoges University Hospital, Limoges; and <sup>c</sup> Department of Obstetrics and Gynecology and Reproductive Biology, Estaing University Hospital, Clermont-Ferrand, France

**Objective:** To highlight the possible correlation between deep-infiltrating endometriosis (DIE) resection and subsequent uterine rupture.

**Design:** Case series and review of the literature.

**Setting:** Endometriosis referral hospitals.

**Patient(s):** Seven young women who underwent laparoscopic resection of DIE, six of whom had uterine rupture before or during labor; the seventh patient had a posterior wall defect that placed her at increased risk of future uterine rupture.

**Intervention(s):** Diagnosis of uterine rupture before or during labor in patients with a history of prior resection of DIE, leading to delivery by emergency delivery section or emergency laparotomy for exploration and repair.

**Main Outcome Measure(s):** Immediate neonate and maternal salvaging caesarean delivery or laparotomy followed by surgical correction of the rupture.

**Result(s):** As of 2019, no publications in the literature had considered uterine rupture among the obstetric complications of endometriosis. The reporting of such findings is crucial because of the increase in surgical management of endometriosis. We report seven cases of uterine rupture in pregnancy in women who had undergone resection of DIE. In six patients, surgeons found uterine rupture at the level of the previous resected endometriosis and diagnosed a posterior wall defect at the same level in one patient.

**Conclusion(s):** Our case series sheds light on the potential increased risk of uterine rupture during pregnancy among women who have had a prior resection of DIE. In future, if these patients are considered high-risk pregnancy cases, their care should be managed by high-risk obstetric specialists. (*Fertil Steril Rep*® 2020;1:213–8. ©2020 by American Society for Reproductive Medicine.)

**Key Words:** Deep infiltrating endometriosis, laparoscopy, uterine rupture

**Discuss:** You can discuss this article with its authors and other readers at <https://www.fertstertdialog.com/posts/xfre-d-20-00112>

Uterine rupture is a dangerous, uncommon obstetric complication in young women. One percent of uterine ruptures occur in patients with previously scarred uteri, most commonly after a caesarian delivery or a myomectomy (1). Uterine rupture also has been noted in women without a history of scarring at a rate 0.6 per 10,000 deliveries (1–2). Seven

cases of uterine rupture have been reported in the literature in patients who had undergone laparoscopic resection of deep-infiltrating endometriosis (DIE).

To our knowledge, there are no published studies identifying the resection of infiltrating deep pelvic endometriosis as a risk factor of uterine rupture. In the study by Vercellini et al. (3) on

obstetric complications in primigravida women who had been operated on for endometriosis, no cases of uterine rupture were noted. Herein, we present a multicenter case series of seven patients who underwent laparoscopic resection of DIE. Six of them had uterine rupture during labor, and the seventh patient had a large posterior wall defect that was likely to increase her

Received June 5, 2020; revised August 31, 2020; accepted September 4, 2020.

H.Z. has nothing to disclose. P.P. has nothing to disclose. A.L. has nothing to disclose. M.C. has nothing to disclose. S.A. has nothing to disclose. T.G. has nothing to disclose. J.N. has nothing to disclose.

Reprint requests: Hanane Ziadeh, M.D., Obstetrics and Gynecology Department, Centre Hospitalier de Versailles, 177 Rue de Versailles, 78150 le Chesnay, France (E-mail: [hananeziadeh@gmail.com](mailto:hananeziadeh@gmail.com)).

*Fertil Steril Rep*® Vol. 1, No. 3, December 2020 2666-3341

© 2020 The Author(s). Published by Elsevier Inc. on behalf of American Society for Reproductive Medicine. This is an open access article under the CC BY-NC-ND license (<http://creativecommons.org/licenses/by-nc-nd/4.0/>).

<https://doi.org/10.1016/j.xfre.2020.09.005>

risk of uterine rupture in a future pregnancy. Written consent from the patients was obtained, and because no identifiable information has been included in the case reports they were approved for publication.

## MATERIALS AND METHODS

### Patient 1

A 26-year-old nulligravid woman with a history of infertility reported having had a laparoscopy for drainage of an ovarian endometrioma the previous year. A magnetic resonance imaging (MRI) scan performed before the surgery showed a right 8-cm endometrioma, a rectovaginal endometriotic nodule, measuring  $4.5 \times 1.8$  cm by 2.5 cm in height at 10 cm from the anal margin. No uterine adenomyosis was identified. The patient underwent laparoscopic right ovarian cystectomy followed by bilateral ureterolysis, excision of the right and left involved pelvic walls, and dissection of the rectovaginal nodule with rectal shaving. Finally, the left and the right ureterosacral ligaments were transected using the inverted U technique. The whole dissection was performed using the UltraCision harmonic scalpel (Ethicon).

The following year the patient conceived spontaneously and had an uneventful prenatal course. Spontaneous labor ensued at 39 weeks and 2 days of gestation, and vacuum extraction was performed due to a fetal heart rate anomaly. A male infant weighing 2,210 grams was born, with Apgar scores of 4, 8, and 9 respectively at 1, 5, and 10 minutes.

After delivery, abnormal, persistent slight bleeding led to a manual exploration of the uterine cavity, where a posterior uterine rupture was found. An emergency laparotomy was performed that confirmed the presence of a 15-cm posterior longitudinal corporeal rupture, which was repaired with 900 mL of blood loss and no complications. The patient recovered without further complications.

### Patient 2

In April 2017, a 31-year-old nulligravid woman presented with mild dysmenorrhea and a 3-year history of infertility. The patient had a noteworthy history of endometriosis resection 4 years before, with adhesiolysis of the sigmoid and the ovaries and dissection that partially reached the uterosacral ligaments. After the procedure, the patient underwent three unsuccessful in vitro fertilization (IVF) attempts.

A pelvic MRI showed extensive endometriosis associated with adenomyosis located mostly on the uterine fundus; a left hematosalpinx and a parietal sigmoid nodule measuring  $20 \times 30$  mm were also identified (Supplemental Fig. 1, available online). In August 2017, she underwent laparoscopic excision of the DIE with the UltraCision harmonic scalpel with complete adhesiolysis, left salpingectomy, dissection of the rectovaginal nodule with rectal shaving, and an appendectomy.

One year later, she conceived after oocyte donation in Spain with embryo transfer. At 34 weeks and 5 days of gestation, she was admitted to the hospital for acute abdominal pain. Non Stress Test revealed an abnormal fetal heart rate without contractions. Consequently, an emergency caesarian delivery was performed, and she gave birth to a female infant

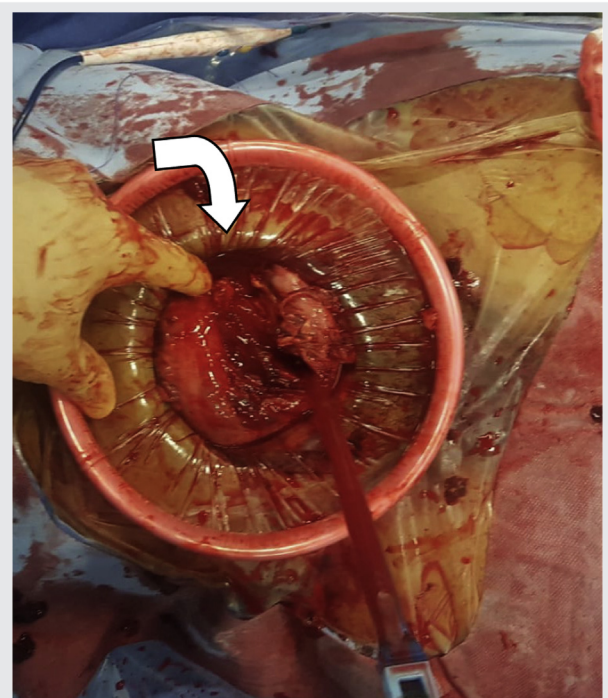
weighing 1,775 grams, with Apgar scores of 7, 8, and 10, at 1, 5, and 10 minutes, respectively. During manual exploration of the uterus, a posterior isthmic transverse uterine rupture measuring 10 cm was noted and repaired using a running-X suture technique with a total blood loss estimated at 700 mL (Fig. 1). The patient was discharged 5 days later with an uneventful follow-up evaluation.

### Patient 3

A 27-year-old woman, para 1, presented with worsening dysmenorrhea, deep dyspareunia, and dyschezia. The patient had a relevant history of stage 4 endometriosis diagnosed in 2015 at the time of a diagnostic laparoscopy, with simple adhesiolysis of the left ovary and the sigmoid colon. A pelvic MRI and a rectal endoscopic ultrasound confirmed the presence of stage 4 endometriosis without adenomyosis. The patient underwent laparoscopic removal using the UltraCision harmonic scalpel of a  $24 \times 15$  mm endometriotic nodule infiltrating the posterior vaginal wall and deeply the rectovaginal septum (Fig. 2). A rectal resection was performed with colorectal anastomosis followed by an ileostomy closed 2 months later.

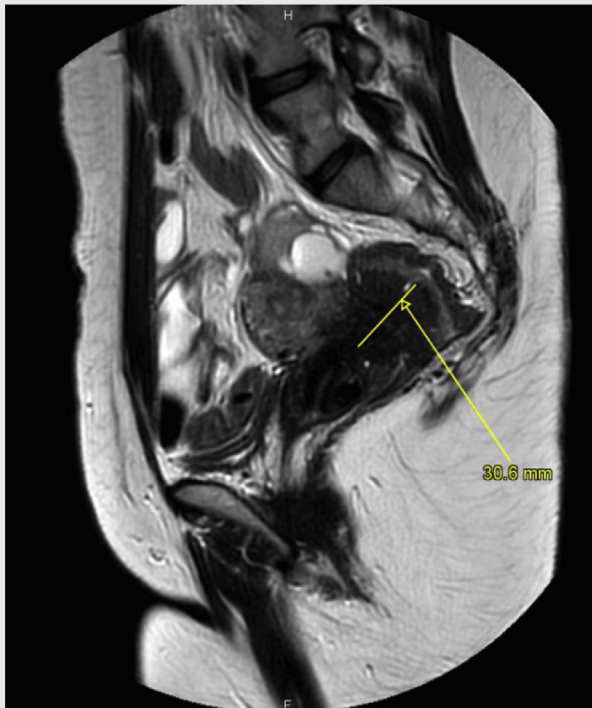In October 2018, the patient conceived spontaneously and maintained an uneventful prenatal course until August 22, 2019, when she was admitted to the hospital for spontaneous labor at 41 weeks and 1 day of gestation. An emergency cesarean delivery was performed for fetal distress and

FIGURE 1



Operative photos showing the posterior transverse uterine rupture of 10 cm before and after being repaired.

Ziadeh. Resection of DIE may cause uterine rupture. *Fertil Steril Rep* 2020.

**FIGURE 2**

Sagittal section of the pelvic magnetic resonance imaging: presence of an important rectovaginal nodule.

Ziadeh. Resection of DIE may cause uterine rupture. *Fertil Steril Rep* 2020.

nonengagement of the fetal vertex, and an infant was delivered weighing 4,329 grams, with Apgar scores of 6 and 8 at 1 and 5 minutes, respectively. A 15-cm posterior longitudinal uterine rupture with stool in the pelvis was noted, so the operating surgeons closed the uterine incision and then repaired the uterine rupture with 1-0 Vicryl using the running-X suture technique. An exploration of the colon revealed a 10-cm seromuscular sigmoid tear requiring a Hartmann intervention with pelvic drainage. The patient underwent an uneventful recovery.

#### Patient 4

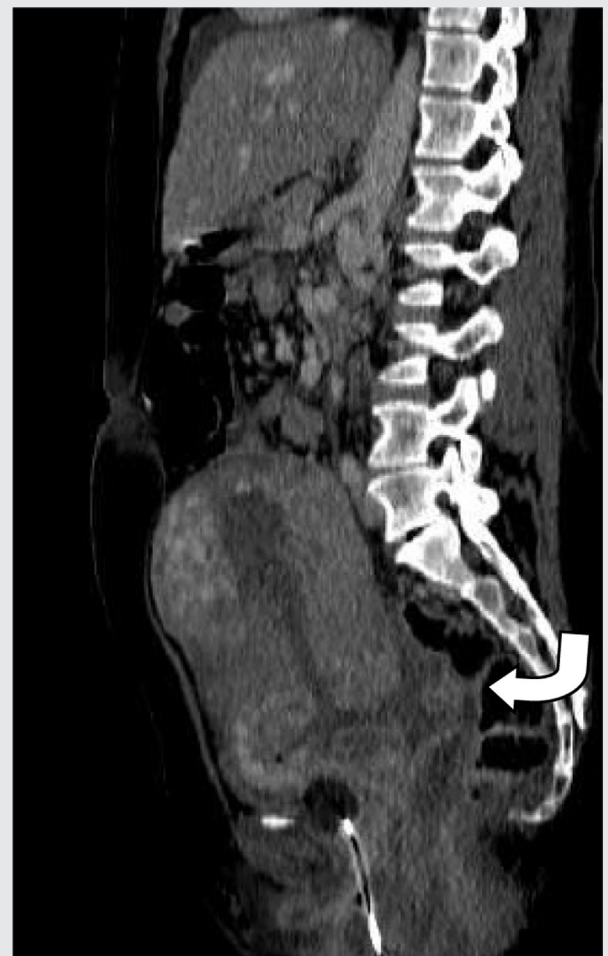A 35-year-old nulliparous woman with a 2-year history of infertility who underwent MRI was found to have a 12-mm rectovaginal nodule without evidence of adenomyosis. In March 2011 she had a laparoscopic excision of this nodule with rectal shaving and dissection of the uterosacral ligaments using the UltraCision scalpel.

In July 2013, she conceived through IVF and had an uncomplicated prenatal course. Labor was induced at 41 weeks and 6 days with Dinoprostone (Propress) followed by a vacuum extraction for nonreassuring fetal heart rate. A male infant was born weighing 3,550 grams with an Apgar score of 4, 4, and 6 at 1, 5, and 10 minutes of life, respectively. Subsequently, the patient complained of intense scapular pain; an abdominal ultrasound revealed a 7 cm × 5 cm effusion in

Morison's pouch. A computed tomography (CT) scan showed an intraperitoneal effusion of at least 600 mL with significant break-in of the posterior uterine isthmus wall of 3–4 cm with clots in the pouch of Douglas (Fig. 3). At laparotomy, the posterior uterine rupture was repaired by double-layer closure using Vicryl sutures. The total blood loss was estimated at 1,000 mL. The patient and her infant were discharged from the hospital 12 days later, with an uncomplicated outpatient course.

#### Patient 5

In November 2019, a 36-year-old woman, gravida 1, with a history of infertility treatment was admitted to the delivery unit in spontaneous labor at 38 weeks and 1 day of gestation. This pregnancy had been achieved through IVF with intracytoplasmic sperm injection (ICSI). The patient's past surgical history was relevant for a laparoscopic excision of a 14 × 12 mm left uterosacral nodule diagnosed via MRI.

**FIGURE 3**

Sagittal section of the abdominal computed tomography scan after delivery: evidence of posterior uterine rupture of 4 cm.

Ziadeh. Resection of DIE may cause uterine rupture. *Fertil Steril Rep* 2020.

Adhesiolysis using an UltraCision device was also performed to free up the right ovary from the sigmoid colon.

The patient delivered via forceps extraction and episiotomy after an abnormal fetal heartrate tracing. A live infant weighing 3,210 grams was born, with an Apgar score of 10 and 10 at 1 and 5 minutes of life, respectively. The patient complained of severe postpartum right flank pain. An abdominal pelvic CT scan revealed an 11-cm retroperitoneal hematoma without active bleeding, with mild effusion in the pouch of Douglas. The patient was managed conservatively, and by 1 week later the pelvic pain had worsened, prompting a pelvic MRI.

A 3-cm posterior isthmus wall rupture was identified associated with intrauterine and retrouterine hematoma in continuation with the previous known perineal hematoma described on the CT scan. The hematoma was evacuated with clots by vaginal approach with no active bleeding. A follow-up MRI and hysterorrhaphy were scheduled for a later time.

### Patient 6

A 27-year-old nulliparous patient presented with chronic pelvic pain. A pelvic MRI showed a rectovaginal nodule of 3 cm. In March 2016, the patient underwent a laparoscopic excision of the rectovaginal nodule with anterior resection of the rectum using the UltraCision scalpel followed by lateroterminal colorectal anastomosis. We also noted bipolar cauterization of two uterine foci of endometriosis at the level of the left fallopian tube.

One year later, the patient had a recurrence of pelvic pain and primary infertility. A follow-up pelvic MRI revealed a recurrence of her endometriosis, with new lesions located mostly at the uterine isthmus and the posterior vaginal fornix with retracted uterosacral ligaments. A small right endometrioma with endometriotic spots was noted in the uterovesical recess posteriorly, and mild fundal adenomyosis was identified.

The patient underwent oocyte retrieval and preservation before her second laparoscopy. The second laparoscopy, performed in October 2018, consisted of UltraCision bilateral ureterolysis, dissection of the rectovaginal space with rectal shaving, resection of uterosacral ligaments, right oophorectomy, and excision of multiple uterovesical superficial lesions.

She conceived spontaneously in June 2019, and her prenatal course was uncomplicated until about 31 weeks and 3 days of gestation. The patient experienced sudden and severe abdominal pain leading to an emergency department encounter. On admission, fetal bradycardia was noted, and an emergency caesarian delivery was performed. A live female infant was delivered, weighing 1,690 grams and with Apgar scores of 0, 1, 6, and 8 at 1, 5, 10, and 15 minutes, respectively.

A massive hemoperitoneum was found associated with a fundal uterine rupture of 3 cm, which was sutured in two layers. The total blood loss was estimated at 1,700 mL. The patient recovered uneventfully, but the infant's 3-month MRI revealed neurologic sequelae.

### Patient 7

In March 2015, a 27-year-old nulliparous woman presented at our center with severe dysmenorrhea and infertility. A pelvic MRI revealed DIE with a rectovaginal nodule. In June 2015, she underwent a laparoscopic excision of the rectovaginal nodule, with the UltraCision and a colorectal resection with end-to-end anastomosis protected by an ileostomy. One week later, closure of the ileostomy was performed. Six days after, a bowel obstruction complicated the procedure, and a second look via laparoscopy confirmed the diagnosis. She was discharged 5 days later with no more adverse incidents.

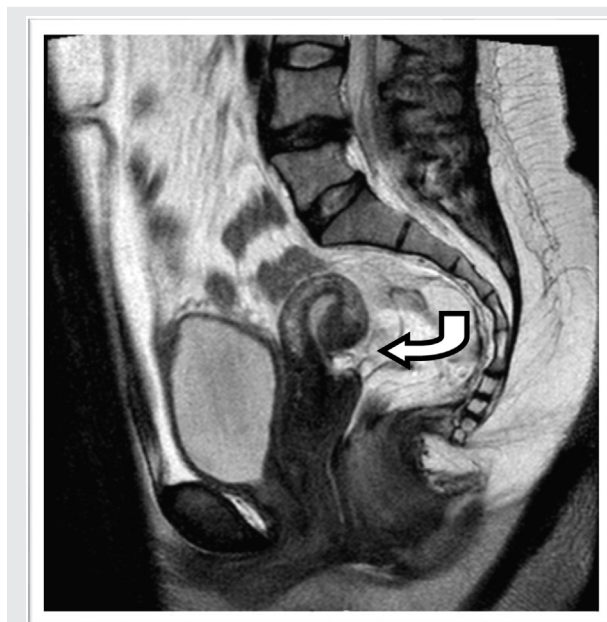
On January 28, 2019, the patient returned to our facility for symptom recurrence and failure to conceive spontaneously. A follow-up pelvic MRI revealed bilateral small endometriomas with substantial thinning of the isthmus, defined on the MRI as a posterior wall defect (Fig. 4).

## RESULTS AND DISCUSSION

Uterine rupture is a dangerous obstetric complication with serious sequelae for both mother and infant. Historically, studies had identified several causes of uterine rupture, such as a scarred uterus and adenomyosis; they also have mentioned uterine ruptures with an unscarred uterus (1, 2, 4).

After reviewing the literature, Parker et al. (5) noted 19 women who had uterine ruptures after laparoscopic myomectomy (5). Although no maternal deaths were noted, three fetuses died. In 2018 Wu et al. (6) reported on 10 cases of uterine rupture after laparoscopic myomectomy, with four

FIGURE 4



Sagittal section of the recent pelvic magnetic resonance imaging: evidence of posterior wall defect.

Ziadeh. Resection of DIE may cause uterine rupture. *Fertil Steril Rep* 2020.

fetal deaths and no maternal incidents. In both studies, they concluded that the principal cause was the quality and type of suture and the high use of monopolar and bipolar cautery for hemostasis.

In the series of Xiaoxia et al. (7), 67 uterine ruptures occurred among 128,599 deliveries (equivalent to 0.0521%), where 59 patients had a history of cesarean delivery, one had had a myomectomy, three had uterine malformations, and two had instrumental delivery; in three patients no etiology was identified. A Swedish cohort study by Hesselman et al. (8) reported 109 patients with uterine rupture who had attempted vaginal birth after a previous caesarian delivery, equivalent to an incidence of 1.3%. For the first delivery, the indications for a caesarian procedure were infection and fetal macrosomia. For the second delivery, they found that the risk factors for uterine rupture were induction of labor, epidural analgesia, and fetal macrosomia (8). Furthermore, in a review of literature from 1904 to 1944 (9), investigators found that adenomyosis was also responsible for some obstetric complications such as uterine rupture, as described by Haydon in 1942 (10).

We have reported on six cases of uterine rupture as well as one patient with surgically managed DIE who was diagnosed a uterine wall defect. We performed a review of the literature to investigate whether a cause–effect relationship exists between the excision of endometriotic lesions—mainly those located at the level of the uterine isthmus—and uterine rupture occurring during or before labor. Currently, endometriosis affects 10% of premenopausal women (11), and it is responsible for a large number of cases of chronic pelvic pain and infertility, requiring surgical management to alleviate the pain. However, those surgeries may result in severe obstetric complications, which have few descriptions in the literature.

A series by Vercellini et al. (3) followed 419 patients who underwent laparoscopic excision of superficial peritoneal endometriosis or ovarian and/or rectovaginal endometriosis then conceived for the first time spontaneously. They reported 20.8% spontaneous miscarriages and 1.9% ectopic pregnancies. Among the 324 patients remaining, they noted hypertension and preeclampsia in 4.3%, premature deliveries in 11.7%, and placental abruption in 1.5%. Overall, they observed an increased incidence of placenta previa of 3.7%. In the subgroup of patients who had rectovaginal nodule excision, the number increased to 7.6%. No uterine rupture was reported, and no other studies has been published that examine endometriosis as a risk factor for uterine rupture.

Only seven cases of uterine rupture after surgery for endometriosis were published in the literature from 1999 to 2019. All of the women were nulliparous and aged between 29 and 36 years old. They had previous history of stage 4 endometriosis and underwent laparoscopic excision of rectovaginal nodules. Among them, two patients had endometriosis lesions all over the uterus, necessitating extensive cauterization (12). Three out of seven cases conceived spontaneously (13–15), and the other four patients successfully conceived after IVF and embryo transfer (12, 16, 17). Before labor, two of the women experienced acute abdominal pain at 32 weeks and 33 weeks of gestation (12); labor was induced with oxytocin in one patient (15) and with

dinoprostone (Proress) in another (16). The other women were admitted to the hospital for spontaneous labor. Two out of four vaginal deliveries were vacuum assisted, and the fetal weights ranged between 2,100 and 3,600 grams (16, 17). Uterine rupture occurred before labor in two patients, who had described acute pain early in their pregnancies (12). Uterine rupture occurred during labor for the others. The uterine rupture was located on the posterior lower uterine segment in five patients; in two patients the rupture was observed in extensive uterine endometriosis at the level of the left cornual area (12). No fetal deaths were noted, and the maternal prognosis was favorable, apart from two patients who underwent hysterectomies for uncontrolled bleeding (14, 17). In total, the time between the surgery and the rupture varied between 5 months and 6 years.

In our case series, all our patients were nulliparous and aged 26 to 35 years old. They all had a previous history of rectovaginal nodule excision by laparoscopy. Two of our patients had a posterior lower segment uterine rupture between 34 weeks and 5 days, and 31 weeks and 1 day of gestation before the onset of labor. The uterine rupture occurred in four other patients during labor between 38 weeks and 1 day, and 41 weeks and 6 days. The uterine rupture was corporeal and isthmic in five patients and fundal in one patient. Of note, there were no documented fetal or maternal deaths in our case series.

We would like to highlight that the total of 13 cases described in literature for patients with posterior uterine rupture had same commonality: resection of DIE. In most cases, the patient underwent excision of a rectovaginal nodule and subsequently rupture occurred, mostly at the level of this excision, exactly on the lower posterior uterine segment. Thus, resection of posterior DIE should be considered a potential risk factor for uterine rupture.

This relationship of DIE with uterine rupture may be explained by the fact that the depth of necessary excision remains controversial—surgically it is difficult to delineate the healthy from the diseased tissue (13). This element makes the uterine wall thin and more vulnerable to rupture. The decreased vascularization of the uterine tissue that follows the extensive bipolar coagulation required in these surgeries may lead to a later rupture as well (12). In view of the current increase in laparoscopy used to diagnose and treat mild, moderate, and deep endometriosis, our case series suggests that safety measures and precautions should be observed to prevent complications such as uterine rupture.

Our case report study raises the following questions. Should we consider patients with previous excision of rectovaginal septum endometriosis as having a scarred uterus and apply same protocols? Are there other additive factors that enhance the risk of rupture such as fetal weight, time between surgery and delivery, age of gestation at delivery, labor induction and stimulation, and traumatic extraction? What are the precautions to take intraoperatively and postoperatively?

Studies have shown that neither MRI nor ultrasound can predict uterine rupture after cesarean delivery or myomectomy. However, we would recommend obtaining a postoperative MRI 3 months after the procedure to assess the thickness of the posterior uterine wall before proceeding with conception. We

would consider caesarean delivery for patients with a thin or posterior wall defect. We also suggest that these patients should be followed strictly by a specialist in high-risk pregnancies during their pregnancies. To prove our hypothesis, a prospective study should be designed for patients with previous resection of DIE after their pregnancy and delivery.

## CONCLUSION

Uterine rupture is a serious complication that endangers a patient and her fetus. Any previous history of resection of DIE, especially a rectovaginal nodule, should be considered a potential risk factor for uterine rupture. Further guidelines should be developed for this group of patients to prevent this perinatal complication. Those guidelines should include a systematic evaluation of the quality of the posterior wall by postoperative imaging and before conception occurs. Additional follow-up evaluations for high-risk patients should occur during pregnancy and delivery at a hospital, where an obstetrician and anesthesiologist should be immediately available to perform an emergency cesarean delivery.

**Acknowledgments:** The authors thank Dr. Joe Mawad, founder and president of Inland Empire Woman's Center, Medical Associates in San Bernardino, CA, for his help and assistance in the completion of this work.

## REFERENCES

1. Kaczmarczyk M, Sparen P, Terry P, Cnattingius S. Risk factors for uterine rupture and neonatal consequences of uterine rupture: a population-based study of successive pregnancies in Sweden. *BJOG* 2007;114:1208–14.
2. Hofmeyer GJ, Say L, Gulmezoglu AM. WHO systematic review of maternal mortality and morbidity: the prevalence of uterine rupture. *BJOG* 2005;112:1221–8.
3. Vercellini P, Parazzini F, Pietropaolo G, Cipriani S, Frattaruolo M, Fedele L. Pregnancy outcome in women with peritoneal, ovarian and rectovaginal endometriosis: a retrospective cohort study. *BJOG* 2012;119:1538–43.
4. Pafumi C, Farina M, Pernicone G, Russo A, Bandiera S, Giardina P, et al. Adenomyosis and uterus rupture during labor. *Zhonghua Yi Xue Za Zhi (Taipei)* 2001;64:244–6.
5. Parker WH, Einarsson J, Istre O, Dubuisson JB. Risk factors for uterine rupture after laparoscopic myomectomy. *J Minim Invasive Gynecol* 2010;17:551–4.
6. Wu X, Jiang W, Xu H, Ye X, Xu C. Characteristics of uterine rupture after laparoscopic surgery of the uterus: clinical analysis of 10 cases and literature review. *J Int Med Res* 2018;46:3630–9.
7. Xiaoxia B, Zhengping W, Xiaofu Y. Clinical study on 67 cases with uterine rupture (article in Chinese). *Zhonghua Fu Chan Ke Za Zhi* 2014;49:331–5.
8. Hesselman S, Högberg U, Ekholm-Selling K, Råsjö EB, Jonsson M. The risk of uterine rupture is not increased with single- compared with double-layer closure: a Swedish cohort study. *BJOG* 2015;122:1535–41.
9. Bensaid F, Kettani F, Fehri S, Chraïbi C, Alaoui MT. Obstetric complications of adenomyosis; literature review and two case reports. *J Gynecol Obstet Biol Reprod* 1996;25:416–8.
10. Haydon GB. A study of 569 cases of endometriosis. *Am J Obstet Gynecol* 1942;43:704–9.
11. Eskenazi B, Warner ML. Epidemiology of endometriosis. *Obstet Gynecol Clin North Am* 1997;24:235–58.
12. Fettback PB, Pereira RM, Domingues TS, Zacharias KG, Chamié LP, Serafini PC. Uterine rupture before the onset of labor following extensive resection of deeply infiltrating endometriosis with myometrial invasion. *Int J Gynecol Obstet* 2015;129:268–70.
13. Van De Putte I, Campo R, Gordts S, Brosens I. Uterine rupture following laparoscopic resection of rectovaginal endometriosis: a new risk factor? *Br J Obstet Gynecol* 1999;106:608–9.
14. Villa G, Mabrouk M, Guerrini M, Mignemi G, Colleoni G, Venturoli S, et al. Uterine rupture in a primigravida with adenomyosis recently subjected to laparoscopic resection of rectovaginal endometriosis: case report. *J Minim Invasive Gynecol* 2008;15:360–1.
15. Chester JM, Israfil-Bayli F. Endometriosis: a possible cause of uterine rupture in labour? *J Obstet Gynaecol* 2015;35:638.
16. Delepine O, Curinier S, Agar N, Piquier-Perretet G, Gallot D, Houle C, et al. About a case of uterine per-partum rupture, 37 months after resection of a rectovaginal endometriosis nodule (article in French). *J Gynecol Obstet Biol Reprod (Paris)* 2016;45:985–9.
17. Vystavěl J, Eim JB, Pilka R. Consecutive intrapartum uterine rupture following endoscopic resection of deep rectovaginal and bladder endometriosis. *Ceska Gynekol* 2018;83:354–8.