

Strongyloides stercoralis hyperinfection in patient with autoimmune hepatitis and purpura fulminans

Neha Rathor, Vikas Khillan, S. K. Sarin¹

Abstract

Strongyloidiasis is usually an asymptomatic chronic nematodal disease. The term hyperinfection is used to denote autoinfection, a phenomenon in which the number of worms increases enormously. Development or exacerbation of gastrointestinal and pulmonary symptoms is seen, (A) and the detection of increased numbers of larvae in stool and or sputum is the hallmark. It is known to occur with a change in immune status of the host; this can occur due to immunosuppressants. Cytomegalovirus (CMV) is also known to suppress host immunity. Due to the nonspecific presentation, the diagnosis is frequently missed, and the outcome remains poor with 15–87% mortality despite therapy. We report here a case of *Strongyloides stercoralis* hyperinfection following immunosuppressive therapy for autoimmune hepatitis and concomitant CMV infection with purpura fulminans and frank sepsis, with fatal outcome.

Keywords: Autoimmune hepatitis, purpura fulminans, strongyloides

Access this article online

Website: www.ijccm.org

DOI: 10.4103/0972-5229.173694

Quick Response Code:



Introduction

Strongyloides hyperinfection is a well-known entity; however this is the first case report of a North Indian patient with autoimmune hepatitis and purpura fulminans. In India, the epicenter lies in southern states, with a paucity of cases reports from northern states.^[1] To our knowledge, this is the first case report of strongyloides hyperinfection with concurrent cytomegalovirus (CMV) infection and gram-negative sepsis from North India.

Case Report

A 59-year-old Indian female presented to our hospital, with c/o abdominal distension for last 2 months, generalized weakness, productive cough, and purpuric rashes over both lower limbs and fever for 2 days. The patient was a known hypertensive and hypothyroid on medications and past history of cholecystectomy 17 years back.

She was recently diagnosed as a case of chronic liver disease due to autoimmune hepatitis 3 months back was being treated for the same. She was started on wysolone 60 mg for last 3 months and azoran 100 mg for past 1 month.

On general examination, she was conscious, oriented, and afebrile. Physical examination revealed pallor, pedal edema, palpable purpuric spots on both the lower limbs. Her blood pressure was low (80/50 mm of Hg), progesterone receptor - 118/min, and risk ratio - 20/min. Chest examination revealed bilateral normal air entry with basal crepitations. Abdomen was distended and tender with sluggish bowel sounds.

Initial laboratory investigation confirmed anemia (hemoglobin - 9.3 g/dl), total lung capacity $8.9 \times 10^9/L$

This is an open access article distributed under the terms of the Creative Commons Attribution-NonCommercial-ShareAlike 3.0 License, which allows others to remix, tweak, and build upon the work non-commercially, as long as the author is credited and the new creations are licensed under the identical terms.

From:

Departments of Microbiology and ¹Gastroenterology, Institute of Liver and Biliary Sciences, New Delhi, India

Correspondence:

Dr. Neha Rathor, Department of Microbiology, Institute of Liver and Biliary Sciences, New Delhi, India.
E-mail: neharathor.s@gmail.com

For reprints contact: reprints@medknow.com

How to cite this article: Rathor N, Khillan V, Sarin SK. *Strongyloides stercoralis* hyperinfection in patient with autoimmune hepatitis and purpura fulminans. Indian J Crit Care Med 2016;20:52-4.

with neutrophilia, (neutrophil - 83%, lymphocyte - 11%, and eosinophil - 1%), and platelets $139 \times 10^9/L$.

Her kidney function were deranged - urea 120 mg/dl, creatinine 2.08 mg/dl, sodium 133 mmol/L, and potassium 4.39 mmol/L. Liver function tests were also deranged, (total bilirubin - 1.4 mg/dl, aspartate aminotransferase - 98 IU/L, alanine aminotransferase - 82 IU/L, serum alkaline phosphatase - 519 IU/L, gamma glutamyl transferase - 800 IU/L, albumin - 2.0 g/dl, and globulin - 3.3 g/dl).

Arterial blood gas revealed respiratory acidosis and lactate 3.2 (pH - 7.30, HCO_3^- - 20 mm Hg, PCO_2 - 46 mm Hg, and PO_2 - 87 mm Hg.) C reactive protein 144 mg/L, because of the worsening respiratory status and altered sensorium she was intubated and put on a mechanical ventilator. She also had paralytic ileus (high RT aspirate 600 ml/24 h).

Chest X-ray showed bilateral fluffy alveolar opacities with infiltrates, left side consolidation and right homogenous opacities with ground glass appearance. Baseline ECHO with 50%, no regional wall motion abnormality, inferior vena cava 20. Ultrasonography showed liver with irregular outlines and coarse echotexture, minimal interloop ascites, few dilated fluid filled small bowel loops were seen with sluggish peristaltic movement.

Cytologic examination of the bronchial wash and lavage comprised benign respiratory epithelial cells, few polymorphs and histiocytes over hemorrhagic background. A wet mount was seen which revealed motile larvae resembling larvae of *Strongyloides stercoralis* [Figures 1-4].

Interestingly bronchoalveolar lavage culture grew *Klebsiella pneumoniae*. Other cultures were sterile. CMV DNA quant $1.81 \times 10^6/ml$.

Absolute eosinophil count was -55/cumm (reference range 40-440) Serum immunoglobulin E was 319 (reference range 100). Skin biopsy showed occasional thrombi in dermal vessels with extravasation of red blood cells; epidermis was largely unremarkable which is compatible with purpura fulminans. No larvae were seen.

Treatment

Antibiotics were added as per sensitivity reports. Ivermectin 12 mg once daily was added. A high ionotropic support was given to maintain mean arterial pressure of 65 mmHg.

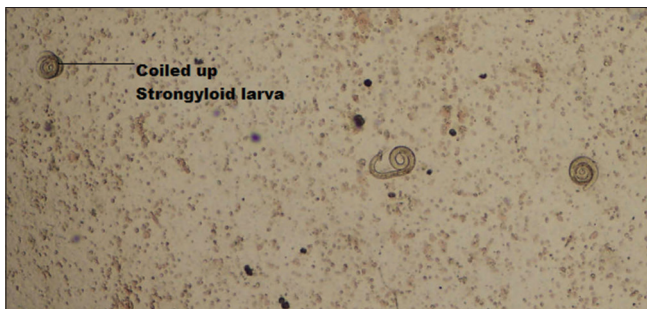

Figure 1: Coiled up strongyloides larvae

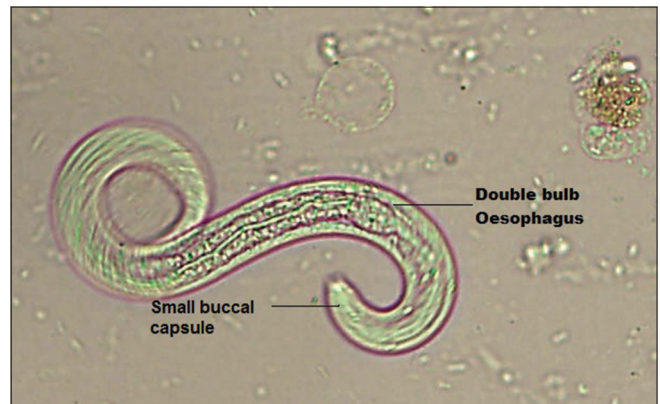

Figure 2: Double bulb esophagus

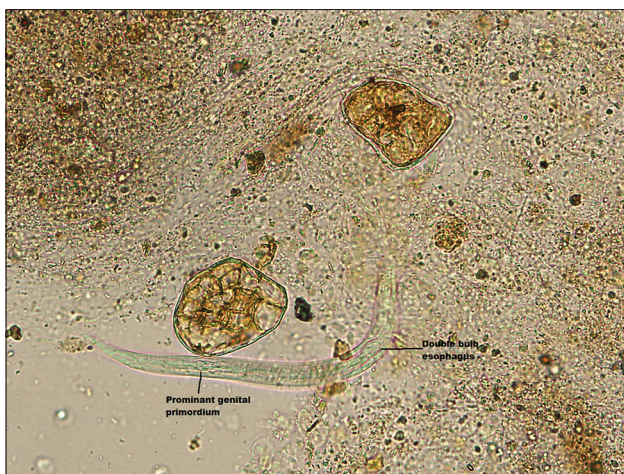


Figure 3: Primordial genital primordium

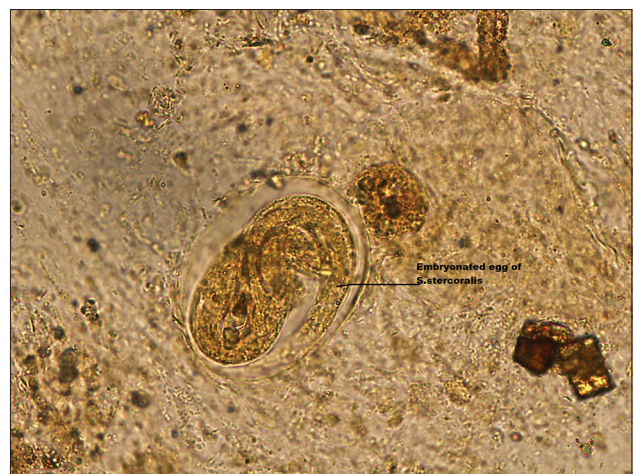

Figure 4: Embryonated egg

Further course

She had a sudden onset of cardiac arrest and despite best possible effort. She could not be revived. Postmortem liver biopsy features were consistent with liver cirrhosis with features of sepsis. Muscle biopsy showed transversely and longitudinally cut muscle fibers with a focal group of atrophic muscles.

Discussion

Fatal *S. stercoralis* hyperinfection with immune suppression was first reported in 1966 by Cruz *et al.*^[2] Immunosuppression may occur due to steroids and other immunosuppressants. Some viruses such as CMV, also lower immunity. Female worms produce more eggs in the presence of exogenous steroids; this further facilitates worm growth and development.^[3,4] In our patient, all the above factors got together to deliver the fatal blow.

Hyperinfection may develop as early as 20 days after the onset of corticosteroid therapy and as late as several years in immunocompetent persons.^[5,6] Symptoms may include dyspnea, cough, pleuritic chest pain, hemoptysis, infiltrates of varying character on chest imaging, and mild blood eosinophilia. Concomitant use of corticosteroids or bacterial coinfection, as seen in our patient, suppresses the eosinophilia. Respiratory failure may occur in severe cases.^[7] Purpura fulminans has been described in both sepsis and strongyloidiasis. In Strongyloidiasis, it is periumbilical and thumbprinting in appearance. In such cases strongyloidiasis larvae is seen in the skin biopsy, this was absent in our case. Therefore, Purpura in our case could be due to underlying sepsis. Strongyloid larvae carry gastrointestinal flora, while it migrates, causing sepsis.^[8,9]

Paralytic ileus, caused by obstruction resulting from heavy parasite burdens may be a subtle pointer.^[10]

Ironically, an inverse relationship between autoimmune liver diseases and *S. stercoralis* infection, has been proposed, a possible link between deworming and the emergence of immunological disease has been described, with some authors suggesting helminths, safe and effective in the treatment of inflammatory bowel disease: A possible example of Th2 conditioning of the mucosal immune response.^[11,12]

However, a high mortality despite therapy warrants, not only screening and monitoring but, a state of constant, high alert as concurrent sepsis may further obscure the presentation and waylays the clinician.

As stool studies are often negative, aspiration of duodenojejunal fluid and enzyme-linked immunosorbent assay serologic testing may be used as adjunct diagnostic tools.^[13] Patients who have positive serologic tests and an exposure history, regardless of a negative stool results, should receive a course of treatment (ivermectin, 200 µg/kg/day for 2 days, and repeat after 2 weeks).^[14]

Subsequent decisions about screening and prophylactic ivermectin must be individualized, but at the very least, a low threshold for performing stool exams should be maintained. Persons residing in strongyloidiasis-endemic areas or in high-risk occupations need to be educated about modes of parasite transmission to avoid recurrent infection.

Financial support and sponsorship

Nil.

Conflicts of interest

There are no conflicts of interest.

References

1. Singh S, Sharma MP. *Strongyloid stercoralis* in Northern India. *Indian J Microbiol* 1992;10:197-203.
2. Cruz T, Rebouças G, Rocha H. Fatal strongyloidiasis in patients receiving corticosteroids. *N Engl J Med* 1966;275:1093-6.
3. Spencer JV, Lockridge KM, Barry PA, Lin G, Tsang M, Penfold ME, *et al.* Potent immunosuppressive activities of cytomegalovirus-encoded interleukin-10. *J Virol* 2002;76:1285-92.
4. Hunter CJ, Petrosyan M, Asch M. Dissemination of *Strongyloides stercoralis* in a patient with systemic lupus erythematosus after initiation of albendazole: A case report. *J Med Case Rep* 2008;2:156.
5. Debussche X, Toublane M, Camillieri JP, Assan R. Overwhelming strongyloidiasis in a diabetic patient following adrenocorticotropic treatment and keto-acidosis. *Diabetes Metab* 1988;14:294-8.
6. Rivera E, Maldonado N, Vélez-García E, Grillo AJ, Malaret G. Hyperinfection syndrome with *Strongyloides stercoralis*. *Ann Intern Med* 1970;72:199-204.
7. Mani RK, Sardana R, Chawla R, Bansal A, Bansal MS, Kansal S, *et al.* Respiratory failure, coma and cutaneous lesions due to disseminated strongyloidiasis. *Indian J Crit Care Med* 2003;7:132-6.
8. Bank DE, Grossman ME, Kohn SR, Rabinowitz AD. The thumbprint sign: Rapid diagnosis of disseminated strongyloidiasis. *J Am Acad Dermatol* 1990;23 (2 Pt 1):324-6.
9. Link K, Orenstein R. Bacterial complications of strongyloidiasis: *Streptococcus bovis* meningitis. *South Med J* 1999;92:728-31.
10. Mori S, Konishi T, Matsuoka K, Deguchi M, Ohta M, Mizuno O, *et al.* Strongyloidiasis associated with nephrotic syndrome. *Intern Med* 1998;37:606-10.
11. Aoyama H, Hirata T, Sakugawa H, Watanabe T, Miyagi S, Maeshiro T, *et al.* An inverse relationship between autoimmune liver diseases and *Strongyloides stercoralis* infection. *Am J Trop Med Hyg* 2007;76:972-6.
12. Garg SK, Croft AM, Bager P. Helminth therapy (worms) for induction of remission in inflammatory bowel disease. *Cochrane Database Syst Rev* 2014;1:CD009400.
13. Loutfy MR, Wilson M, Keystone JS, Kain KC. Serology and eosinophil count in the diagnosis and management of strongyloidiasis in a non-endemic area. *Am J Trop Med Hyg* 2002;66:749-52.
14. Zaha O, Hirata T, Kinjo F, Saito A, Fukuhara H. Efficacy of ivermectin for chronic strongyloidiasis: Two single doses given 2 weeks apart. *J Infect Chemother* 2002;8:94-8.