

The Path of Birth is Not Always Normal: A Case Report of Cervicovaginal Agenesis

Kavita Khoiwal*, Meenakshi Singh, Anchal Agarwal, Jaya Chaturvedi

Department of Obstetrics and Gynecology, All India Institute of Medical Sciences, Rishikesh, Uttarakhand, India

Abstract

Cervical agenesis is a rare congenital Mullerian anomaly. Its association with vaginal agenesis is further rare, reported in 39% of cases of cervical agenesis. The conventional treatment for this condition was hysterectomy. However, with evolving surgical skills and assisted reproductive techniques, conservative surgery could be considered as the first-line treatment in the current era. We report one such case of cervicovaginal agenesis in a 13-year-old adolescent girl managed successfully with cervicovaginoplasty. The patient was relieved of cyclical pain abdomen and resumed menstrual cycles postoperatively.

Keywords: Cervicovaginal agenesis, cervicovaginoplasty, cyclical pain abdomen, primary amenorrhea

INTRODUCTION

In adults, Mullerian duct forms uterus, cervix, fallopian tube, and upper one-third of the vagina. Its anomaly has a mean prevalence of 4.3% of general population.^[1] In 2013, European Society of Human Reproduction and Embryology (ESHRE) has proposed a newer classification system for Mullerian anomalies on the basis of uterine anatomy. In addition, anomalies of the cervix and vagina are classified separately.^[2] In the ESHRE classification, cervical and vaginal agenesis are classified as C4 and V4, respectively.

Cervical agenesis is a rare congenital Mullerian anomaly, with an incidence of 1:80,000–1:100,000.^[3] Its association with vaginal agenesis is further rare, reported in 39% of cases of cervical agenesis.^[4]

Cervical or cervicovaginal agenesis usually presents around the age of menarche with complaints of primary amenorrhea and/or cyclical abdominal pain. In these cases, endometrium functions normally, but menstrual blood has no path to

exit from vagina, leading to hematocolpos followed by hematometra formation. The condition can further aggravated with hematosalpinx and endometriosis if left undiagnosed. Diagnosis and management should be done early in these cases to avoid progression of the disease. We present a case of 13-year-old female with cervicovaginal agenesis, who was managed by conservative surgery.

CASE REPORT

A 13-year-old girl presented in Gynecology Emergency Department with the complaint of severe abdominal pain for 1 day not relieving on injectable analgesics. She had a history of primary amenorrhea with cyclical abdominal pain for the last 1 year. There was no significant past, personal, or family history. There was no history of *in utero* exposure to diethylstilbestrol.

General physical examination revealed average built with normal secondary sexual characters (breast - tanner stage 4,

Address for correspondence: Dr. Kavita Khoiwal,
Department of Obstetrics and Gynaecology, All India Institute of Medical
Sciences, Rishikesh, Uttarakhand, India.
E-mail: kavita.kh27@gmail.com

Article History:

Submitted: 2 June 2020

Revised: 10 September 2020

Accepted: 9 December 2020

Published: 5 November 2021

Access this article online

Quick Response Code:



Website:
www.e-gmit.com

DOI:
10.4103/GMIT.GMIT_57_20

This is an open access journal, and articles are distributed under the terms of the Creative Commons Attribution-NonCommercial-ShareAlike 4.0 License, which allows others to remix, tweak, and build upon the work non-commercially, as long as appropriate credit is given and the new creations are licensed under the identical terms.

For reprints contact: WKHLRPMedknow_reprints@wolterskluwer.com

How to cite this article: Khoiwal K, Singh M, Agarwal A, Chaturvedi J. The path of birth is not always normal: A case report of cervicovaginal agenesis. *Gynecol Minim Invasive Ther* 2021;10:247-51.

pubic hairs - tanner stage 4). Thyroid and breast examination was normal. Abdomen was soft, no organomegaly was noted, while tenderness present in the lower abdomen on deep palpation. A gentle vaginal examination revealed a blind vaginal pouch (2 cm × 1 cm) and no cervical tissue felt. She was carrying ultrasound (USG) and magnetic resonance imaging (MRI) reports with her. USG pelvis showed collection in the endometrial cavity along with hematocolpos. MRI pelvis revealed uterine enlargement (8.9 cm × 6 cm × 4.2 cm) with collection in the endometrial cavity, suggestive of hematometra along with hematocolpos. Bilateral ovaries and renal system were normal. On the basis of imaging findings, a provisional diagnosis of low transverse vaginal septum was made.

In view of intractable pain, the patient was taken to the emergency operation theater for vaginal septum excision followed by hematocolpos and hematometra drainage. Consent was taken for examination under anesthesia (EUA) with transverse vaginal septum excision with laparotomy if required. EUA revealed a blind vaginal pouch (2 cm × 1 cm) [Figure 1], and surgical excision of the vaginal septum was attempted; however, soon, we realized that there was no vaginal cavity as well as no cervical tissue, making it a case of cervicovaginal agenesis (U0C4V4). A decision of cervicovaginoplasty was made by abdominoperineal approach. Informed and written consent of abdominoperineal cervicovaginoplasty was taken. An approximately 6 cm × 3 cm neovagina was created by dissecting in between bladder and rectum by McIndoe technique. After that, suprapubic transverse minilaparotomy was performed. Uterus was enlarged up to 8 weeks size with left-sided hematosalpinx, while right tube and bilateral ovaries were healthy. Endometriotic spots were present on the surface of uterus, ovaries, and pouch of Douglas. A stab incision was made over anterior wall of the uterus; 80–100 ml of chocolate-colored fluid was drained from the endometrial cavity [Figure 2a].

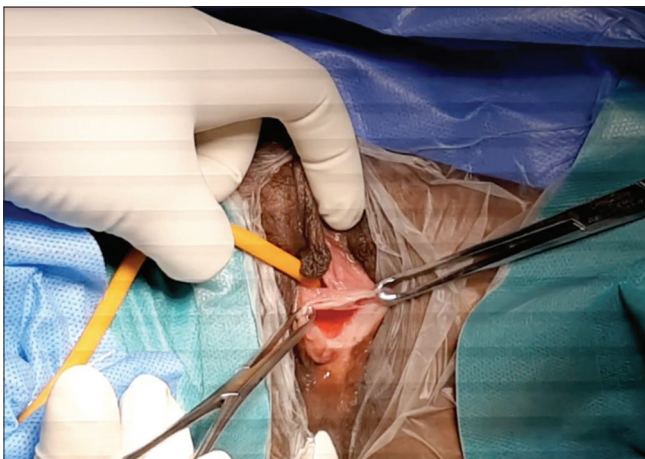


Figure 1: Examination under anesthesia revealed a blind vaginal pouch

A long curved artery forceps was then introduced through the cavity toward neovagina [Figure 2b], and an incision was given from below vaginally to create neocervix. A silicone Malecot catheter No. 18 was inserted in the uterine cavity through neocervix by rail-road technique to keep neocervix patent. Uterine wall was sutured with delayed absorbable suture. Foam mold (6 cm × 3 cm) encircling Malecot catheter [Figure 2c] was kept in the neovagina [Figure 2d] to avoid re-approximation of vaginal walls. Her postoperative course was uneventful. On the 7th postoperative day, foam mold was changed to glass mold and Malecot catheter was kept *in situ*, 1–2 cm outside the cervical os. Mold care was explained to the patient and her mother on discharge. She had three follow-up visits till now at 1, 3, and 6 months postoperatively. The patient had uneventful postoperative period and has resumed normal menstrual cycles. Consent for publication was obtained from the patient and her parents and institutional ethical board (AIIMS/IEC/20/338).

DISCUSSION

Cervicovaginal agenesis is a rare congenital anomaly of the female genital tract. Only few scattered cases and case series are reported in the literature^[4-18] [Table 1].

Most common presenting complaint is primary amenorrhea with cyclical abdominal pain and/or chronic pelvic pain, palpable mass per abdomen, and urinary complaints.

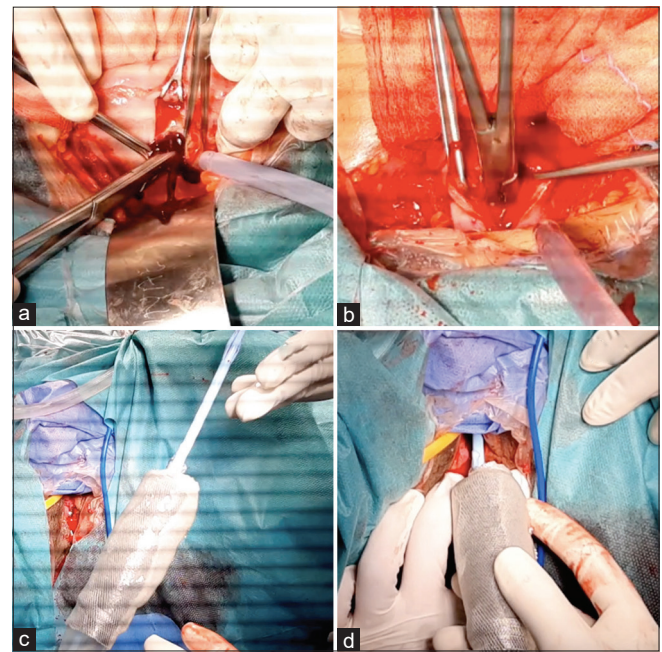


Figure 2: (a) Drainage of chocolate-colored fluid from endometrial cavity, (b) a long curved artery forceps was introduced through the cavity toward neovagina. (c) Foam mold (6 cm × 3 cm) encircling silicone Malecot catheter. (d) Foam mold being inserted in the neovagina with silicone Malecot catheter in the neocervix and endometrial cavity

Table 1: Previous reported cases of cervicovaginal agenesis

Author (year)	Age of presentation (years)	Presenting complaint	Examination finding	Imaging (MRI/USG)	Management	Outcome
Meena <i>et al.</i> (2019) ^[8]	13	Primary amenorrhea and cyclical abdominal pain	Blind vagina, Skeletal deformity	MRI: Bicornuate uterus with hematometra, absent cervix and vagina	Laparoscopic excision of bilateral uterine horns	-
Bagga <i>et al.</i> (2018) ^[9]	18	Primary amenorrhea and cyclical abdominal pain; history of vaginoplasty	Blind vaginal pouch~1.5 cm	MRI: Left-sided uterine horn with hematometra, left endometriotic cyst, absent cervix	Uterine horn-vaginal anastomosis by abdominoperineal approach	Resumed regular menstruation
Mishra <i>et al.</i> (2016) ^[10]	16	Primary amenorrhea and cyclical abdominal pain	Per abdomen–deep tenderness	MRI: 38 mm Ssdomi hematometra and hematosalpinx with blind ended uterus and absence of cervix and vagina	Laparotomy vaginoplasty (McIndoe method) uterovaginal anastomosis by neocervix	Resumed regular menstruation
Jeon <i>et al.</i> (2016) ^[11]	2 cases (17 and 12)	Primary amenorrhea and cyclic pelvic pain	Blind vagina	MRI: Absence of a cervix and vagina, hematometra	Laparoscopy transvaginal uterovaginal anastomosis	Resumed regular menstruation
Kisku <i>et al.</i> (2014) ^[12]	Median age 15 (<i>n</i> =18)	Primary amenorrhea and cyclical abdominal pain	Absent vagina or a small vaginal pouch	-	Laparotomy and sigmoid neovaginoplasty utero-coloneovaginoplasty	Complications; one colon anastomotic leak, two patients developed chocolate cysts, one recurrent pelvic collection, one asymptomatic neovaginal mucosal prolapse
Gasim <i>et al.</i> (2013) ^[13]	14	Primary amenorrhea and cyclical abdominal pain	Abdominopelvic mass up to xiphisternum	USG: Blind upper vagina, bicornuate uterus with right hematometra	Laparotomy, hysterectomy, excision of left rudimentary horn and right salpingo-oophorectomy	-
Kriplani <i>et al.</i> (2012) ^[14]	Mean age 15.2 (<i>n</i> =14)	Primary amenorrhea and cyclical abdominal pain	-	-	laparoscopic assisted uterovaginal anastomosis	Successful; except one patient had restenosis, hysterectomy required
Jain and Sircar (2011) ^[15]	18	Primary amenorrhea and cyclical abdominal pain	Absent vagina	USG: Cervical and vaginal agenesis, uterus, and right ovary normal. A 10 cm×10 cm endometriotic cyst in left ovary	Laparoscopic hysterectomy and neovagina creation by Vecchietti technique	-
Raudrant <i>et al.</i> (2008) ^[16]	13	Primary amenorrhea and cyclic pelvic pain	Blind vaginal pouch	USG: Absence of the cervix with two rudimentary horns and a right hematometra	Laparoscopic uterovaginal anastomosis	Resumed regular menstruation

Contd...

Table 1: Contd...

Author (year)	Age of presentation (years)	Presenting complaint	Examination finding	Imaging (MRI/USG)	Management	Outcome
Gurbuz <i>et al.</i> (2005) ^[17]	15	Primary amenorrhea and cyclical abdominal pain	Partial vaginal agenesis	USG: Hematometra and absent cervix	Laparotomy and uterovaginal anastomosis	Resumed regular menstruation
Grimbizis <i>et al.</i> (2004) ^[18]	15	Primary amenorrhea and cyclical abdominal pain	Normal findings	USG: Uteri corpus and both ovaries were normal	Laparotomy and end-to-end cervicocervical anastomosis	Resumed regular menstruation

USG: Ultrasound, MRI: Magnetic resonance imaging

Differential diagnosis includes imperforate hymen, vaginal agenesis, or transverse vaginal septum, which should be excluded before definitive management. Although clinical history and examination are crucial in such cases, pelvic imaging should be considered to know the exact anatomical anomaly. MRI is considered as the gold standard for diagnosis as well as to look for associated renal tract anomalies.^[5] In our case, imaging was not really helpful as it suggested a diagnosis of transverse vaginal septum while there were no vaginal cavity and hematocolpos present during surgery.

Surgical treatment for imperforate hymen and transverse vaginal septum is easy and has minimal complications. However, creation of the neovagina and neocervix requires more complex operations and is associated with high morbidity and limited success; many of these patients ultimately require hysterectomy. In the literature, many authors^[6,7] have concluded that the treatment of choice should be hysterectomy, and psychological support as reconstructive surgery has serious complication as sepsis, endometriosis, and need for multiple surgeries due to restenosis. Moreover, the patient has low possibility of spontaneous conception due to endometriosis. On the contrary, as surgical skills and assisted reproductive technique are evolving over the time, conservative surgery could be considered as the first-line treatment.^[9-12,14,16-18] Patient's femininity and a distortion of her physical image which can affect her self-esteem should be kept in mind. In our case, we preferred conservative surgery over hysterectomy with due consent from the patient and her parents. At the same time, we also emphasize that the management option should be individualized and possibility of hysterectomy should always be considered particularly in extreme cases.^[8,13,15] Minimally invasive approach is preferred whenever feasible.

Regular follow-up with clinical examination and USG pelvis is required. Patency of track is determined by occurrence of regular menstrual flow without recurrence of hematometra.

Cervicovaginal agenesis is to be kept in mind whenever a young girl presents with primary amenorrhea and cyclical

abdominal pain. Early diagnosis and management are crucial for successful outcome. Exact delineation of pelvic anatomy on imaging is must to avoid complications. First-line surgical option is cervicovaginoplasty, but management has to be individualized in each patient with keeping possibility of need of hysterectomy. Psychological counseling and long-term follow-up are essential.

Ethical review

This report has been approved by Institutional Ethics Committee of All India Institute of Medical Sciences, Rishikesh (approval no. AIIMS/IEC/20/338).

Declaration of patient consent

The authors certify that they have obtained all appropriate patient consent forms. In the form, the patient's parent has given consent for images and other clinical information to be reported in the journal. The patient's parent understands that the names and initials will not be published and due efforts will be made to conceal identity, but anonymity cannot be guaranteed.

Financial support and sponsorship

Nil.

Conflicts of interest

There are no conflicts of interest.

REFERENCES

- Grimbizis GF, Camus M, Tarlatzis BC, Bontis JN, Devroey P. Clinical implications of uterine malformations and hysteroscopic treatment results. *Hum Reprod Update* 2001;7:161-74.
- Grimbizis GF, Gordts S, Di Spiezio Sardo A, Brucker S, De Angelis C, Gergolet M, *et al.* The ESHRE/ESGE consensus on the classification of female genital tract congenital anomalies. *Hum Reprod* 2013;28:2032-44.
- Suganuma N, Furuhashi M, Moriwaki T, Tsukahara Si, Ando T, Ishihara Y, *et al.* Management of missed abortion in a patient with congenital cervical atresia. *Fertil Steril* 2002;77:1071-3.
- Deffarges JV, Haddad B, Musset R, Paniel BJ. Utero-vaginal anastomosis in women with uterine cervix atresia: Long-term follow-up and reproductive performance. A study of 18 cases. *Hum Reprod* 2001;16:1722-5.
- Rock JA, Roberts CP, Jones HW Jr. Congenital anomalies of the uterine cervix: Lessons from 30 cases managed clinically by a common

- protocol. *Fertil Steril* 2010;94:1858-63.
6. Rock JA, Schlaff WD, Zacur HA, Jones HW Jr. The clinical management of the congenital absence of the uterine cervix. *Int J Gynaecol Obstet* 1984;22:231-5.
 7. Hampton HL. Role of the gynaecologic surgeon in the management of urogenital anomalies in adolescents. *Curr Opin Obstet Gynaecol* 1990;2:812-8.
 8. Meena J, Bharti J, Roy KK, Kumar S, Singhal S, Shekhar B, *et al.* Bicornuate uterus with complete cervico-vaginal agenesis and skeletal deformity: A Case report. *J Obstet Gynaecol India* 2019;69:67-70.
 9. Bagga R, Muthyala T, Saha PK, Kalra J, Singla R, Arora A, *et al.* Functioning left uterine horn with cervico-vaginal atresia and ovarian maldescent – An unclassified Müllerian anomaly treated with horn-vaginal anastomosis. *J Obstet Gynaecol* 2018;38:1176-8.
 10. Mishra V, Saini SR, Nanda S, Choudhary S, Roy P, Singh T, *et al.* Uterine conserving surgery in a case of cervicovaginal agenesis with unicornuate uterus. *J Hum Reprod Sci* 2016;9:267-70.
 11. Jeon GH, Kim SH, Chae HD, Kim CH, Kang BM. Simple uterovaginal anastomosis for cervicovaginal atresia diagnosed by magnetic resonance imaging: A report of two cases. *J Obstet Gynaecol Res* 2016;42:738-42.
 12. Kisku S, Varghese L, Kekre A, Sen S, Karl S, Mathai J, *et al.* Cervicovaginal atresia with hematometra: Restoring menstrual and sexual function by utero-coloneovaginoplasty. *Pediatr Surg Int* 2014;30:1051-60.
 13. Gasim T, Al Jama FE. Massive hematometra due to congenital cervicovaginal agenesis in an adolescent girl treated by hysterectomy: A Case report. *Case Rep Obstet Gynecol* 2013;2013:640214.
 14. Kriplani A, Kachhawa G, Awasthi D, Kulshrestha V. Laparoscopic-assisted uterovaginal anastomosis in congenital atresia of uterine cervix: Follow-up study. *J Minim Invasive Gynecol* 2012;19:477-84.
 15. Jain N, Sircar R. Laparoscopic management of congenital cervico-vaginal agenesis. *J Gynecol Endosc Surg* 2011;2:94-6.
 16. Raudrant D, Chalouhi G, Dubuisson J, Golfier F. Laparoscopic uterovaginal anastomosis in Mayer-Rokitansky-Küster-Hauser syndrome with functioning horn. *Fertil Steril* 2008;90:2416-8.
 17. Gurbuz A, Karateke A, Haliloglu B. Abdominal surgical approach to a case of complete cervical and partial vaginal agenesis. *Fertil Steril* 2005;84:217.
 18. Grimbizis GF, Tsalikis T, Mikos T, Papadopoulos N, Tarlatzis BC, Bontis JN. Successful end-to-end cervico-cervical anastomosis in a patient with congenital cervical fragmentation: Case report. *Hum Reprod* 2004;19:1204-10.