

[ PICTURES IN CLINICAL MEDICINE ]

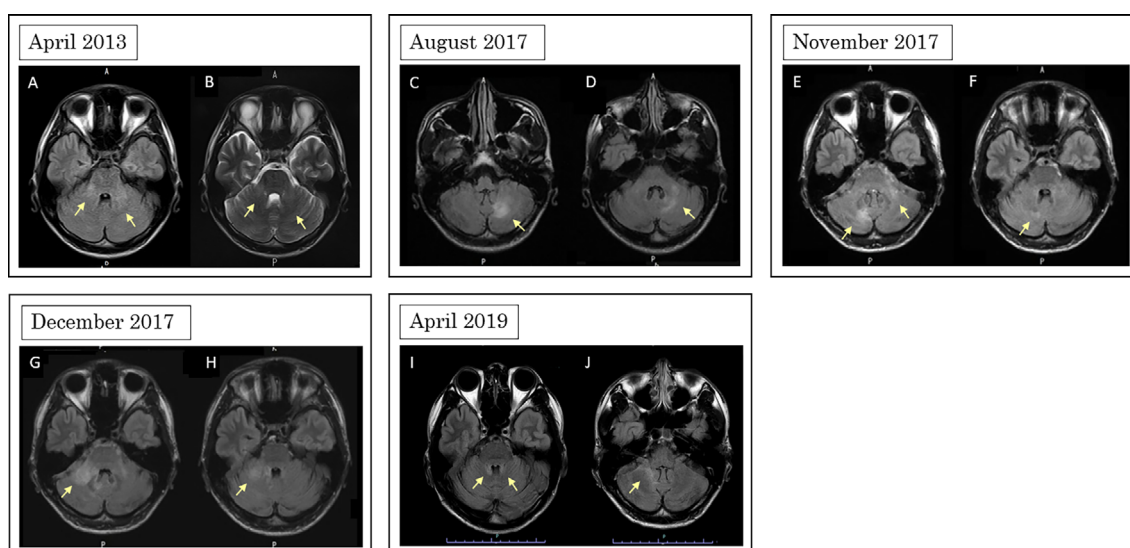
## Myelin Oligodendrocyte Glycoprotein Antibody-associated Disease with Frequent Cerebellitis

Teruyuki Ishikura<sup>1</sup>, Tatsusada Okuno<sup>1</sup>, Toshiyuki Takahashi<sup>2,3</sup> and Hideki Mochizuki<sup>1</sup>

**Key words:** myelin oligodendrocyte glycoprotein antibody-associated disease (MOGAD), myelin oligodendrocyte glycoprotein (MOG), cerebellar lesion, cerebellitis

(Intern Med 61: 3629-3630, 2022)

(DOI: 10.2169/internalmedicine.9446-22)



**Picture.**

A 21-year-old man presented with fever and headache in April 2013. Cerebrospinal fluid (CSF) showed pleocytosis, and magnetic resonance imaging revealed T2 hyperintensity in the bilateral cerebellar peduncles (Picture A, B). The patient's condition gradually improved without medication. In August, November, and December 2017, he experienced dizziness and unsteadiness of gait with a left cerebellar lesion (Picture C, D), bilateral cerebellar lesions (Picture E, F), and a right cerebellar peduncle lesion (Picture G, H), respectively, and the CSF showed pleocytosis. He responded well to methylprednisolone pulse therapy, and we initiated oral prednisolone after determining negativity for anti-SS-A, anti-SS-B, anti-thyroid peroxidase, anti-thyroglobulin, anti-glutamic acid decarboxylase, and anti-aquaporin-4 antibodies, and positivity for antibodies against myelin oligodendro-

cyte glycoprotein (MOG). In April 2019, he experienced bilateral cerebellar peduncle relapse because of drug noncompliance (Picture I, J). Although MOG antibody-associated disease (MOGAD) with cerebellitis has been reported (1, 2), this patient notably had recurrent cerebellar lesions for over seven years. Furthermore, no relapse occurred after starting oral steroids, highlighting the importance of evaluated the anti-MOG antibody status in cases of recurrent cerebellitis. Cerebellar peduncles are reportedly an early site of myelination during brain development (3, 4). We therefore speculate that the MOG expression is high in cerebellar peduncle and hemisphere.

**The authors state that they have no Conflict of Interest (COI).**

<sup>1</sup>Department of Neurology, Osaka University Graduate School of Medicine, Japan, <sup>2</sup>Department of Neurology, Tohoku University Graduate School of Medicine, Japan and <sup>3</sup>Department of Neurology, National Hospital Organization Yonezawa National Hospital, Japan

Received: January 25, 2022; Accepted: April 1, 2022; Advance Publication by J-STAGE: May 14, 2022

Correspondence to Dr. Hideki Mochizuki, hmoichizuki@neuro.med.osaka-u.ac.jp

### Acknowledgement

We thank Kimihiko Kaneko for the measurement of anti-MOG antibody and Taro Higuchi for the English language editing.

Teruyuki Ishikura and Tatsusada Okuno contributed equally to this work.

### References

1. Jurynczyk M, Gerald R, Probert F, et al. Distinct brain imaging characteristics of autoantibody-mediated CNS conditions and multiple sclerosis. *Brain* **140**: 617-627, 2017.
2. Fujimori J, Takahashi T, Matsumoto Y, et al. Two Japanese cases

of anti-MOG antibody-associated encephalitis that mimicked neuro-Behçet's disease. *J Neuroimmunol* **334**: 577002, 2019.

3. Ashikaga R, Araki Y, Ono Y, et al. Appearance of normal brain maturation on fluid-attenuated inversion-recovery (FLAIR) MR images. *AJNR Am J Neuroradiol* **20**: 427-431, 1999.
4. Matsumoto Y, Misu T, Mugikura S, et al. Distinctive lesions of brain MRI between MOG-antibody-associated and AQP4-antibody-associated diseases. *J Neurol Neurosurg Psychiatry* **92**: 682-684, 2021.

The Internal Medicine is an Open Access journal distributed under the Creative Commons Attribution-NonCommercial-NoDerivatives 4.0 International License. To view the details of this license, please visit (<https://creativecommons.org/licenses/by-nc-nd/4.0/>).