

Case Report

Ecstatic and gelastic seizures relate to the hypothalamus

Kenney Roy Roodakker ^{a,*}, Bisrat Ezra ^a, Helena Gauffin ^b, Francesco Latini ^c, Maria Zetterling ^c, Shala Berntsson ^a, Anne-Marie Landtblom ^{a,b,d}

^a Department of Neuroscience, Neurology, Uppsala University, University Hospital, Uppsala, Sweden

^b Department of Neurology, Department of Clinical and Experimental Medicine, Linköping University, Sweden

^c Department of Neuroscience, Neurosurgery, Uppsala University, Uppsala, Sweden

^d Neurology division, Clinic of Medical Specialist, Motala General Hospital, Motala, Sweden

ARTICLE INFO

Article history:

Received 21 August 2019

Received in revised form 21 January 2020

Accepted 28 February 2020

Available online 21 March 2020

Keywords:

Ecstatic seizures

Gelastic seizures

Epilepsy

Hamartoma

Hypothalamus

ABSTRACT

Ecstatic seizures constitute a rare form of epilepsy, and the semiology is diverse. Previously, brain areas including the temporal lobe and the insula have been identified to be involved in clinical expression. The aim of this report is to review changes in ecstatic seizures in a patient before and after operation of a hypothalamic hamartoma, and to scrutinize the relation to gelastic seizures. In this case, the ecstatic seizures disappeared after surgery of the hamartoma but reappeared eleven years later.

Clinical information was retrospectively obtained from medical records, interviews, and a questionnaire covering seizure semiology that pertained to ecstatic and gelastic seizures. Our findings imply a possible connection between gelastic and ecstatic seizures, originating from a hypothalamic hamartoma. To our knowledge, this location has not previously been described in ecstatic seizures. Gelastic seizures may in this case were associated with ecstatic seizures.

We speculate patients with ecstatic seizures may have an ictal activation of neuronal networks that involves the insula.

Our case may add information to the growing knowledge concerning ecstatic seizures.

© 2020 The Author(s). Published by Elsevier Inc. This is an open access article under the CC BY-NC-ND license (<http://creativecommons.org/licenses/by-nc-nd/4.0/>).

1. Introduction

Ecstatic seizures are considered a rare phenomenon and occur in people with epilepsy experiencing an altered state of consciousness and “feeling of total bliss”. Clinical examples described in the contemporary scientific literature are few. In addition, there are cases from history and religion, such as St Paul and Joan of Arc [1–5]. A recent review contains all published clinical cases so far, altogether totally 52 patients [6].

This type of seizures was initially suspected to involve the limbic system evoking “heightened self-awareness”. The patients may describe “absence of time, absence of planning or fear and a positive emotional reinforcement” [6]. The condition may be disregarded in the clinic, since some patients can be unwilling to reveal such overwhelming personal feelings to their physicians. Such patients are sometimes reluctant to take medication due to their desire to experience pleasant sensations [7].

Attempts to identify the anatomical structures involved in the complex semiology of ecstatic seizures have brought conflicting results [6,7]. Previously, the origin of ecstatic seizures has been linked to the medial and lateral *temporal lobe* [7,8]. There are descriptions of subjects with

ecstatic seizures with temporal EEG findings as wells as patients with brain tumors located in the anterior temporal lobe [8–11].

There is now substantial evidence for the involvement of the *insula* in ecstatic seizures [6,12] provided by brain imaging utilizing multimodal techniques [6,13], but also supported by cases with direct electrical stimulation of the brain using intracerebral electrodes [14,15]. The known functions of the anterior-dorsal insula supports such a hypothesis [12]. However, there are other patients with ecstatic seizures that have an epileptic focus distant to the insula such as in the left frontal gyrus [16], the right occipital lobe [17] and the parietal lobe [18]. Interestingly, in addition a few patients with generalized epilepsy have experienced ecstatic seizures to confound localization [19].

Some studies have suggested lateralization in patients with seizures manifesting emotions, especially when the seizure onset zone is in the temporal lobe and the amygdala [20]. Such a lateralization with respect to the insula was reported— with euphoric feelings lateralizing to the left (e.g. mirth), and dysphoric feelings lateralizing to the right (e.g. fear, anger, sadness) [21]. However, discrete lateralization of emotions was unable to be confirmed in a larger study of patients with ecstatic seizures [7].

Gelastic seizures occur in early childhood [22], and are known to be related to hypothalamic hamartomas [22]. The gelastic seizure is described as a “desire or pressure to laugh” that often occurs without

* Corresponding author at: Department of Neuroscience, Neurology, Uppsala University, S-751 85, Sweden.

E-mail address: kenneyroodakker@gmail.com (K.R. Roodakker).

any “funny” emotional feeling but may also be associated with a sensation of joy [23]. Seizure onset typically occurs with laughter. The patient is often aware of it, and it may occur daily. The laughter may be the only ictal manifestation during childhood, but is later often followed by multiple focal and generalized seizures due to evolution of epileptogenesis during maturation [22,24]. According to one author, it is difficult to differentiate gelastic seizures due to a hypothalamic hamartoma versus seizures with laughter of frontal or temporal cortical origin [24].

Epileptic activity within pre-existing neuronal wiring of functional networks causes seizures [25,26]. Consequently, ecstatic seizures rely on abnormal activation, probably in a dynamic interplay between the region of onset and connected target areas [12,27,28]. This is in agreement with connectomic theories on brain organization and functions, suggesting complex functional connectivity behind each symptom [29–32].

We sought to investigate changes in ecstatic seizures in one patient before and after the operation of a hypothalamic hamartoma. We hoped in this way to better understand the origin and propagation of such seizures. A secondary goal was to analyze the relationship between gelastic and ecstatic seizures.

2. Case report

2.1. Ecstatic seizures in a patient with a hypothalamic hamartoma

Semiology changes related to ecstatic seizures were evaluated over an eleven-year follow-up period including assessment before and after the resection of a hypothalamic hamartoma.

2.1.1. Medical history

A Swedish man born in 1964 to a family with no history of epilepsy or other neurological disorders experienced paroxysmal episodes of smiling and giggling beginning at the age of one, retrospectively felt to represent gelastic seizures. At six years of age, the patient had an accident, which might have been caused by a fit¹. At the age of eight, he was diagnosed with epilepsy following the onset of focal motor seizures affecting the right half of the body. Soon after, other focal seizures were described with contraction of the corner of the right side of the mouth. At times, there were associated features including eye deviation, tachycardia, impaired consciousness and dysphasia. During adolescence, the patient experienced his first generalized tonic-clonic seizure, and during this time, gelastic seizures became more frequent. The patient's earliest memories of ecstatic seizures are from the same period.²

2.1.2. Clinical investigations, surgical and pharmacological treatment

Pneumoencephalography in childhood revealed atrophy centrally and around the left ventricle. MRI later showed that the left temporal lobe was slightly smaller than the right. In adulthood, he underwent an epilepsy surgery investigation, where MRI revealed a hypothalamic hamartoma in the third ventricle.

Repeated interictal EEGs demonstrated epileptiform activity bilaterally, but most prominent in the left frontotemporal region. Ictal EEG was performed, but no focal ictal onset was identified (See Table 1). Ictal SPECT showed hyperperfusion in the frontal region of the left hemisphere. At the age of 41, the patient had surgery for a left-side predominant hypothalamic hamartoma. The surgical approach was sub-frontal, using lamina terminalis as a surgical corridor. No white matter bundles crossing the region were identified to be involved by the tumor. The surgical resection was not radical and residual hamartoma remained in the corpus mamillare.

¹ The type of accident needs to be defined relative to head injury and implications for a seizure. Please identify a “fit” as a seizure and define the type- was it focal awareness seizure or a generalized seizure?

² Insert the patient description of the ecstatic seizures at the end of the paper to be added in this paragraph.

Table 1
Investigations in a patient with a hypothalamic hamartoma and ecstatic seizures.

Ictal EEG preoperative	Six seizures are discovered during video-EEG out of sleep. The head turned slightly to the right followed by clonic jerking of the right arm and leg for 10 to 15 s. No seizure activity was identified on the EEG independent of myogenic artifact. No post-ictal features were present on EEG after the seizure. A second cluster of five seizures were recorded out of during sleep. During these seizures, the patient would raise his right arm and flex his left arm. Tonic contraction of the right side of the face was followed by evolution to a bilateral tonic clonic seizure. Normal interictal EEG was followed by muscle artifact without a focal or lateralized ictal onset identifiable. At the end of the seizure there is generalized rhythmic activity that is more pronounced over the left hemisphere.
Ictal SPECT preoperative	Ictal single photon emission computed tomography (SPECT) injection was performed seconds after the start of a seizure. The semiology reflected a focal tonic seizure involving the right side of the face as the patient was laughing. He was aphasic and the pupils were dilated bilaterally. Regional cerebral hyperperfusion was present in the cortex just above the level of the basal ganglia in the left frontal lobe
Ictal EEG postoperative	During sleep thirteen brief focal seizures manifest as tonic “stretching” of the right arm lasting approximately 5 s were identified. Only muscle artifact was present on EEG. A few of the seizures showed rhythmic generalized activity present on the EEG.
Ictal SPECT postoperative	Regional cerebral hyperperfusion during ictal SPECT localized to the left frontal lobe in front of the central sulcus. The semiology consisted of elevation of the right arm and rotation of his head to the right followed by focal motor tonic-clonic seizures for up to 3 min.

Postoperatively, a repeat video-EEG monitoring was performed, though no ictal onset was visible due to obscuration by muscle artifact during the seizures. The ictal SPECT was repeated and confirmed earlier findings showing focal hyperperfusion in left frontal lobe (See Table 1).

Since childhood the patient was treated with antiseizure medication in polytherapy. Different combinations involving carbamazepine, valproate, phenytoin, oxcarbazepine, clonazepam, topiramate, vigabatrin and zonisamide were utilized. A vagus nerve stimulator (VNS) was implanted in 2012, with improved seizure control. In 2015, antiseizure medications included levetiracetam, primidone and lacosamide.

2.1.3. Questionnaire, medical records and radiological data

We developed a questionnaire on the subjective experiences of epileptic seizure symptoms, aimed for a larger upcoming study on epileptic seizure semiology. However, it is still unvalidated and unpublished. Three patient interviews were conducted over time in order to obtain clinical information on evolving seizure semiology. In addition, serial brain MRIs in 2005 (preoperative), 2006 (postoperative) and 2017 (most recent investigation) were used to reconstruct the tumor size.

3. Results

3.1. Questionnaire, medical records and patient interviews

The clinical data obtained from the questionnaire, records and interviews together confirmed ecstatic seizures in our patient. In the questionnaire, the patient acknowledged all three criterial symptoms of ecstatic seizures [6]: intense serenity and bliss (“strong feelings of euphoria; happiness without a cause”), enhanced physical well-being (“feelings in the head”) and clarity (“a feeling of hearing and understanding everything”), see citation.

The *ecstatic seizures* were sometimes preceded by gelastic seizures, but had otherwise no particular triggers. According to the patient, the ecstatic seizures may occur in clusters of up to 30 seizures per day during a few days, followed by a few seizure-free weeks or months. They

started as a pleasant feeling that would intensify and eventually reach a climax of euphoria before completely fading away. No impairment of conscience was reported. Each seizure lasted for a few minutes. Their intensity often increased during the day to reach a climax in the afternoon and become moderate in the evening.

The *gelastic seizures* occurred in periods 5–10 times per day according to the patient. The frequency was higher during days with ecstatic seizures. No audible laughter or impairment of consciousness was reported by witnesses. The seizures seemed interlinked with the emotional state of the patient in that they could be triggered by emotions as well as reinforce whatever emotion the patient would experience at seizure onset. Melancholy would deepen and happiness would become stronger, although never as intense as during the ecstatic seizures. Seizure symptoms would increase in intensity until reaching a plateau, before fading. The gelastic seizures often fluctuated in intensity over longer time-periods before vanishing completely.

In both ecstatic and gelastic seizures there might be speech impairment and sometimes contraction of the corner of the right side of the mouth.

A couple of years before surgery the seizures intensified with frequent focal motor seizures, affecting the right side of the body and face, including problems speaking. There were also nightly tonic-clonic seizures, sometimes several times per week. They were later complicated by a persistent Todd's paresis of the right side of the body. A second opinion at an epilepsy center was performed. The generator for the focal epileptic seizures was felt to reside in the SMA – region in the left hemisphere. This was the area approximated by the regional cerebral hyperperfusion identified during the ictal SPECT. This epileptogenic zone was felt to be secondary to the hamartoma.

The patient described clear difference in the experience involving his ecstatic seizures compared to the “laughing seizures”. The ecstatic seizures were connected to an indescribable bliss, but the gelastic seizures contained a vague “funny feeling”. Heightened emotions seemed to trigger his gelastic seizures.

3.1.1. Semiology changes

After surgery in 2005, the seizures changed, both the gelastic and the ecstatic seizures vanished completely, but the severity of the focal motor seizures increased. Focal seizures with right-sided motor symptoms evolved to bilateral convulsive seizures and became longer and more intense. They remained relatively constant until about 2015 when the patient experienced return of infrequent gelastic seizures and in 2016 return of ecstatic seizures.

3.2. Analysis of morphological MRI scans

According to standard anatomic MRI, the tumor was invading the left lateral wall of the third ventricle on its lower border in close proximity to the midline. The tumor volume was 0.50 cm^3 at the preoperative MRI scan in 2005 with a prominent exophytic component within the third ventricle; the postoperative investigation in 2006 showed 0.20 cm^3 of tumor remaining within the wall of the third ventricle. Eleven years later the MRI scan showed a stable volume of 0.22 cm^3 . No ischemic lesions or other signal alterations were identified postoperatively (See Fig. 1).

4. Discussion

We describe a long-term follow-up report of a patient with a left-sided hypothalamic hamartoma who experienced a dynamic change in gelastic and ecstatic seizures before and after surgery.

4.1. Interpretation of semiology

Laughter during childhood as a semiology associated with gelastic seizures, is known to be related to hypothalamic hamartomas [22]. The network involved in the ictal manifestation of laughter has not been fully elucidated. Some authors suggest epileptiform discharges may even involve the cerebellar connections either via the cerebro-ponto-cerebellar pathway or propagation via the thalamus to the brainstem as demonstrated by ictal SPECT [33].

Hypothalamic hamartomas are often associated with multiple seizure types. While usually associated with dacrystic seizures, our case was associated with ecstatic seizures. Gelastic seizures are believed to originate from the hamartoma itself, while seizures of other semiology in such a patient may have connections with other cortical areas like the frontal, temporal and insular regions due to secondary propagation vs epileptogenesis [34]. The hypothalamus is connected by white matter tracts to several cortex regions including the insula [35,36]. Subsequently, there is a possibility that in our patient with gelastic seizures, there was an activation of neuronal networks that involves the insula. Considering that gelastic and ecstatic seizures resolved following initial surgical resection, yet focal seizures persisted, one may postulate that an independent frontal seizure focus was unmasked and dominated the clinical semiological picture with frequent focal and focal to bilateral tonic-clonic seizures. When the gelastic seizures reappeared after many years, incomplete resection of the hamartoma reestablishing ictogenesis in the hypothalamus was suspected. This appeared to

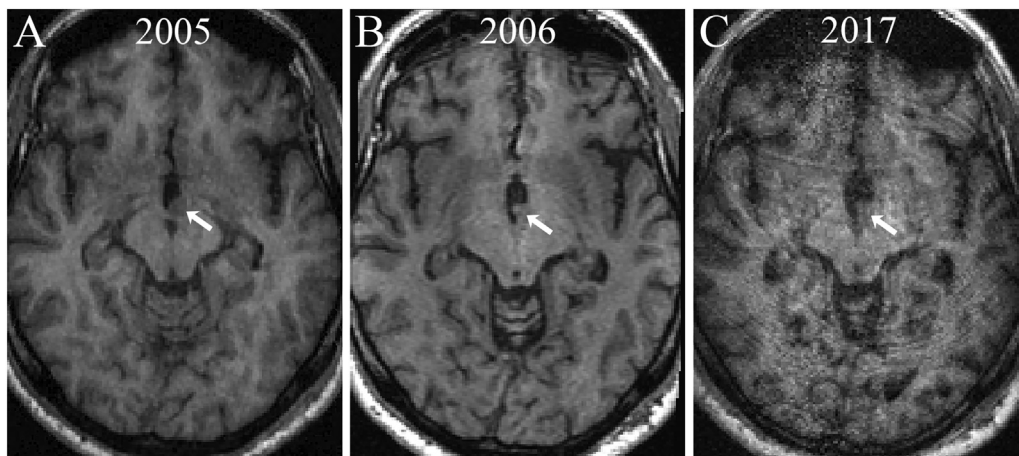


Fig. 1. Three anatomic T1-weighted MRI axial images during presurgical evaluation in 2005 (A) postsurgical evaluation in 2006 (B) and 2017 (C). Note that following initial surgical resection in 2006, the tumor volume was reduced to less than half of the original one. The arrow points to the intraventricular component of the tumor, in relation to the lateral inferior wall of the third ventricle.

subsequently trigger and realign with redevelopment of ecstatic seizures a year later reflecting a reactivated neuronal network probably involving the insula.

We also found that the patient's gelastic seizures were reflexively provoked by emotional stimuli. Furthermore, when gelastic seizures occurred, they were often found to trigger associated ecstatic seizures similar to gelastic-dacrystic seizures occurring in the same patient. There have been other reports of patients with ecstatic seizures that were able to be stimulated by specific memories and emotions [7,27]. Even minimal stimuli was capable of triggering an epileptic discharge in these individuals [37].

4.2. Limitations

Our article has several limitations. Firstly, the patient had several seizure types that changed in frequency over time so the ecstatic seizures were challenging to classify and quantify. In addition, ictal EEG demonstrated no focal seizure onset zone due to obscuration by muscle artifacts though this is not uncommon in deep midline and brief extratemporal focal seizures. Lastly, radiological follow-ups were limited by VNS though post-operative progression was not identified despite evolution of seizure semiology.

5. Conclusion

We describe the longitudinal effects in a patient with comorbid gelastic and ecstatic seizures beginning in childhood in relation to a hypothalamic hamartoma. To the best of our knowledge this has not previously been described in detail before. Our case implicates a connection between these seizure types both before and after surgery for a hypothalamic hamartoma.

We agree with other reports on ecstatic seizures that ictal semiology is due to propagation of ictal activity between cortical and subcortical regions of the brain and may change over time [6] likely involving the insula and displaying a unique combination of activation/deactivation of cortical areas leading to a changing spectrum of focal seizures [38]. More studies are warranted to better clarify the anatomical-functional networks behind the complex and fascinating manifestation of patients with gelastic-ecstatic seizures.

"Feelings in the head, a happy feeling without a cause, a pleasant feeling, a dream about something wonderful, a feeling of hearing and understanding everything, like when a dark sky is being lit up by the sun. Words cannot describe it. No other life experience is comparable" The experience of an ecstatic seizure described by the patient in our study.(Patient interview, August 2016)³

Ethics

The study was performed according to the ethical standards of the Helsinki declaration. The study was approved by the ethical committee (ethical permission number 2017/186, Uppsala) and an informed written consent was obtained. The index patient clearly stated his approval of our publication of the clinical data in this article, in written form.

Conflict of interest

The authors declare that the research was conducted in the absence of any commercial or financial relationships that could be construed as a potential conflict of interest.

³ This is a very useful paragraph that should be deleted in the Conclusion and moved to the case report.

Funding

This research did not receive any specific grant from funding agencies in the public, commercial, or not-for-profit sectors.

Acknowledgments

The authors thank Markus Fahlström, research engineer at the Department of Surgical Sciences, section of Radiology, Uppsala University Hospital, for his help in the processing and normalization of the MRI sequences. The authors also thank Johan Richter, neurosurgeon at Linköping University Hospital who investigated the patient, and Eylert Brodtkorb, professor at the Department of Neurology, St Olav's Hospital, University Hospital, Trondheim, Norway, for his interest in our study. Finally, the authors are grateful to the patient for his participation and insights into this very rare but extremely interesting condition.

References

- [1] Landsborough D. St Paul and temporal lobe epilepsy. *J Neurol Neurosurg Psychiatry* 1987;50:659–64.
- [2] Foote-Smith E, Bayne L. Joan of Arc. *Epilepsia* 1991;32:810–5.
- [3] Carrazana E, Cheng J. St Theresa's dart and a case of religious ecstatic epilepsy. *Cogn Behav Neurol* 2011;24:152–5.
- [4] d'Orsi G, Tinuper P. "I heard voices...": from semiology, a historical review, and a new hypothesis on the presumed epilepsy of Joan of Arc. *Epilepsy Behav* 2006;9:152–7.
- [5] Landtblom AM. Did St Birgitta suffer from epilepsy? A neuropathography. *Seizure* 2004;13:161–7.
- [6] Gschwind M, Picard F. Ecstatic epileptic seizures: a glimpse into the multiple roles of the insula. *Front Behav Neurosci* 2016;10:21.
- [7] Asheim Hansen B, Brodtkorb E. Partial epilepsy with "ecstatic" seizures. *Epilepsy Behav* 2003;4:667–73.
- [8] Mulder DW, Daly D. Psychiatric symptoms associated with lesions of temporal lobe. *JAMA* 1952;150:173–6.
- [9] Morgan H. Dostoevsky's epilepsy: a case report and comparison. *Surg Neurol* 1990;33:413–6.
- [10] Rideout HJ, Lang-Rollin I, Stefanis L. Involvement of macroautophagy in the dissolution of neuronal inclusions. *Int J Biochem Cell Biol* 2004;36:2551–62.
- [11] Landtblom AM. The "sensed presence": an epileptic aura with religious overtones. *Epilepsy Behav* 2006;9:186–8.
- [12] Picard F, Craig AD. Ecstatic epileptic seizures: a potential window on the neural basis for human self-awareness. *Epilepsy Behav* 2009;16:539–46.
- [13] Landtblom AM, Lindehammar H, Karlsson H, Craig AD. Insular cortex activation in a patient with "sensed presence"/ecstatic seizures. *Epilepsy Behav* 2011;20:714–8.
- [14] Isnard J, Guenet M, Sindou M, Mauguier F. Clinical manifestations of insular lobe seizures: a stereo-electroencephalographic study. *Epilepsia* 2004;45:1079–90.
- [15] Bartolomei F, Lagarde S, Scavarda D, Carron R, Benar CG, Picard F. The role of the dorsal anterior insula in ecstatic sensation revealed by direct electrical brain stimulation. *Brain Stimul* 2019;12:1121–6.
- [16] Penfield W, Kristiansen K. Epileptic seizure patterns: a study of the localizing value of initial phenomena in focal cortical seizures: Springfield. Charles C Thomas: IL; 1951.
- [17] Vera CL, Patel SJ, Naso W. "Dual pathology" and the significance of surgical outcome in "Dostoevsky's epilepsy". *Epileptic Disord* 2000;2:21–5.
- [18] Stefan H, Schulze-Bonhage A, Pauli E, Platsch G, Quiske A, Buchfelder M, et al. Ictal pleasant sensations: cerebral localization and lateralization. *Epilepsia* 2004;45:35–40.
- [19] Cabrera-Valdivia F, Jimenez-Jimenez FJ, Tejero J, Ayuso-Peralta L, Vaquero A, Garcia-Albea E. Dostoevsky's epilepsy induced by television. *J Neurol Neurosurg Psychiatry* 1996;61:653.
- [20] Guillery SA, Bujarski KA. Exploring emotions using invasive methods: review of 60 years of human intracranial electrophysiology. *Soc Cogn Affect Neurosci* 2014;9:1880–9.
- [21] Craig AD. Forebrain emotional asymmetry: a neuroanatomical basis? *Trends Cogn Sci* 2005;9:566–71.
- [22] Berkovic SF, Arzimanoglou A, Kuzniecky R, Harvey AS, Palmieri A, Andermann F. Hypothalamic hamartoma and seizures: a treatable epileptic encephalopathy. *Epilepsia* 2003;44:969–73.
- [23] Sturm JW, Andermann F, Berkovic SF. "Pressure to laugh": an unusual epileptic symptom associated with small hypothalamic hamartomas. *Neurology* 2000;54:971–3.
- [24] Panayiotopoulos CP. A clinical guide to epileptic syndromes and their treatment. . 2 ed. London: Springer-Verlag; 2010.
- [25] Engel Jr J, Thompson PM, Stern JM, Staba RJ, Bragin A, Mody I. Connectomics and epilepsy. *Curr Opin Neurol* 2013;26:186–94.
- [26] Gotman J. Epileptic networks studied with EEG-fMRI. *Epilepsia* 2008;49(Suppl. 3):42–51.
- [27] Picard F. State of belief, subjective certainty and bliss as a product of cortical dysfunction. *Cortex* 2013;49:2494–500.

- [28] Bartolomei F, Lagarde S, Wendling F, McGonigal A, Jirsa V, Guye M, et al. Defining epileptogenic networks: contribution of SEEG and signal analysis. *Epilepsia* 2017;58:1131–47.
- [29] Spencer SS. Neural networks in human epilepsy: evidence of and implications for treatment. *Epilepsia* 2002;43:219–27.
- [30] Wig GS. Segregated systems of human brain networks. *Trends Cogn Sci* 2017;21:981–96.
- [31] Besson P, Bandt SK, Proix T, Lagarde S, Jirsa VK, Ranjeva JP, et al. Anatomic consistencies across epilepsies: a stereotactic-EEG informed high-resolution structural connectivity study. *Brain* 2017;140:2639–52.
- [32] De Benedictis A, Duffau H. Brain hodotopy: from esoteric concept to practical surgical applications. *Neurosurgery* 2011;68:1709–23 [discussion 1723].
- [33] Kameyama S, Masuda H, Murakami H. Ictogenesis and symptomatogenesis of gelastic seizures in hypothalamic hamartomas: an ictal SPECT study. *Epilepsia* 2010;51:2270–9.
- [34] Mittal S, Mittal M, Montes JL, Farmer JP, Andermann F. Hypothalamic hamartomas. Part 1. Clinical, neuroimaging, and neurophysiological characteristics. *Neurosurg Focus* 2013;34:E6.
- [35] Saper CB. Hypothalamic connections with the cerebral cortex. *Prog Brain Res* 2000;126:39–48.
- [36] Lemaire JJ, Frew AJ, McArthur D, Gorgulho AA, Alger JR, Salomon N, et al. White matter connectivity of human hypothalamus. *Brain Res* 2011;1371:43–64.
- [37] Illingworth JL, Ring H. Conceptual distinctions between reflex and nonreflex precipitated seizures in the epilepsies: a systematic review of definitions employed in the research literature. *Epilepsia* 2013;54:2036–47.
- [38] Chauvel P, McGonigal A. Emergence of semiology in epileptic seizures. *Epilepsy Behav* 2014;38:94–103.