

Available online at www.sciencedirect.com

ScienceDirect

journal homepage: <http://Elsevier.com/locate/radcr>

Case Report

Congenital dermoid fistulas of the anterior chest region (CDFACR): usefulness of sonography for complete resection

Takahiro Hosokawa MD^{a,*}, Yoshitake Yamada MD^b, Hiroaki Takahashi MD^a, Yumiko Sato MD^a, Yutaka Tanami MD^a, Keisuke Suzuki MD^c, Hiroshi Kawashima MD^c, Eiji Oguma MD^a

^a Department of Radiology, Saitama Children's Medical Center, 2100 Magome, Iwatsuki, Saitama 339-8551, Japan

^b Department of Diagnostic Radiology, Keio University School of Medicine, Shinjuku, Tokyo, Japan

^c Department of Surgery, Saitama Children's Medical Center, Iwatsuki, Saitama, Japan

ARTICLE INFO

Article history:

Received 28 April 2017

Received in revised form

1 June 2017

Accepted 1 June 2017

Available online 4 July 2017

Keywords:

Dermoid cyst

Sternoclavicular joint

Branchial cleft cyst

ABSTRACT

Congenital dermoid fistulas of the anterior chest regions (CDFACRs) consist of a skin orifice at the anterior border of the sternocleidomastoid muscle with fistulas extending caudally in the subcutaneous tissue near the sternoclavicular joint. We report 2 pediatric CDFACR cases with pathognomonic sonography findings. By using sonography, we could diagnose the fistulas as CDFACRs by focusing on their location and direction and could reveal the distal side for complete resection. We suggest that sonography, which does not involve radiation or require sedation, is a better choice for the initial examination of CDFACRs than computed tomography or MRI.

© 2017 the Authors. Published by Elsevier Inc. under copyright license from the University of Washington. This is an open access article under the CC BY-NC-ND license (<http://creativecommons.org/licenses/by-nc-nd/4.0/>).

Introduction

Congenital dermoid fistulas of the anterior chest regions (CDFACRs) consist of a skin orifice at the anterior border of the sternocleidomastoid muscle with fistulas extending caudally in the subcutaneous tissue near the sternoclavicular joint [1–7]. Histologically, CDFACRs have a keratin-containing tubular structure lined with keratinizing

stratified squamous epithelium [1–7] and are perhaps connected to the sternoclavicular joint via fibrous tissue [1]. They have also been termed congenital fistulas of the sternoclavicular joint area [2], congenital cutaneous fistulas at the sternoclavicular joint [6], and congenital sternoclavicular dermoid sinuses [7].

The prevalence of CDFACR cases is unclear, and only a few case reports have described their physical diagnosis [1–8] or

Ethical Consideration: This article does not contain any studies with human subjects performed by any of the authors. And this study was approved by the ethics committee of our institution.

Competing Interests: The authors have declared that no competing interests exist.

* Corresponding author.

E-mail address: snowglobe@infoseek.jp (T. Hosokawa).

<http://dx.doi.org/10.1016/j.radcr.2017.06.003>

1930-0433/© 2017 the Authors. Published by Elsevier Inc. under copyright license from the University of Washington. This is an open access article under the CC BY-NC-ND license (<http://creativecommons.org/licenses/by-nc-nd/4.0/>).

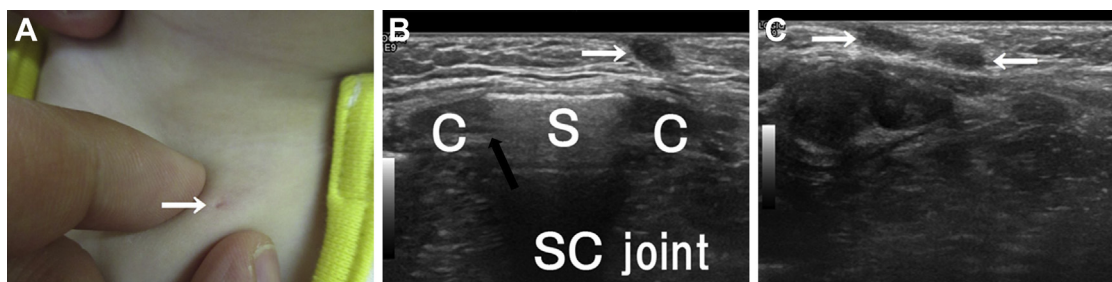


Fig. 1 – Congenital dermal fistula of the anterior chest region in an 11-month-old girl. (A) The skin orifice of the fistula (white arrow) is situated near the sternoclavicular joint in the left anterior chest region. The direction of the fistula is not apparent. (B) Transverse grayscale sonography of the anterior chest region. The image shows a hypoechoic fistula (white arrow) located at the level of the sternoclavicular joint (black arrow). (C) Longitudinal grayscale sonography of the anterior chest region. The image shows a hypoechoic fistula (white arrows) that extends caudally to the sternoclavicular joint. The direction of the fistula is not apparent. C, clavicle; S, sternum; SC, sternoclavicular.

presented computed tomography (CT) images [3,8], MRIs [1], or fistulagrams [7]. Because CDFACRs are congenital and occur in infants and children, radiation exposure should be minimal. Complete resection is required to prevent recurrence [2,7], and preoperative radiologic images of the caudal part of the fistula are important. To the best of our knowledge, sonography findings for CDFACRs have not been reported thus far. Herein, we describe 2 pediatric CDFACR cases and the pathognomonic sonography findings that confirmed their diagnosis.

Case report

The clinical details of 2 CDFACR cases are presented below.

Case 1

An 11-month-old girl, who had a cutaneous pit at the slightly superior to the left sternoclavicular joint at birth, was referred to our institution for a detailed examination. Physical examination detected a dermal pit 1 mm in diameter (Fig. 1A). Sonography without sedation revealed a fistula extending caudally from the pit toward the left sternoclavicular joint (Figs 1B and C). Surgical and histological examination showed that the fistula was lined with squamous or ciliated epithelium with a blind end in the subcutaneous tissue. These findings confirm a diagnosis of a CDFACR with no evidence of malignancy.

Case 2

A 4-year-old girl was referred to our hospital for a detailed examination owing to slight leakage of an effusion from a cutaneous pit that was detected at the slightly superior to the left sternoclavicular joint when she was an infant. Physical examination detected a pit 1 mm in diameter. Sonography without sedation showed a fistula extending caudally from the dermal pit toward the left sternoclavicular joint (Figs 2A and B). MRI performed without sedation revealed a

well-circumscribed mass in the subcutaneous tissue in the sternoclavicular joint area (Figs 2C–F). Surgical and histological examination showed that the fistula was lined with squamous or ciliated epithelium (Fig. 2G) with a blind end in the subcutaneous tissue. The skin orifice was situated at the anterior border of the sternocleidomastoid muscle and in line with the clavicular bone. These findings confirm a diagnosis of a CDFACR with no evidence of malignancy.

Discussion

Although CDFACRs are thought to be congenital, their etiology is unclear. There are 2 hypotheses. First, as suggested by Araki et al [2], CDFACRs result from disorderly fusions between the sternum and clavicle. The sternum arises from 2 bands of somatopleural mesenchyme near the median plane of the thorax about 6 weeks after fertilization, when the blastemal clavicles are appearing [9,10]. The proximal portion of the clavicle fuses to the upper part of the sternum, specifically, the interclavicular blastema [10]. In some cases, the distal region of the CDFACR extends and, via fibrous tissue, connects to the sternoclavicular joint [2]. In the present case, sonography showed that the caudal region of the CDFACR was also connected to the sternoclavicular joint. Second, as proposed by Ohno et al [6], CDFACRs originate from remnants of the fourth branchial cleft. Moreover, Liston [11] and Moore [9] suggest that the dermal pit of the fistula in the fourth branchial cleft is located near the anterior border of the sternoclavicular joint. Ohno et al [6] reported CDFACR tended to located left side as location of the pyriform sinus fistula. Our sonography findings, which showed the CDFACR on the left side of the chest and extending into the sternoclavicular joint, did not allow us to distinguish between the 2 hypotheses.

Differential diagnoses of a DFACR include a congenital dermoid cyst [12] and a congenital skin fistula with sternal cleft [13] as well as either a lateral cervical sinus/fistula or a pyriform sinus fistula [6]. However, using sonography, we can

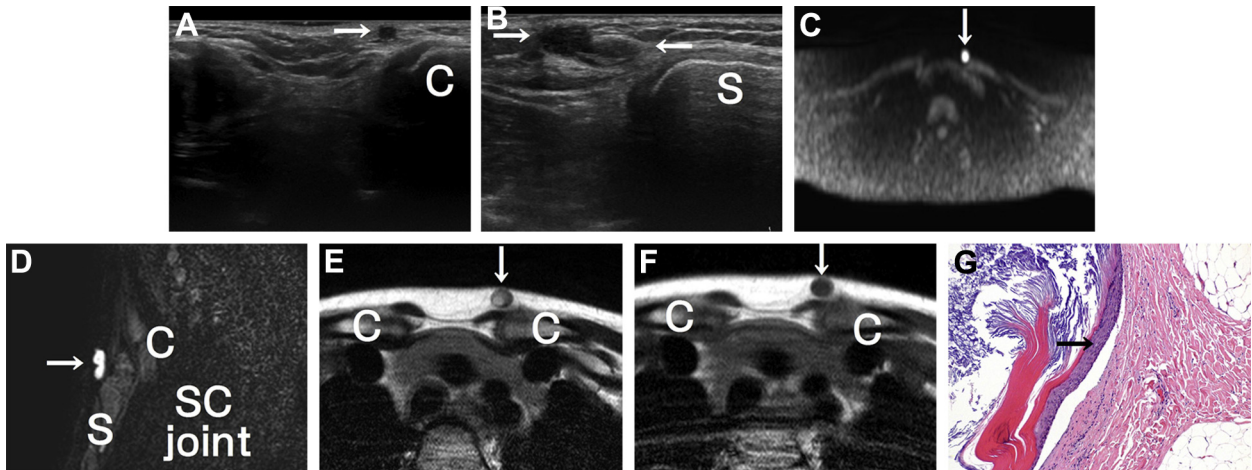


Fig. 2 – A 4-year-old girl with a congenital dermal fistula of the anterior chest region. (A) Transverse grayscale sonography of the anterior chest region. The image shows a hypoechoic fistula (white arrow) located at the level of the sternoclavicular joint (arrow). (B) Longitudinal grayscale sonography of the anterior chest region. The image shows a hypoechoic fistula (white arrows) that extends caudally to the sternoclavicular joint. (C) Diffusion-weighted MRI shows high signal intensity (white arrow) in the sternoclavicular joint area. (D) Sagittal fat-suppressed T2-weighted MRI shows high signal intensity (white arrow) extending to the sternoclavicular joint. (E) T2-weighted MRI shows a cystic lesion (white arrow) with high signal intensity near the sternoclavicular joint. (F) T1-weighted MRI shows a cystic lesion (white arrow) with low signal intensity near the sternoclavicular joint. (G) Histological examination of the fistula (100 \times , hematoxylin and eosin staining). The fistula was lined with stratified squamous epithelium (black arrow). C, clavicle; S, sternum; SC, sternoclavicular.

distinguish CDFACRs from these other fistula types. First, CDFACRs usually occur on the left side, rather than in the median portion, of the chest [2,6,7]. Congenital skin fistulas with sternal cleft occur in the midline of the anterior chest wall [13], and congenital dermoid cysts occur at the mid-ventral or mid-dorsal embryogenic fusion site [12]. However, similar to CDFACRs, dermoid cysts are thought to result from fusion of the 2 bands of the somatopleural mesenchyme of the sternum [13]. Second, the direction in which a fistula extends is useful for differentiating a CDFACR from a branchial sinus/fistula, as CDFACRs extend caudally. A lateral cervical sinus, also known as a second pharyngeal or branchial cleft fistula/sinus, arises from the remnants of the second branchial cleft, and the sinus or fistula is directed toward a region between the internal and external carotid arteries [14]. A pyriform sinus fistula originates from the remnants of the fourth branchial cleft, with the fistula extending toward the pyriform sinus [15].

Previous studies have reported CT and MRI findings for CDFACRs. CT and MRI allow visualization of the anterior sternal region including sternal anomalies [8,13] and well-circumscribed masses near the sternoclavicular joint [1], respectively. However, for visualization of cutaneous regions, sonography provides higher resolution images compared with CT or MRI. Unlike CT or MRI, sonographic examination of congenital anomalies does not involve radiation or require sedation, which carry small risks to infants and children. Furthermore, sonography provides the caudal side of CDFACRs, and it is useful to perform complete resection and prevent recurrence. For these reasons, sonography may be a better choice for the initial examinations evaluating CDFACRs than CT or MRI.

Conclusion

Sonography allowed visualization of CDFACRs extending to the sternoclavicular joint on the left side of the sternum, thus facilitating their definitive diagnosis. Detection the caudal side of CDFACRs is useful to perform complete resection. Because it does not involve radiation or require sedation, sonography is a viable option for identifying CDFACRs in infants and children.

REFERENCES

- [1] Adachi K, Yoshida Y, Yamamoto O. Symmetrical congenital dermoid fistulae of the anterior chest region. *Eur J Dermatol* 2009;19(2):181–2.
- [2] Araki N, Hamajia A, Onodera T, Uchida Y. Congenital fistula of the sternoclavicular joint area. *J Plast Reconstr Surg* 2015;35:86–91.
- [3] Ise M, Fumiyo Y, Konohana I. A case of congenital dermoid fistula at the left sternoclavicular joint. *Rinsyo Hihuka* 2014;68(3):234–8.
- [4] Matunaga W, Ishihara T, Yasuno K. Congenital dermoid fistula of the anterior chest region. *Nishinohon J Dermatol* 1994;56:34–9.
- [5] Muto J, Mori N, Konohana I, Sato H. Congenital dermoid fistula of the anterior chest region. *Clin Exp Dermatol* 2004;29(1):96–7.
- [6] Ohno M, Kanamori Y, Tomonaga K, Yamashita T, Migita M, Takezoe T, et al. Congenital cutaneous fistula at the sternoclavicular joint - not a dermoid fistula but the remnant

- of the fourth branchial (pharyngeal) cleft ? *Int J Pediatr Otorhinolaryngol* 2015;79(12):2120–3.
- [7] Willaert A, Bruninx L, Hens G, Hauben E, Devriendt K, Vander Poorten V. Congenital sternoclavicular dermoid sinus. *Int J Pediatr Otorhinolaryngol* 2016;81:65–7.
- [8] Numajiri T, Nishino K, Uenaka M, Sowa Y. Congenital dermoid fistula of the anterior chest region. *Acta Derm Venereol* 2008;88(5):538–40.
- [9] Moore K, Persaud TVN, editors. The pharyngeal apparatus. In: *The developing human*. 7th ed. Philadelphia: Saunders. 2007; pp 202-240.
- [10] O'Rahilly R, Muller F. *Human embryology and teratology*. 2nd ed. Wiley-Liss, Inc; 1996. p. 343–4.
- [11] Liston SL. Fourth branchial fistula. *Otolaryngol Head Neck Surg* 1981;89(4):520–2.
- [12] Vittore CP, Goldberg KN, McClatchey KD, Hotaling AJ. Cystic mass at the suprasternal notch of a newborn: congenital suprasternal dermoid cyst. *Pediatr Radiol* 1998;28(12):984–6.
- [13] Miyamoto T, Hosoda Y, Fujimoto Y, Fujishima M, Sasaoka R, Mihara M. Congenital skin fistula with sternal cleft. *Br J Dermatol* 1995;132(3):492–4.
- [14] Hosokawa T, Yamada Y, Sato Y, Tanami Y, Amano H, Fujiogi M, et al. Lateral cervical sinus: specific sonographic findings in two pediatric cases. *J Med Ultrason* (2001) 2015;42(4):595–9.
- [15] Hosokawa T, Yamada Y, Sato Y, Tanami Y, Amano H, Fujiogi M, et al. Five neonatal cases of pyriform sinus fistula with cervical cystic lesion: a comparison between sonography and other modalities. *J Med Ultrason* (2001) 2015;42(4):579–85.