

# Review of 3-dimensional Facial Anatomy: Injecting Fillers and Neuromodulators

David A. Sieber, MD; Jack F. Scheuer III, MD; Nathaniel L. Villanueva, MD; Ronnie A. Pezeshk, MD; Rod J. Rohrich, MD

**Summary:** To achieve consistent results utilizing facial injectables, practitioners must understand the pertinent anatomy of the forehead, temple, cheek, nose, and perioral areas. A detailed understanding of facial blood vessels, nerves, and musculature is essential for safe and effective placement of fillers and neuromodulators. (*Plast Reconstr Surg Glob Open* 2016;4:e1166; doi:10.1097/GOX.0000000000001166; Published online 14 December 2016.)

**R**ecent publications have provided indications and dosages of neuromodulators and fillers.<sup>1</sup> To achieve consistent results utilizing facial injectables, practitioners must understand the pertinent anatomy of the forehead, temple, cheek, nose, and perioral areas. Key anatomy will be highlighted for safe and efficacious injections of neuromodulators and fillers.

### FOREHEAD

To treat forehead rhytids, neuromodulator injections into the frontalis should be at least 2cm above the orbital rim to prevent brow ptosis. The corrugator supercilii and procerus muscles are the 2 main brow depressors responsible for glabellar rhytids. When injecting these muscles with neuromodulators, their inferior bony origin and superior dermal insertions must be kept in mind. (See video, Supplemental Digital Content 1, which teaches the proper techniques to safely administer injectables into the forehead and temporal regions by demonstrating on a cadaver. This video is available in the “related videos” section of the full-text article on PRSGlobalOpen.com or available at <http://links.lww.com/PRSGO/A310>.)

Likewise, fine rhytids in the glabellar region can be treated with intradermal filler injections. In multiple reviews, the glabella was the most common filler injection site leading to visual loss.<sup>2,3</sup>

*From the Department of Plastic Surgery, University of Texas Southwestern Medical Center, Dallas, Tex.*

*Presented at the The Cosmetic Bootcamp meeting, Aspen, Colo., July 8-11, 2016.*

*Received for publication May 6, 2016; accepted October 12, 2016.*

*Copyright © 2016 The Authors. Published by Wolters Kluwer Health, Inc. on behalf of The American Society of Plastic Surgeons. All rights reserved. This is an open-access article distributed under the terms of the Creative Commons Attribution-Non Commercial-No Derivatives License 4.0 (CCBY-NC-ND), where it is permissible to download and share the work provided it is properly cited. The work cannot be changed in any way or used commercially without permission from the journal.*

DOI: 10.1097/GOX.0000000000001166

### TEMPORAL REGION

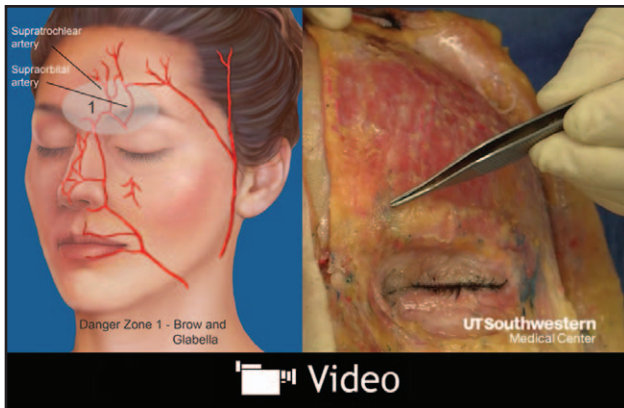
The frontal branch of the temporal artery traverses the temporal hollow within the temporoparietal fascia. (See video, Supplemental Digital Content 2, which teaches the proper techniques to safely administer injectables into the cheeks by demonstrating on a cadaver. This video is available in the “related videos” section of the full-text article on PRSGlobalOpen.com or available at <http://links.lww.com/PRSGO/A311>) Cannulation of this branch can lead to ischemia and blindness via anastomoses with the supraorbital and supratrochlear arteries. Therefore, inject into the superficial subcutaneous plane taking care to stay above the temporoparietal fascia.

Neuromodulator injections into the lateral orbicularis oculi treat periorbital rhytids. Along the lateral orbital rim, injections begin below the tail of the brow, proceeding inferiorly to the vertical plane of the lateral canthus. Injections should be subdermal because deeper ones can paralyze the zygomaticus major, weakening the ipsilateral smile.

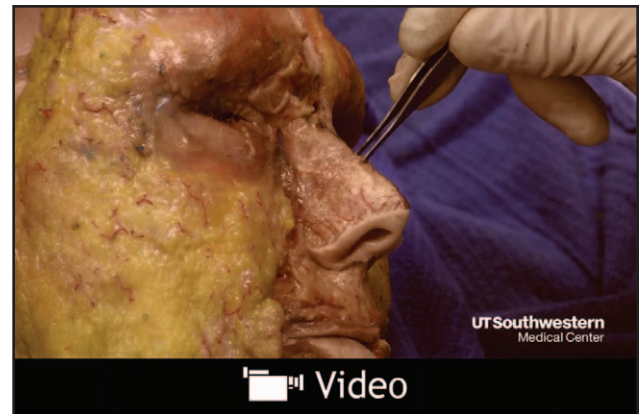**Disclosure:** Dr. Rohrich receives instrument royalties from Eriem Surgical, Inc., and book royalties from CRC Press and Taylor and Francis Publishing. Neither of the other authors has any financial disclosures. The Article Processing Charge for this proceeding was paid for by Allergan plc, as part of an unrestricted educational grant to support the entire Cosmetic Boot Camp 2016 Supplement. Allergan plc had no involvement in the production, selection, or review of this proceeding supplement.

Supplemental digital content is available for this article. Clickable URL citations appear in the text.

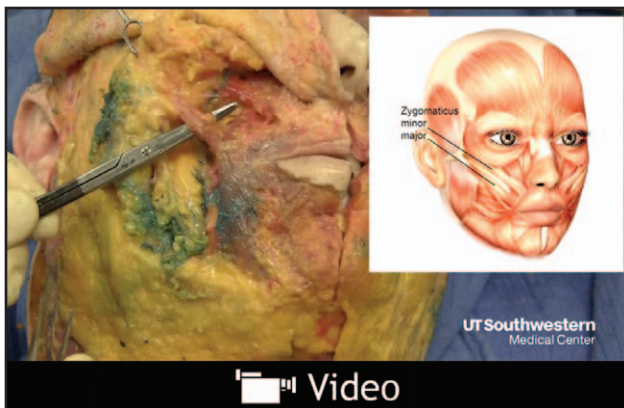
**Cosmetic Bootcamp:** PRS Global Open proudly publishes the proceedings from The Cosmetic Bootcamp July 2016 meeting that was held in the St Regis Resort in Aspen, Colorado on July 8-11th, 2016.



**Video Graphic 1.** Anatomical approach to injectables in the forehead and temporal regions teaches the proper techniques to safely administer injectables into the forehead and temporal regions by demonstrating the techniques on a cadaver. This video is available in the “related videos” section of the full-text article on PRSGlobalOpen.com or available at <http://links.lww.com/PRSGO/A310>.



**Video Graphic 3.** Anatomical approach to injectables in the nose and lips teaches the proper techniques to safely administer injectables into the nose and perioral regions by demonstrating on a cadaver. This video is available in the “related videos” section of the full-text article on PRSGlobalOpen.com or available at <http://links.lww.com/PRSGO/A312>.



**Video Graphic 2.** Anatomical approach to injectables in the cheeks teaches the proper techniques to safely administer injectables into the cheeks by demonstrating on a cadaver. This video is available in the “related videos” section of the full-text article on PRSGlobalOpen.com or available at <http://links.lww.com/PRSGO/A311>.

## CHEEK

Aesthetic facial contours are formed through sustained fullness within the facial fat compartments, most importantly the deep and high (superficial) malar compartments.<sup>4</sup> Clinically, the infraorbital foramen lies slightly less than a fingerbreadth below the infraorbital rim in the vertical plane immediately lateral to the medial limbus. When injecting a filler into the malar fat compartments, stay lateral to the infraorbital foramen. Injections can be superficial or deep depending on the location of volume loss.

In the inferior two thirds of the nasolabial fold, filler injections should be in the superficial subcutaneous tissue or deep dermal plane so as to avoid the facial artery. Because the facial artery becomes superficial superiorly, injections in the superior third of the nasolabial fold should be in the deep dermal or in the preperiosteal plane.

## NOSE

The nasal vessels are superficial. To avoid vessel injury or compression, filler injections into the tip and dorsum should be in the preperiosteal and preperichondrial layers. Because the lateral nasal artery runs in the subdermal plexus 2 to 3 mm superior to the alar groove, injections into the sidewall should be above this landmark.<sup>5</sup> (See video, **Supplemental Digital Content 3**, which teaches the proper techniques to safely administer injectables into the nose and perioral regions by demonstrating on a cadaver. This video is available in the “related videos” section of the full-text article on PRSGlobalOpen.com or available at <http://links.lww.com/PRSGO/A312>.) Proceed with extreme caution in patients who have had multiple nasal surgeries as the remaining blood supply to the nose is unpredictable.

## PERIORAL

Upper and lower lip filler injections should be less than 3 mm deep and within vermilion-cutaneous border or the dry vermilion. Commissure injections proceed in the superficial subcutaneous plane within a thumb breadth of the angle of the mouth. Both techniques avoid injury to the labial and facial arteries, respectively.

Various locations of injections of neuromodulators exist in the perioral area.<sup>6</sup> It is important to understand the relationship between the depressor anguli oris and the depressor labii inferioris. Neuromodulator injections of the depressor anguli oris should be superficial and immediately medial to the mandibular ligament to avoid inadvertent injection of the depressor labii inferioris.

## CONCLUSIONS

A detailed knowledge of facial anatomy allows safe and efficacious injections of neuromodulators and fillers.

**Rod J. Rohrich, MD**

*The Dallas Plastic Surgery Institute  
9101 North Central Expressway  
Dallas, TX 75231  
E-mail: rod.rohrich@dpsi.org*

#### REFERENCES

1. Rohrich RJ. The “soft-tissue fillers and neuromodulators: international and multidisciplinary perspectives” supplement. *Plast Reconstr Surg.* 2015;136:1S–3S.
2. Ozturk CN, Li Y, Tung R, et al. Complications following injection of soft-tissue fillers. *Aesthet Surg J.* 2013;33:862–877.
3. Li X, Du L, Lu JJ. A novel hypothesis of visual loss secondary to cosmetic facial filler injection. *Ann Plast Surg.* 2015;75:258–260.
4. Rohrich RJ, Pessa JE. The fat compartments of the face: anatomy and clinical implications for cosmetic surgery. *Plast Reconstr Surg.* 2007;119:2219–2227; discussion 2228.
5. Rohrich RJ, Gunter JP, Friedman RM. Nasal tip blood supply: an anatomic study validating the safety of the transcolumellar incision in rhinoplasty. *Plast Reconstr Surg.* 1995;95:795–799; discussion 800–801.
6. Trévidic P, Sykes J, Criollo-Lamilla G. Anatomy of the lower face and botulinum toxin injections. *Plast Reconstr Surg.* 2015;136:84S–91S.