



## Case report

## A case of caecal “PECOMA”: An uncommon entity

Azharuddin Razak. O, Christopher L. Varela, Manar Mohammed Ahmed Nassr, Mi Jang, Yoon Dae Han\*

Department of General Surgery, Mother Hospital Pvt Ltd, India

Division of Colorectal Surgery, Department of Surgery, Severance Hospital, Yonsei University College of Medicine, Seoul, Republic of Korea

Department of Pathology, National Health Insurance Service Ilsan Hospital, Goyang, Republic of Korea

## ARTICLE INFO

## Keywords:

Case report

PEComa

Perivascular epithelioid cells (PEC)

## ABSTRACT

**Introduction and importance:** World Health Organization (WHO) defines PEComa as a mesenchymal tumor composed of histologically and immunohistochemically distinctive perivascular epithelioid cells. The symptoms and clinical signs of PEComa patients are nonspecific. Hence, diagnosis is usually difficult. Since it's a rare diagnosis, further research might help in understanding the disease better.

**Case presentation:** The patient in this study was an asymptomatic patient, who did colonoscopy as part of a regular check-up. A submucosal cecal tumor was detected in colonoscopy, and apart from that, all other investigative parameters were within normal limits.

**Clinical discussion:** Laparoscopic ileocecectomy was performed, and the histopathology report was suggestive of Pecomatosis (PEComa – Perivascular epithelioid cell tumor). The PEComas, neoplasms with perivascular epithelioid cell differentiation, are mesenchymal tumors composed of histologically and immunohistochemically distinctive perivascular epithelioid cells (PEC). The characteristic features of PEC are the positivity of melanocytic markers and smooth muscle markers.

**Conclusion:** Perivascular epithelioid tumors are mostly rare in the gastrointestinal tract, and even more unusual to be detected in Cecum. Surgery is the mainstay of the treatment, although, adjuvant therapy has been tried in recent times. The patients have to be kept in close follow-up, as there are reported cases of recurrences and distant metastasis.

## 1. Introduction

According to Masson P [1], the first description of Perivascular epithelioid cell (PEC) was given by Apitz in 1943 [2], as an “abnormal myoblast” in a renal Angiomyolipoma (AML). In the early 1990s, further description of this distinctive cell type was done by Maurizio Pea and Bonetti F [3]. In 1991, Bonetti et al. described the unusual cellular link among clear cell ‘sugar’ tumor (CCST) of the lung, the epithelioid clear cell component of angiomyolipoma (AML) of the kidney and liver and lymphangiomyomatosis (LAM). Zamboni et al. proposed the term “PEComa” for mesenchymal tumors that contain epithelioid cells that had a close association with blood vessels along with evidence of smooth muscle and melanocytic differentiation [4]. According to the World Health Organization, PEComa is “a mesenchymal tumor composed of histologically and immunohistochemically distinctive perivascular epithelioid cells” [5]. Besides, there is no known normal tissue

counterpart to PEC. Lu B et al. reported Gastrointestinal (GI) related PECOMA recently, but not many cases are reported in the literature [6].

## 2. Case report

This case report has been reported in line with the SCARE 2020 criteria [7]. A 69-years-old female patient was referred to our institution for a cecal submucosal tumor. She underwent colonoscopy for a regular check-up, and a cecal submucosal tumor was detected. She had no symptoms, and her physical examination was normal. Her laboratory tests were also normal, including the tumor markers. She had no relevant past medical history. Computed tomography (CT) of the abdomen didn't show any bowel wall thickening or enlarged lymph nodes. The first institution, where she consulted in the beginning, diagnosed her disease as submucosal GIST (gastrointestinal stromal tumor) of the cecum, however, they didn't perform any procedure or biopsy.

\* Corresponding author at: Department of General Surgery, Severance Hospital, Yonsei University, Seoul, Republic of Korea.

E-mail address: [acylyoon@yuhs.ac](mailto:acylyoon@yuhs.ac) (Y.D. Han).

<https://doi.org/10.1016/j.ijscr.2021.106689>

Received 20 November 2021; Received in revised form 10 December 2021; Accepted 14 December 2021

Available online 21 December 2021

2210-2612/© 2021 Published by Elsevier Ltd on behalf of IJS Publishing Group Ltd. This is an open access article under the CC BY-NC-ND license

(<http://creativecommons.org/licenses/by-nc-nd/4.0/>).

On explorative laparoscopy, there were no evident features of malignancy or metastasis. Hence, we performed a laparoscopic ileocecectomy avoiding a right hemicolectomy. However, due to the uncertainty of the primary lesion, the ileocolic pedicle was ligated at its origin to achieve an oncologic resection. Histology of the specimen revealed as PEComatosis. The patient was discharged from the hospital without any complications. The patient has been on follow-up for 48 months and there are no evidence of any recurrence or metastasis (Figs. 1–6).

### 3. Discussion

The PEComas, neoplasms with perivascular epithelioid cell differentiation, are mesenchymal tumors composed of histologically and immunohistochemically distinctive perivascular epithelioid cells. The characteristic features of PEC are the positivity of melanocytic markers, such as Human melanoma black-45 (HMB-45), Melan-A, tyrosinase, microphthalmia transcription factor, and NKI/C3 [8]. Also, smooth muscle markers can be shown, such as smooth muscle actin, pan-muscle actin, muscle myosin and calponin. Our patient shows positivity in actin, HMB45 and vimentin.

The histogenesis of PEComas is unknown. There is no consensus about the diagnostic criteria of malignant PEComa. PEComas can usually take both benign and malignant courses [9]. Features suggesting malignancy are tumor size more than 5 cm, vascular invasion, invasive growth, tumor necrosis, high-grade atypia, high cellularity, and 1 mitotic figure  $>/50$  high-power field (400 $\times$ ) [10,11]. In our case, there are no features of malignancy. TSC2 (tuberous sclerosis) deletion and TFE3 (Transcription Factor Binding to IGHM Enhancer 3) rearrangement had been reported in PEComas [12], but we did not examine chromosomal or genetic abnormality of our patient.

The most common site of PEComa is the kidney, but the cases of lungs, uterus, lymphatics are not uncommon [3]. In 2004, Birkhaeuser et al. reported the first case of PEComa in the colon [13]. Unlike PEComas occurring in other organs, PEComas in the GI tract show no differences in prevalence in both male and female patients, with regards to the female predominance in PEComa tumors at other sites [3,14]. The PEComas affecting the GI tract are classified under PEComas-not otherwise specified (PEComa-NOS) type. As GI PEComas-NOS are rare and have relatively short follow-up periods, further details about prognostic factors, malignancy criteria and biologic behaviors are limited.

The symptoms and clinical signs of PEComa patients are nonspecific. It is related to the involved organ, site, and size of the tumor. The most common symptom of PEComas in the colon is abdominal pain. Melena, rectal bleeding, and obstructions also have been reported. There are no specific signs in PEComas, and the diagnosis is usually made with imaging studies. Computed tomography, magnetic-resonance imaging and ultrasonography can be used, but there are no criteria confined to diagnosing PEComa [15]. In our case, both CT abdomen and

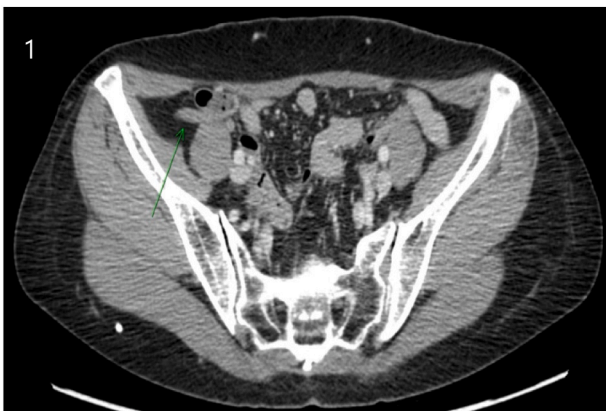

Fig. 1. CT scan of the abdomen.

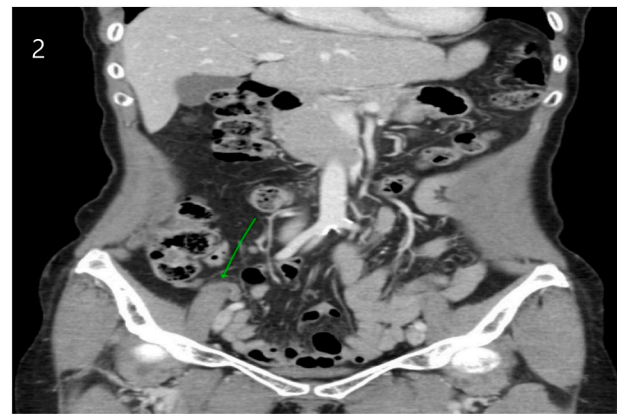


Fig. 2. Appendix and cecum are seen normal, without any wall thickening or enlarged lymph nodes.

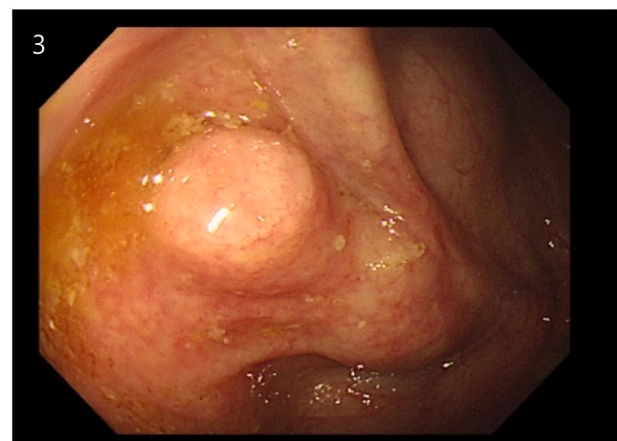


Fig. 3. A submucosal tumor was found in cecum during colonoscopy.

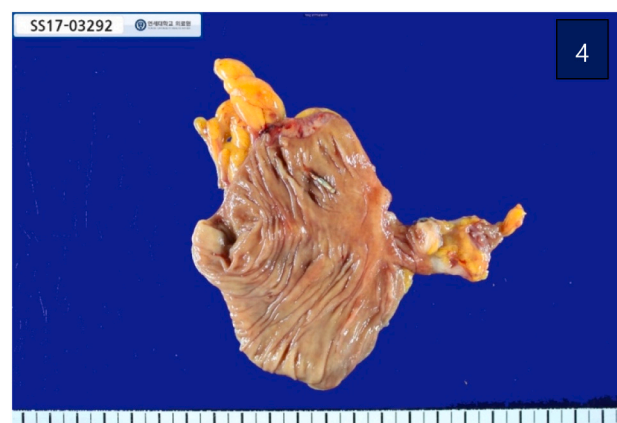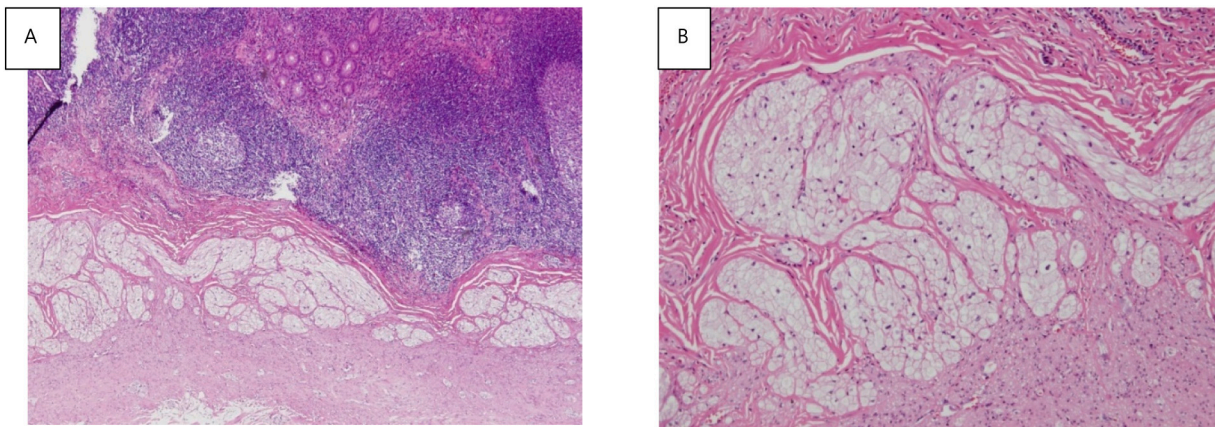


Fig. 4. Gross pathology of lesion. Appendix was impacted with mucinous contents. There are no definite lesions visible in colon and terminal ileum.

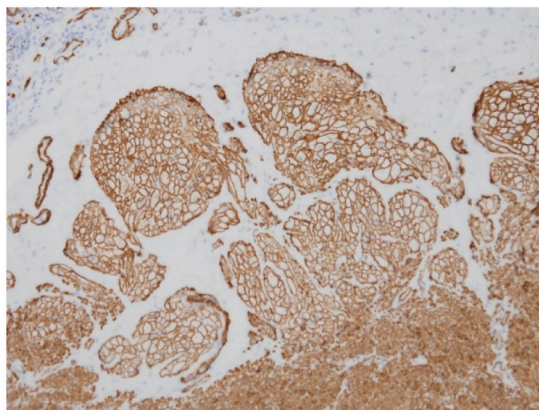
ultrasonography didn't help in finding the lesion, however, a routine colonoscopy was the reason for diagnosing the lesion.

The treatment of choice for PEComa is surgery, and a combination with radiotherapy can be considered if there are any features of metastasis. Treatment for unresectable PEComa is limited, and there is no standard chemotherapeutic regimen for PEComa. Clinical trials of mTOR inhibitors as target agents are reported. Sirolimus and everolimus showed favorable responses among mTOR inhibitors [11]. mTOR

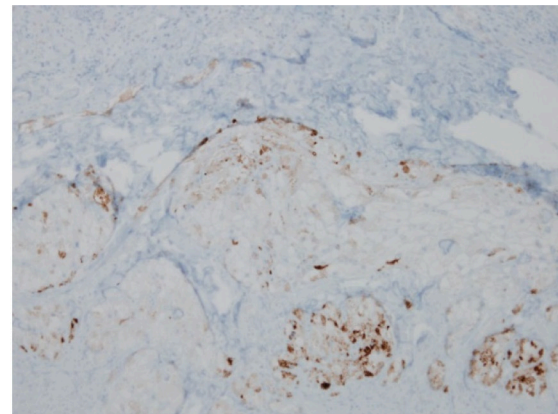




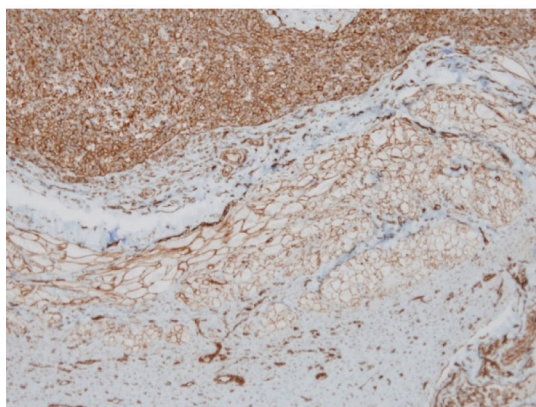
**Fig. 5.** Microscopic finding, hematoxylin and Eosin (HE) stain of the specimen. A)  $\times 40$  and B)  $\times 100$ . Submucosal and muscular proliferation of epithelioid cell clusters with clear cytoplasm consistent with PEComatosis. Tumor extended to submucosa and muscularis propria. There was no lymphovascular invasion or perineural invasion.



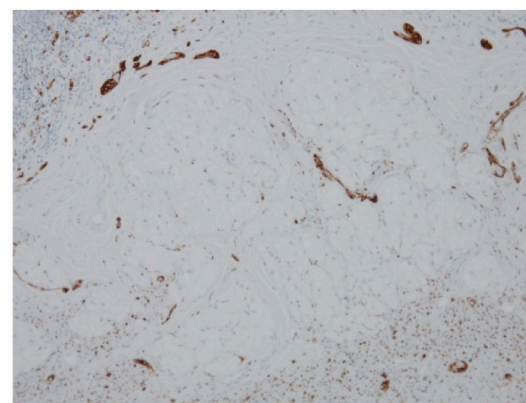
A) Actin (SMA) stain, x 100



B) HMB45 stain, x100



C) Vimentin, x 100



D) S-100, x 100

**Fig. 6.** Immunohistochemical stains of the specimen. The specimen showed positive in actin (SMA), HMB45, and vimentin S-100 showed negative stain in this patient.

inhibitors have shown some effects against the disease, as they are directly related to the pathogenesis of this cancer. Lack of *TSC2* gene involvement in TFE3-rearranged PEComas suggests that these patients may also not respond to mTOR inhibitors [11]. Therefore, further studies must be done to know the efficacy of such drugs.

Metastasis or recurrence has been reported on gastrointestinal tract

PEComa [14]. Even though there aren't many studies based on patients affected with PEComa in the gastrointestinal tract, Folpe et al., had conducted a study with 24 patients with PEComas [10]. These cases included a variety of visceral and somatic soft tissue sites including the gastrointestinal tract. Approximately 26 months follow-up in 18 PEComa cases revealed that 2 tumors recurred locally, 3 metastasized

hematogenously to liver, bone and lung and one of them died. Hence, our patient has been on follow-up with CT abdomen annually for 48 months and there aren't any features of recurrence or metastasis.

To conclude, PEComa is a rare disease in which plenty of studies is being conducted to understand more about the pathogenesis, as well as the management criteria. However, surgical management and close follow-up are warranted in every case of PEComa.

#### Sources of funding

None.

#### Ethical approval

Study exempted from ethical approval.

#### Consent

Written informed consent has been obtained.

#### Author contribution

Dr. Yoon Dae Han - Study concept, Study design, Data collection, data interpretation, writing.

Dr. Azharuddin Razak – Study design, Data collection, data interpretation, writing.

Dr. Mi Jang – Data collection.

Dr. Cristopher Varela -writing, critical revision.

Dr. Manar MA Nassr – writing, critical revision.

#### Research registration

N/a.

#### Guarantor

Dr. Yoon Dae Han.

#### Declaration of competing interest

None.

#### References

- [1] P. Masson, Origin of fibromyolipomas, in: *Human Tumors. Histology, Diagnosis and Technique*, Wayne State University Press, Detroit, 1970, pp. 735–736.
- [2] K. Apitz, Die Geschwülste und Gewebsmissbildungen der Nierenrinde. II Mitteilg. Die mesenchymalen Neubildungen, *Virchows Arch* 311 (1943) 306–327.
- [3] K. Thway, C. Fisher, PEComa: morphology and genetics of a complex tumor family, *Ann. Diagn. Pathol.* 19 (2015) 359–368.
- [4] G. Zamboni, M. Pea, G. Martignoni, et al., Clear cell “sugar” tumor of the pancreas. A novel member of the family of lesions characterized by the presence of perivascular epithelioid cells, *Am.J. Surg Pathol.* 20 (1996) 722–730.
- [5] A.L. Folpe, Neoplasms with perivascular epithelioid cell differentiation (PEComas), in: Fletcher CDM, K.K. Unni, J. Epstein, F. Mertens (Eds.), *Pathology and genetics of tumours soft tissue and bone. Series : WHO Classification of tumours*, Press, Lyon, 2002, pp. 221–222.
- [6] B. Lu, C. Wang, J. Zhang, R.P. Kuiper, M. Song, X. Zhang, S. Song, A.G.V. Kessel, A. Iwamoto, J. Wang, H. Liu, Perivascular epithelioid cell tumor of gastrointestinal tract: case report and review of the literature, *Medicine (Baltimore)* 94 (3) (2015 Jan), e393.
- [7] R.A. Agha, T. Franchi, C. Sohrabi, G. Mathew, A. Kerwan, SCARE Group, The SCARE 2020 guideline: updating consensus Surgical CAse REport (SCARE) guidelines, *Int. J. Surg.* 84 (2020) 226–230, <https://doi.org/10.1016/j.ijsu.2020.10.034>. Dec.
- [8] G. Martignoni, M. Pea, D. Reghellin, G. Zamboni, F. Bonetti, PEComas: the past, the present and the future, *Virchows Arch.* 452 (2008) 119–132.
- [9] C. Fletcher, Pathology and genetics of tumors of soft tissue and bone, in: *World Health Organization Classification of Tumors 4*, 2002, pp. 35–46.
- [10] A.L. Folpe, T. Mentzel, H.A. Lehr, C. Fisher, B.L. Balzer, S.W. Weiss, Perivascular epithelioid cell neoplasms of soft tissue and gynecologic origin: a clinicopathologic study of 26 cases and review of the literature, *Am. J. Surg. Pathol.* 29 (2005) 1558–1575.
- [11] P.L. Rutkowski, J.T. Mullen, Management of the “other” retroperitoneal sarcomas, *J. Surg. Oncol.* 117 (2018) 79–86.
- [12] C.D. Fletcher, The evolving classification of soft tissue tumours—an update based on the new 2013 WHO classification, *Histopathology* 64 (2014) 2–11.
- [13] F. Birkhaeuser, C. Ackermann, T. Flueckiger, et al., First description of a PEComa (perivascular epithelioid cell tumor) of the colon: report of a case and review of the literature, *Dis. Colon Rectum* 47 (2004) 1734–1737.
- [14] L.A. Doyle, J.L. Hornick, C.D. Fletcher, PEComa of the gastrointestinal tract: clinicopathologic study of 35cases with evaluation of prognostic parameters, *Am J Surg Pathol* 37 (2013) 1769–1782, o.
- [15] Z. Chen, S. Han, J. Wu, et al., A systematic review: perivascular epithelioid cell tumor of gastrointestinal tract, *Medicine (Baltimore)* 95 (2016), e3890.