

Multiple synchronous acute Marjolin ulcer: A report of 2 cases and literature review



Misty Hobbs, BSc,^a Elliott Campbell, BSc,^a K. Adam Braun, MD, FAAD,^b and Lesley Wong, MD, FACS^c
Lexington, Kentucky

Key words: acute Marjolin ulcer; burn scars; multiple; squamous cell carcinoma; synchronous.

INTRODUCTION

Marjolin ulcers are rare and aggressive cutaneous malignancies that arise in previously injured, chronically inflamed, or irritated skin. Most often, they manifest as squamous cell carcinomas (SCC) after burns. Marjolin ulcers occur in 2 forms, acute and chronic. Chronic Marjolin ulcers develop at least 12 months after an injury, whereas the acute form occurs within 12 months. The acute form is exceedingly rare, with scant representation in the literature.¹ The synchronous occurrence of multiple Marjolin ulcers is rarer still, with no published case in the literature thus far. We present 2 cases of multiple acute Marjolin ulcers arising synchronously in areas of healing burns.

CASE REPORTS

Case 1

A 66-year-old woman with a history of multiple SCCs of the skin was evaluated in our clinic 1 month after sustaining a 4% total body surface area partial-thickness grease burn on her shins bilaterally. On evaluation, there was a significant amount of dried, sloughed skin remaining. On follow-up 3 weeks later, after using bacitracin ointment and daily showers to debride nonviable skin, her burn sites appeared to be healing well, with mild color change and tenderness to light touch.

Five new lesions were noted at this time (7 weeks postburn), all located within the perimeter of the burned area. These consisted of 5 discrete 0.2- to 1.2-cm × 0.2- to 1.1-cm, well-circumscribed, friable, hyperkeratotic, white-tan papules and nodules (Figs 1-3).

Abbreviation used:

SCC: squamous cell carcinoma

Pathology findings via excision biopsy confirmed 3 of 5 lesions as well-differentiated SCC with negative margins (Fig 4). The remaining 2 were histologically diagnosed as marked solar elastosis with focal actinic changes, and actinic keratosis with background solar elastosis. A diagnosis of multiple synchronous acute Marjolin ulcers was made because of the clinical scenario, pathology findings, and short latency period. Thus far (2 years postexcision), there has been no evidence of recurrence with yearly dermatologic examinations. A dermatologist had seen the patient 1 month before the burn and did not appreciate any cutaneous abnormalities in or around the area of the future burn sites. The patient did incidentally have a biopsy-proven SCC at a separate location during this encounter.

Case 2

A 64-year-old man with no history of skin cancer was evaluated after sustaining a 12% total body surface area partial-thickness flame burn involving his face, arms, and legs while burning brush with gasoline. One month later, the burn site was well healed; however, 2 tender nodules measuring 1.0 × 1.0 cm each were observed by the patient's home health nurses. Both were in areas of healed burns, one on the left knee and the other on the right forearm. At 2 months postburn, he presented to the Veterans Affairs dermatology clinic with these lesions, which had grown into a 2.8- × 2.7-cm

From University of Kentucky College of Medicine^a and the Divisions of Dermatology^b and Plastic Surgery,^c University of Kentucky College of Medicine.

Funding sources: Funding for submission comes from University of Kentucky College of Medicine Dermatology and Plastic Surgery research fund.

Conflicts of interest: None disclosed.

Correspondence to: Misty Hobbs, BSc, 135 Regency Point Path, Lexington, KY 40503. E-mail: misty.hobbs@uky.edu.

JAAD Case Reports 2019;5:511-3.
2352-5126

© 2019 by the American Academy of Dermatology, Inc. Published by Elsevier, Inc. This is an open access article under the CC BY-NC-ND license (<http://creativecommons.org/licenses/by-nc-nd/4.0/>).

<https://doi.org/10.1016/j.jidcr.2019.04.002>

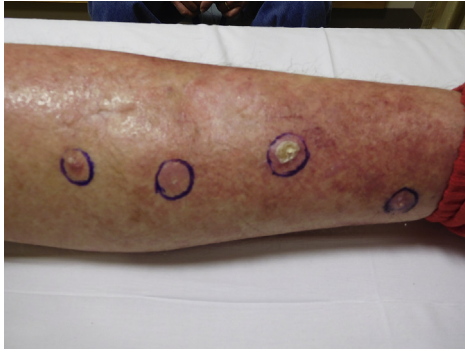

Fig 1. Four friable lesions arose synchronously on the burned area of the patient's left calf 7 weeks postburn. An additional pretibial lesion arose simultaneously, also in an area that had been burned (not pictured).

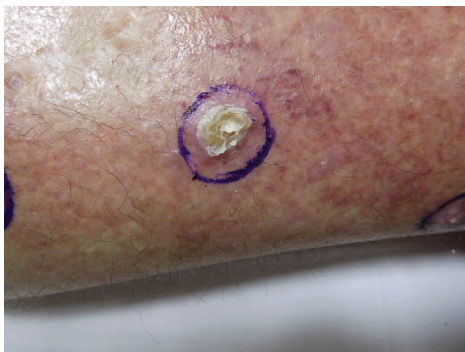

Fig 2. This 1.2- × 1.1- × 0.3-cm hyperkeratotic, irregular, tan-white to tan-yellow exophytic lesion was excised with clear margins. Pathology findings confirmed well-differentiated SCC.

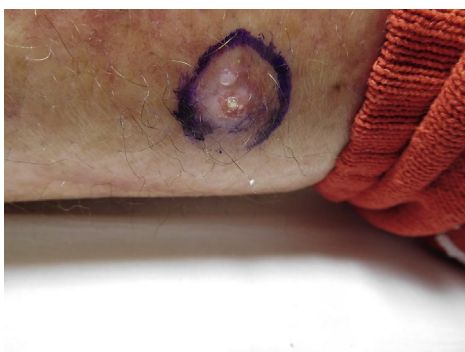


Fig 3. This 0.9- × 0.6- × 0.2-cm firm, white, slightly raised lesion was excised with clear margins. Pathology findings confirmed well-differentiated SCC.

ulcerated polypoid mass on the right forearm and a 2.6- × 1.2-cm well-circumscribed, circular white nodule on the left knee. Biopsy from both lesions found well-differentiated SCCs. A diagnosis of multiple synchronous acute Marjolin ulcers was made

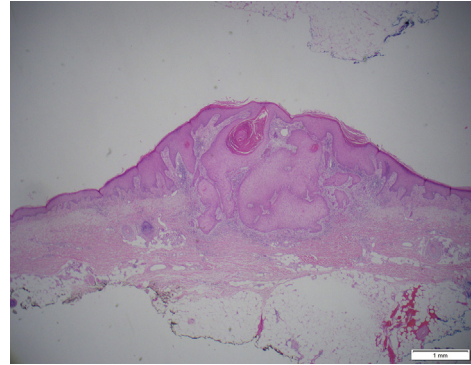


Fig 4. Pathology findings for 3 of the 5 specimens showed well-differentiated SCC.

because of the clinical scenario and short latency period, and both neoplasms were ultimately excised with negative margins. Thus far (2.5 years postexcision), there has been no evidence of recurrence with yearly dermatologic examinations. No suspicious lesions had been reported in the affected areas before acquiring the burn.

DISCUSSION

In 1828, Jean Nicholas Marjolin described ulcerative lesions arising in chronic scar tissue, and in 1903, Da Costa coined the term *Marjolin ulcer*.^{2,3} Marjolin ulcers are considered rare, occurring in 0.77% to 2.0% of burn scars and comprise 2% of all SCCs.^{1,4} The acute form is rarer still, with relatively few case reports. One retrospective study found that 7% of Marjolin ulcers were of the acute variety.⁵

To date, no concrete pathophysiology for the development of Marjolin ulcers, whether in burns or other wound types, has been established. Some possible mechanisms relevant to our cases include chronic inflammation, toxin release, poor vascularization of scar tissue, immunologic privilege, and co-carcinogen theory.^{3,4,6,7} The co-carcinogen theory, which suggests chemical and/or physical injury stimulates proliferation of an already existing yet latent malignant cell in the setting of immunologically unprivileged tissue, is especially pertinent given the rapid, multiple, synchronous nature of these cases.⁶

A review of the literature elicits only one other reported case of multiple Marjolin ulcers, which were of the chronic type (unlike our cases, which were of the acute type). No explicit information is provided regarding timing of development between ulcers in this case, but the patient presented to care with all of the lesions present; thus, they may have arisen synchronously.⁸ A handful of other studies suggest multiple ulcers without explicit discussion of

multiplicity or timing. After an extensive review of the literature, we believe that our cases are the first to clearly document multiple synchronous Marjolin ulcers; however, it is possible that some of the more ambiguous cases in the literature also demonstrated this phenomenon.

Although the distinction between acute and chronic Marjolin ulcers has been widely adopted, it may be clinically an arbitrary one, as the most extensive review of acute Marjolin ulcers did not find any clinical, histologic or prognostic differences between the 2.⁹ However, there may be a difference in the pathophysiology when a skin cancer arises within weeks of the burn wound healing.¹⁰ Because of their rarity, it is unclear if multiple synchronous Marjolin ulcers are more likely to occur in acute versus chronic Marjolin ulcers. Nevertheless, it is important for dermatologists and other physicians who provide care for patients with burns to be aware that neoplasms may develop both rapidly and synchronously.

REFERENCES

1. Copcu E. Marjolin's ulcer: a preventable complication of burns? *Plast Reconstr Surg*. 2009;124(1):156e-164e.
2. Marjolin NJ. *Ulce' re dictionnaire de medecine*. 21. Paris: Bechet; 1828:31-50.
3. Da Costa JC III. Carcinomatous changes in an area of chronic ulceration, or Marjolin's ulcer. *Ann Surg*. 1903;37(4):496-502.
4. Treves N, Pack GT. The development of cancer in burn scars: an analysis and report of thirty-four cases. *Surg Gynecol Obstet*. 1930;51:749-751.
5. Sadegh Fazeli M, Lebaschi AH, Hajirostam M, Keramati MR. Marjolin's ulcer: clinical and pathologic features of 83 cases and review of literature. *Med J Islam Repub Iran*. 2013;27(4):215-224.
6. Bazaliński D, Przybek-Mita J, Barańska B, Więch P. Marjolin's ulcer in chronic wounds - review of available literature. *Contemp Oncol (Pozn)*. 2017;21(3):197-202.
7. Kowal-Vern A, Criswell BK. Burn scar neoplasms: a literature review and statistical analysis. *Burns*. 2005;31(4):403-413.
8. Zuo KJ, Tredget EE. Multiple Marjolin's ulcers arising from irradiated post-burn hypertrophic scars: a case report. *Burns*. 2014;40(4):e21-e25.
9. Chang JB, Kung TA, Cederna PS. Acute Marjolin's ulcers: a nebulous diagnosis. *Ann Plast Surg*. 2014;72(5):515-520.
10. Mohammadi AA, Foroutan A, Mohammadi S, Anbardar MH. An odd very early Marjolin's ulcer after minimal hand burn. *Ann Burns Fire Disasters*. 2017;30(3):218-219.