


## CASE REPORT

# Tailoring NIV by dynamic laryngoscopy in a child with spinal muscular atrophy type I

Maria Vollsæter<sup>1,2,3</sup>  | Anett Skjoldmo<sup>4</sup> | Ola Røksund<sup>1,5,6</sup> | Magnus Hilland<sup>6</sup> | Tiina Andersen<sup>3,4,5</sup>

<sup>1</sup>Department of Pediatrics, Haukeland University Hospital, Bergen, Norway

<sup>2</sup>Department of Clinical Science, University of Bergen, Bergen, Norway

<sup>3</sup>Norwegian Advisory Unit for Home Mechanical Ventilation, Thoracic Department, Haukeland University Hospital, Bergen, Norway

<sup>4</sup>Department of Physiotherapy, Haukeland University Hospital, Bergen, Norway

<sup>5</sup>Faculty of Health and Social Sciences, Western Norway University of Applied Sciences, Bergen, Norway

<sup>6</sup>Department of Head and Neck surgery, ENT, Haukeland University Hospital, Bergen, Norway

## Correspondence

Maria Vollsæter, Department of Pediatrics, Haukeland University Hospital, Bergen No 2021, Norway.

Emails: maria.vollseter@helse-bergen.no, mvollsaeter@gmail.com

## Abstract

Dynamic laryngoscopy during noninvasive (NIV) respiratory therapy is feasible and may facilitate optimal and individualized treatment in patients with chronic respiratory failure, also in children.

## KEYWORDS

ear nose and throat, neurology, pediatrics, respiratory medicine

## 1 | INTRODUCTION

Following Spinraza<sup>®</sup>, children with Spinal Muscular Atrophy (SMA) face a possibility of better health, most particularly those with SMA type I, who previously died early. Effective respiratory aids are crucial to prevent and treat respiratory complications and maintain quality of life. We shed light on a challenge in the respiratory management in children with SMA type I.

## 2 | CASE REPORT

An infant child displayed profound muscular hypotonia and poor head control, progressing from 6 weeks of age. SMA type I was diagnosed at 5 months of age, genetic tests revealed lack of the Survival Motor Neuron (SMN) 1 gene, and

two SMN2 gene copies. CHOP INTEND (The Children's Hospital of Philadelphia Infant Test of Neuromuscular disorders motor function score) was 35/64, the child was cognitive alert, smiled, had weak cough, weak voice, bell-shaped thorax, normal SpO<sub>2</sub>, and transcutaneous CO<sub>2</sub> during sleep at the first visit to the pulmonologist. The child had the first dose of Spinraza 3 days after genetic diagnosis. Immunizations for Respiratory Syncytial virus and Influenza were given. We planned equipment for respiratory support, and parents and health personnel received organized training. At 6 months, following a viral lower respiratory infection during which the child was critically ill, the child started using bilevel positive airway pressure (BIPAP) during sleep and as intermittent high-span treatment, as well as mechanical insufflation-exsufflation (MI-E) device daily, all in the family home.

At 6, 7, and 9 months, the child was admitted acutely for severe illness during viral pneumonias, needing

This is an open access article under the terms of the Creative Commons Attribution-NonCommercial-NoDerivs License, which permits use and distribution in any medium, provided the original work is properly cited, the use is non-commercial and no modifications or adaptations are made.

© 2021 The Authors. *Clinical Case Reports* published by John Wiley & Sons Ltd.

prolonged intensive care with noninvasive ventilation (NIV). The child started using intermittent negative pressure ventilation and intrapulmonary percussive ventilation. *Pseudomonas aeruginosa* grew in tracheal aspirates, treatment commenced accordingly, with intravenous and inhaled antibiotics as well as inhaled hypertonic saline 2.8% daily, due to excessive secretions. This treatment led to successful eradication.

The child breastfed initially, but swallowing difficulties increased and weight gain flattened. The child had a nasogastric tube at 7 months of age, and a percutaneous gastrostomy at 9 months, by when the child tolerated only minimal oral liquids or solids without needing support.

At 11 months, Chop-Intend score was 45/64, respiratory status was unchanged, the child used BIPAP during all sleep and more during airway infections, which were still frequent, and they had to bring the MI-E device and suction aids wherever they traveled outside their home. The parents now reported periodic problems with the MI-E device, as difficulties inflating the child's chest and evacuating secretions.

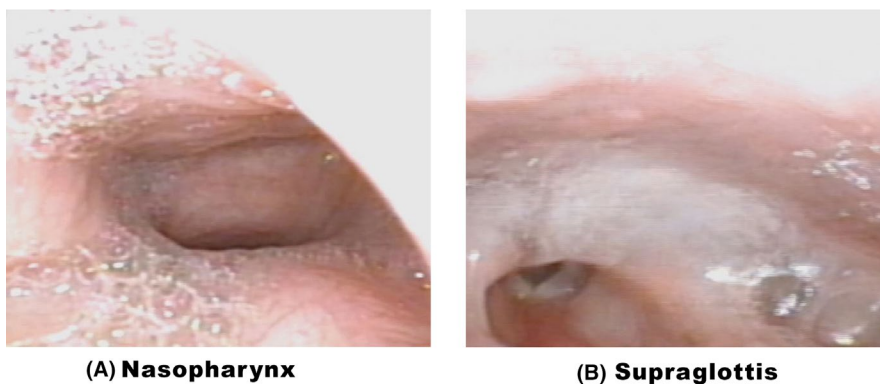
At 12 months of age, we performed dynamic transnasal fiberoptic laryngoscopy (TFL) during ongoing MI-E treatment, after nasal decongestion spray, and with Xylocaine lubricant gel on the laryngoscope.<sup>1</sup> A Toddler Facemask (Respironics Cough Assist Accessories), was customized with an extra opening for the laryngoscope. The child was awake and sitting supported in the mother's lap. A direct laryngeal image revealed increased amounts of secretions in oropharynx and supraglottis, indicating ongoing aspiration (Figure 1). Insufflation pressures of +35 cm H<sub>2</sub>O provoked adduction of supraglottic structures<sup>1</sup> (Figure 2A). By simultaneously reducing the inspiratory flow and the insufflation pressure to +25 cm H<sub>2</sub>O, the child responded with laryngeal abduction (Figure 2B). The child tolerated the procedure well, without objecting or crying. Air-flow patterns registered by the MI-E device were studied afterwards, revealing altered insufflation flow geometry with the initial settings, improving after modifying the flow and pressure as described (Figure 2).

### 3 | DISCUSSION

Spinal muscular atrophy is an autosomal recessive disease caused by a homozygous deletion in the Survival Motor Neuron (SMN) 1 gene on chromosome 5. With loss of SMN protein, progressive loss of spinal lower motor neurons commences in the anterior horn of the spinal cord, causing advanced atrophy of skeletal muscle. SMA clinically subtypes into four, type I being most common and most severe. While appearing normal at birth, symptoms present before 6 months of age, with the child being progressively hypotonic, losing most strength and movement in the limbs, with poor head control, weak swallowing, frequent aspiration and failure to thrive, but normal cognition.<sup>2</sup> Due to marked respiratory muscle weakness, infants rapidly progress to respiratory failure, previously most died prior to 2 years of age.

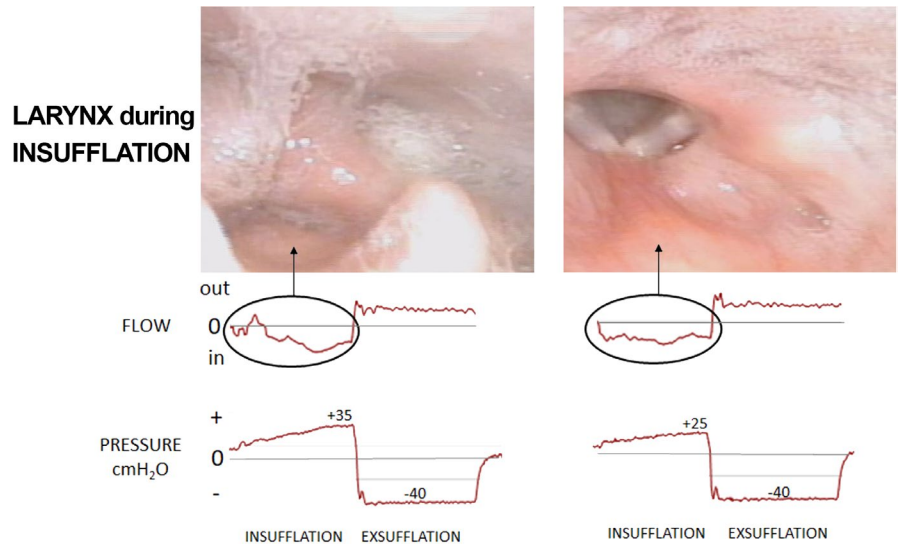
The oligonucleotide Spinraza<sup>®</sup> (Nusinersen) is an intrathecal drug acting as a splicing modifier in the SMN2 protein production, enhancing the production of functioning SMN2 protein. Due to promising results with improvement in motor milestones as well as event-free survival (time to death or use of assisted ventilation), Spinraza was rapidly introduced, following limited trials.<sup>3</sup> This dramatically changed the treatment paradigm for SMA I. Affected children may now survive, some exhibit head control and sit, stand, or walk independently, however, many still have poor motor, feeding, and respiratory function, and dependency on technical respiratory aids.<sup>4</sup> Long-term treatment effects remain unknown.<sup>5</sup> This raises important ethical concerns. The daily treatment in these children needs to be efficient, well-tolerated, and improving life quality.

Our SMA I patient had a clear motor effect of Spinraza, although less effect on respiration and feeding. Dynamic laryngoscopy during ongoing MI-E revealed signs of aspiration, as well as laryngeal closure in response to high inspirational pressures, indicating bulbar affection—in line with clinical observations—and similar to what we previously observed in adult patients with Amyotrophic Lateral Sclerosis (ALS).<sup>1</sup>



**FIGURE 1** Depicts the view through the laryngoscope A, of the nasopharynx and B, of the supraglottis and glottic area

**FIGURE 2** Depicts flow and pressure curves from the mechanical insufflation-exsufflation (MI-E) device with high inspiratory pressures (+35 cm H<sub>2</sub>O) when the larynx closes at inspiration (left), and at lower inspiratory pressures (+25 cm H<sub>2</sub>O) when the larynx stays open during inspiration (right)



The application of TFL during NIV treatment enabled us to adjust MI-E settings directly, by titrating insufflation pressures and flow to the most optimal levels of laryngeal opening, partly alluded to in a previous model.<sup>6</sup> The procedure led to immediate changes in treatment. When setting up technical respiratory aids, individual adaptations are compulsory. If the patient shows evidence of poor tolerance or inability to respond as wished, adjustments should commence accordingly. If problems appear and persist, dynamic TFL could be a valuable and well-tolerated tool, by providing direct views of the oropharynx and larynx, and responses to ongoing treatment. Our patient tolerated the procedure excellent, perhaps because the child was familiar with frequent suctioning of the upper airways through the nose.

## 4 | CONCLUSION

We propose that dynamic laryngoscopy during noninvasive respiratory therapy may facilitate optimal and individualized NIV treatment in patients with chronic respiratory failure, also in pediatric patients. It is a feasible aid that might be used to directly adjust complex respiratory treatment.

## ACKNOWLEDGMENTS

Thanks to the Norwegian Advisory Unit for Home Mechanical Ventilation and Bergen ILO group for providing technical and scientific support, as well as a stimulating research environment. Thanks to Thor Andre Ellingsen for technical support with figures.

## CONFLICTS OF INTEREST

There are no conflicts of interest for any of the authors.

## AUTHOR CONTRIBUTIONS

MV and TA: conceptualized and designed the study by directly examining and coordinating the treatment of the patient, drafted the initial manuscript, and reviewed and revised the manuscript. OR, MH, and AS: involved in the examination and treatment of the patient, and all reviewed and critically revised the manuscript. All authors approved the final manuscript as submitted, and agreed to be accountable for all aspects of the work.

## ETHICAL APPROVAL

This case describes a patient from the everyday clinic in the Department of Pediatrics, and a procedure that was performed in a patient on clinical indication. This was not performed as part of clinical research. Both parents consented to publication.

## DATA AVAILABILITY STATEMENT

All available data are provided in the manuscript.

## ORCID

Maria Vollsaeter  <https://orcid.org/0000-0003-2545-0190>

## REFERENCES

- Andersen T, Sandnes A, Brekka AK, et al. Laryngeal response patterns influence the efficacy of mechanical assisted cough in amyotrophic lateral sclerosis. *Thorax*. 2017;72(3):221-229.
- Kolb SJ, Kissel JT. Spinal muscular atrophy. *Neurol Clin*. 2015;33(4):831-846.
- Finkel RS, Mercuri E, Darras BT, et al. Nusinersen versus sham control in infantile-onset spinal muscular atrophy. *N Engl J Med*. 2017;377(18):1723-1732.
- LoMauro A, Mastella C, Alberti K, Masson R, Aliverti A, Baranello G. Effect of nusinersen on respiratory muscle function in different subtypes of type 1 spinal muscular atrophy. *Am J Respir Crit Care Med*. 2019;200(12):1547-1550.

5. Pane M, Palermo C, Messina S, et al. Nusinersen in type 1 SMA infants, children and young adults: preliminary results on motor function. *Neuromuscul Disord.* 2018;28(7):582-585.
6. Hov B, Andersen T, Toussaint M, Fondenes O, Carlsen KCL, Hovland V. Optimizing expiratory flows during mechanical cough in a pediatric neuromuscular lung model. *Pediatr Pulmonol.* 2020;55(2):433-440.

**How to cite this article:** Vollsæter M, Skjoldmo A, Røksund O, Hilland M, Andersen T. Tailoring NIV by dynamic laryngoscopy in a child with spinal muscular atrophy type I. *Clin Case Rep.* 2021;9:1925–1928. <https://doi.org/10.1002/cer3.3905>