

Bilateral traumatic C6-C7 facet dislocation with C6 spondyloptosis and large disk sequestration in a neurologically intact patient

SAGE Open Medical Case Reports
Volume 8: 1–4
© The Author(s) 2020
Article reuse guidelines:
sagepub.com/journals-permissions
DOI: 10.1177/2050313X20929189
journals.sagepub.com/home/sco



Liad Haimovich, Ofir Uri , Jacob Bickels, Gil Laufer, Gabriel Gutman, Yoram Folman and Eyal Behrbalk

Abstract

Traumatic cervical spondyloptosis is an uncommon and severe form of facet joint dislocation that commonly leads to severe neurological damage. Decision making regarding the reduction and fixation technique is challenging, especially when a patient is neurologically intact, since an undiagnosed prolapsed disk at the involved level may lead to severe neurological consequences during reduction. A 24-year-old male was admitted after sustaining a severe direct axial blow to his head. Computed tomographic and magnetic resonance imaging scans revealed an acute C6C7 fracture dislocation with spondyloptosis of C6 vertebra and a large disk fragment posterior to C6 vertebral body. The patient was neurologically intact, apart from mild bilateral numbness over C6 distribution. The patient underwent C6 corpectomy to avoid acute cord compression related to the large sequestered disk behind C6 vertebra. Following C6 corpectomy, we were unable to exert enough axial pull to reduce the facet dislocation through the anterior approach. Therefore, the reduction was performed through a posterior approach with C5T1 posterior fusion, followed by anterior cage placement and C5-7 anterior fusion (front-back-front approach). At postoperative follow-up of 24 months, the patient demonstrated a full and pain-free cervical range-of-motion and remained neurologically intact. Follow-up radiographs of the cervical spine demonstrated good instrumental alignment with solid fusion at 6-month follow-up.

Keywords

Cervical facet dislocation, traumatic cervical spondylolisthesis, cervical spondyloptosis, cervical spine fusion, treatment of cervical dislocation

Date received: 6 February 2020; accepted: 29 April 2020

Introduction

Bilateral facet joint dislocation of the cervical spine is a severe injury, presenting with neurological deficit in 85%–90% of cases and with complete spinal cord lesion and quadriplegia in 50%–84% of the patients.^{1–3} The injury may be caused by bilateral pedicle fractures, bilateral locked facets, or bilateral lateral mass fractures, with or without fracture of the laminae. In rare cases of bilateral cervical spine facet dislocation, spondyloptosis may occur at the height of injury, increasing the risk for severe neurological deficit.⁴ Narrowing of the spinal canal due to vertebral translation and possibly due to disk herniation contributes to the high prevalence of a neurological damage.^{5,6} Early reduction of the cervical dislocation is the standard of care; however, performing reduction

of cervical spondyloptosis in a neurological intact patient presents a unique challenge, due to the risk of worsening the neurological status during reduction manipulation.^{5–7}

We present an uncommon case of traumatic bilateral C6C7 facet dislocation with C6 spondyloptosis accompanied by a large disk sequestration into the spine canal, in a neurologically intact patient and describe our patient management and decision-making process.

Department of Orthopaedic Surgery, Hillel Yaffe Medical Center, Hadera, Israel

Corresponding Author:

Ofir Uri, Department of Orthopaedic Surgery, Hillel Yaffe Medical Center, Ha-Shalom St, Hadera 38100, Israel.
Email: ofiruri@gmail.com



Case presentation

A 24-year-old male with unremarkable medical history was admitted to our emergency department after sustaining a direct axial blow to his head, caused by jumping head first into a shallow swimming pool and bumping his head against the pool's bottom. Physical examination on admission revealed severe cervical tenderness and limited motion. No apparent bruising or deformity were noticed. Muscular power was preserved in all muscle groups in the upper and lower extremities. Cutaneous sensation in all dermatomes was preserved, apart from mild numbness over C6 distribution of both upper extremities. Normal reflex response was demonstrated in all extremities, with no pathological reflexes.

Hard cervical collar applied and an urgent computed tomographic (CT) scan of the cervical spine was performed in the emergency department demonstrated a C6C7 bilateral facet joint fracture dislocation with high-grade anterior spondylolisthesis/spondyloptosis of C6 vertebra over C7 vertebral body (Figure 1). As the patient remained neurologically intact, we decided to perform an urgent magnetic resonance imaging (MRI) scan of the cervical spine prior to intervention. The MRI findings revealed a large sequestration of C6-7 disk, which migrated cranially behind the body of C6 vertebra with mild compression on the anterior cord (Figure 2). Based on the MRI findings, we decided to avoid traction and close reduction attempt due to the risk of causing acute spinal cord injury related to compression of the sequestered disk fragment on the cord. We planned to

proceed with an anterior decompression by corpectomy of C6 vertebral body and excision of the displaced disk fragment, with subsequent anterior reduction of the dislocation with instrumental fixation by cage and plate. An attempt to excise such a large sequestered disk behind C6 vertebral body without corpectomy seems too risky in our opinion.

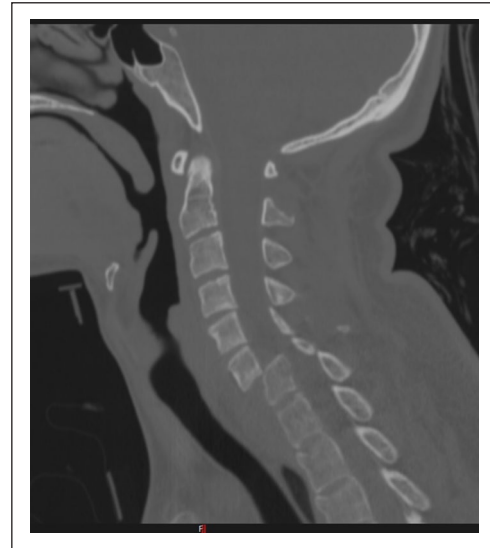


Figure 1. A lateral cervical CT scan taken on admission demonstrating a severe bilateral facet joint dislocation at C6-7 level with anterior spondyloptosis of C6 vertebra over C7 vertebral body.

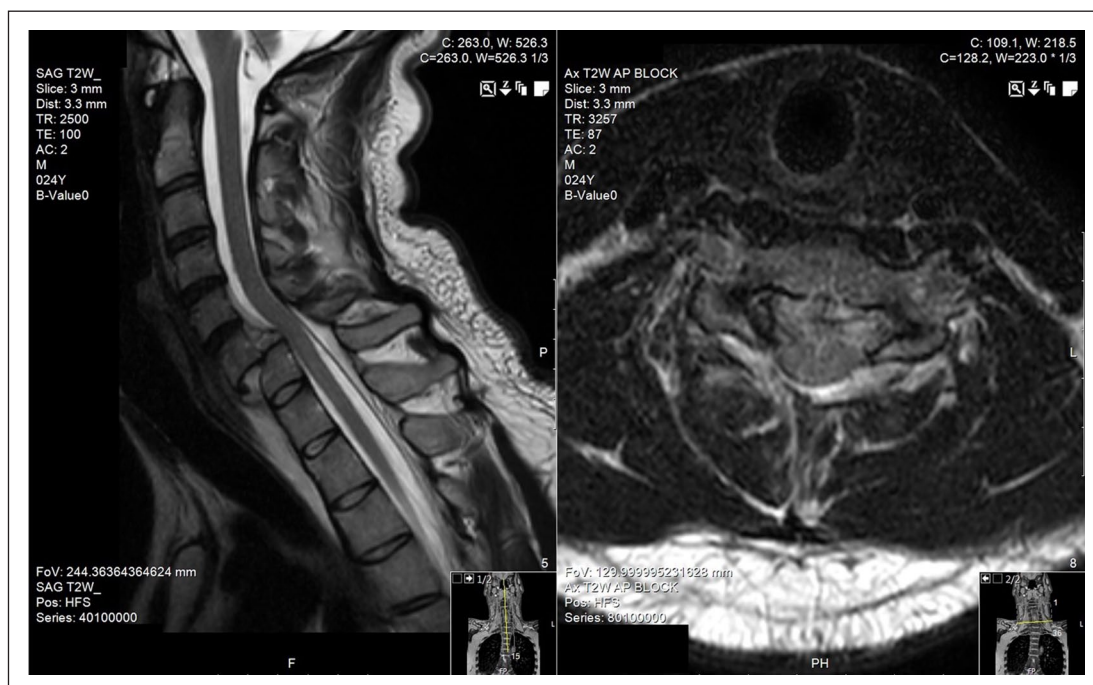


Figure 2. A lateral cervical (left) and transverse (right) T2 MRI scan demonstrating the injury. A large disk fragment can be seen posterior to C6 vertebral body with mild compression on the anterior cord.

The treatment rational, risks and benefits were discussed with the patient and his family, who accepted the potential risks and were ready to proceed with the planned surgery.

The procedure was performed under general anesthesia with neuro-monitoring control and fluoroscopy guidance. The patient was placed in a supine position with the head stabilized in Mayfield frame with traction. An anterior Smith-Robinson approach was performed exposing C5-C7 vertebrae. A corpectomy of C6 vertebra was performed using a dedicated high-speed drill and a surgical microscope. A large disk fragment, compressing the spinal cord, was found behind C6 vertebral body and was excised. The dural sac was found intact with no tears. We made all efforts to reduce the dislocated facets of C6-C7 vertebrae using axial traction on the Caspar pins located in C5 and C7 vertebrae and with the help of end plate spreaders and increasing the Mayfield traction. Unfortunately, following C6 corpectomy we were unable to exert enough axial pull via C5 to reduce the facet dislocation at C6-7 level. Therefore, we were forced to reduce the dislocation through a posterior approach with partial, upper part, resection of the C7 facets to allow an easier C6 facet reduction. The patient was placed in the prone position with Mayfield frame for head fixation. Through a midline incision C4 to T1 laminae and lateral mass were exposed, partial C7 facetectomy was performed and reduction of C6 facets was carried out with the help of Freer dissector in a cantilever maneuver over C7 facets. Posterior fixation was performed with polyaxial 3.5-mm lateral mass screws at C4 to T1 levels and 3.5-mm longitudinal rods (Vertex Max Reconstruction System, Medtronic, USA). The patient was then positioned again in the supine position and a 16-mm cage (T2 Altitude Expandable Corpectomy Device, Medtronic, USA), filled with autologous bone graft and demineralized bone matrix (Grafton DBM, Medtronic, USA), was placed between C5 and C7 vertebral bodies and extended to 19 mm. An anterior plate was fixed to the anterior aspect of C5 and C7 vertebral bodies to provide further stabilization (Venture Anterior Cervical Plate System, Medtronic, USA). The wound was closed by layers. A surgical microscope was used for the anterior approach and magnification loops was used for the posterior approach. The patient's neck was supported with a cervical collar and he was transferred to our intensive care unit for close monitoring.

After initial monitoring in the intensive care unit for 24 hours, the patient was transferred to our spine unit. Neurological examination was normal with intact motor function and improvement of the initial numbness over C6 dermatome. Prophylactic antibiotics were administered for 3 days postoperatively. A follow-up CT angiogram of the cervical spine demonstrated intact vertebral arteries. Unassisted ambulation was permitted at the second postoperative day and the patient was discharged from the hospital 8 days postoperatively with instructions to use the cervical collar for additional 6 weeks. Physiotherapy for controlled neck motions was then started with gradual improvement of neck range of motion. At 3-, 6- and 12-month postoperative

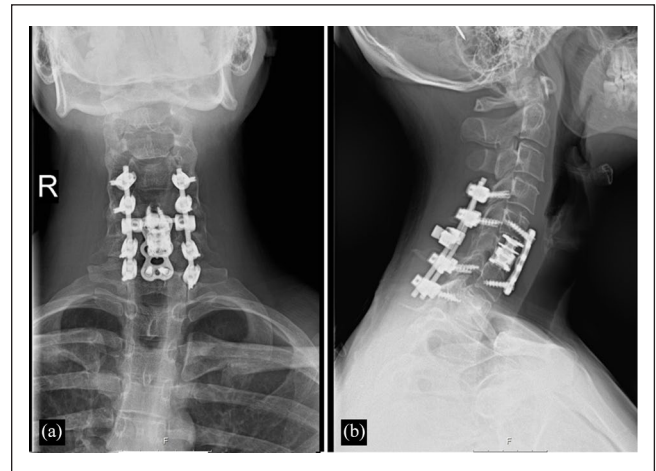


Figure 3. An anterior-posterior (a) and lateral (b) cervical spine radiographs at 12-month follow-up demonstration an anatomical bony and metalwork alignment with solid fusion.

follow-up in our outpatient clinic the patient was doing well, demonstrated a full and pain-free range of motion of his cervical spine and remained neurologically intact. Follow-up cervical spine radiographs demonstrated an anatomical bony and metalwork alignment with solid fusion initially seen at 6-month follow-up (Figure 3).

Discussion

Numerous reports have presented cases of bilateral facet dislocation with significant neurological deficits; however, only a handful of cases of such high-grade slip injuries with no neurological deficits have been reported.¹⁻⁶ We present a case of traumatic bilateral facet dislocation at C6-7 level resulting in C6-7 spondyloptosis, in a neurologically intact patient, with further complication of a large cranially sequestered disk compressing the spinal cord behind C6 vertebral body, which in our opinion necessitated corpectomy of C6 rather than a simple anterior cervical decompression and fusion (ACDF) in order to avoid acute cord compression. Unfortunately, following C6 corpectomy a reduction of the facet dislocation could not be achieved through the anterior approach, forcing us to perform the front-back-front approach which made the surgery much complex and longer.

Loss of bony constraint of the spinal canal due to significant associated fractures and posterior arch injury is assumed to maintain canal patency, explaining the preserved neurological status in the presence of such dreadful injury.^{6,8}

Reviewing previous reports of bilateral facet dislocation with no neurological deficits shows a lack of uniformity in the treatment algorithm of these patients. Baker and Grubb⁹ presented in 1983 a case of such injury at C6-7 level which recovered successfully following non-operative treatment with gradual close reduction by traction for several days and halo brace protection for 6 months. In more recent reports, operative treatment was the treatment of choice; however,

various surgical options have been described, differing in whether preoperative close reduction was attempted and in the preferred surgical approach.^{1–6}

Several authors warned about cervical traction in neurologically intact patients with bilateral facet joint dislocation, due to the risk of causing or exacerbating disk displacement, which may lead to acute spinal cord compression, and highlighted the importance of obtaining MRI imaging prior to any intervention.^{4,10} Ramieri et al.,⁶ on the other hand, reported that gradual cervical halo traction up to 20 lb over a period of 7–10 days is less likely to cause neurological worsening, even in the presence of spondyloptosis and disk herniation. In their experience, preoperative traction, as described, is recommended, as it may realign spondylolisthesis and facilitate subsequent open reduction in cases of spondyloptosis.⁶

Anterior approach alone for cord decompression, deformity reduction and spinal fusion may be the preferred operative approach, when complete reduction can be achieved without further intervention, as described in previous studies.^{6,11} In cases like the one presented here, where corpectomy is performed and results in an inability to reduce the facet dislocation through an anterior approach alone (due to difficulty to transfer axial traction forces to the dislocated facets), a combined anterior-posterior-anterior approach may be required.

In conclusion, the treatment of bilateral facet joint dislocation, especially in neurologically intact patient, is challenging. Obtaining a cervical MRI scan in query of disk herniation, that may endanger the spinal cord during close reduction attempt, should be considered mandatory. Whether preoperative gradual traction for several days should be applied to facilitate surgical reduction, and which surgical approach should be preferred for a certain injury pattern, remain topics of debate. We believe the presented front-back-front approach, although time-consuming and surgically challenging, should be taken into consideration when planning surgical treatment of a high-grade cervical facet dislocation with a large sequestered disk that may lead to acute cord compression during facet reduction.

Declaration of conflicting interests

The author(s) declared no potential conflicts of interest with respect to the research, authorship, and/or publication of this article.

Ethics approval

Our institution does not require ethical approval for reporting individual cases or case series.

Funding

The author(s) received no financial support for the research, authorship, and/or publication of this article.

Informed consent

Written informed consent was obtained from the patient(s) for their anonymized information to be published in this article.

ORCID iD

Ofir Uri  <https://orcid.org/0000-0002-7497-4364>

References

- Chakravarthy V, Mullin JP, Abbott EE, et al. Neurologically intact patient following bilateral facet dislocation: case report and review of literature. *Ochsner J* 2014; 14(1): 108–111.
- Nassr A, Lee JY, Dvorak MF, et al. Variations in surgical treatment of cervical facet dislocations. *Spine (Phila Pa 1976)* 2008; 33(7): E188–E193. DOI: 10.1097/BRS.0b013e3181696118.
- Kim SW, Ciccarelli JM and Fedder IL. Bilateral cervical facet dislocation without neurological injury. *Orthopedics* 2004; 27(12): 1297–1298.
- Tumialan LM, Dadashev V, Laborde DV, et al. Management of traumatic cervical spondyloptosis in a neurologically intact patient: case report. *Spine (Phila Pa 1976)* 2009; 34(19): E703–E708. DOI: 10.1097/BRS.0b013e3181b1fc3a.
- Shah KC and Rajshekhar V. Successful management of post-traumatic C7-T1 spondyloptosis with uninstrumented ventral surgery. *Surg Neurol* 2004; 62(5): 431–434.
- Ramieri A, Domenicucci M, Cellocchio P, et al. Traumatic spondylolisthesis and spondyloptosis of the subaxial cervical spine without neurological deficits: closed re-alignment, surgical options and literature review. *Eur Spine J* 2014; 23(Suppl. 6): 658–663. DOI: 10.1007/s00586-014-3560-z.
- Sribnick EA, Hoh DJ and Dhall SS. Traumatic high-grade cervical dislocation: treatment strategies and outcomes. *World Neurosurg* 2014; 82(6): 1374–1379. DOI: 10.1016/j.wneu.2014.02.008.
- Ivancic PC, Pearson AM, Tominaga Y, et al. Mechanism of cervical spinal cord injury during bilateral facet dislocation. *Spine (Phila Pa 1976)* 2007; 32(22): 2467–2473.
- Baker RP and Grubb RL Jr. Complete fracture-dislocation of cervical spine without permanent neurological sequelae. Case report. *Neurosurg* 1983; 58(5): 760–762.
- Menku A, Kurtsoy A, Tucer B, et al. The surgical management of traumatic C6-C7 spondyloptosis in a patient without neurological deficiencies. *Minim Invasive Neurosurg* 2004; 47(4): 242–244.
- Srivastava SK, Agrawal KM, Sharma AK, et al. C3-C4 spondyloptosis without neurological deficiency—a case report. *Spine J* 2010; 10(7): e16–e20. DOI: 10.1016/j.spinee.2010.05.002.