

## GASTROENTEROLOGY

**Endoscopic features of esophageal adenocarcinoma derived from short-segment versus long-segment Barrett's esophagus**

Akira Yamasaki,<sup>\*,†</sup> Tomoki Shimizu,<sup>‡</sup> Hiroshi Kawachi,<sup>§</sup> Noriko Yamamoto,<sup>§</sup> Shoichi Yoshimizu,<sup>\*</sup> Yusuke Horiuchi,<sup>\*</sup> Akiyoshi Ishiyama,<sup>\*</sup> Toshiyuki Yoshio,<sup>\*</sup> Toshiaki Hirasawa,<sup>\*</sup> Tomohiro Tsuchida,<sup>\*</sup> Yutaka Sasaki<sup>†</sup> and Junko Fujisaki<sup>\*</sup>

Departments of <sup>\*</sup>Gastroenterology, <sup>§</sup>Pathology, Cancer Institute Hospital, Tokyo, <sup>†</sup>Department of Gastroenterology and Hepatology, Graduate School of Medical Sciences, Kumamoto University, Kumamoto and <sup>‡</sup>Department of Gastroenterology, Yokohama Sakae Kyosai Hospital, Yokohama, Japan

**Key words**

Barrett's esophagus, esophageal adenocarcinoma, long-segment Barrett's esophagus, short-segment Barrett's esophagus, superficial Barrett's esophageal adenocarcinoma.

Accepted for publication 4 August 2019.

**Correspondence**

Dr Junko Fujisaki, Department of Gastroenterology, Cancer Institute Hospital, 3-8-31 Ariake, Koto-ku, Tokyo 135-8550, Japan. Email: junko.fujisaki@jfc.or.jp

**Declaration of conflict of interest:** The authors have no financial conflicts of interest to disclose concerning the study.

**Abstract**

**Background and Aim:** The study aims to clarify the endoscopic features and clinicopathological differences in superficial Barrett's esophageal adenocarcinoma (s-BEA) derived from short-segment Barrett's esophagus (SSBE) and long-segment Barrett's esophagus (LSBE).

**Methods:** We reviewed data of 130 patients (141 lesions) with pathologically confirmed s-BEA (SSBE: 95 patients and 95 lesions; LSBE: 35 patients and 46 lesions). We analyzed endoscopic and clinicopathological features of s-BEA in patients with SSBE and LSBE.

**Results:** The distribution of lesions according to macroscopic findings were as follows (s-BEA in SSBE vs LSBE): flat type (0-IIb), 3.2% (3/95) vs 32.6% (15/46) ( $P < 0.001$ ); accompanied type 0-IIb, 2.1% (2/95) vs 21.7% (10/46) ( $P < 0.001$ ); and complex type (0-I + IIb, 0-IIa + IIc, etc.), 30.5% (29/95) vs 50.0% (23/46) ( $P = 0.025$ ). Complex-type s-BEAs had high incidences of T1b invasions and poorly differentiated components (simple type: 22.5% [20/89] and 18.0% [16/89]; complex type: 59.6% [31/52] and 44.2% [23/52],  $P < 0.001$  and  $P = 0.002$ , respectively). In SSBE, 72.6% (69/95) of lesions were located at the right anterior wall ( $P = 0.01$ ). All flat-type or depressed-type lesions derived from SSBE were identified as reddish areas, whereas only 65.2% (15/23) from LSBE were identified as reddish areas ( $P < 0.001$ ).

**Conclusions:** In LSBE, flat-type, accompanied-type 0-IIb, and complex-type lesions were significantly more prevalent. Furthermore, complex-type s-BEAs tended to have T1b invasions and poorly differentiated components. S-BEAs in LSBE should be more carefully evaluated on endoscopic appearance including flat-type and complex-type lesions than in SSBE.

**Introduction**

Barrett's esophagus (BE) is a precursor for esophageal adenocarcinoma, which is rapidly increasing in prevalence and has a highly fatal.<sup>1,2</sup> The incidence of esophageal adenocarcinoma has increased over the past decades in many Western countries.<sup>3–5</sup> Recently, several reports indicated that the incidence of BE and Barrett's esophageal adenocarcinoma (BEA) are rising in Asia because of the decreasing prevalence of *Helicobacter pylori* infection and the westernization of eating habits.<sup>6,7</sup>

The prevalence of BEA differs according to geographic region. In addition, a systematic review and meta-analysis suggested that long-segment Barrett's esophagus (LSBE) is common in Europe and the United States,<sup>8</sup> whereas in Asia, including Japan, short-segment Barrett's esophagus (SSBE) is more common.<sup>9,10</sup> The annual rate of progression to BEA significantly differed between SSBE (0.03–0.07% per year) and LSBE (0.22–0.31% per year).<sup>11–13</sup> Furthermore, because the prevalence of BE differs according to region, diagnosis and therapeutic strategies in Asia are different from Europe and the United States.<sup>14</sup>

In past, there were several reports comparing BEA derived from SSBE and LSBE.<sup>12,15,16</sup> However, there have been no reports that have compared the endoscopic features of superficial Barrett's esophageal adenocarcinoma (s-BEA) between SSBE and LSBE. Here, we conducted an analysis to differentiate both the endoscopic features and clinicopathological differences of s-BEA between SSBE and LSBE.

**Methods**

**Study design.** This was a retrospective study in which we identified the endoscopic features (macroscopic type, localization, and color) according to s-BEA derived from SSBE and LSBE. Additionally, we investigated the relationship between macroscopic type and pathological findings.

**Subjects.** Between April 2005 and December 2017, we studied a total of 130 patients (141 lesions) who were pathologically

confirmed as s-BEA in the Cancer Institute Hospital. The patients were divided into a SSBE group (95 patients and 95 lesions) and a LSBE group (35 patients and 46 lesions), and the endoscopic features (macroscopic type and localization) were compared between the two groups. In addition, the color change of flat-type or depressed-type lesions was compared in terms of white-light imaging (WLI) or narrow-band imaging (NBI) findings, between the two groups (SSBE group [35 lesions] and LSBE group [23 lesions]). These patients underwent endoscopic mucosal resection, endoscopic submucosal dissection (ESD), or surgical operation at our institution. We reviewed all medical records retrospectively. We received written informed consent from all study subjects, and the Ethics Committee of the Cancer Institute Hospital approved the study protocol (Approval number: 2016-1073).

**Definition of Barrett's esophagus.** The esophagogastric junction (EGJ) was defined as the lower margin of the palisading small vessels or the upper end of the gastric folds.<sup>17</sup> Endoscopic diagnosis of the presence of Barrett's epithelium was determined upon the observation of columnar epithelium on the proximal side of the EGJ.<sup>17</sup> The length of the columnar-lined esophagus was determined using the Prague C and M criteria.<sup>18</sup> According to Sharma *et al.*, BE was classified as LSBE when the maximum length of the Barrett's epithelium was  $\geq 3$  cm and as SSBE when the length was  $< 3$  cm.<sup>19–22</sup> In the United States and most European countries, the diagnosis of BE requires histologically confirmed intestinal metaplasia. However, in the UK and Asian countries, including Japan, histological examination is not required according to official guidelines.<sup>17</sup> Therefore, in Japan, BE is commonly diagnosed endoscopically without histological examination. In this study, we adapted the Prague C and M extents as the inclusion criteria.

**Histology of superficial Barrett's esophageal adenocarcinoma.** BEA was defined as adenocarcinoma that was endoscopically confirmed in the Barrett's epithelium, or adenocarcinoma observed upon pathological examination of the resected specimen showing squamous islands, esophageal glands, or double layers of muscularis mucosa within the lesion or on the anal side.<sup>17</sup> The depth of tumor invasion was categorized into T1a if the tumor limited to the lamina propria mucosa or invaded into, but not through, the deep muscularis mucosa (DMM), or into T1b if there was the submucosa (SM) invasion. Histological type was classified into a well-moderately differentiated type, a poorly differentiated type, or mixed of both types.<sup>17</sup> According to the World Health Organization classification, we defined that poorly cohesive carcinomas are composed of neoplastic cells that are isolated or arranged in small aggregates. All lesions were diagnosed by expert two pathologists (H. K. and N. Y.).

**Endoscopic diagnosis.** We performed high-resolution WLI endoscopy (GIF-H260 or GIF-H290Z; Olympus, Tokyo, Japan). In addition, NBI without magnified endoscopy and chromoendoscopy using indigo carmine were performed. The macroscopic classification was determined in accordance with the Japanese Classification of Esophageal Cancer.<sup>17</sup> The macroscopic type was retrospectively evaluated by three endoscopists

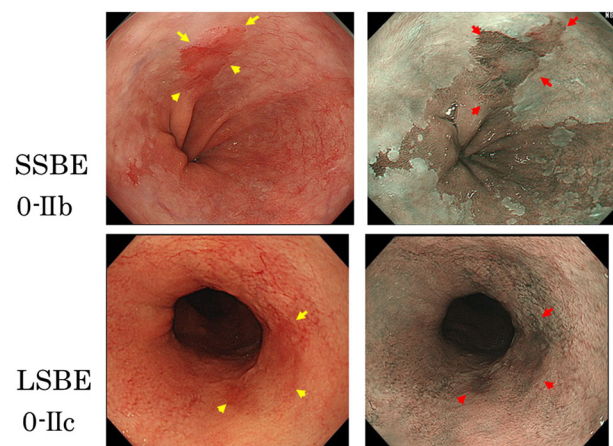
who were certified by the Japan Gastroenterological Endoscopy Society. The final macroscopic type was determined based on the consensus of three endoscopists according to the Japanese Classification of Esophageal Cancer (A. Y., T. S., and J. F.).

We placed each primary macroscopic type into one of two groups (elevated type and flat or depressed type) based on the classification of the primary macroscopic type, for example, elevated types included type 0-I + IIc or 0-IIa + IIc + IIb, whereas flat or depressed types included type 0-IIb or 0-IIc + IIa. The typical cases of flat or depressed types are shown in Figure 1. On WLI endoscopy, there were reddish flat-type or depressed-type lesions, and when NBI were utilized, we observed brownish areas.

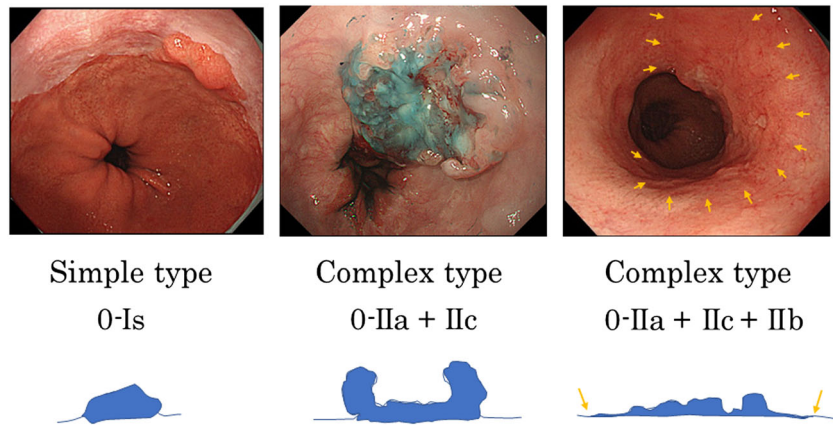
Furthermore, we classified macroscopic type into simple macroscopic type or complex macroscopic type. For example, simple macroscopic types included type 0-I (0-Is and 0-Ip), 0-IIa, 0-IIb, and 0-IIc, whereas complex macroscopic types included type 0-I + IIa or 0-IIa + IIc + IIb (Fig. 2). We classified lesions that included 0-IIb components among the complex macroscopic type as the accompanied type 0-IIb. For example, the accompanied type 0-IIb included type 0-I + IIb or 0-IIa + IIc + IIb. The diagnosis of flat-type lesions included the accompanied type 0-IIb, which was evaluated by referencing the histological mapping of resected specimens, in addition to the endoscopic findings.

Furthermore, the elevated type is easily to find due to its shape, so we evaluated the color change on flat and depressed types.

**Statistical analysis.** Fisher's exact probability test was performed to compare the two groups. The mean values and standard deviations for age and body mass index, and the median and range for tumor diameter were analyzed using *t*-tests and *F*-tests. When equal variances were not assumed, Mann-Whitney *U*-tests were performed. When the odds ratio (OR) and 95% confidence interval (CI) of the tumor diameter were calculated, a cut-off value was set with regard to the median tumor diameter. A *P*-value  $< 0.05$  was considered a statistically significant difference. SPSS version 22.0 (SPSS Inc., Chicago, IL, USA) was used for all statistical analyses.



**Figure 1** Typical cases of flat or depressed type. On white-light imaging (WLI) endoscopy, there were reddish flat-type or depressed-type lesions (yellow arrow). When narrow-band imaging (NBI) were utilized, we observed brownish areas (red arrow). [Color figure can be viewed at [wileyonlinelibrary.com](http://wileyonlinelibrary.com)]



**Figure 2** Examples of different lesion types: simple macroscopic types include 0-I (0-I<sub>s</sub>, 0-I<sub>p</sub>), 0-II<sub>a</sub>, 0-II<sub>b</sub>, and 0-II<sub>c</sub>; complex macroscopic types include 0-II<sub>a</sub> + II<sub>c</sub> or 0-II<sub>a</sub> + II<sub>c</sub> + II<sub>b</sub>. We showed the accompanied type 0-II<sub>b</sub> (orange arrow) and the diagrams of different lesion types. [Color figure can be viewed at [wileyonlinelibrary.com](http://wileyonlinelibrary.com)]

## Results

**Baseline characteristics.** A total of 130 patients (141 lesions) were enrolled in this study. Baseline characteristics of the study patients are shown in Table 1. There was a higher prevalence of BEA in males. Multiple lesions presented in five patients, who were LSBE cases ( $P = 0.001$ ). The median tumor diameter was significantly larger in LSBE cases (OR, 2.53; 95% CI, 1.13–5.64;  $P = 0.001$ ). The ratio of lesions involving more

than one half of the lumen was significantly larger in cases of LSBE (OR, 11.3; 95% CI, 2.33–54.8;  $P < 0.001$ ). The percentage of type 0-II<sub>b</sub> lesions in the study population was only 3.2% (3/95) for SSBE, whereas it was 32.6% (15/46) for LSBE (OR, 14.8; 95% CI, 4.02–54.7;  $P < 0.001$ ). Surgery was the most common treatment for LSBE (OR, 3.75; 95% CI, 1.68–8.40;  $P = 0.001$ ). There was no significant difference in the ratio of T1b invasion and poorly differentiated components between the SSBE and LSBE groups.

**Table 1** Baseline characteristics

	SSBE	LSBE	<i>P</i> -value
Patient characteristics	<i>n</i> = 95	<i>n</i> = 35	
Age, years, mean ± SD <sup>†</sup>	63.9 ± 11.7	62.1 ± 9.7	0.43
Sex, male	82 (86.3)	33 (94.3)	0.35
BMI, kg/m <sup>2</sup> , mean ± SD <sup>†</sup>	22.8 ± 3.2	23.0 ± 3.4	0.77
Multiple lesions	0 (0)	5 (14.3)	0.001
Lesion characteristics	<i>n</i> = 95	<i>n</i> = 46	
Tumor diameter (mm) <sup>‡</sup>	15 (10–20) [3–38]	20 (11–30) [1–82]	0.001
More than one half of the lumen	2 (2.1)	9 (19.6)	< 0.001
Primary macroscopic type			
0-I (0-I <sub>s</sub> and 0-I <sub>p</sub> )	15 (15.8)	7 (15.2)	1.00
0-II <sub>a</sub>	45 (47.4)	16 (34.8)	0.21
0-II <sub>b</sub>	3 (3.2)	15 (32.6)	< 0.001
0-II <sub>c</sub>	32 (33.7)	8 (17.4)	0.05
Color			
Reddish	91 (95.8)	38 (82.6)	0.02
Treatment			
EMR/ESD	2/78 (84.2)	5/22 (58.7)	0.001
Surgery	15 (15.8)	19 (41.3)	
Depth of tumor invasion			
T1a	59 (62.1)	31 (67.4)	0.58
T1b	36 (37.9)	15 (32.6)	
Histological type			
Well-moderately differentiated type	69 (72.6)	33 (71.7)	1.00
Mixed type (poorly differentiated component)	26 (27.4)	13 (28.3)	
Poorly differentiated type	0 (0)	0 (0)	

Data are presented as numbers (%).

<sup>†</sup>Age and BMI are expressed as mean ± SD (standard deviation).

<sup>‡</sup>Tumor diameter is expressed as median (interquartile range) [range].

BMI, body mass index; EMR, endoscopic mucosal resection; ESD, endoscopic submucosal dissection; LSBE, long-segment Barrett's esophagus; SD, standard deviation; SSBE, short-segment Barrett's esophagus.

**Macroscopic type.** The distribution of all macroscopic types and T1b invasion rates are shown in Table 2. When we placed each primary macroscopic type into one of two groups (elevated type and flat or depressed type), we found that elevated types accounted for 63.2% (60/95) of SSBE lesions, whereas among LSBE patients, 50.0% (23/46) of the lesions were flat or depressed type. The most common macroscopic type of T1b invasion was type 0-IIa + IIc.

The prevalence of simple and complex macroscopic types is shown in Table 3. In the SSBE group, simple macroscopic types accounted for 69.5% (66/95), whereas the complex macroscopic type accounted for 50.0% (23/46) in the LSBE group (OR, 2.28; 95% CI, 1.10–4.67;  $P = 0.025$ ). The complex macroscopic type

was more prevalent in the LSBE group than in the SSBE group (e.g. type 0-IIa + IIb or 0-IIa + IIc + IIb). Among the complex macroscopic-type lesions with accompanied type 0-IIb, 2.1% (2/95) and 21.7% (10/46) were SSBE and LSBE, respectively (OR, 12.9; 95% CI, 2.70–61.8;  $P < 0.001$ ).

**Relationship between macroscopic type and pathological findings.**

The relationship between macroscopic type and the pathological findings are shown in Table 4. T1b invasion rates were 22.5% (20/89) and 59.6% (31/52) in the simple macroscopic and complex macroscopic types, respectively. Moreover, there was a significant difference, in terms of T1b invasion, between the complex macroscopic types and simple macroscopic types (OR, 5.09; 95% CI, 2.42–10.7;  $P < 0.001$ ). As for the poorly differentiated component rates, they followed a similar trend as the T1b invasion rates, with a significant difference between the simple and complex macroscopic lesion types (simple type: 18.0% [16/89]; complex type: 44.2% [23/52]; OR, 3.62; 95% CI, 1.68–7.81;  $P = 0.002$ ). Most s-BEAs with poorly differentiated components showed SM invasion, with some showing DMM invasion (DMM: 17.9% [7/39]; SM: 79.5% [31/39]). In addition, poorly differentiated adenocarcinomas were frequently seen in part such as type 0-IIa or 0-IIc included accompanied type 0-IIc.

**Localization.** The details of localization in the study patients are shown in Table S1. We found that the lesions located at the right anterior wall (0–3 o'clock position) in the lower esophagus accounted for 72.6% (69/95) of SSBE lesions, whereas, 47.8% (22/46) of LSBE lesions were located in regions other than the right anterior wall (OR, 0.38; 95% CI, 0.18–0.78;  $P = 0.01$ ). We evaluated whether the lesions were adjoined at the upper end of the BE. In SSBE lesions, 96.8% (92/95) of lesions were located at the upper end of the BE, indicating that most lesions were located at the lower end of the squamous epithelium. In contrast, the lesions in the LSBE group located at the upper end of BE only accounted for 65.2% (30/46) of lesions (OR, 0.06; 95% CI, 0.02–0.22;  $P < 0.001$ ).

**Color change of flat-type or depressed-type superficial Barret's esophageal adenocarcinoma.**

The color changes in flat-type or depressed-type lesions are shown in Table S2. In cases of SSBE, all lesions were identified by both a reddish area and a brownish area when NBI was employed. For LSBE lesions, only 65.2% (15/23) of lesions were identified by a reddish area (OR, 1.53; 95% CI, 1.14–2.07;  $P < 0.001$ ), while 73.9% (17/23) were observed as a brownish area (OR, 1.35; 95% CI, 1.06–1.73;  $P = 0.002$ ). A representative case of LSBE is shown in Figure 3. On WLI endoscopy, we could not recognize the lesions clearly. When we used NBI, on the anterior side, the lesions were detected as brownish areas. For this case, NBI was found to be particularly useful.

**Discussion**

This study is the first report on the endoscopic differences, such as macroscopic type, of s-BEA between SSBE and LSBE. Matsui et al.<sup>23</sup> reported conventional white light endoscopic features of s-BEA in SSBE (30 patients and 30 lesions), although there were

**Table 2** Details of macroscopic types and T1b invasion rates

	SSBE (n = 95)	T1b (n = 36)	LSBE (n = 46)	T1b (n = 15)
Elevated type	n = 60	n = 24	n = 23	n = 11
0-I <sup>†</sup>	11 (11.6)	2 (5.6)	2 (4.3)	2 (13.3)
0-I + IIa	—	—	1 (2.2)	—
0-I + IIa + IIb	—	—	1 (2.2)	1 (6.7)
0-I + IIb	2 (2.1)	1 (2.8)	1 (2.2)	1 (6.7)
0-I + IIc	2 (2.1)	2 (5.6)	1 (2.2)	1 (6.7)
0-I + IIc + IIb	—	—	1 (2.2)	1 (6.7)
0-IIa <sup>‡</sup>	24 (25.3)	6 (16.7)	1 (2.2)	—
0-IIa + I	1 (1.1)	—	—	—
0-IIa + IIb	—	—	3 (6.5)	—
0-IIa + IIc <sup>‡</sup>	20 (21.1)	<b>13 (36.1)</b>	10 (21.7)	<b>4 (26.7)</b>
0-IIa + IIc + IIb	—	—	2 (4.3)	1 (6.7)
Flat or depressed type	n = 35	n = 12	n = 23	n = 4
0-IIb <sup>†</sup>	3 (3.2)	—	15 (32.6)	2 (13.3)
0-IIc <sup>†</sup>	28 (29.5)	8 (22.2)	5 (10.9)	—
0-IIc + I	1 (1.1)	1 (2.8)	—	—
0-IIc + IIa	3 (3.2)	3 (8.3)	1 (2.2)	1 (6.7)
0-IIc + IIb	—	—	1 (2.2)	1 (6.7)
0-IIc + III + IIb	—	—	1 (2.2)	—

Complex types are presented as primary + accompanied macroscopic type. Data are presented as numbers (%).

<sup>†</sup>Simple type. Other macroscopic types are complex type.

<sup>‡</sup>The most common macroscopic type of T1b invasion is shown in bold. LSBE, long-segment Barrett's esophagus; SSBE, short-segment Barrett's esophagus.

**Table 3** Distribution of simple and complex macroscopic types

	SSBE (n = 95)	LSBE (n = 46)	P-value
Simple type <sup>†</sup>	66 (69.5)	23 (50.0)	0.025
Complex type <sup>‡</sup>	29 (30.5)	23 (50.0)	
Accompanied type 0-IIb	2 (2.1)	10 (21.7)	< 0.001

Data are presented as numbers (%).

<sup>†</sup>Simple type: 0-I, 0-IIa, 0-IIb, and 0-IIc.

<sup>‡</sup>Complex type: 0-I + IIa, 0-IIa + IIc + IIb, and so on.

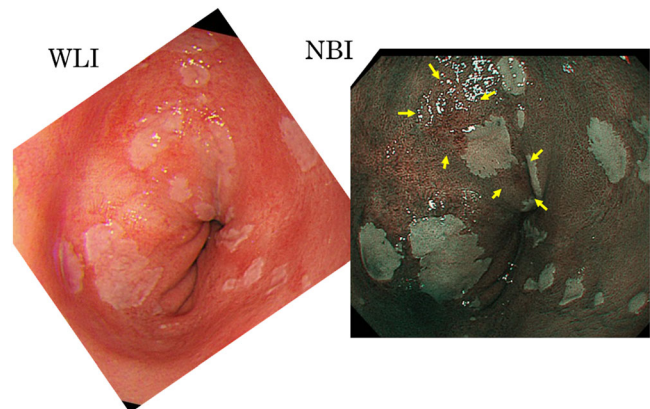
LSBE, long-segment Barrett's esophagus; SSBE, short-segment Barrett's esophagus.

**Table 4** Relationship between macroscopic type and pathological findings

	SSBE ( <i>n</i> = 95)	LSBE ( <i>n</i> = 46)	SSBE + LSBE ( <i>n</i> = 141)	<i>P</i> -value
T1b invasion				
Simple type	16/66 (24.2)	4/23 (17.4)	20/89 (22.5)	} <0.001
Complex type	20/29 (69.0)	11/23 (47.8)	31/52 (59.6)	
	} <i>P</i> = 0.58			
Poorly differentiated component				
Simple type	14/66 (21.2)	2/23 (8.7)	16/89 (18.0)	} 0.002
Complex type	12/29 (41.4)	11/23 (47.8)	23/52 (44.2)	
	} <i>P</i> = 1.00			

Data are presented as numbers (%).

LSBE, long-segment Barrett's esophagus; SSBE, short-segment Barrett's esophagus.



**Figure 3** A representative case of LSBE. On white-light imaging (WLI) endoscopy, we could not recognize the lesions clearly. When narrow-band imaging (NBI) was utilized, we observed brownish areas on the anterior side (yellow arrow). In this case, NBI was very useful. [Color figure can be viewed at [wileyonlinelibrary.com](http://wileyonlinelibrary.com)]

few comparisons with LSBE. Moreover, the prevalence of multiple neoplasia was significantly correlated with tumor size and length of BE.<sup>15</sup> However, to our knowledge, there have been no reports that have compared the endoscopic features of s-BEA between SSBE and LSBE.

The current study described differences in macroscopic types, between SSBE and LSBE groups; flat-type lesions, including the accompanied type 0-IIb, were significantly more prevalent in LSBE cases, making it difficult to detect s-BEA in LSBE, as compared to SSBE. Therefore, it is important to detect flat-type lesions associated BEA in the LSBE group. Type 0-IIb and the accompanied type 0-IIb were very important macroscopic types, because they related to detection and diagnosis for a range of lesions.

As previously noted, therapeutic strategies are different in Asia than in Europe and the United States. In Japan, complete tumor

resection by ESD is preferred, whereas in Europe and the United States, endoscopic mucosal resection for visible lesions combined with radio-frequency ablation for residual metaplasia epithelium is recommended for BEA.<sup>24,25</sup> Furthermore, in Europe and the United States, random biopsy based on the Seattle protocol remains the gold standard to identify dysplasia or adenocarcinoma before treatment.<sup>26</sup> Conversely, Japanese endoscopists usually conduct an endoscopically targeted biopsy for a lesion suspected of adenocarcinoma. As LSBE is common in Europe and the United States, high-grade dysplasia and flat-type lesions are commonly detected. Therefore, it seems reasonable that random biopsy and radio-frequency ablation are conducted in Europe and the United States. However, as we are careful about flat-type lesions in diagnosing patients with LSBE, we believe that ESD might be an appropriate standard treatment. Therefore, we believe that

ESD is a potential effective therapeutic option for esophageal neoplasms in patients with LSBE, as well as SSBE.<sup>27</sup> A total of 86 patients who underwent ESD in the previous study were included in this study (SSBE: 68 of 78 cases; LSBE: 18 of 22 cases).<sup>27</sup> Based on our data, multiple lesions and the ratio of lesions involving more than one half of the lumen were significantly higher in LSBE cases (Table 1). Therefore, when diagnosing or treating s-BEA in LSBE, caution should be paid to lesions, including the accompanied type 0-IIb or multiple lesions.

The incidence of complex macroscopic-type lesions was higher in LSBE than SSBE (Table 3). SSBE lesions are easier to detect than LSBE, and the rate of simple macroscopic types was higher. Therefore, we considered endoscopic treatments to be more common in SSBE cases. There was no significant difference in the ratio of T1b invasion and poorly differentiated components between the SSBE and LSBE groups (Tables 1 and 4). However, in the entire s-BEA, complex macroscopic-type lesions had a high incidence of T1b invasion and poorly differentiated components (Table 4). The most common macroscopic type of T1b invasion was type 0-IIa + IIc (Table 2). Therefore, special attention should be paid to T1b invasion and poorly differentiated components when diagnosing s-BEA of complex macroscopic types.

The localization of the lesions is an important factor in s-BEA detection. s-BEA is frequently found in the right or anterior wall of the EGJ.<sup>28–30</sup> As previously reported, our study revealed that s-BEA in SSBE were typically located at the right anterior wall of the EGJ, whereas s-BEAs in LSBE were located at both the posterior wall to the left wall, as well as the right anterior wall (Table S1). We reported that the location of s-BEA mostly corresponds to the direction of gastroesophageal reflux,<sup>31</sup> by using a pH catheter with eight sensors developed at the Shimane Medical University and Star Medical (8-channel pH catheter SA800, Tokyo, Japan).<sup>32</sup> In many cases, acid reflux was located at the right anterior wall, which corresponded with the location of cancer. If s-BEAs were detected in a location other than the right anterior wall side, it can be speculated that there might be acid reflux in the direction of the lesion's position. Therefore, by knowing the location of acid reflux using pH monitoring, we may easily detect s-BEA in LSBE at an early stage. In particular, given that the localization of LSBE lesions is not necessarily at the right anterior wall, knowing the direction of acid reflux would aid in detecting s-BEA.

For flat-type or depressed-type lesions, color change is also an important factor in s-BEA detection. In SSBE cases, all lesions were identified as both a reddish and brownish area. Although in LSBE cases, we could identify only 65.2% of lesions by reddish areas on WLI endoscopy, and we could observe 73.9% of these lesions as brownish areas using NBI (Table S2). Our findings suggest that in cases of LSBE, some lesions could not be recognized as reddish areas. It would therefore be useful to observe such BEA lesions with weakly magnifying endoscopy using NBI. However, even if NBI could be employed, there are still a significant number of cases in which we cannot detect s-BEA in LSBE lesions. Flat-type lesions included the accompanied type 0-IIb could not be detected, which were evaluated by referencing the histological mapping of resected specimens.

Among the BE patients followed up at our institute during the study period, an estimated 1000 patients had SSBE and 36 had LSBE. During the follow-up period, progression to BEA was seen

in the following cases: SSBE, one to two cases per year, and LSBE, one case.

In this study, if the palisading small vessels were unclear, the upper end of the gastric folds were defined as the EGJ.<sup>17</sup> The position of the upper end of the gastric folds may not be well visualized in the context of atrophic gastritis, which is frequently encountered in Japan.<sup>33,34</sup> There were only a few cases with no definitive histological criteria, and these cases were found endoscopically in the palisading small vessels. According to the World Health Organization classification, the diagnosis of BE is restricted to columnar epithelium with goblet cells in North America and parts of Europe.<sup>35,36</sup> However, some authorities accept columnar epithelium without goblet cells as a part of the definition.<sup>37–40</sup>

This study was subject to some limitations. First, we used a retrospective study design. Second, the study was performed at a single center. Prospective studies at multiple centers would be warranted to verify our results.

In conclusion, in SSBE, s-BEAs were often recognized as an elevated reddish appearance located at the right anterior wall of the EGJ. In LSBE, flat-type lesions, including the accompanied type 0-IIb, and multiple lesions, the ratio of lesions involving more than one half of the lumen, and complex macroscopic types were significantly more prevalent. When we diagnose and treat s-BEA, it is necessary to consider the differences between s-BEA derived from SSBE and that from LSBE, such as macroscopic types.

## Acknowledgment

We would like to thank Editage ([www.editage.jp](http://www.editage.jp)) for English language editing.

## References

- 1 Thrift AP, Whiteman DC. The incidence of esophageal adenocarcinoma continues to rise: analysis of period and birth cohort effects on recent trends. *Ann. Oncol.* 2012; **23**: 3155–62.
- 2 Thrift AP, El-Serag HB. Sex and racial disparity in incidence of esophageal adenocarcinoma: observations and explanations. *Clin. Gastroenterol. Hepatol.* 2016; **14**: 330–2.
- 3 Hur C, Miller M, Kong CY *et al.* Trends in esophageal adenocarcinoma incidence and mortality. *Cancer* 2013; **119**: 1149–58.
- 4 Caygill CP, Royston C, Charlett A *et al.* Mortality in Barrett's esophagus: three decades of experience at a single center. *Endoscopy* 2012; **44**: 892–8.
- 5 Shaheen NJ, Richter JE. Barrett's oesophagus. *Lancet* 2009; **373**: 850–61.
- 6 Wu JC. Gastroesophageal reflux disease: an Asian perspective. *J. Gastroenterol. Hepatol.* 2008; **23**: 1785–93.
- 7 Hongo M, Nagasaki Y, Shoji T. Epidemiology of esophageal cancer: orient to occident. Effects of chronology, geography and ethnicity. *J. Gastroenterol. Hepatol.* 2009; **24**: 729–35.
- 8 Sikkema M, de Jonge PJ, Steyerberg EW, Kuipers EJ. Risk of esophageal adenocarcinoma and mortality in patients with Barrett's esophagus: a systematic review and meta-analysis. *Clin. Gastroenterol. Hepatol.: The Official Clinical Pract. J. Am. Gastroenterol. Assoc.* 2010; **8**: 235–44 quiz e32.
- 9 Azuma N, Endo T, Arimura Y *et al.* Prevalence of Barrett's esophagus and expression of mucin antigens detected by a panel of monoclonal antibodies in Barrett's esophagus and esophageal adenocarcinoma in Japan. *J. Gastroenterol.* 2000; **35**: 583–92.

- 10 Amano Y, Kushiyama Y, Yuki T *et al.* Prevalence of and risk factors for Barrett's esophagus with intestinal predominant mucin phenotype. *Scand. J. Gastroenterol.* 2006; **41**: 873–9.
- 11 Hamade N, Vennelaganti S, Parasa S *et al.* Lower annual rate of progression of short-segment vs long-segment Barrett's esophagus to esophageal adenocarcinoma. *Clin. Gastroenterol. Hepatol.* 2018; **17**: 864–8.
- 12 Pohl H, Pech O, Arash H *et al.* Length of Barrett's oesophagus and cancer risk: implications from a large sample of patients with early oesophageal adenocarcinoma. *Gut* 2016; **65**: 196–201.
- 13 Chandrasekar VT, Hamade N, Desai M *et al.* Significantly lower annual rates of neoplastic progression in short- compared to long-segment non-dysplastic Barrett's esophagus: a systematic review and meta-analysis. *Endoscopy* 2019; **51**: 665–72.
- 14 Goda K, Singh R, Oda I *et al.* Current status of endoscopic diagnosis and treatment of superficial Barrett's adenocarcinoma in Asia-Pacific region. *Dig. Endosc.* 2013; **25**: 146–50.
- 15 Altorki NK, Lee PC, Liss Y *et al.* Multifocal neoplasia and nodal metastases in T1 esophageal carcinoma: implications for endoscopic treatment. *Ann. Surg.* 2008; **247**: 434–9.
- 16 Tan MC, Murrey-Ittmann J, Nguyen T, Ketwaroo GA, El-Serag HB, Thrift AP. Risk profiles for Barrett's esophagus differ between new and prevalent, and long- and short-segment cases. *PLoS ONE* 2016; **11**: e0169250.
- 17 Japan Esophageal S. Japanese classification of esophageal cancer, 11th edition: part I. *Esophagus* 2017; **14**: 1–36.
- 18 Sharma P, Dent J, Armstrong D *et al.* The development and validation of an endoscopic grading system for Barrett's esophagus: the Prague C & M criteria. *Gastroenterology* 2006; **131**: 1392–9.
- 19 Sharma P, Morales TG, Sampliner RE. Short segment Barrett's esophagus—the need for standardization of the definition and of endoscopic criteria. *Am. J. Gastroenterol.* 1998; **93**: 1033–6.
- 20 Shaheen NJ, Falk GW, Iyer PG, Gerson LB. American College of G. ACG clinical guideline: diagnosis and management of Barrett's esophagus. *Am. J. Gastroenterol.* 2016; **111**: 30–50 quiz 1.
- 21 Fitzgerald RC, di Pietro M, Raganath K *et al.* British Society of Gastroenterology guidelines on the diagnosis and management of Barrett's oesophagus. *Gut* 2014; **63**: 7–42.
- 22 Matsuhashi N, Sakai E, Ohata K *et al.* Surveillance of patients with long-segment Barrett's esophagus: a multicenter prospective cohort study in Japan. *J. Gastroenterol. Hepatol.* 2017; **32**: 409–14.
- 23 Matsui A, Kuribayashi Y, Nomura K *et al.* Conventional white light endoscopic features of small superficial Barrett's esophageal adenocarcinoma. *Digestion* 2016; **93**: 47–52.
- 24 Pimentel-Nunes P, Dinis-Ribeiro M, Ponchon T *et al.* Endoscopic submucosal dissection: European society of gastrointestinal endoscopy (ESGE) guideline. *Endoscopy* 2015; **47**: 829–54.
- 25 Phoa KN, Pouw RE, Bisschops R *et al.* Multimodality endoscopic eradication for neoplastic Barrett oesophagus: results of an European multicentre study (EURO-II). *Gut* 2016; **65**: 555–62.
- 26 American Gastroenterological A, Spechler SJ, Sharma P, Souza RF, Inadomi JM, Shaheen NJ. American Gastroenterological Association medical position statement on the management of Barrett's esophagus. *Gastroenterology* 2011; **140**: 1084–91.
- 27 Shimizu T, Fujisaki J, Omae M *et al.* Treatment outcomes of endoscopic submucosal dissection for adenocarcinoma originating from long-segment Barrett's esophagus versus short-segment Barrett's esophagus. *Digestion* 2018; **97**: 316–23.
- 28 Pech O, Gossner L, Manner H *et al.* Prospective evaluation of the macroscopic types and location of early Barrett's neoplasia in 380 lesions. *Endoscopy* 2007; **39**: 588–93.
- 29 Enestvedt BK, Lugo R, Guarner-Argente C *et al.* Location, location, location: does early cancer in Barrett's esophagus have a preference? *Gastrointest. Endosc.* 2013; **78**: 462–7.
- 30 Cassani L, Sumner E, Slaughter JC, Yachimski P. Directional distribution of neoplasia in Barrett's esophagus is not influenced by distance from the gastroesophageal junction. *Gastrointest. Endosc.* 2013; **77**: 877–82.
- 31 Omae M, Fujisaki J, Shimizu T *et al.* Correlation of the location of superficial Barrett's esophageal adenocarcinoma (s-BEA) with the direction of gastroesophageal reflux. *Endosc. Int. Open.* 2016; **4**: E515–20.
- 32 Kinoshita Y, Furuta K, Adachi K, Amano Y. Asymmetrical circumferential distribution of esophagogastric junctional lesions: anatomical and physiological considerations. *J. Gastroenterol.* 2009; **44**: 812–8.
- 33 Kusano C, Kaltenbach T, Shimazu T, Soetikno R, Gotoda T. Can Western endoscopists identify the end of the lower esophageal palisade vessels as a landmark of esophagogastric junction? *J. Gastroenterol.* 2009; **44**: 842–6.
- 34 Amano Y, Ishimura N, Furuta K *et al.* Which landmark results in a more consistent diagnosis of Barrett's esophagus, the gastric folds or the palisade vessels? *Gastrointest. Endosc.* 2006; **64**: 206–11.
- 35 Odze RD. Barrett esophagus: histology and pathology for the clinician. *Nat. Rev. Gastroenterol. Hepatol.* 2009; **6**: 478–90.
- 36 Wang KK, Sampliner RE. Practice parameters committee of the American College of G. Updated guidelines 2008 for the diagnosis, surveillance and therapy of Barrett's esophagus. *Am. J. Gastroenterol.* 2008; **103**: 788–97.
- 37 Chandrasoma P. Controversies of the cardiac mucosa and Barrett's oesophagus. *Histopathology* 2005; **46**: 361–73.
- 38 Riddell RH, Odze RD. Definition of Barrett's esophagus: time for a rethink—is intestinal metaplasia dead? *Am. J. Gastroenterol.* 2009; **104**: 2588–94.
- 39 Remstein ED, Dogan A, Einerson RR *et al.* The incidence and anatomic site specificity of chromosomal translocations in primary extranodal marginal zone B-cell lymphoma of mucosa-associated lymphoid tissue (MALT lymphoma) in North America. *Am. J. Surg. Pathol.* 2006; **30**: 1546–53.
- 40 Takubo K, Aida J, Naomoto Y *et al.* Cardiac rather than intestinal-type background in endoscopic resection specimens of minute Barrett adenocarcinoma. *Hum. Pathol.* 2009; **40**: 65–74.

## Supporting information

Additional supporting information may be found online in the Supporting Information section at the end of the article.

**Table S1.** Localization of Barrett's esophageal adenocarcinoma.

**Table S2.** Color change in flat- or depressed-type lesions.