

Received: 2020.05.27

Accepted: 2020.09.04

Available online: 2020.11.05

Published: 2020.12.26

# A Case of Lingua Villosa Nigra (Black Hairy Tongue) in a 3-Month-Old Infant

## Authors' Contribution:

Study Design A  
Data Collection B  
Statistical Analysis C  
Data Interpretation D  
Manuscript Preparation E  
Literature Search F  
Funds Collection G

ABCEF **Joanna E. Owczarek-Drabińska**  
CEG **Małgorzata Radwan-Oczko**

Department of Oral Pathology, Wrocław Medical University, Wrocław, Poland

**Corresponding Author:** Joanna E. Owczarek-Drabińska, e-mail: [joanna.owczarek@umed.wroc.pl](mailto:joanna.owczarek@umed.wroc.pl)  
**Conflict of interest:** None declared  
**Source of support:** Oral Pathology Department of Wrocław Medical University

**Patient:** Female, 3-month-old  
**Final Diagnosis:** Black hairy tongue  
**Symptoms:** Discolored tongue  
**Medication:** —  
**Clinical Procedure:** Gentle tongue brushing  
**Specialty:** Pediatrics and Neonatology

**Objective:** Rare disease


**Background:** Black hairy tongue is a self-limiting, usually asymptomatic, benign lesion that most often affects men and people aged over 30–40 years. The lesion is extremely rare among newborns and infants. *Lingua villosa nigra* is characterized by the presence of elongated filiform papillae of the dorsum of the tongue, which gives a hairy appearance. The overgrown papillae can accumulate fungi, bacteria, pigments originating from food, or any other debris that can contribute to the discoloration of the tongue. The prognosis for black hairy tongue is positive. Gentle tongue brushing or scraping as well as the elimination of predisposing factors usually leads to cessation of the lesion.

**Case Report:** A generally healthy, exclusively breastfed 3-month-old female baby was admitted to the Oral Pathology Department of Wrocław Medical University due to a persistent tongue lesion. Intraorally, dark, blackish, elongated tongue papillae were observed. Three weeks earlier, the baby's pediatrician had diagnosed thrush and prescribed systemic antifungal treatment with *Nystatinum*, without prior mycological examination. The lesion did not resolve and the girl was referred to the Department of Oral Pathology. A meticulous medical and dietary interview revealed that since the 28<sup>th</sup> day of life the baby had been supplemented with vitamin C. This, together with an intraoral examination, led to the diagnosis of black hairy tongue. The lesion disappeared partially after 4 weeks of tongue brushing.

**Conclusions:** To prevent infants from undergoing persistent and unnecessary treatment (topical or systemic drugs) or additional diagnostic procedures, such as biopsy, it is essential to be familiar with the characteristics of *lingua villosa nigra* as well as its origin and management. The consideration of this condition is invaluable for babies' health and safety.

**MeSH Keywords:** Ascorbic Acid • Infant • Tongue, Hairy

**Full-text PDF:** <https://www.amjcaserep.com/abstract/index/idArt/926362>



1367



2



2



9



## Background

*Lingua villosa nigra*, also known as black hairy tongue (BHT), is a self-limiting, usually asymptomatic, benign lesion that most often affects men and people over 30–40 years old, as well as people who do not brush their tongue [1–3]. *Lingua villosa nigra* is characterized by the presence of elongated filiform papillae of the dorsum of the tongue, which gives a hairy appearance. They develop due to a hypertrophic reaction connected with either abnormal keratin accumulation or altered keratinized layer desquamation [4]. The overgrown papillae can accumulate fungi, bacteria, food, liquid pigments, or any other debris that can contribute to the discoloration of the tongue. The incidence of this lesion is positively correlated with age and consumption of pulpy food. This disorder is also commonly observed in patients undergoing antibacterial therapy (penicillin, aureomycin, mepazine, neomycin, tetracycline, doxycycline, fluoxetine, lansoprazole, erythromycin, or linezolid), using drugs that can induce xerostomia (antipsychotics, anticholinergics, or antidepressants), undergoing radiation therapy, or using oxidizing mouthwashes. It is also commonly observed in tobacco smokers and patients infected with *Candida albicans*. The development of BHT is also connected with changes in pH of the saliva in the mouth. Dietary products such as herbal remedies or vitamin supplements contribute to this process [1,2,5]. The prevalence of *lingua villosa nigra* differs between researchers, showing a wide range in different settings: between 0% in Caucasian school children in South Africa, 0.06% in Minnesota (USA) school children, 8.9% in Iranian dental patients, and up to almost 54% among Turkish patients visiting for conservative dentistry [1]. Hairy tongue begins to form in the midline of the tongue, around the foramen cecum, and spreads sideways and forward. Involved filiform papillae change their color, elongate gradually, and can reach a length of several millimeters [2]. The prognosis for BHT is positive. Gentle tongue brushing or scraping as well as the elimination of predisposing factors usually results in cessation of the lesion. In addition, topical usage of baking soda or hydrogen peroxide, topical and oral retinoids, antifungal drugs, 40% urea, gentian violet, salicylic acid, vitamin B complex, and even topical triamcinolone or podophyllin have been described in the literature as successfully resolving BHT [1,3,5].

In this report, we describe a rare case of BHT in a 3-month-old infant and the conservative treatment approach undertaken. To the best of our knowledge, this case is the eighth to be described in the literature and the first to be observed after topical supplementation with vitamin C.

## Case Report

A 3-month-old female baby was admitted to the Oral Pathology Department due to a persistent, dark tongue lesion. The infant

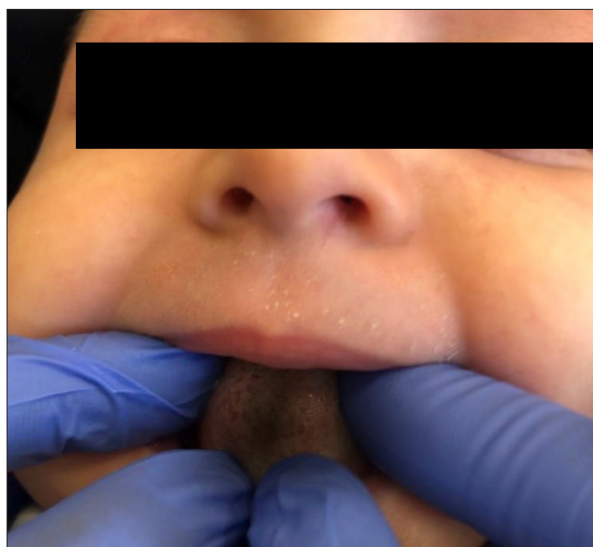


Figure 1. Black hairy tongue in an infant.

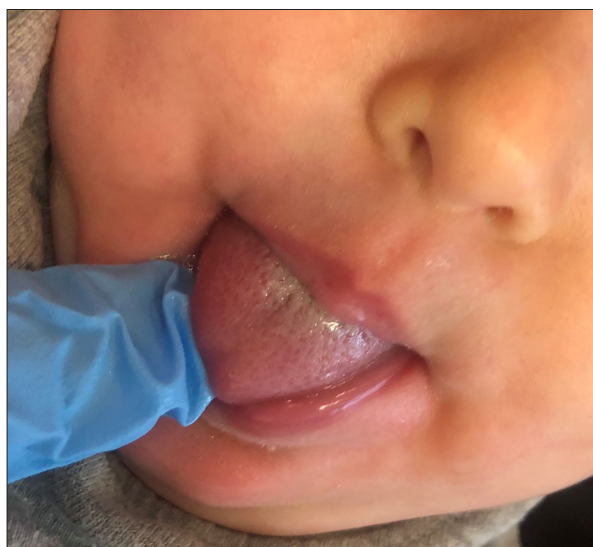

Figure 2. The tongue after 4 weeks of treatment.

was generally healthy, delivered on time by natural forces to healthy parents, without any family history of Addison's disease, Peutz-Jegher syndrome, or von Recklinghausen disease. She was exclusively breastfed. The initial diagnosis, made 3 weeks earlier by her pediatrician solely on the basis of clinical presentation of the tongue's lesion, was thrush. The doctor prescribed systemic antifungal treatment with *Nystatinum* (5×/day, 2000 units, per os), without prior mycological examination. The lesion was still present after 10 days. The pediatrician took a swab for confirmation of fungal infection. Although the result was negative, the doctor nevertheless retained the systemic antifungal treatment and referred the infant to the Department of Oral Pathology. Intraoral examination revealed dark, blackish, elongated tongue papillae, especially in the median-anterior part of the dorsum of the tongue (Figure 1). No

**Table 1.** Naranjo adverse drug reaction probability scale with answers in regard to the presented case.

Naranjo question	Naranjo answer and score
1. Are there previous conclusive reports on this reaction?	No; 0
2. Did the adverse events appear after the suspected drug was given?	Yes; +2
3. Did the adverse reaction improve when the drug was discontinued or a specific antagonist was given?	Yes; +1
4. Did the adverse reaction appear when the drug was readministered?	Do not know; 0
5. Are there alternative causes that could have caused the reaction?	No; +2
6. Did the reaction reappear when a placebo was given?	Do not know; 0
7. Was the drug detected in any body fluid in toxic concentrations?	Do not know; 0
8. Was the reaction more severe when the dose was increased, or less severe when the dose was decreased?	Do not know; 0
9. Did the patient have a similar reaction to the same or similar drugs in any previous exposure?	Do not know; 0
10. Was the adverse event confirmed by any objective evidence?	Yes; +1

other discolorations were found in the oral mucosa or on the skin. Moreover, the baby presented in generally good condition. Up-to-date blood test results for morphology and C-reactive protein and test results for thyroid function, presented by the mother on the day of the visit, were confirmed. A meticulous medical and dietary interview revealed that since the 28<sup>th</sup> day of life, the baby had been supplemented with vitamin C (ascorbic acid, Cebion), 5–6 drops daily. This, together with the clinical manifestation, led to the diagnosis of BHT. The mother was advised to stop both *Nystatin* and ascorbic acid and to start gently brushing her daughter's tongue, at least twice daily, with a silicon finger toothbrush. The lesion partially resolved after 4 weeks (Figure 2). The disappearance was only partial because the mother had encountered problems in reaching the deeper parts of the tongue. There was no recurrence after 4 months.

## Discussion

BHT is observed moderately often in adults, but it is extremely rare among newborns and infants. The youngest patient with a clinical diagnosis of BHT was reported by Schwartz and Lee [6]. This 2-week-old, healthy newborn had been fed both breast milk and formula, and had no medication or herbal infusions in his medical history. In this baby, the lesion started to disappear after 3 days of soft bristle tongue brushing. No recurrence of the lesion was reported, but the etiology remained undiscovered by the authors. The next 2 reports of *lingua villosa nigra* concerned two 8-week-old infants, both exclusively breastfed [7,8]. One of them was treated unsuccessfully with topical miconazole for 20 days; this was prescribed by a family pediatrician to treat the condition. However, the baby then responded well to topical treatment with 10% urea [7]. For the second baby, who had a 4-week history of BHT, Körber and Voshege [8]

**Table 2.** Interpretation of total scores of the Naranjo adverse drug reaction probability scale.

Naranjo score	Interpretation
≥9	Definite
5–8	Probable
1–4	Possible
0	Doubtful

did a biopsy on the infant, but before they had obtained the results, the lesion resolved spontaneously. Similarly to our case, Popik et al. [9] and Pouloupoulos et al. [5] reported cases of *lingua villosa nigra* that probably developed due to dietary habits. In the case presented by Popik et al., an herbal tea (mix of chamomile, mint, fennel, anise, thyme, and maltodextrin) induced BHT in a 2-month-old healthy girl. The BHT was diagnosed thanks to a detailed medical interview and deep insight into the family's medical history, and was confirmed by histopathological results. Pouloupoulos et al. diagnosed BHT in a 45-day-old male infant who was being supplemented orally with vitamin D and an anticolitic herbal infusion (mixture of *Melissa officinalis*, chamomile, and *Lactobacillus acidophilus*). The last 2 cases, along with our own case reported here, implicate a possible association with usage of some herbal infusions as well as some vitamin supplements (vitamins C and D). The creation of a low pH (acidic) environment in the oral cavity and on the tongue surface may be a predisposing factor to BHT development. To justify this hypothesis, the Naranjo Adverse Drug Reaction Probability Scale in Thompson and Kessler's adaptation for BHT was used to verify our case [1]. In our reported case, the total Naranjo score was 6, which indicates that the association between ascorbic acid supplementation and BHT was probable (Tables 1, 2). However,

it must not be forgotten that overgrown, elongated filiform papillae much more easily accumulate particles, and this may result in color change of the tongue. Therefore, it is difficult to determine the exact initial cause of BHT development.

BHT, although it may be worrisome for babies' guardians, is above all a benign lesion. Proper oral hygiene and elimination of predisposing factors should be introduced for the best results in treatment. It must be remembered that antifungal treatment should not be the first option for treating this disorder. Although *Candida* may sometimes be identified in the swab taken from *lingua villosa nigra*, it is not a primary fungal infection, and will not respond to antifungal drugs. For the sake of the infants' health, conservative treatments such as gentle tongue scraping or brushing as well as cessation of some predisposing dietary factors should always be considered as the first choice for treatment.

## References:

1. Thompson DF, Kessler TL: Drug-induced black hairy tongue. *Pharmacotherapy*, 2010; 30(6): 585–93
2. Gurvits GE, Tan A: Black hairy tongue syndrome. *World J Gastroenterol*, 2014; 20(31): 10845–50
3. Schlager E, St. Claire C, Ashack K, Khachemoune A: Black hairy tongue: Predisposing factors, diagnosis, and treatment. *Am J Clin Dermatol*, 2017; 18: 563–69
4. Manabe M, Lim HW, Winzer M, Loomis CA: Architectural organization of filiform papillae in normal and black hairy tongue epithelium. *Arch Dermatol*, 1999; 135: 177–81
5. Pouloupoulos AK, Antoniadis DZ, Epivatianos A et al: Black hairy tongue in a 2-month-old infant. *J Paediatr Child Health*, 2008; 44(6): 377–79
6. Schwartz RH, Lee T: A Two-week-old term baby with a black tongue. *Clin Pediatr (Phila)*, 2015; 54(11): 1110–12
7. González Gómez JM, Peláez Cantero MJ, De La Mota Ybancos JL et al: [Black hairy tongue in an infant]. *An Pediatr*, 2012; 77(3): 209–10 [in Spanish]
8. Körber A, Voshege N: Black hairy tongue in an infant. *CMJA*, 2012; 184(1): 68
9. Popik E, Barroso F, Pombeiro J et al: Hairy tongue in a 1-month-old infant. *Arch Dis Child*, 2019; 104: 158

## Conclusions

It is important to remember that, although very rare in babies, black hairy tongue can be seen in general practitioners', pediatricians', or dentists' offices. To prevent infants like our patient from undergoing persistent and unnecessary treatment (topical or systemic antifungal drugs) or additional diagnostic procedures, such as biopsy, it is essential to be familiar with the characteristics of *lingua villosa nigra* as well as its proper management. This knowledge is invaluable for health and safety reasons. It must be remembered that commonly used infants' dietary supplements (e.g. herbal infusions, vitamin C, or any others) may induce black hairy tongue development, the intraoral manifestation of which can be very distressing for parents.

## Conflict of interest

None.