



Resection of heterotopic ossification around the hip after trauma

Nicolas de l'Escalopier^{1,2}

Marjorie Salga³

Laure Gatin¹

François Genêt³

Philippe Denormandie¹

- Traumatic neurological lesions may lead to development of heterotopic ossification. These cases are classified as 'neurogenic heterotopic ossifications' (NHOs). The associated neurological lesions can be caused by cranial trauma or spinal cord injury and may sometimes include a local trauma.
- NHOs that form around the hip joints are of particular interest because they often cause the patient to avoid the sitting position or the resumption of walking.
- Whilst NHO can involve the knee, shoulder and elbow joints, hip-involving NHOs are more numerous, and sometimes develop in close contact with vascular or neurological structures.
- Multi-disciplinary clinical examination is fundamental to evaluate patients for surgical intervention and to define the objectives of the surgery. The best investigation to define an NHO mass is a computerized tomography (CT) scan.
- Resection is performed to liberate a fused joint to provide functionality, and this need not be exhaustive if it is not necessary to increase the range of motion.
- While recurrence does occur post-surgery, a partial resection does not pose a greater risk of recurrence and there are no adjuvant treatments available to reduce this risk.
- The greatest risks associated with NHO surgical resection are infection and haematoma; these risks are very high and must be considered when evaluating patients for surgery.

Keywords: neurogenic heterotopic ossification; osteoma; hip; surgery; trauma

Cite this article: *EFORT Open Rev* 2019;4
DOI: 10.1302/2058-5241.4.180098

Introduction

Neurogenic heterotopic ossification (NHO) is a spontaneous differentiation of muscle tissues to endochondral bone in an unregulated fashion. This bone development occurs in patients who have sustained a traumatic neurological lesion, affecting either the brain or the spinal cord. Since the genesis of NHO is not well understood,¹ few preventive measures reduce its incidence. However, sadly, these measures are often insufficient to control the development of large troublesome NHOs that can fuse joints and completely restrict movement.¹⁵ At Raymond Poincaré Hospital (Garches, France), 377 first-line procedures were performed for neurogenic heterotopic ossification of the hip between 1993 and November 2016.² Of these 377 patients, 293 were secondary to a traumatic injury, with 189 cases involving patients who had sustained a traumatic brain injury and 104 associated with spinal cord injury. Heterotopic ossification of the hip may occur after isolated trauma of the hip.³ In some cases local trauma and neurologic trauma are associated. Luckily, most of our cases were not associated with local trauma of the hip, where significant ossification of the hip associated with consolidation problems may occur.

Our expertise in performing effective surgery to treat NHO has progressed during this experience, and standard practice has advanced and adapted to better treat the pathology, and provide patients with improved quality of life outcomes. Surgical intervention or treatment, and particularly rehabilitation of complicated patients, requires a healthcare setting that can assess and accommodate specific requirements that often cross multiple medical disciplines. Therefore, if possible, these patients should be hospitalized in a rehabilitation department of a 'Medico-surgical unit'. Moreover, the decision to proceed with surgery requires a multidisciplinary consultation to assess correctly patient outcomes. To address

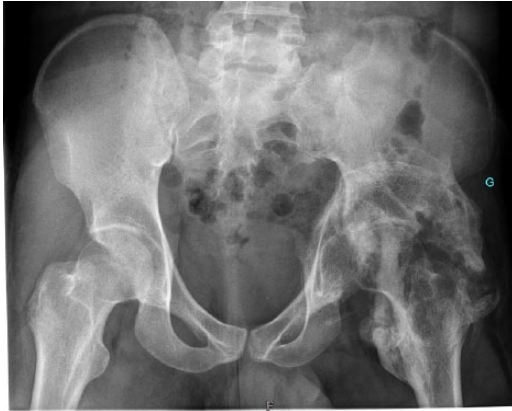

Fig. 1 Antero-posterior X-ray both hips showing neurogenic heterotopic ossification around the left hip and femoral head necrosis.

patient expectations, assessment for surgery should include the patient, or a representative. The overall goal of the multidisciplinary consultation process involves clearly defining the functional impediment produced by the heterotopic ossification, not only for the surgical team but also for the patient. Once a course of action has been negotiated a contractual agreement is made, which stipulates specific clinical gains that are expected from the surgical procedure. This contract describes the extent of resection that will be performed, as complete resection incurs significantly increased risk of morbidity. When indications are correct, results of the surgical response can include a long-lasting functionality of the hip joint.⁴ The process of assessing NHO patients for surgical interventions that will lead to positive functional outcomes involves five main points, which will be discussed further. These include: understanding the disease background, pre-operative patient management, the surgical strategy, post-operative care, and the risks of infection and recurrence.

The disease background

Two types of central nervous system trauma may lead to the formation of NHO of the hip: traumatic brain injury (TBI)^{5,6} and spinal cord injury (SCI).⁷ Most often, they concern polytraumatized patients, who usually require a period of critical care and have sustained various associated neurological and non-neurological lesions from the trauma. Furthermore, the degree of neurological recovery remains uncertain and unpredictable. As a consequence, clinical presentations are multiple. If we want a realistic indication adapted to individual functional demand, neurological status needs to be assessed, and other lesions have to be taken into account.

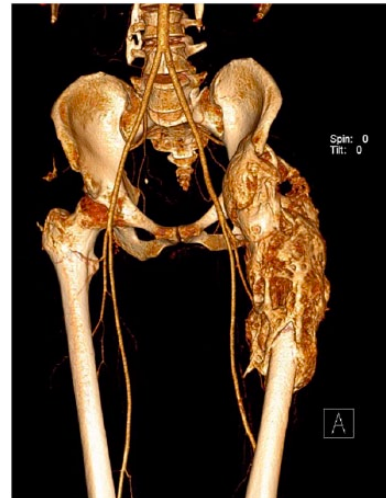

Fig. 2 3D reconstruction showing neurogenic heterotopic ossification associated with a proximal femoral fracture.

Isolated trauma of the hip may occur in patients who develop non-neurological NHO,⁸ though hip trauma is not necessary for NHO. In fact, NHO can be secondary to an isolated neurological lesion, such as that sustained in the absence of trauma during a stroke.^{9,10} However, the association of neurological and local hip trauma can often result in the formation of major NHOs. In our experience, and in most cases, there is an absence of trauma involving the hip. However, in some cases of NHO, TBI went unnoticed. When NHO formations occur in the same hip that sustained a traumatic lesion, the strategy of treatment becomes complicated. This is due to an eventual necessity for an implantation such as a prosthesis, which poses major risks of infection. The following classical cases of combined central nervous system trauma and local trauma involving the hip demonstrate the complications that can arise:

- (1) A patient sustained a posterior hip dislocation with acetabular fracture, and TBI in a motorcycle accident. One year later, the patient had developed an excessive NHO involving the hip and also femoral head necrosis (Fig. 1).
- (2) A patient sustained an SCI at level T11 with partial recovery, and a proximal femoral fracture. Eighteen months after injury, the fracture did not appear to have consolidated, whilst an NHO had developed that formed a bridge of bone connecting the two femoral fragments. In this case, the development of NHO was useful, as the NHO had formed a consolidating bridge between the two femoral fragments. Therefore, surgical intervention to fuse the femoral fragments does not seem necessary (Fig. 2).

NHO can develop in numerous locations around the hip, and development of NHO in these sites appears to be partly dependent on the aetiology of trauma sustained. For example, in patients with SCI, more than half of all NHO developed anterior to the hip (55%), whereas NHOs that developed in patients sustaining TBI were more often localized to the antero-medial zone (39.7%) with frequent proximity to the vascular bundle. The severity of cranial trauma correlates with ossification volume.¹¹ The other locations are medial, posterior – frequently with sciatic compression¹² – lateral, or sometimes circumferential.

The heterotopic ossification grows around, but never involves, joints. Two cleavage planes are useful: the capsule and the periosteum. They permit control of the resection. The capsule is sometimes thin, but still conserved. It is not necessary to perform an arthrotomy if nothing has to be done to the joint. The muscles are often laminated and stretched, but tendon insertions are good landmarks because they are always conserved. The arteries are often surrounded by heterotopic ossification but, maybe due to the blood pressure, are not invaded. By contrast, veins are frequently compressed, and in some instances they may disappear or may be laminated. This happens most frequently with the posterior circumflex vein. If there is still mobility, a bursitis develops at the free end of the HO. If there is a type of ‘pseudarthrosis’ in the HO, the area involved shows fibrosis and multiple small bone fragments between the fragments of the HO.

Pre-operative preparation for the surgical procedure

The optimal time for surgical intervention is when NHO impedes function and becomes ‘troublesome’. Neurogenic heterotopic ossification is defined as ‘troublesome’ when it produces loss of joint motion, or because it is producing pain due to neural or vascular compression. The interval between trauma and surgery does not affect the incidence of recurrence.

We do not perform scintigraphy or other investigations before surgery. We perform surgery if the patient’s status permits it and if there is a likely functional gain. Moreover, early surgery is feasible, and does not have any impact on the risk of recurrence.^{13–15} However, if the delay is too long, in cases with ankylosis of the hip, epiphyseal osteoporosis and cartilage loss may occur causing joint fusion in the worst cases. This bony fragility leads to a risk of cervical fracture which necessitates femoral head neck resection or total hip replacement.

The mean interval between trauma and surgery in our series was 16 months (range 10–38 months). The patients with SCI usually had an anterior heterotopic ossification associated with paraplegia. For those patients the

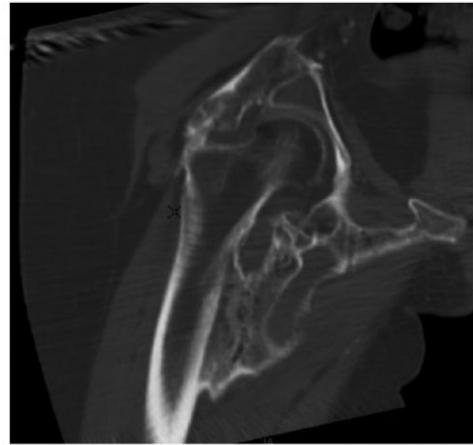


Fig. 3 Computerized tomography (CT) coronal slice showing a conserved joint despite extensive ossification.

objective was to obtain a stable seated posture and self-catheterization. The patients with TBI usually had posterior NHO with sciatic compression in most cases. For them, the problem was a flexion deformity of the hip.

Along with local evaluation of any affected joint and functional disability related to it, it is important to assess the neurological status of the patient. Spasticity and neurological deficit, central or peripheral depending on the aetiology, need to be taken into account.¹⁶ If there are clinical signs of neural compression, a pre-operative electromyography (EMG) must be carried out to confirm the peripheral contribution to the central deficit. If the heterotopic ossification is close to the blood vessels, the detailed vascularity needs to be explored: arterial with a CT scan, and venous with Doppler in cases with signs of phlebitis.

If the X-ray demonstrates the diagnosis and follow-up of the evolution of heterotopic ossification, the essential pre-operative examination is the 3D CT. It allows the definition of the surgical strategy and is essential for pre-operative work-up.¹² The characteristics of the heterotopic ossification, such as the volume and shape,¹⁷ the type and size of any implants and/or an eventual pseudarthrosis can be precisely planned. Moreover, it gives essential information about the joint, such as the epiphyseal vitality, and can assess bone density (Fig. 3). The relationships with vascular or neurological structures may be appreciated, by direct signs for arteries and veins, and indirect for neural compression. In our experience 3D reconstruction is a very useful tool to optimize pre-operative planning.¹⁸

Surgical strategy

The first step is to determine the approach. The location of the heterotopic ossification drives this choice. The different approaches have been described in one of our

previous publications.¹⁹ Next, the proximal and distal implantations have to be identified. The heterotopic ossification is exposed with an electric cautery to reduce bleeding. The covering muscles are released progressively. This exposure may be difficult if the ossification is not continuous. In those cases, fibrosis complicates soft tissue release and increases the risk to vessels or nerves during dissection. Because of that they need to be located and released ahead of resection. The joint capsule needs to be respected and the limits of the joint defined. Finally, only after all the exposure is finished, the resection can start in the most satisfactory way.

The aims of this resection are different from an oncological resection. In the case of heterotopic ossification, it is not necessary to be exhaustive; the limits are 'functional'. Only ossifications which cause limitation of mobility, vascular or nervous compression require removal. Moreover, exhaustive resection can increase morbidity, with no functional advantage, and no impact on risk of recurrence. For example, femoral implantation should be limited to avoid the risk of iatrogenic fracture.

The principal peri-operative risk is haemorrhage, especially when the heterotopic ossification is in contact with vessels. But there is an average 300–500 cc intra-operative blood loss, and up to 1 litre post-operatively due to oozing from the resection. If there is a vascular risk, pre-operative imaging is particularly important for planning the resection. Careful step-by-step haemostasis should be performed to keep bleeding under control in soft tissue and when resecting. We do not use surgical wax anymore due to evidence of late rejection. The large dead zones of resection must have adequate drainage. Usually we use two non-aspirative Redon drains for the first 48 hours associated with a sub-cutaneous Redon aspiration drain.

Procedures on the joints are no longer performed as first-line procedures in our practice. Some authors have described arthrolysis or other joint procedures.²⁰ In the majority of cases it is not necessary, and the stiffness is only extra-articular due to the heterotopic ossification. The rare cases with intra-articular stiffness are caused by cartilage degeneration with fibrosis or fusion between the femoral head and acetabulum. This cartilage degeneration occurs when the delay is prolonged between the trauma and the surgery; this is an important argument for early surgery. There are two solutions, total hip replacement or head and neck resection, which can be scheduled when the pre-operative work-up allows such intra-articular lesions to be foreseen.

One rare problem may be important, which is osteoporosis of the epiphysis, with cartilage that is depressed under pressure even without fracture. In such cases, we graft the epiphysis with cancellous bone harvested from the heterotopic ossification.

The risk during mobilization if there is an intra-articular stiffness, is a fracture below the head after resection of the heterotopic ossification. This is a rare but real complication and, as mentioned before, care must be taken not to weaken the femur in resecting the implantation base of the heterotopic ossification. This risk is exacerbated by ankylosis and by a delay exceeding two years post trauma, with bone demineralization increasing the risk of mobilization causing a fracture below the head.

Our approach depends on NHO location and our objectives. Surgical strategy and details of our resection techniques are summarized in our paper on NHO of the hip.²¹ If two approaches are necessary, most of the time we perform them in two stages to avoid infections and bleeding risk.

Post-operative care

The mobilization begins after the first post-operative week. During the first days after surgery the objective is to limit inflammation and the risk of haematoma. The early primary objectives are pain relief and skin care. Non-steroidal anti-inflammatory drugs are used more for analgesia than to prevent recurrence, for which they have no proven value.²² After the first week, the drains are removed and pain is diminished. The rehabilitation begins more actively at this time, and is always carried out in a dedicated centre. Rehabilitation can be intensified once the sutures have been removed on day 15, and is focused on function. Resumption of weight bearing depends on the risk of femoral head compaction and femoral neck fracture when epiphyseal bone density is low, and is of course adapted according to the patient's general health status. When the bones are fragile, weight bearing is resumed very gradually, beginning with an inclined plane.

Risk of infection, complications and recurrence

The major problem at mid-term is the infection risk, which is high. Preventive measures are essential and should always be taken.²³ Especially for paraplegic patients, painstaking decontamination has to be implemented, especially at the urinary and cutaneous levels. We do not perform the procedure unless urine samples are sterile. Bedsores are a recurrent problem, because they increase the risk of infection and recurrence despite all peri-operative precautions and antibiotic therapy, and are difficult to treat before the surgery because of the limited function related to the heterotopic ossification. Antibiotic prophylaxis (vancomycin and cefazolin) is initiated the day before surgery and continued during the procedure. The infectious complications are frequent notably in SCI patients. There is a 10.3% infection rate in our experience. We have observed variation according to

location: 17.4% in anterior neurogenic ossification, 5% in TBI, but 22% in medullary injury, and aetiology. One of the factors which seems to be predictive of infections in SCI patients is the skin pH.²⁴

The recurrence risk is quite low. In our experience, only 3.5% of patients required revision for recurrence.² The recurrence is difficult to detect and to define because there are no agreed clinical or radiological criteria. The risk does not correlate with primary neurological pathology, trauma-to-surgery time or whether resection was partial or extensive.^{22,25–28} There is, however, a correlation with hypertonia. Moreover, black patients and those with medullary injury seem more at risk of recurrence.²⁹ The other probable risk factors, although not demonstrated, are post-operative haematoma and local inflammation. Peri-operative radiation therapy is often a subject of discussion: some teams consider it as adjuvant to resection, reducing the risk of recurrence.³⁰ Honoré conducted a case-control study³¹ in our department with 19 cases managed by resection plus radiation therapy (a dose of 7 Grays was used for 24 hours before surgery) and 76 controls without radiation therapy. The results showed only a trend toward reduced recurrence risk, with a significantly higher rate of post-operative complications, notably infection in cases with a medullary lesion. That is why, in our practice, complementary radiation therapy is not used anymore in neurogenic heterotopic ossification, and especially not in cases with a medullary lesion.

Conclusions

The management of poly-traumatized patients, who are frequent victims of NHO, and the surgery of post-traumatic neurological heterotopic ossification has to be performed and organized in an adapted centre by a multidisciplinary team. Patients require a very good medico-surgical environment; although peri-operative risks are significant, clinical results are good and recurrence risk limited in these conditions.

AUTHOR INFORMATION

¹Service de Chirurgie Orthopédique, Hôpital Raymond Poincaré, France.

²Service de Chirurgie Orthopédique, Traumatologie et Chirurgie Réparatrice des Membres, Hôpital d'Instruction des Armées Percy, France.

³Service de médecine physique et réadaptation, Hôpital Raymond Poincaré, France.

Correspondence should be sent to: N. de l'Escalopier, Hôpital d'Instruction des Armées Percy - Service de Chirurgie Orthopédique, Traumatologie et Chirurgie Réparatrice des Membres, 101 avenue Henri Barbusse, Clamart 92141, France.
Email: ndeescalopier@gmail.com

FUNDING STATEMENT

No benefits in any form have been received or will be received from a commercial party related directly or indirectly to the subject of this article.

ICMJE CONFLICT OF INTEREST STATEMENT

L. Gatin declares consultancy for Allergan; travel/accommodation/meeting expenses from Merz France Pharma, activities outside the submitted work. M. Salga declares payment for lectures from Allergan/Merz/IPSEN, activities outside the submitted work. F. Genet declares board membership of Allergan SA and Ipsen Pharma; consultancy, expert testimony, payment for lectures and travel/meeting expenses from Allergan SA, Ipsen Pharma, Merz Pharma and Lagarrigue SA, activities outside the submitted work.

LICENCE

© 2019 The author(s)

This article is distributed under the terms of the Creative Commons Attribution-Non Commercial 4.0 International (CC BY-NC 4.0) licence (<https://creativecommons.org/licenses/by-nc/4.0/>) which permits non-commercial use, reproduction and distribution of the work without further permission provided the original work is attributed.

REFERENCES

1. Genêt F, Kulina I, Vaquette C, et al. Neurological heterotopic ossification following spinal cord injury is triggered by macrophage-mediated inflammation in muscle. *J Pathol* 2015;236:229–240.
2. Genêt F, Jourdan C, Schnitzler A, et al. Troublesome heterotopic ossification after central nervous system damage: a survey of 570 surgeries. *PLoS One* 2011;6:e16632.
3. Foley KL, Hebela N, Keenan MA, Pignolo RJ. Histopathology of periarticular non-hereditary heterotopic ossification. *Bone* 2018;109:65–70.
4. Moore TJ. Functional outcome following surgical excision of heterotopic ossification in patients with traumatic brain injury. *J Orthop Trauma* 1993;7:11–14.
5. Sullivan MP, Torres SJ, Mehta S, Ahn J. Heterotopic ossification after central nervous system trauma: a current review. *Bone Joint Res* 2013;2:51–57.
6. Garland DE, Blum CE, Waters RL. Periarticular heterotopic ossification in head-injured adults. Incidence and location. *J Bone Joint Surg Am* 1980;62:1143–1146.
7. Garland DE, Orwin JF. Resection of heterotopic ossification in patients with spinal cord injuries. *Clin Orthop Relat Res* 1989;169–176.
8. Hoyt BW, Pavey GJ, Potter BK, Forsberg JA. Heterotopic ossification and lessons learned from fifteen years at war: a review of therapy, novel research, and future directions for military and civilian orthopaedic trauma. *Bone* 2018; 109:3–11.
9. Genêt F, Minooe K, Jourdan C, Ruet A, Denormandie P, Schnitzler A. Troublesome heterotopic ossification and stroke: features and risk factors. A case control study. *Brain Inj* 2015;29:866–871.
10. Hajek VE. Heterotopic ossification in hemiplegia following stroke. *Arch Phys Med Rehabil* 1987;68:313–314.
11. Ebinger T, Roesch M, Kiefer H, Kinzl L, Schulte M. Influence of etiology in heterotopic bone formation of the hip. *J Trauma* 2000;48:1058–1062.
12. Salga M, Jourdan C, Durand M-C, et al. Sciatic nerve compression by neurogenic heterotopic ossification: use of CT to determine surgical indications. *Skeletal Radiol* 2015;44:233–240.

13. **Genêt F, Chehense C, Jourdan C, Lautridou C, Denormandie P, Schnitzler A.** Impact of the operative delay and the degree of neurologic sequelae on recurrence of excised heterotopic ossification in patients with traumatic brain injury. *J Head Trauma Rehabil* n.d.;27:443–448.
14. **Genet F, Marmorat J-L, Lautridou C, Schnitzler A, Mailhan L, Denormandie P.** Impact of late surgical intervention on heterotopic ossification of the hip after traumatic neurological injury. *J Bone Joint Surg Br* 2009;91:1493–1498.
15. **Genêt F, Ruet A, Almangour W, Gatin L, Denormandie P, Schnitzler A.** Beliefs relating to recurrence of heterotopic ossification following excision in patients with spinal cord injury: a review. *Spinal Cord* 2015;53:340–344.
16. **Sarafis KA, Karatzas GD, Yotis CL.** Ankylosed hips caused by heterotopic ossification after traumatic brain injury: a difficult problem. *J Trauma* 1999;46:104–109.
17. **Carlier RY, Safa DML, Parva P, et al.** Ankylosing neurogenic myositis ossificans of the hip. An enhanced volumetric CT study. *J Bone Joint Surg Br* 2005;87:301–305.
18. **Arduini M, Mancini F, Farsetti P, Piperno A, Ippolito E.** A new classification of peri-articular heterotopic ossification of the hip associated with neurological injury: 3D CT scan assessment and intra-operative findings. *Bone Joint J* 2015;97–B:899–904.
19. **Denormandie P, de l'Éscalopier N, Gatin L, Grelier A, Genêt F.** Resection of neurogenic heterotopic ossification (NHO) of the hip. *Orthop Traumatol Surg Res* 2018;104:S121–S127.
20. **Gacon G, Deidier C, Rhenster JL, Minaire P.** [Ectopic bone formation in neurological lesions (author's transl)]. *Rev Chir Orthop Repar Appar Mot* n.d.;64:375–390.
21. **Denormandie P, de l'Éscalopier N, Gatin L, Grelier A, Genêt F.** Resection of neurogenic heterotopic ossification (NHO) of the hip. *Orthop Traumatol Surg Res* 2018;104(1S):S121–S127.
22. **Almangour W, Schnitzler A, Salga M, Debaud C, Denormandie P.** Recurrence of heterotopic ossification after removal in patients with traumatic brain injury. *Ann Phys Rehabil Med* 2016;59:263–9.
23. **Garland DE, Hanscom DA, Keenan MA, Smith C, Moore T.** Resection of heterotopic ossification in the adult with head trauma. *J Bone Joint Surg Am* 1985;67:1261–1269.
24. **Gatin L, Genet F, Dinh A, Denormandie P.** Postoperative infections after excision of neurogenic heterotopic ossifications at the hip: risk factors and causative organisms. *Orthop Traumatol Surg Res* 2017;103:357–361.
25. **Genêt F, Jourdan C, Lautridou C, et al.** The impact of preoperative hip heterotopic ossification extent on recurrence in patients with head and spinal cord injury: a case control study. *PLoS One* 2011;6:e23129.
26. **Chalidis B, Stengel D, Giannoudis PV.** Early excision and late excision of heterotopic ossification after traumatic brain injury are equivalent: a systematic review of the literature. *J Neurotrauma* 2007;24:1675–1686.
27. **Ippolito E, Formisano R, Caterini R, Farsetti P, Penta F.** Operative treatment of heterotopic hip ossification in patients with coma after brain injury. *Clin Orthop Relat Res* 1999;130–138.
28. **Frischhut B, Stockhammer G, Saltuari L, Kadletz R, Bramanti P.** Early removal of periarticular ossifications in patients with head injury. *Acta Neurol (Napoli)* 1993;15:114–122.
29. **Stover SL, Niemann KM, Tulloss JR.** Experience with surgical resection of heterotopic bone in spinal cord injury patients. *Clin Orthop Relat Res* 1991;263:71–77.
30. **Cipriano C, Pill SG, Rosenstock J, Keenan MA.** Radiation therapy for preventing recurrence of neurogenic heterotopic ossification. *Orthopedics* 2009;32:685–689.
31. **Honoré T.** *Place de la radiothérapie dans le traitement de la paraostéarthropathie de hanche chez les patients blessés médullaires ou traumatisés crânien.* Paris: Descartes, 2016.