

# Retroperitoneoscopic partial nephrectomy for renal cell carcinoma: A single-center Indian experience

Suresh Kumar, Pranjal R. Modi, Bipin C. Pal, Vivek Kothari, Amit Mishra

Department of Urology and Transplantation Surgery, Institute of Kidney Disease and Research Centre, Dr. H.L. Trivedi Institute of Transplant Sciences, Civil Hospital Campus, Ahmedabad, Gujarat, India

## Abstract

**Objective:** Retroperitoneoscopy, by avoiding peritoneal breach and injury to intra-abdominal organs, provides a more direct and rapid access to the kidney and the renal hilum. Laparoscopic partial nephrectomy by retroperitoneal route (LPNR) is less commonly performed than transperitoneal route for early stage renal cancer. The objective of this study is to carry out the outcomes of partial nephrectomy using retroperitoneal approach.

**Materials and Methods:** Patients, who underwent LPNR from period 2008 to 2014, were retrospectively analyzed. Outcomes of interest included demographic data, preoperative data, perioperative variables, surgical complications, recurrence of disease, and mortality, if any, during their follow-up.

**Results:** Among 24 patients, 16 were male, and 8 were female. Mean age and mean body mass index, respectively, were 49.16 years (range: 25–75) and 25.35 kg/m<sup>2</sup> (17.84–34.25). Among renal masses, the right-sided to left-sided distribution was 13:11. The proportions of low-risk and intermediate-risk nephrometry score (NS) cases were 13 (54.17%) and 11 (45.83%), respectively, as assessed by renal NS. Mean operative duration, mean warm ischemia time, mean estimated blood loss, and mean hospital stay, respectively, were 132.5 min (90–170), 21.83 min (15–44), 106 ml (25–300) ml, and 5.25 days. During the postoperative period, complications encountered were lung atelectasis in one, bleeding in two, and urinary leakage in one. Histopathology revealed malignancy in 23 patients and leiomyoma in the remaining one. All patients but two experienced a disease free survival during a median follow-up period of 33 months.

**Conclusion:** Overall outcomes for LPNR is comparable to the outcomes for open and transperitoneal laparoscopic partial nephrectomy mentioned in the literature and is equally safe for the right-sided and left-sided lesions.

**Keywords:** Malignant renal mass, partial nephrectomy, renal cell carcinoma, retroperitoneoscopy

**Address for correspondence:** Dr. Suresh Kumar, Department of Urology and Transplantation Surgery, Institute of Kidney Disease and Research Centre, Dr. H.L. Trivedi Institute of Transplant Sciences, Civil Hospital Campus, Asarwa, Ahmedabad - 380 013, Gujarat, India.

E-mail: sureshsingla08@gmail.com

**Received:** 11.02.2018, **Accepted:** 21.08.2018

## INTRODUCTION

Due to frequent use of radiological imagings, such as ultrasound and computed tomography (CT), more and

more renal cell carcinoma (RCC) has been detected incidentally. Incidental detection of RCC is more than 50% currently. These tumors are usually of the lower

Access this article online	
Quick Response Code:	Website: www.urologyannals.com
	DOI: 10.4103/UA.UA_20_18

This is an open access journal, and articles are distributed under the terms of the Creative Commons Attribution-NonCommercial-ShareAlike 4.0 License, which allows others to remix, tweak, and build upon the work non-commercially, as long as appropriate credit is given and the new creations are licensed under the identical terms.

**For reprints contact:** reprints@medknow.com

**How to cite this article:** Kumar S, Modi PR, Pal BC, Kothari V, Mishra A. Retroperitoneoscopic partial nephrectomy for renal cell carcinoma: A single-center Indian experience. *Urol Ann* 2018;10:400-5.

stage, and surgery is the only treatment for these localized RCC.<sup>[1]</sup> Whenever feasible, nephron-sparing surgery (NSS) has become the preferred surgical approach for T1 RCC because of two reasons. First, literature supports that radical nephrectomy (RN) increases the chances of cardiovascular events<sup>[2]</sup> and more renal failure<sup>[3]</sup> in Stage 1 renal cancer. Moreover, chronic renal failure is further independently associated with higher mortality.<sup>[4]</sup> Second, oncological outcomes of NSS is same as that of RN. It has been well proven that partial nephrectomy through minimally invasive approach results in decreased analgesic use in postoperative period, shorter hospitalization, and decreased wound-related morbidity and early ambulation compared to open partial nephrectomy, but with similar renal function outcomes.<sup>[5]</sup> Laparoscopic partial nephrectomy by transperitoneal route was first described by Winfield *et al.*, in 1993, for benign disease.<sup>[6]</sup> Although laparoscopic partial nephrectomy by retroperitoneal route (LPNR) was first reported by Gill *et al.* in 1994,<sup>[7]</sup> retroperitoneal route is still less commonly performed than transperitoneal route. The purpose of this study is to report the surgical and oncological outcomes of LPNR.

## MATERIALS AND METHODS

Before the beginning of LPNR, the surgeon had prior experience in performing retroperitoneal laparoscopic kidney surgeries and laparoscopic suturing, omitting the influence of early learning curve with regard to the LPNR. With the permission of the Internal Review Board and Institutional Ethics Committee, patients who underwent LPNR from period 2008 to 2014 were retrospectively analyzed. Inclusion criteria in our study were as follows: T1a and selective T1b renal masses, low-to-intermediate-risk nephrometry score (NS) cases. Exclusion criteria were complex/hilar tumor, large anteromedially located tumors, high-risk NS cases, and patient not willing for laparoscopic surgery.

Outcomes of interest included demographic data (age, sex, body mass index, comorbidity, and solitary unit) and preoperative data comprising maximal tumor size on contrast-enhanced CT (CECT) scan, RN scoring whether low or intermediate and laterality. Perioperative variables (total operative duration, warm ischemia time [WIT], estimated blood loss, and hospital stay) were recorded. Medcalc software, version 12.0.0.0, (Ostend, Belgium) was used for statistical analysis (student independent *t*-test). Complications and histopathology were analyzed. All patients were initially followed up at 3 months with clinical examinations, serum creatinine, urinalysis, and sonography whole abdomen then annually

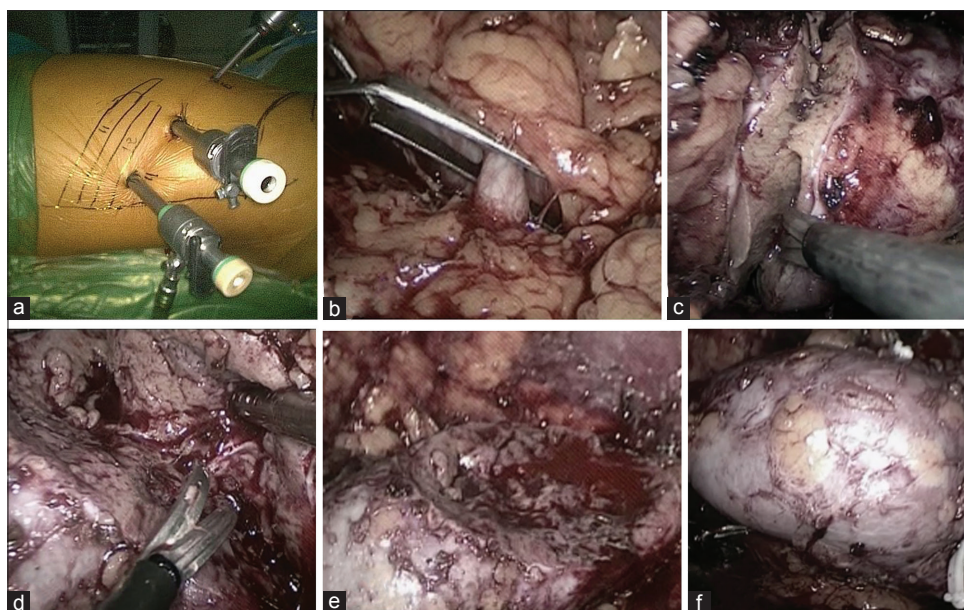
with sonography, chest X-ray, and biochemical profile. CECT of the abdomen and pelvis was once done at 2 years and then when indicated. CECT of the chest was done when indicated. Recurrence of disease and mortality, if any, was recorded. The overall and cancer-specific survival was calculated.

## Operative technique

After induction of patient in general anesthesia, indwelling catheter was inserted. Subsequently, the patient was kept in flank lateral position. An incision of roughly 1–1.2 cm was given below and anterior or posterior to the tip of 12<sup>th</sup> rib depending on the location of renal angle. Retroperitoneum was entered by splitting muscle fibers and incising the lumbodorsal fascia and was dissected in cranial and posterior direction with the help of a peanut dissector. Retroperitoneum was further dissected using double finger of surgical glove balloon dissection technique. Balloon was inflated with saline (10–12 ml/kg), kept inflated for a while, after which, it was deflated and removed. 11-mm laparoscopic port was placed, just inside the edge of lumbodorsal fascia and fixed. Pneumoretroperitoneum was created, and the pressure was kept at 15-mm mercury. Subsequently, two working ports 11 mm and 6 mm were placed under vision [Figure 1a]. Gerota fascia was incised along the medial border of psoas muscle. The kidney was swept along the medial border of psoas muscle. Dissecting loose areolar tissue, renal artery was identified, circumferentially dissected, mannitol 12.5 g intravenously was given during dissection of renal artery, and renal vein was routinely not dissected. Perinephric fat was removed to delineate the tumor margins. Scoring of renal tumor was carried out by laparoscopic hook at about 3–5-mm margin of the tumor. Laparoscopic bulldog clamp was applied over renal artery through posterior working port [Figure 1b]. Dissection of renal tumor was carried out by laparoscopic cold scissor and suction [Figure 1c-e]. Inner endosinus complex was sutured by polyglactin 3-0 with hem-o-lok clip at the tail end of the suture. The outer cortical renorrhaphy was subsequently carried out with polyglactin 2-0, continuous, unknotted with sliding hem-o-lok clips [Figure 1f]. Bulldog clamp over the renal artery was removed. Hemostasis was checked. Specimen was retrieved through extending the camera port incision after putting in a self-made indigenous plastic bag. Ports closure was done in standard fashion.

## RESULTS

Patients details and tumor characteristics are shown in Table 1. Among 24 patients, one patient was intraoperatively converted to laparoscopic RN regarding excising through



**Figure 1:** (a) Ports placement, (b) laparoscopic bulldog application over dissected renal artery, (c and d) dissection of tumor using laparoscopic scissor and suction, (e) renal tumor bed, and (f) cortical renorrhaphy

**Table 1: Patients details and tumor characteristics**

Parameters	Results
Number of cases (n)	24
Age (years), mean	25-75 (49.16)
Male: female	16: 8
BMI (kg/m <sup>2</sup> ), mean	17.84-34.25, 25.35
Number of patients having solitary unit	2
Comorbidity	
Hypertension	3
Diabetes mellitus	1
Tuberculosis	1
Stone disease	2
Maximal tumor size on CT-scan (cm), mean	2.2-6.6 (4.3 cm)
Laterality (right: left)	13: 11
Tumor location	
Upper polar	9 (37.50)
Mid polar	10 (41.66)
Lower polar	5 (20.84)
Proportions assessed by renal NS	
Low risk	13 (54.17)
Intermediate risk	11 (45.83)

BMI: Body mass index, CT: Computed tomography, NS: Nephrometry score

tumor because of the inability to access the surgical margin properly in view of lack of intraoperative laparoscopic ultrasound facility. This case was excluded from statistical analysis. One patient needed angioembolization in view of persistent bleeding. This patient developed intermittent bouts of hematuria, needing cystoscopic clot evacuation on 6<sup>th</sup> postoperative day (POD). On 10<sup>th</sup> POD, he developed massive hematuria, two units pack cell were transfused, cardiology opinion was sought, and the patient was shifted to Intensive Cardiac Coronary Unit. Angiography revealed normal middle pole, a renal arteriovenous fistula (AVF), and another middle pole pseudoaneurysm from a separate inferior branch of middle pole artery. Selective coil embolization was

done. Complete occlusion of renal AVF and pseudoaneurysm was achieved. Postangioembolization, he developed fever, sonography revealed moderate perinephric collection and clots in the bladder for which he underwent cystoscopic clot evacuation and perinephric drainage tube.

One patient needed reexploration in view of bleeding. There was a retroperitoneal hematoma and source of bleeding was loosening of suture from renorrhaphy site. Hematoma was evacuated, and renorrhaphy site was again sutured with placement of Ethicon surgical (oxidized regenerated cellulose). One patient developed fever and urinary soakage from specimen retrieval site. This patient was readmitted, treated with antibiotics. Subsequently, retrograde pyelography revealed contrast extravasation from one of minor calyx, double J stent was inserted and managed conservatively, leakage from main wound stopped on 18<sup>th</sup> day of operation, and stent was taken out after 1 month.

Perioperative parameters, Clavien grading complications, and histopathological analysis are shown in Table 2. One patient (4.1%) had positive surgical margin, which underwent open RN, although final histopathology revealed no evidence of malignancy.

During a median follow-up period of 33 months (mean: 43.125 months and range: 24–60 months), one patient, who had a history of open RN in 2006, had a disease recurrence locally with metastatic disease in the abdomen and bilateral pulmonary metastasis at 42 months of follow-up with serum creatinine 1.75 mg/dl and

**Table 2: Perioperative parameters, complications, and histopathological analysis**

Characteristics	Results
Perioperative parameters	
Mean WIT (min)	21.83
Mean EBL (ml)	106
Mean operative time (min)	132.5
Mean hospital stay (days)	5.25
Clavien grading complications	
1	1
2	1
3a	2
3b	1
4	0
5	0
Histopathological analysis	
Clear cell RCC	15
Chromophobe eosinophilic RCC	6
Papillary RCC	1
c	1
Leiomyoma	1

EBL: Estimated blood loss, WIT: Warm ischemia time, RCC: Renal cell carcinoma

subsequently expired. Another one patient developed pulmonary metastasis without any local recurrence at 24 months of follow-up, he had been kept on tablet Pazopanib 400 mg twice a day after consultation with medical oncologist, he had partial response of disease and alive during 36 months of follow-up. In this study, the overall survival during a median follow-up of 33 months was 95.65%, and cancer-specific survival was 91.30%. All patients except one (having solitary unit at the time of LPNR) had serum creatinine within normal range.

## DISCUSSION

Partial nephrectomy is indicated in three settings as follows: absolute, relative, and elective. It is absolutely indicated when there is solitary kidney whether anatomic or functional. It is relatively indicated when contralateral kidney might be affected in future in view of the presence of comorbidities such as diabetes, hypertension, stone disease, etc., that may impair renal function. It is electively indicated when there is healthy opposite kidney. Patients with hereditary RCCs are also another indication of partial nephrectomy because these group of patients has a high risk of developing additional renal tumors.<sup>[3]</sup> In this study, indications were absolute in two cases, relative in six cases, and elective in remaining 16 cases. LPNR has not gained much popularity. In a study by Gill *et al.*, when he compared LPNR versus transperitoneal route, he mentioned that the rate of former dropped down from 32.6% to 20.8% to 1.3% in his subsequent experience.<sup>[8]</sup> It may be due to limited working space of retroperitoneal approach; however, in our study, we did not encounter any problem of limited space.

Although warm ischemia provides clear surgical field, at the same time, it damages the remaining kidney functionally. Warm ischemic time of more than 20 min might induce consistent deterioration of renal parenchymal function.<sup>[9]</sup> Damage to renal function that occurred during partial nephrectomy is dependent upon multiple factors: quantity and quality of nephrons present, duration of WIT and extent of excision of healthy renal parenchyma during resection. Different ways, such as ice slush,<sup>[10]</sup> cooling through ureteric catheter retrogradely,<sup>[11]</sup> creating hypothermia by the use of angiocatheter into renal artery,<sup>[12]</sup> have been attempted to reduce WIT; however, these maneuvers to reduce renal dysfunction remains unproven. Several studies have suggested that early unclamping<sup>[13]</sup> (after the first layer of cortical renorrhaphy) or segmental clamping<sup>[14]</sup> or even a tertiary arterial branch clamping<sup>[15]</sup> to reduce WIT. All these manipulations are technically challenging and could not be popularized. Moreover, sometimes it is difficult to identify the tumor supplying branch, and hence, ischemia is extended to healthy renal parenchyma as well. Although period is important in determining postoperative renal ischemia, many have recommended critical threshold of WIT ~20–25 min.<sup>[16,17]</sup>

Several techniques for the reconstruction of renal bed (renorrhaphy) involve laparoscopic suturing comprising two layers versus single layer, continuous versus interrupted, figure of eight, and knotting versus sliding hem-o-lok clip with varying results. Further, the use of biological hemostatic agents to achieve further hemostasis has been mentioned in the literature. We used two layers, continuous, unknotted renorrhaphy technique using polyglactin suture with sliding hem-o-lok clips at the tail end. Wahafu *et al.*, in their study, demonstrated the advantages of using poliglecaprone suture because of its monofilament nature.<sup>[18]</sup> Recently, Covidien V-loc suture has been described with advantages of its unidirectional, self-retaining nature, and presence of barbs. In developing countries, we still use polyglactin sutures, and majority of time, we did not encounter any problem of tearing in renal parenchyma, and we did not find any case of stone formation during follow-up. One problem that we noticed that in lower polar mass, there is slight difficulty in suturing because of angulation in LPNR.

There was no difference in WIT in first half (1–12) and second half (13–24) cases in our study ( $P = 0.796$ ). Hence, WIT was not predictive of learning curve from our study. When patients were segregated into tumor size <4 cm, ( $n: 14$ ), and >4 cm ( $n: 9$ ) lesions, WIT was statistically significant ( $P = 0.0092$ ). On further stratifying the patients into low-risk ( $n: 13$ ) and intermediate-risk ( $n: 10$ ) NS,

former were having lower WIT than later; however, it was not statistically significant ( $P = 0.1598$ ). Simmons *et al.* in a multivariate analysis observed that the size of tumor was a significant predictor of WIT.<sup>[19]</sup> Our study supports Simmons observation that tumor size is a predictor of WIT.

Table 3 shows the perioperative outcome in various studies.<sup>[14,15,20,21]</sup> Perioperative outcome in our study is comparable to previous studies, although mean tumor size in our study was relatively large and operative duration was shorter.

Complications were graded using the modified clavien system. In this study, one patient developed lung atelectasis (grade 1 complication), managed by chest physiotherapy; one patient developed grade 2 and 3a complications, needing re-admission, parenteral antibiotic and ureteral stenting; one patient developed grade 3a complication, requiring angio-embolisation; one patient developed grade 3b complications, needing re-exploration in view of bleeding, clot evacuation and re-suturing. None of our patients developed Grade 4 and 5 complications. Few studies have reported complication within 30- and 90-day framework. We did not encounter any complication beyond 1-month period.

Hayn *et al.* had shown that patients with a low-risk NS are less likely to have a bleeding or urinary leakage complications compared with intermediate-risk NS patients whereas patients with high-risk NS have five times more risk of having postoperative urologic complication.<sup>[22]</sup> In this study, all the three patients, who developed complications, were of moderate complexity. Further, we did not perform laparoscopic partial nephrectomy in high-complexity cases since there is enough literature to support high risk of complications in this group.

In a multi-institutional study of NSS of 1800 patients by minimally invasive and open approach, Gill *et al.*<sup>[23]</sup> reported

a 3.1% urinary leak rate and 5.8% blood transfusion rate for laparoscopic partial nephrectomy. In our series, we experienced a urinary leak rate in one patient (4.34%), and two patients (8.69%) needed blood transfusion.

In a study by Tabayoyong *et al.*, overall 806 patients (7%) had surgical margin positivity, and the prevalence rate was 8.1% for laparoscopic partial nephrectomy.<sup>[24]</sup> In this study, one patient, 4.1%, had a positive surgical margin on histopathology which underwent open RN.

Measurement of renal function by serum creatinine is difficult after NSS, particularly in setting of functioning opposite kidney. Although the duration of ischemia is commonly used an index of renal damage, Dube *et al.* in 2015, in their study on robot-assisted partial nephrectomy, demonstrated that even omitting second layer cortical renorrhaphy may decrease WIT significantly but improvement in renal function remains questionable.<sup>[25]</sup> Hence, the extent of excision and repair remains the main fundamentals of kidney function after NSS. Renal scan can estimate the glomerular filtration rate of individual units; however, it is rarely used in clinical practice.<sup>[16]</sup>

Limitation of our study is that first, it is retrospective, observational, and limited size. Second, there may be selection bias because we have included only low-risk and intermediate-risk NS cases. Moreover, it is a single-surgeon series.

## CONCLUSION

Retroperitoneal laparoscopic partial nephrectomy for low-risk and intermediate-risk NS renal masses in experienced hands is safe, with overall outcomes comparable to open and laparoscopic transperitoneal approach mentioned in the literature. However, a large, multi-institutional, and prospective study is required to strengthen the conclusion. Even in the era of robotic surgery,

**Table 3: Perioperative outcome of retroperitoneal laparoscopic partial nephrectomy**

Study	Year	Number of patients	Mean tumor size (cm)	Mean operative duration (min)	Mean WIT (min)	Mean EBL (ml)	Mean hospital stay (days)
Shiyu Song <i>et al.</i> <sup>[20]</sup>	2015	14	3.1±1.0 (1.4-5.2)	171.1±47.2 (83-246)	15.9±9.8 (7-35)	89.3±102.2 (10-300)	6.2±1.9 (4-10)
Tugcu <i>et al.</i> <sup>[21]</sup>	2011	23	3.1	185	25	204	4.1
NG CS <i>et al.</i> <sup>[14]</sup>	2005	63	2.5	174	28	—	2.2
Wright JL <i>et al.</i> <sup>[15]</sup>	2005	32	2.09	210	—	192	2.3
Our study	2017	24	4.3	132.5 (90-170)	21.83 (15-44)	106 (25-300)	3.85 (2-5)* 12.25 (4-27) <sup>†</sup> 5.25 <sup>‡</sup>

Mean hospital stay: \*Those who did not develop complications, <sup>†</sup>Those who develop complications and <sup>‡</sup>Overall mean hospital stay. EBL: Estimated blood loss, WIT: Warm ischemia time

although robotic-assisted transperitoneal laparoscopic partial nephrectomy is evolving, robotic-assisted retroperitoneal surgery is still in infancy, and further in developing countries, where robotic facilities do not exist, LPNR is an alternative, viable, and minimally invasive option for laparoscopic partial nephrectomy.

### Financial support and sponsorship

Nil.

### Conflicts of interest

There are no conflicts of interest.

### REFERENCES

- Ljungberg B, Cowan NC, Hanbury DC, Hora M, Kuczyk MA, Merseburger AS, *et al.* EAU guidelines on renal cell carcinoma: The 2010 update. *Eur Urol* 2010;58:398-406.
- Thompson RH, Boorjian SA, Lohse CM, Leibovich BC, Kwon ED, Chevillet JC, *et al.* Radical nephrectomy for pT1a renal masses may be associated with decreased overall survival compared with partial nephrectomy. *J Urol* 2008;179:468-71.
- Huang WC, Levey AS, Serio AM, Snyder M, Vickers AJ, Raj GV, *et al.* Chronic kidney disease after nephrectomy in patients with renal cortical tumours: A retrospective cohort study. *Lancet Oncol* 2006;7:735-40.
- Go AS, Chertow GM, Fan D, McCulloch CE, Hsu CY. Chronic kidney disease and the risks of death, cardiovascular events, and hospitalization. *N Engl J Med* 2004;351:1296-305.
- Marszalek M, Meixl H, Polajnar M, Rauchenwald M, Jeschke K, Madersbacher S, *et al.* Laparoscopic and open partial nephrectomy: A matched-pair comparison of 200 patients. *Eur Urol* 2009;55:1171-8.
- Winfield HN, Donovan JF, Godet AS, Clayman RV. Laparoscopic partial nephrectomy: Initial case report for benign disease. *J Endourol* 1993;7:521-6.
- Gill IS, Delworth MG, Munch LC. Laparoscopic retroperitoneal partial nephrectomy. *J Urol* 1994;152:1539-42.
- Gill IS, Kamoi K, Aron M, Desai MM. 800 laparoscopic partial nephrectomies: A single surgeon series. *J Urol* 2010;183:34-41.
- Simmons MN, Schreiber MJ, Gill IS. Surgical renal ischemia: A contemporary overview. *J Urol* 2008;180:19-30.
- Cicco A, Salomon L, Hoznek A, Saint F, Alame W, Gasman D, *et al.* Results of retroperitoneal laparoscopic radical nephrectomy. *J Endourol* 2001;15:355-9.
- Gasman D, Saint F, Barthelemy Y, Antiphon P, Chopin D, Abbou CC, *et al.* Retroperitoneoscopy: A laparoscopic approach for adrenal and renal surgery. *Urology* 1996;47:801-6.
- Hoznek A, Salomon L, Antiphon P, Radier C, Hafiani M, Chopin DK, *et al.* Partial nephrectomy with retroperitoneal laparoscopy. *J Urol* 1999;162:1922-6.
- Haber GP, Gill IS. Laparoscopic partial nephrectomy: Contemporary technique and outcomes. *Eur Urol* 2006;49:660-5.
- Ng CS, Gill IS, Ramani AP, Steinberg AP, Spaliviero M, Abreu SC, *et al.* Transperitoneal versus retroperitoneal laparoscopic partial nephrectomy: Patient selection and perioperative outcomes. *J Urol* 2005;174:846-9.
- Wright JL, Porter JR. Laparoscopic partial nephrectomy: Comparison of transperitoneal and retroperitoneal approaches. *J Urol* 2005;174:841-5.
- Porpiglia F, Fiori C, Bertolo R, Angusti T, Piccoli GB, Podio V, *et al.* The effects of warm ischaemia time on renal function after laparoscopic partial nephrectomy in patients with normal contralateral kidney. *World J Urol* 2012;30:257-63.
- Thompson RH, Lane BR, Lohse CM, Leibovich BC, Fergany A, Frank I, *et al.* Every minute counts when the renal hilum is clamped during partial nephrectomy. *Eur Urol* 2010;58:340-5.
- Wahafu W, Ma X, Li HZ, Ding Q, Wang BJ, Shi TP, *et al.* Evolving renorrhaphy technique for retroperitoneal laparoscopic partial nephrectomy: Single-surgeon series. *Int J Urol* 2014;21:865-73.
- Simmons MN, Ching CB, Samplaski MK, Park CH, Gill IS. Kidney tumor location measurement using the C index method. *J Urol* 2010;183:1708-13.
- Song S, Zhang H, Ma L, Huang Y, Zhao L, Wang G, *et al.* The application of "Renal pedicle rotation" method in retroperitoneal laparoscopic partial nephrectomy for renal ventral tumors. *J Endourol* 2015;29:1038-43.
- Tugcu V, Bitkin A, Sonmezay E, Polat H, Ilbey YO, Taşçi AI, *et al.* Transperitoneal versus retroperitoneal laparoscopic partial nephrectomy: Initial experience. *Arch Ital Urol Androl* 2011;83:175-80.
- Hayn MH, Schwaab T, Underwood W, Kim HL. RENAL nephrometry score predicts surgical outcomes of laparoscopic partial nephrectomy. *BJU Int* 2011;108:876-81.
- Gill IS, Kavoussi LR, Lane BR, Blute ML, Babineau D, Colombo JR Jr., *et al.* Comparison of 1,800 laparoscopic and open partial nephrectomies for single renal tumors. *J Urol* 2007;178:41-6.
- Tabayoyong W, Abouassaly R, Kiechle JE, Cherullo EE, Meropol NJ, Shah ND, *et al.* Variation in surgical margin status by surgical approach among patients undergoing partial nephrectomy for small renal masses. *J Urol* 2015;194:1548-53.
- Dube H, Bahler CD, Sundaram CP. The learning curve and factors affecting warm ischemia time during robot-assisted partial nephrectomy. *Indian J Urol* 2015;31:223-8.