

Post COVID Acute Cerebellar Ataxia and Myoclonus (ACAM)

Sir,

Generalized myoclonus, cerebellar ataxia, or the ‘Opsoclonus–myoclonus syndrome’ (OMS) are among the most common movement disorders associated with COVID-19.^[1,2] A closely related, rarer entity, immune-mediated acute cerebellar ataxia and myoclonus (ACAM) without opsoclonus also exists.^[3] Less than 10 cases of ACAM have been reported in association with COVID-19.^[2-8] We report a case of post-COVID ACAM with unusual MRI and 18FDG-PET-CT findings.

A 20-year-old man presented to us with fever and behavioral changes of 3 days duration. He had a history of mild COVID-19, 2 months earlier. Severe acute respiratory syndrome coronavirus 2 reverse transcriptase polymerase chain reaction (SARS CoV2 RT PCR) during this admission was negative. On examination, he was febrile, disoriented, and multifocal spontaneous, postural, and action-induced myoclonus with ataxia. Opsoclonus or ocular flutter were absent. Magnetic resonance imaging (MRI) brain with contrast showed bilateral symmetrical hyperintense areas with restricted diffusion in the basal ganglia and left parieto-occipital cortex. CSF study was normal including a pan encephalitic PCR panel [Table 1]. Electroencephalogram (EEG) showed generalized slowing with a background activity of 4-5 Hz over both posterior heads. Neuromyelitis optica, Myelin oligodendrocyte glycoprotein (NMO, MOG) antibodies, autoimmune encephalitis panel, paraneoplastic panel, and ganglioside antibody panels were negative. An immune-mediated ACAM without opsoclonus was considered. He was treated with brivaracetam 50 mg, sodium valproate, clonazepam, and IV methylprednisolone 1 gm/day for 5 days. Fluoro-deoxy-glucose Positron emission tomography, computed tomography (FDG- PET CT) showed multifocal areas of hypermetabolism [Figure 1, Video 1]. The rest of the whole-body PET CT was normal. He was administered Rituximab 1 gm IV and discharged on oral prednisolone 30 mg/day. Over the next 40 days, his myoclonus and ataxia disappeared. However, he had persistent insomnia,

logorrhea, and residual hypomania. A repeat brain PET-CT on day 40 showed significant resolution of the multifocal hypermetabolic areas. He was administered a second dose of Rituximab 1 gm IV and sodium valproate and olanzapine were continued for mood stabilization. Oral prednisolone 20 mg/day was also added.

Adult OMS is seen with many etiologies.^[3,9] Para or post-infectious COVID-19-OMS (C-OMS), as well as post COVID-19 vaccination OMS, have also been described. COVID-19 can also exacerbate pre-existing OMS.

OMS is diagnosed if three of the following four criteria are fulfilled: a) opsoclonus, b) myoclonus, and/or ataxia c) behavioral changes, and/or sleep disturbances, and d)

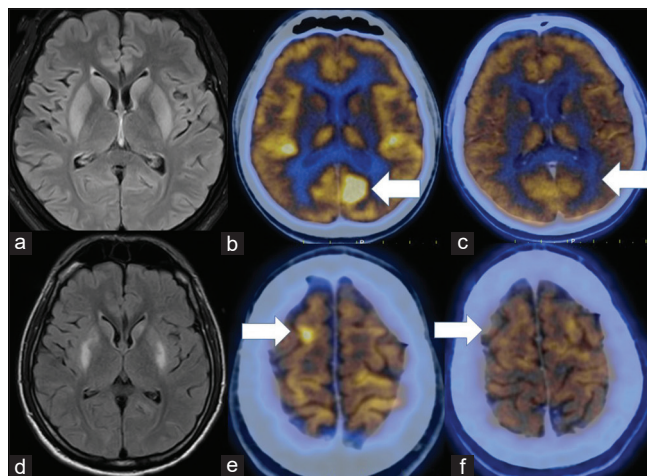


Figure 1: Top panel- Panel a: Initial FLAIR MRI; Symmetrical hyperintensities involving the bilateral putamina and caudate nuclei. PET CT images b: hypermetabolic area in occipital cortex (cuneus). Panel c: hypermetabolic area in the right frontal cortex. Bottom panel- FLAIR MRI (d) on day 20; mild interval reduction in the hyperintensities involving the bilateral putamina and caudate nuclei. PET CT images, at day 40-. e: Metabolic resolution of the hypermetabolic area in the cuneus, f: Metabolic resolution of the hypermetabolic area in the right frontal cortex

Table 1: Tests performed in our patient

Pan-encephalitic PCR panel
<i>Streptococcus pneumoniae</i>
<i>Haemophilus influenzae</i>
<i>Neisseria meningitidis</i>
<i>Mycobacterium tuberculosis</i>
<i>Cryptococcus neoformans</i>
Herpes Simplex Virus 1 & 2
Cytomegalovirus
Varicella Zoster Virus
Human Herpes Virus-6
John Cunningham Virus
Dengue 1-4
West Nile
Enteroviruses
Chikungunya
Rabies
Chandipura
Measles
Mumps
Rubella
Nipah
Japanese B virus
<i>Toxoplasma gondii</i>
Paraneoplastic antibody panel
Antineuronal Nuclear antibodies 1 (Anti Hu)
ANNA-1, ANNA -2
Purkinje Cell cytoplasmic antibodies (PCA 1/Anti Yo)
Amphiphysin
Collapsin response mediator protein-5 (CRMP-5)
Ma 2/Ta
Autoimmune neuronal antibodies
GABA B receptor antibody,
Glutamate receptor antibody NMDA (Anti NR-1),
Contactin-associated protein 2 (CASPR2)
Leucine-rich glioma inactivated protein 1(LGI1)
AMPA 1 and AMPA 2 antibodies
GAD 65
NMO
MOG IgG
GD1b, GQ1b and GM1 IgG and IgM antibodies

Underlying neoplasia and/or the presence of antineuronal antibodies.^[9]

Immune-mediated acute cerebellar ataxia and myoclonus (ACAM) without opsoclonus, is a closely related condition that usually fulfills only two of the four criteria for OMS (usually criteria b and c). Rarely, ACAM may fulfill three of the four criteria (b, c, and d) [with antineuronal antibodies].^[4] Hence it is considered a part of the spectrum of OMS and maybe a forme fruste of OMS.

Opsoclonus is attributed to brainstem ‘burst cell’ overactivity due to either immune-mediated injury to the pontine omnipause neurons or the cerebellar Purkinje cells. Generalized myoclonus in OMS is also presumed to have a brainstem origin by electrophysiological studies. While we could not perform such studies on our patient, a

multifocal cortical origin could not be excluded, based on the FDG-PET-CT images.

Few descriptions of FDG PET-CT in ACAM are available (two cases-showing deep cerebellar hypometabolism and three cases showing a normal PET-CT). In the acute stage of OMS, FDG PET-CT is normal or demonstrates deep cerebellar nuclei hypermetabolism.^[4] The occipital lobes show decreased metabolism due to reciprocal inhibitory functional connectivity changes between the vestibular and visual sensory systems.

Under normal viewing conditions, saccadic eye movements are accompanied by a loss of visual sensitivity saccadic suppression, to reduce eye movement associated with retinal smear and visual blurring. Similarly, the chaotic eye movements of the opsoclonus suppress visual processing in the motion-sensitive magnocellular pathway. During acute OMS, this suppression manifests as PET-CT occipital hypometabolism. However, during the recovery phase, PET CT changes reverse with hypermetabolism of the occipital lobe and hypometabolism of the cerebellar nuclei.

As with COVID-19 associated OMS (C-OMS), we used a combination immunomodulatory treatment with IV methylprednisolone and Rituximab. While IVIg and plasma exchange are often used in C-OMS, our therapeutic decision was influenced by financial considerations and patient preferences. As our patient developed ACAM within 8 weeks of COVID within the time frame for post-COVID complications [such as multisystem inflammatory disease in adults (MIS-A) which occurs within 12 weeks (3 months) of COVID-19], we attributed ACAM to a post-COVID etiology after excluding other causes.

OMS or C-OMS may require prolonged immunosuppressive treatment due to its propensity to relapse. Long term treatment with oral steroids, Mycophenolate mofetil, or azathioprine may also be required. Rituximab or cyclophosphamide are usually used as second-line therapies for recalcitrant disease, or relapses. While most cases of ACAM in the literature, improved with IVIg or IV methylprednisolone, we opted to continue Rituximab and oral steroids due to our behavioral changes and sleep disturbances. Post-COVID-ACAM responds to immunomodulatory therapy and should be considered early in the disease.

Declaration of patient consent

The authors certify that they have obtained all appropriate patient consent forms. In the form the patient(s) has/have given his/her/their consent for his/her/their images and other clinical information to be reported in the journal. The patients understand that their names and initials will not be published and due efforts will be made to conceal their identity, but anonymity cannot be guaranteed.

Financial support and sponsorship

Nil.

Conflicts of interest

There are no conflicts of interest.

Boby Varkey Maramattom, Shagos Gopalan Nair Santhamma¹

Departments of Neurology and ¹Nuclear Medicine, Aster Medcity, Kochi, Kerala, India

Address for correspondence: Dr. Boby Varkey Maramattom, Department of Neurology, Aster Medcity, Kochi - 682 027, Kerala, India. E-mail: bobvarkey@gmail.com

REFERENCES

1. Emamikhah M, Babadi M, Mehrabani M, Jalili M, Pouranian M, Daraie P, *et al.* Opsoclonus-myoclonus syndrome, a post-infectious neurologic complication of COVID-19: Case series and review of literature. *J Neurovirol* 2021;27:26-34.
2. Chan JL, Murphy KA, Sarna JR. Myoclonus and cerebellar ataxia associated with COVID-19: A case report and systematic review. *J Neurol* 2021;268:3517-48.
3. Foucard C, San-Galli A, Tarrano C, Chaumont H, Lannuzel A, Roze E. Acute cerebellar ataxia and myoclonus with or without opsoclonus: A para-infectious syndrome associated with COVID-19. *Eur J Neurol* 2021;28:3533-6.
4. Grimaldi S, Lagarde S, Harlé J-R, Boucraut J, Guedj E. Autoimmune encephalitis concomitant with SARS-CoV-2 infection: Insight from 18 F-FDG PET imaging and neuronal autoantibodies. *J Nucl Med* 2020;61:1726-9.
5. Schellekens MM, Bleeker-Rovers CP, Keurlings PA, Mummery CJ, Bloem BR. Reversible myoclonus-ataxia as a postinfectious

6. Chaumont H, San-Galli A, Martino F, Couratier C, Joguet G, Carles M, *et al.* Mixed central and peripheral nervous system disorders in severe SARS-CoV-2 infection. *J Neurol* 2020;267:3121-7.
7. Delorme C, Paccoud O, Kas A, Hesters A, Bombois S, Shambrook P, *et al.* COVID-19-related encephalopathy: A case series with brain FDG-positron-emission tomography/computed tomography findings. *Eur J Neurol* 2020;27:2651-7.
8. Dijkstra F, Van Den Bossche T, Willekens B, Cras P, Crosiers D. Myoclonus and cerebellar ataxia following COVID-19 clinical practice. *Mov Disord Clin Pract* 2020;7:974-6.
9. Armangué T, Sabater L, Torres-Vega E, Martínez-Hernández E, Ariño H, Petit-Pedrol M, *et al.* Clinical and immunological features of opsoclonus-myoclonus syndrome in the era of neuronal cell surface antibodies. *JAMA Neurol* 2016;73:417-24.

Submitted: 21-Feb-2022 **Revised:** 28-Mar-2022 **Accepted:** 08-Apr-2022

Published: 31-Oct-2022

Video available on: www.annalsofian.org

This is an open access journal, and articles are distributed under the terms of the Creative Commons Attribution-NonCommercial-ShareAlike 4.0 License, which allows others to remix, tweak, and build upon the work non-commercially, as long as appropriate credit is given and the new creations are licensed under the identical terms.

DOI: 10.4103/aian.aian_187_22