



Case Report

Graves' Disease Thyrotoxicosis and Propylthiouracil Related Agranulocytosis Successfully Treated with Therapeutic Plasma Exchange and G-CSF Followed by Total Thyroidectomy

Anna Candoni¹, Federico De Marchi¹, Fabio Vescini², Sara Mauro¹, Cristina Rinaldi³, Marco Piemonte⁴, Nicholas Rabassi¹, Maria Vittoria Dubbini¹ and Renato Fanin¹

¹ Division of Hematology, University Hospital-Santa Maria Misericordia, Udine, Italy.

² Division of Endocrinology, University Hospital of Udine.

³ Therapeutic Apheresis Unit and Stem Cell Manipulation Laboratory, Department of Transfusion Medicine, University Hospital of Udine.

⁴ Otorhinolaryngology Unit, University Hospital of Udine.

Competing interests: The authors have declared that no competing interests exist.

Abstract. Antithyroid drugs can be a rare cause of agranulocytosis (0.5% of treated patients). Suspension of these drugs is mandatory in these patients and may result in worsening hyperthyroidism. We report the case of a 27-year-old woman who is 3 months post-partum, breastfeeding, and suffering with Graves' disease hyperthyroidism treated first with methimazole and then with propylthiouracil due to a methimazole allergy. She was admitted for urosepsis and agranulocytosis. The patient was diagnosed with propylthiouracil related agranulocytosis, diffuse toxic goiter and thyro-gastric syndrome. Antithyroid drug therapy was stopped resulting in a worsening of thyrotoxicosis. Agranulocytosis was treated with 8 doses of G-CSF with full recovery. To rapidly restore euthyroidism and to perform a thyroidectomy, the patient received 6 therapeutic plasma exchange (TPE) procedures, to clear thyroid hormones and anti-TSH receptor antibodies from blood, resulting in a pre-surgical euthyroid state without antithyroid drug therapy. Two years after thyroidectomy, the patient is well under thyroid hormone replacement therapy with a normal granulocyte count.

Keywords: Plasma exchange; Hyperthyroidism, Agranulocytosis; Propylthiouracil.

Citation: Candoni A., De Marchi F., Vescini F., Mauro S., Rinaldi C., Piemonte M., Rabassi N., Dubbini M.V., Fanin R. Graves' disease thyrotoxicosis and propylthiouracil related agranulocytosis successfully treated with therapeutic plasma exchange and G-CSF followed by total thyroidectomy. *Mediterr J Hematol Infect Dis* 2017, 9(1): e2017058, DOI: <http://dx.doi.org/10.4084/MJHID.2017.058>

Published: October 16, 2017

Received: July 8, 2017

Accepted: October 8, 2017

This is an Open Access article distributed under the terms of the Creative Commons Attribution License (<https://creativecommons.org/licenses/by-nc/4.0>), which permits unrestricted use, distribution, and reproduction in any medium, provided the original work is properly cited.

Correspondence to: Anna Candoni, Division of Hematology, University Hospital Santa Maria Misericordia, Udine. E-mail: anna.candoni@asuiud.sanita.fvg.it

Introduction. Graves' disease is an autoimmune thyroid syndrome characterized by the presence of anti-thyroid antibodies, hyperthyroidism, goiter, ophthalmopathy and rarely by dermopathy (pretibial myxedema). Thyrostatic drugs that inhibit thyroid hormone productions, such as methimazole or propylthiouracil, are commonly used to treat this disease.¹⁻⁶ In the majority of

cases these agents are well tolerated and allergic reactions are rare.¹⁻⁶ Skin reactions (mainly urticaria), gastro-intestinal disturbances, arthralgia and hepatotoxicity are reported as possible side effects while vasculitis and neutropenia or agranulocytosis are very rare.¹⁻⁶

Here we report a rare case of a patient with hyperthyroidism and Graves' disease, allergic to

methimazole, treated with propylthiouracil, who developed a propylthiouracil-related agranulocytosis. The patient required granulocyte colony-stimulating factor (G-CSF) administration and received therapeutic plasma exchange (TPE) procedures in order to remove thyroid hormones and anti-TSH receptor antibodies from blood, achieving a mandatory euthyroid state to perform a subsequent safe and curative total thyroidectomy.

Case Report. A 27-year-old breastfeeding woman was admitted to our Department of Hematology for the detection of agranulocytosis complicated with uroseptic fever (blood and urine culture positives for *Escherichia Coli*). Her medical history revealed Graves' disease hyperthyroidism diagnosed in 2007. She was treated with methimazole with repeated episodes of extensive erythroderma causing drug discontinuation and then with propylthiouracil 300 mg/day for 11 months.

On physical examination the patient was tachycardic (105 bpm) and febrile (38.5 °C). A diffuse enlargement of thyroid gland and a mild ophthalmopathy were reported. Antibiotic treatment with piperacillin tazobactam (4.5 g 3 times a day) was started and the following tests were performed:

-Differential Complete Blood Count: hemoglobin 9.8 g/dl (normal range 12-16), MCV 90 fl, platelets 129,000/mm³ (normal range 150,000 to 400,000), leukocytes 1000/mm³ (normal range 4000-11000) with only 2% granulocytes (20/mm³).

-Laboratory tests: lactate dehydrogenase 826 IU/L, haptoglobin <10 mg/dL, total bilirubin 2.70 mg/dL, direct bilirubin 0.64 mg/dL, Coombs test negative; CRP 37 mg/L, erythrocyte sedimentation rate 40 mm/h, B12 Vitamin 171 ng/L (normal values 211-911); renal, hepatic and coagulation tests, folic acid, electrolytes and immunoglobulins were in range. TSH value was less than 0.01 microIU/mL (normal values 0.35 to 5), fT3 6.2 pg/mL (2.3 to 4.2 normal values), fT4 24 pg/mL (8.9 to 17.6). The following auto-antibodies were positive: anti-Thyroglobulin (140 IU/ml- normal values <60), anti-thyroid peroxidase (> 1000 IU/ml-normal value <60), anti-myeloperoxidase (155 AU/ml, normal value <20), anti-TSH receptor (3.84 IU/L; normal value <0.4), anti-intrinsic factor 35 U/mL (normal value 0-5), anti-

neutrophil cytoplasm antibodies (ANCA-1:620, perinuclear pattern). Rheumatoid factor, anti-ds DNA, anti-ENA and anti-transglutaminase antibodies were negative.

-Bone Marrow Aspirate and Biopsy were performed and showed a normocellular hematopoietic parenchyma with marked selective reduction of granulopoiesis, without blastic cells or lymphoid infiltrates. A mild and probably secondary hematopoietic dysplasia with excess of erythroid precursors was reported. Bone marrow karyotype test was normal.

-Electrocardiogram and cardiac examination documented sinus tachycardia without any signs of heart failure.

- Abdominal Ultrasound documented a slight increase in spleen size. No abdominal organ had parenchymal abnormalities and there were no deep enlarged lymph nodes.

According to the above investigations the patient was diagnosed with "Agranulocytosis related to propylthiouracil therapy and complicated by uroseptic fever, thyro-gastric syndrome (intrinsic factor antibodies positivity, vitamin B12 deficiency, anemia, hemolysis and mild thrombocytopenia) in patient with diffuse toxic goiter and thyrotoxicosis".

The treatment plan was shared with endocrinologists, cardiologists and surgeons. Propylthiouracil was stopped while beta blocker therapy (propranolol, 120 mg/day) was maintained. For the treatment of agranulocytosis, the patient received 8 doses of G-CSF, subcutaneously, at a dose of 300 µg/daily. Therapy with piperacillin-tazobactam and steroids was given for 16 days (fever >38°C for 11 days). Thyro-gastric syndrome required supplementation with vitamin B12, 5000 IU/day IV for 8 days.

The patient was then evaluated for surgical treatment and a total thyroidectomy was scheduled. To perform this procedure, normal peripheral blood counts and a euthyroid state were required to avoid thyroid storm during surgery. To reach this goal without antithyroid drugs, 6 therapeutic plasma exchange (TPE) procedures were performed over 12 days to remove the circulating thyroid hormones and the TSH receptor antibodies. In detail, TPE was carried out to exchange 1–1.5 plasma volumes every two days using Spectra Optia apheresis machine (Manufacturer TERUMO BCT). Albumin 5% and normal saline solution were used as the

replacement products; heparin and acid citrate dextrose (ACD-A) 350-400 ml were used as anticoagulants at a 12:1 anticoagulant ratio. Patient underwent TPE using a 16 G peripheral access needle in an antecubital fossa vein; a 20 G venous cannula was placed in the opposite arm for the return line. In order to avoid severe hypocalcemia and acid ACD toxicity during the procedure the patient received an intravenous infusion of 10% calcium gluconate, providing up to 850 mg of calcium. Vital signs were monitored at the beginning, and end of each procedure and patient was monitored for adverse events. Pre and post procedural hematological and renal parameters were evaluated.

Figure 1 shows the decrease of thyroid hormones and anti TSH receptor antibodies during TPE procedures. **Figure 2** shows granulocytic recovery (PMN recovery) during and after G-CSF therapy.

After the administration of 8 daily doses of G-CSF and 6 TPE procedures the patient reached a euthyroid state and a total thyroidectomy was performed. No peri or post-operative complications were reported. Pre surgery differential blood cell count was as follows: hemoglobin 10.2 g/dl, platelets 218,000/mmc, leukocytes 3,900/mmc with granulocytes 57% (2223/mmc).

Thyroid histological examination showed a hyperfunctioning, hyperplastic adenomatous parenchyma, consistent with Graves' disease.

Two year after thyroidectomy the patient is well, undergoing thyroid hormone replacement therapy and maintaining a normal granulocyte count.

Discussion. Hematologic complications during thyroid disease therapy are rare and often require a multidisciplinary approach. This case report shows the complexity of these situations, in which multiple and rare hematological and non-hematological complications are often present together. In this particular case we found:

-Propylthiouracil-related agranulocytosis in a patient allergic to methimazole and therefore without any available drug therapy for her hyperthyroidism.

-A thyro-gastric syndrome with evidence of antibodies against intrinsic factor and proven B12 vitamin deficiency resulting in a secondary hematopoietic dysplasia with anemia and mild thrombocytopenia, successfully treated with B12 vitamin supplementation.

-Hyperthyroidism with signs and symptoms of thyrotoxicosis with the need to remove, without any antithyroid drug available, circulating thyroid hormones and anti-TSH antibodies in order to

Figure 1.

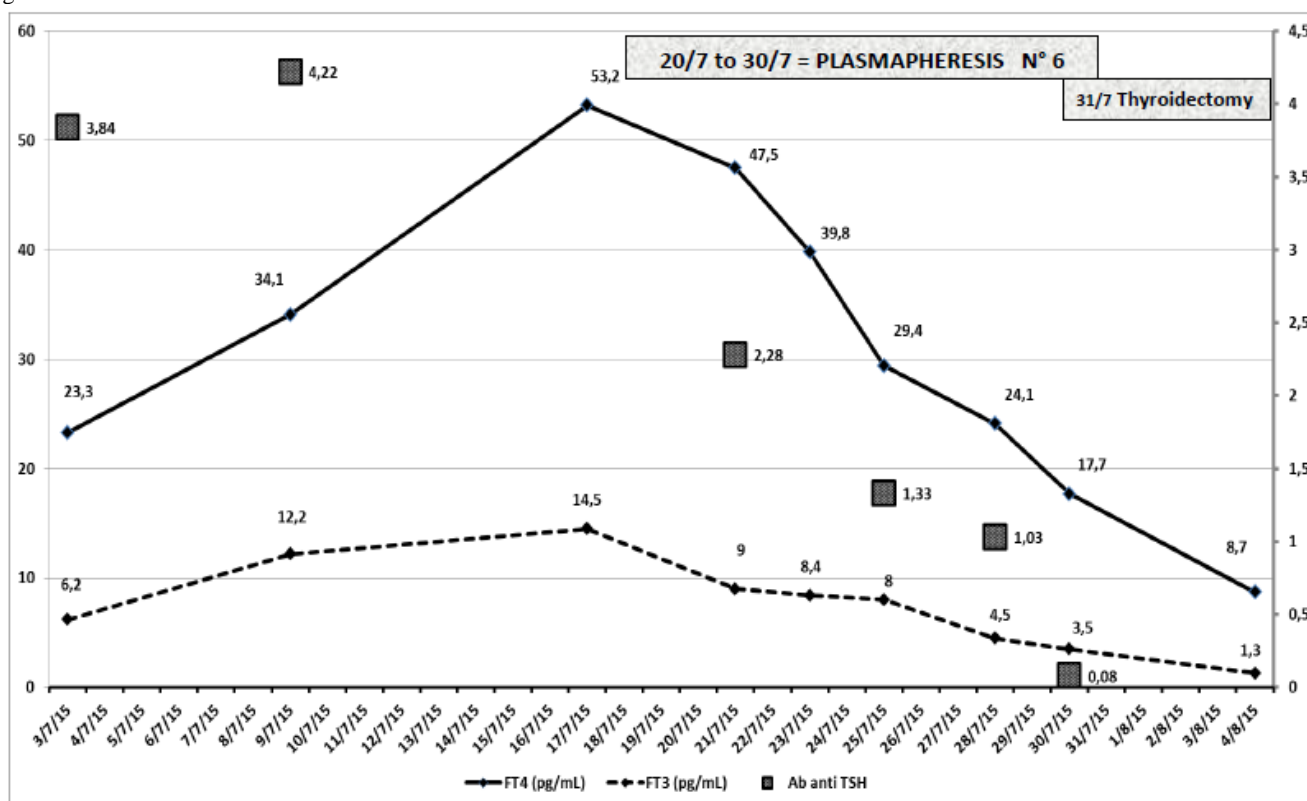
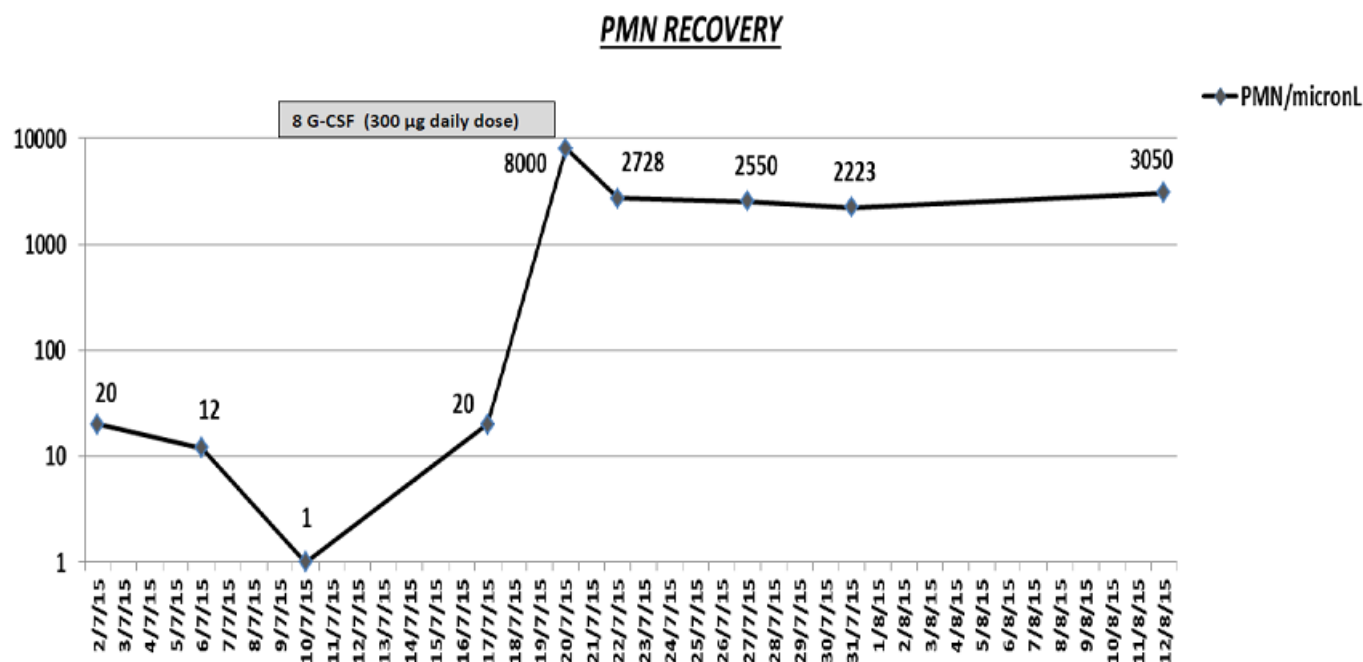


Figure 2.



perform a safe thyroidectomy (to obtain a definitive surgical hyperthyroidism resolution).

Agranulocytosis (defined as an absolute granulocyte count less than 100 cells/mmc) is a rare complication during antithyroid drug therapy with a frequency of less than 0.5% both in methimazole and propylthiouracil treated cases.¹⁻³ In particular, propylthiouracil-induced agranulocytosis occurs more frequently in the first 3 months of treatment.¹⁻³ This condition represents an absolute indication for propylthiouracil discontinuation and may be complicated by severe life-threatening infections. Rather than being a direct toxic drug effect, agranulocytosis seems to be related to an immunological mechanism with production of drug-induced anti-granulocytes antibodies.¹⁻⁷ The presence of these antibodies (ANCA) has also been documented in our case report.

Only rare cases of thyrotoxicosis successfully treated with TPE, without any related complications, has been described in the literature.⁸⁻¹² There were also some data regarding the beneficial effects of intensive TPE followed by immunosuppressive therapy in severe progressive Graves' ophthalmopathy with most marked effects on soft tissue involvement, proptosis, intraocular pressure and visual acuity.¹³ Recently, TPE has

been successfully used also in a case of extreme iatrogenic thyrotoxicosis due to excessive thyroid replacement hormones ingestion showing a rapid decline of total and free T3 and symptoms resolution.¹⁴

In autoimmune based thyroid diseases the positive effect of TPE and its ability to restore a euthyroid state is probably not only linked to direct thyroid hormones removal, but it might also be explained by the clearance of anti-TSH and anti-thyroid antibodies (which maintained the hyperthyroidism), as we showed in **Figure 1**.⁸⁻¹³

Our case confirms the efficacy and the optimal tolerability of TPE procedure and its benefit in the cases where a pharmacological approach is contraindicated or not available. However, the effect of TPE is gradual and only transient, lasting less than 3-4 days. For this reason close and repeated plasma exchange sessions (in our case 6 over 12 days) were necessary to obtain a result and, therefore, this therapeutic option cannot be considered as the only curative treatment in these situations.⁸⁻¹⁴ Nevertheless, TPE can be a lifesaving procedure to obtain a transitional euthyroid state before complete thyroidectomy with minimal risk of thyroid storm or surgical bleeding induced by thyroid tissue hypervascularization.

References:

1. Curtis BR, Drug-induced immune neutropenia/agranulocytosis. *Immunohematology* 2014;30(2): 95-101. PMID:25247619
 2. Andersohn F, Konzen C, Garbe E. Systematic review: agranulocytosis induced by nonchemotherapy drugs. *Ann Intern Med* 2007; 146: 657-65. <https://doi.org/10.7326/0003-4819-146-9-200705010-00009> PMID:17470834

3. Copper DS. The side effects of antithyroid drugs. *Endocrinologist* 1999; 9: 457-67. <https://doi.org/10.1097/00019616-199911000-00008>
4. Khaliq W, Ponor L, Cheripalli P, Tangella K, Chaudry Z. Agranulocytosis secondary to propylthiouracil. *QJ Med* 2012; 105: 1109-1111. <https://doi.org/10.1093/qjmed/hcr168> PMID:21920992
5. Cho, Sang Shon, Dae Yoon. Management of a pregnant patient with Graves' Disease complicated by Propylthiouracil induced agranulocytosis. *The Korean J of Internal Med* 2005; 20: 335-338. <https://doi.org/10.3904/kjim.2005.20.4.335> PMID:16491833 PMCID:PMC3891081
6. Finucane FM, O'Connell J, Kinsley BT. Propylthiouracil induced C-ANCA positive agranulocytosis complicating Graves' thyrotoxicosis in pregnancy. *Ir J Med Sci* 2008; 177(1):69-71. <https://doi.org/10.1007/s11845-007-0055-5> PMID:17611791
7. Waldhauser L, Uetrecht J. Oxidation of propylthiouracil to reactive metabolites by activated neutrophils. Implications for agranulocytosis. *Drug Metab Dispos* 1991; 19: 354-9. PMID:1676636
8. Winters JL. Plasma exchange: concepts, mechanisms, and overview of the American Society of Apheresis guidelines. *Hematology* 2012;7-12. PMID:23233554
9. Bilir BE, Atile NS, Kirkizlar O, Kömtürçü Y, Akpınar S, Sezer A, et al. Effectiveness of preoperative plasmapheresis in a pregnancy complicated by hyperthyroidism and anti-thyroid drug-associated angioedema. *Gynecol Endocrinol.* 2013; 29(5):508-10. <https://doi.org/10.3109/09513590.2012.754871> PMID:23383744
10. Ezer A, Caliskan K, Parlakgumus A, Belli S, Kozanoglu I, Yidirim S. Preoperative therapeutic plasma exchange in patients with thyrotoxicosis. *J Clin Apher* 2009; 24: 111-114. <https://doi.org/10.1002/jca.20200> PMID:19484727
11. Vyas AA, Vyas P, Fillipon NL, Vijayakrishnan R, Trivedi N. Successful treatment of thyroid storm with plasmapheresis in a patient with methimazole-induced agranulocytosis. *Endocr Pract.* 2010 ; 16(4):673-6. <https://doi.org/10.4158/EP09265.CR> PMID:20439250
12. Guvenc B, Unsal C, Gurkan E, Dincer S. Plasmapheresis in the treatment of hyperthyroidism associated with agranulocytosis: a case report. *J Clin Apher* 2004; 19(3): 148-50. <https://doi.org/10.1002/jca.20014> PMID:15493048
13. Glinoeer D1, Etienne-Decerf J, Schrooyen M, Sand G, Hoyoux P, Mahieu P, Winand R. Beneficial effects of intensive plasma exchange followed by immunosuppressive therapy in severe Graves' ophthalmopathy. *Metab Pediatr Syst Ophthalmol* 1988;11(3):133-40.
14. Shah KK, Mbughuni MM, Burgstaler EA, Block DR, Winters JL. Iatrogenic thyrotoxicosis and the role of therapeutic plasma exchange. *J Clin Apher* 2017 [in press]. <https://doi.org/10.1002/jca.21536> PMID:28319287