

Case report

A double-edged sword

A 33-year old man presented because of progressive fatigue, loss of appetite and malaise for 2 months. While carrying out his job as a baggage handler at the airport, he noticed exertional dyspnoea (New York Heart Association class II) with a slight nonproductive cough. There was no weight loss or fever, although he mentioned paroxysmal hot flushes. There were no recent infections and his past medical and familial history were negative. The patient denied the use of drugs, nicotine or alcohol, reported no recent travel and had a stable relationship.

On physical examination, normal vital signs, no fever and normal oxygen saturation while breathing room air were noted. Head-to-toe assessment demonstrated bilateral crackles on lung auscultation, splenomegaly and slight icteric sclera. No cervical or supraclavicular adenopathies were palpable.

Orienting tests including a plain radiograph of the lung, a blood sample and a urine analysis were performed.

The chest radiograph showed a bilateral reticulonodular pattern with basal predominance (figure 1). Laboratory testing showed normocytic anaemia ($7.4 \text{ g}\cdot\text{dL}^{-1}$, normal range (NR) $13.5\text{--}17.5 \text{ g}\cdot\text{dL}^{-1}$, mean corpuscular volume 94.8 fL , NR $80\text{--}96 \text{ fL}$ per red cell), with normal vitamin status (folic acid, vitamin B12 and iron), but with signs of haemolysis (haptoglobin $<0.20 \text{ g}\cdot\text{L}^{-1}$, lactate dehydrogenase $781 \text{ U}\cdot\text{L}^{-1}$ (NR $140\text{--}280 \text{ U}\cdot\text{L}^{-1}$) and a total bilirubin of $2.77 \text{ mg}\cdot\text{dL}^{-1}$ without an increase in direct bilirubin). Coombs test was negative and no schistocytes were found on a peripheral blood smear. White blood cell count was slightly

lowered ($3.3\times 10^9 \text{ L}^{-1}$, NR 4.5 to $11\times 10^9 \text{ L}^{-1}$), with a proportionate differential cell count.

He had a mild increase of alkaline phosphatase $162 \text{ U}\cdot\text{L}^{-1}$ (NR $40\text{--}150 \text{ U}\cdot\text{L}^{-1}$), gamma glutamyltranspeptidase $101 \text{ U}\cdot\text{L}^{-1}$ (NR $12\text{--}64 \text{ U}\cdot\text{L}^{-1}$), aspartate aminotransferase $64 \text{ U}\cdot\text{L}^{-1}$ (NR $5\text{--}34 \text{ U}\cdot\text{L}^{-1}$) and alanine aminotransferase $116 \text{ U}\cdot\text{L}^{-1}$ (NR $0\text{--}55 \text{ U}\cdot\text{L}^{-1}$), no renal dysfunction or electrolyte imbalance was found, and C-reactive protein was not elevated ($5 \text{ mg}\cdot\text{L}^{-1}$, NR $<5 \text{ mg}\cdot\text{L}^{-1}$). Urine analysis showed no leukocyturia, haematuria or proteinuria.

So far, we present a patient with fatigue, malaise and dyspnoea for 2 months, lung crackles and an aberrant chest radiograph, splenomegaly, icterus and disturbed liver tests, and Coombs negative haemolytic anaemia without signs of inflammation.

Task 1: What would be your next step?

- This is a case of Epstein–Barr virus (EBV)/ cytomegalovirus infection with prolonged lethargy. I comfort the patient and plan a follow-up in 1 month.
- I prescribe macrolides to treat *Mycoplasma pneumoniae* because this can give cold agglutinin haemolysis.
- I explain to the patient that the dyspnoea is caused by the anaemia and seek further advice from a haematologist.
- I suspect a systemic disease/malignancy and plan further imaging (computed tomography (CT) of the thorax/abdomen and/or positron emission tomography (PET)-CT).

Cite as: Vandebotermert M, Staels F, Giovannozzi S, *et al.* A double-edged sword. *Breathe* 2020; 16: 200017.

 @ERSpublications

In medicine, not everything is what it seems and sometimes you need all the pieces of the puzzle in order to complete the diagnosis. This is a case of a disease with two different faces and a review of its respiratory impact. <https://bit.ly/2SDKwE5>



CrossMark



© ERS 2020

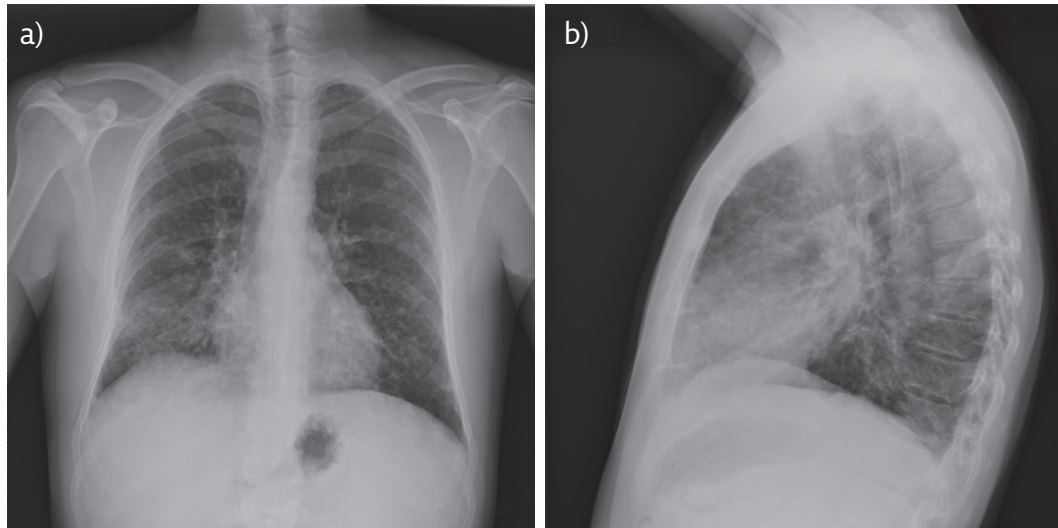


Figure 1 a) Posteroanterior and b) lateral chest radiography showing a diffuse reticulonodular pattern with slight apico-basal gradient and normal cardiac silhouette.

Answer 1

d. The combination of systemic symptoms (malaise, fatigue), with an aberrant lung image, splenomegaly, disturbed liver tests and haemolytic anaemia, warrants further investigation with CT/PET-CT

We can break the differential diagnosis up into three groups: infection, systemic inflammatory/autoimmune disease or malignancy. Infection seems to be the least probable. Serological tests for HIV, hepatitis B virus, hepatitis C virus, cytomegalovirus, EBV and parvovirus B19 were negative. PCR for EBV was negative. The absence of a clear consolidation on radiography, no biochemical inflammation or fever, and a duration of 2 months make a bacterial infection less probable. Moreover, in *Mycoplasma*-induced haemolytic anaemia the Coombs test is mostly

positive. Miliary tuberculosis was included in the differential diagnosis but deemed unlikely.

As a next step, we decided to perform a CT of the thorax/abdomen. The abdominal CT showed diffuse subcentimetric lymph nodes and confirmed splenomegaly and slight hepatomegaly. Selected chest CT images are shown in figure 2.

Task 2: How would you interpret the chest CT shown in figure 2?

- a) A predominant reticular pattern, suggesting fibrosis.
- b) Mediastinal adenopathies and parenchymal nodules suggesting sarcoidosis.
- c) Mediastinal adenopathies, with predominant ground-glass opacities and some nodules.
- d) A combination of consolidation and ground glass suggesting a pulmonary infection.

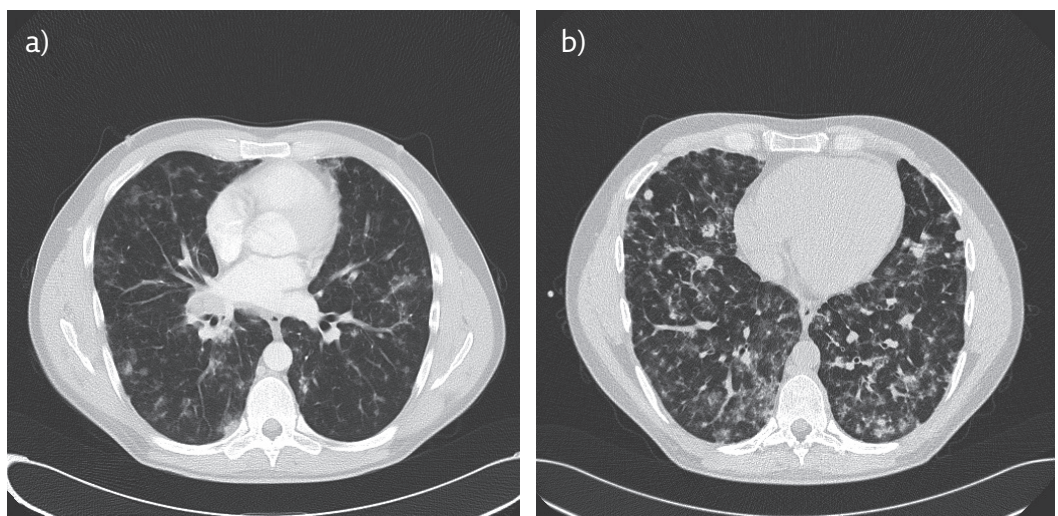


Figure 2 a) Contrast-enhanced chest CT parenchymal window. b) High-resolution CT during inspiration.

Answer 2

c. On the chest CT-scan we see an adenopathy in the right hilus, there are no signs of fibrosis. We see diffuse ground-glass opacities and diffuse subcentrimetric noduli. The two images suggest an apicobasal gradient.

Next to the abdominal adenopathies, subcentrimetric mediastinal lymph nodes were also found. However, the most striking finding was the bilateral pronounced ground-glass opacities together with diffuse parenchymal noduli (± 1 cm). The parenchymal noduli did not follow a lymphatic pattern (*e.g.* close to the fissure), were subcentrimetric, had a smooth margin and a random distribution with basal predominance, making sarcoidosis less likely [1, 2]. There were no signs of fibrosis on this chest CT.

Additional investigations showed a slightly elevated serum angiotensin-converting enzyme (ACE) level ($75 \text{ U}\cdot\text{L}^{-1}$, NR $<50 \text{ U}\cdot\text{L}^{-1}$), serum calcium was normal. Absence of anti-neutrophil cytoplasmic antibodies and anti-nuclear antibodies, together with a normal urinary sediment made vasculitis improbable. Serum IgA ($9 \text{ mg}\cdot\text{dL}^{-1}$, NR $70\text{--}400 \text{ mg}\cdot\text{dL}^{-1}$), IgG ($139 \text{ mg}\cdot\text{dL}^{-1}$, NR $700\text{--}1600 \text{ mg}\cdot\text{dL}^{-1}$) and IgM ($21 \text{ mg}\cdot\text{dL}^{-1}$, NR $40\text{--}230 \text{ mg}\cdot\text{dL}^{-1}$) were markedly lowered. A bronchoscopy was performed with a lymphocytic dominance on alveolar lavage (32%, NR 10–15%). Flow cytometry showed a T-cell dominance (T-lymphocytes 88.5%, B-lymphocytes 11.9%), CD4/CD8-ratio was 1.0.

Microbiological examinations, including cultures for bacteria, tuberculosis or fungi, *Aspergillus* antigen and PCR for *Pneumocystis jirovecii* were negative.

In our view, the differential diagnosis was narrowed to sarcoidosis, primary immunodeficiency or haematological malignancy. Haematologic malignancy was considered among other differential diagnoses because of haemolytic anaemia, hepatosplenomegaly, low IgG and a radiographic presentation of diffuse adenopathies. PET showed diffuse fluorodeoxyglucose (FDG)-avid adenopathies suggesting lymphoma (figure 3).

At this point, we decided to carry out a bone marrow analysis and the excision of a cervical FDG-avid lymph node.

No evidence for a lymphoproliferative malignancy was found. The lymph node excision showed large secondary reactive germinal centres of variable shape and size (so-called reactive follicular hyperplasia). In the subcortical region of the lymph node there were a few sharply delineated granulomas consisting of multinucleated giant cells and epithelioid histiocytes. These granulomas were noncaseating, showed no obvious sclerosis and did not efface the nodal architecture (figure 4).

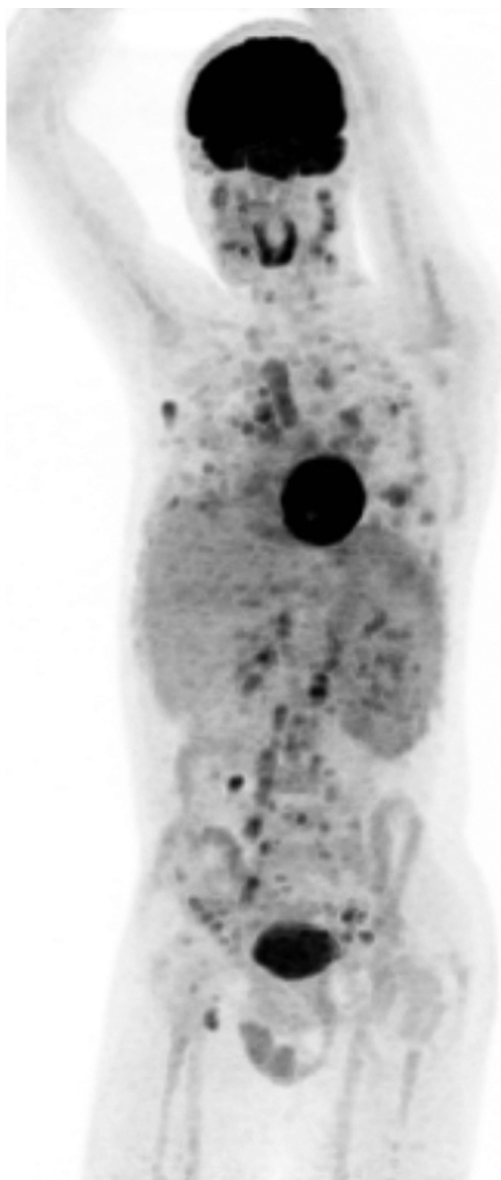


Figure 3 FDG-PET, maximum intensity projection. Diffuse supra- and infra-diaphragmatic distribution of FDG-avid adenopathies with increased captation of the spleen. Diffuse FDG-avid lesions spread in the lung parenchyma.

Task 3: What is the most likely diagnosis?

- Sarcoidosis.
- Common variable immunodeficiency (CVID) with granulomatous and lymphocytic interstitial lung disease (GLILD).
- Hodgkin lymphoma without bone marrow infiltration.
- Lymphocytic interstitial pneumonia due to autoinflammatory disease (*e.g.* Lupus, rheumatoid arthritis).

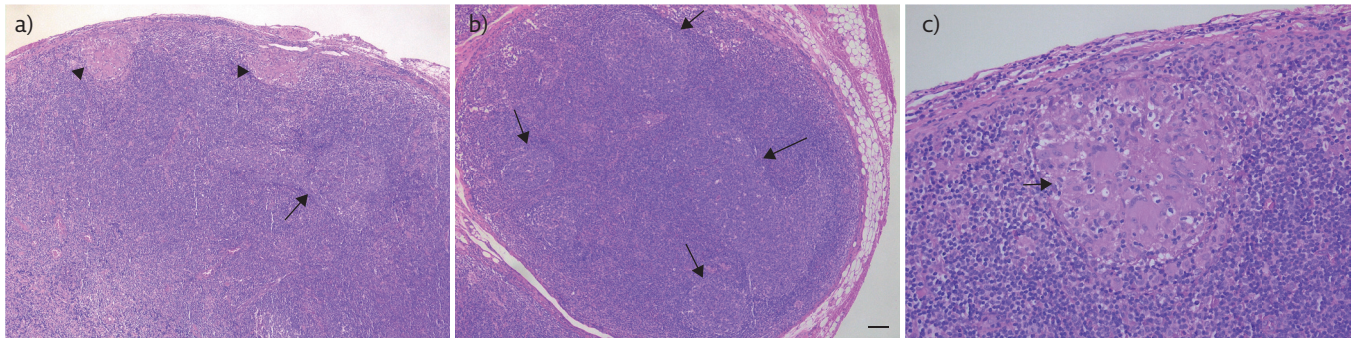


Figure 4 a) Overview of lymph node excision biopsy showing follicular hyperplasia (arrows) and granulomas (arrowheads). b) Detail of multiple, large secondary reactive germ centres of variable shape and size (arrows). Scale bar=100 μ m. c) Detail of the sinus of the lymph node with a sharply delineated granuloma consisting of multinucleated giant cells and histiocytes.

Answer 3

b.

Sarcoidosis would show more prominent noncaseating sclerosing granulomas and normally we expect a normal or increased rather than low IgG level [3–5]. In sarcoidosis haemolytic anaemia and hepatosplenomegaly is also less frequent [6]. In lymphocytic interstitial pneumonia, we would expect to see more cyst-like perivascular lesions and autoimmune disease might be more overt. The lowered immunoglobulin levels, suggestive radiography together with the lymphocytic alveolar lavage and nonmalignant lymphoproliferation were clues towards a diagnosis of CVID, a primary immunodeficiency (PID). The haemolytic anaemia and the disturbed liver function tests could also be attributed to CVID. Raised ACE in CVID has also been described [6]. The diagnosis was confirmed by the absence of switched memory B-cells on B-cell differentiation, aberrant pneumococcal polysaccharide vaccine responses, and absence of a concomitant T-cell deficiency [4].

During follow-up, symptoms of dyspnoea deteriorated and lung function tests declined by up to 10%: forced vital capacity from 5.4 L (108%) to 4.7 L (95%), forced expiratory volume in 1 s from 4.1 L (106%) to 3.8 L (91%), and diffusing capacity from 6.2 mmol \cdot min $^{-1}$ \cdot Kpa $^{-1}$ (69%, percentage of normal corrected for haemoglobin level) towards 7.2 mmol \cdot min $^{-1}$ \cdot Kpa $^{-1}$ (63%, percentage of normal corrected for haemoglobin level). Despite first-line therapy (see later) there was persistent anaemia of 10 g \cdot dL $^{-1}$.

Task 4: What therapy would you start?

- Corticosteroids
- Immunoglobulin substitution therapy (intravenous or subcutaneous)
- Immunoglobulin substitution therapy together with corticosteroids
- Immunoglobulin substitution therapy together with rituximab
- Watchful waiting

Answer 4

c. For CVID, immunoglobulin substitution therapy is mandatory. For a combination of lymphoproliferation, persisting anaemia and lung function decline, additional immunosuppression is warranted, with corticosteroids as first-line therapy.

In our patient CVID was diagnosed and treatment with immunoglobulins initiated. Immune replacement therapy consisted of intravenous immunoglobulins every 3–4 weeks, with a pursued IgG trough level $>7.5 \text{ g}\cdot\text{L}^{-1}$ (which was later increased to $>10 \text{ g}\cdot\text{L}^{-1}$ because of GLILD progression), for which the dose was adapted with a starting dosage of $0.5 \text{ g}\cdot\text{kg}^{-1}$. Because of the haemolytic anaemia and lung function decline attributed to progressive GLILD and systemic lymphoproliferation, additional treatment with corticosteroids ($0.5 \text{ mg}\cdot\text{kg}^{-1}$ prednisone) was prescribed [4, 7].

Discussion

CVID is the most prevalent symptomatic primary antibody deficiency (PAD). Onset can be at any age and diagnosis is often accompanied by an important delay. The cause of CVID is poorly understood and most likely heterogeneous, covering also hereto unidentified monogenic PIDs. Lowered IgG, IgA and/or IgM serum levels in patients aged >4 years are a hallmark of the disease and further evaluation typically shows a poor response to vaccination and/or low switched-memory B-cells [4]. The clinical presentation is characterised by a combination of recurrent infections, autoimmune manifestations (such as autoimmune cytopenia), multisystemic lymphoproliferation (such as lymphadenopathies, hepatosplenomegaly), and/or granulomatous disease. In a subset of patients, a familial history of antibody deficiencies is present. In GLILD, varying forms of liver disease (such as nodular regenerative hyperplasia) can be associated, and an increased risk for lymphoma and cancer is observed [8, 9].

In our patient the immunodeficient state (hypogammaglobulinaemia) was accompanied by lymphoproliferation, haemolytic anaemia, GLILD and biopsy proven nodular regenerative hyperplasia of the liver, indicating immunodysregulation. That is why this disease can be regarded as a double-edged sword or is sometimes compared to the mythological Janus head with two faces, because of the combination of a seemingly paradoxical insufficient and exaggerated immune response. However, autoimmunity (and/or immune dysregulation) is frequently observed in CVID and other PIDs [10]. So, instead of the term common variable immunodeficiency, common variable immunodysregulation would be more appropriate.

In CVID, respiratory disease is an important cause of morbidity and mortality. Recurrent bacterial respiratory infections are common, and lead to a vicious circle that may result in bronchiectasis and a chronic inflammatory response that can lead to airway hyperreactivity and fixed obstruction. CVID-associated interstitial lung disease is challenging and covers a broad spectrum of overlapping histological and radiological patterns (*e.g.* nonspecific interstitial pneumonia, organising pneumonia, granulomatous disease) [7, 8, 11, 12]. This heterogeneity has led to the implementation of the “umbrella” definition of GLILD, which is defined as a distinct clinico-radio-pathological lung disease occurring in patients with CVID, associated with lymphocytic infiltrates and/or granulomas in the lung and in whom other conditions have been considered and where possible excluded. Pathological confirmation was deemed necessary to confirm the diagnosis and to rule out malignancy. For this a surgical lung biopsy is typically suggested [8]. However, in our patient, instead of a surgical lung biopsy, we performed a cervical lymph node excision, guided by the FDG-PET scan result, to support our tentative diagnosis of CVID with GLILD. This approach is less invasive than lung biopsy and provides more histopathological material for confirmation than transbronchial needle aspiration of mediastinal lymph nodes. This approach is possible because GLILD is usually seen in the context of a multisystem granulomatous/lymphoproliferative disease where it is highly associated with autoimmune cytopenias and splenomegaly [8, 11, 13].

B-cell dysregulation, due to B cell-activating factor driven B-cell hyperplasia with formation of tertiary lymphoid structures, is suggested to be a main driving factor in progressive GLILD. This is reflected by higher IgM levels and IgM increases over time, which can identify CVID patients with progressive ILD and is associated with decreased survival [14].

The estimated occurrence of GLILD in CVID patients is one in three, or higher, and is significant because of its association with an increased rate of mortality. Patients who have GLILD have a median survival of 13.7 years, compared with 28.8 years in patients with CVID without ILD [15]. Noteworthy is that the presence of noncaseating granuloma in the lung along with some of the extrapulmonary features of GLILD may lead to an incorrect diagnosis of sarcoidosis. Differentiation between sarcoidosis and GLILD can be guided by chest-CT notwithstanding that both can present with nodules, reticulation, ground glass and adenopathies [1, 6, 16]. In sarcoidosis the nodules are mostly micronodules ($<3 \text{ mm}$) with a lymphatic distribution and upper lobe predominance. In GLILD the nodules are mostly larger, with a random or centrilobular distribution and with a lower lobe predominance. Also, in GLILD the nodules can be surrounded by ground glass, forming a halo sign. Presence of bronchiectasis,

except traction bronchiectasis, or bronchial wall thickening is rarer in sarcoidosis but can suggest CVID-GLILD. Lastly, in sarcoidosis mediastinal and hilar adenopathies are present, whereas in GLILD hilar adenopathies are less frequent. These radiological differences are not absolute and up to now no consensus has been achieved, but together with extrapulmonary manifestations (hepatosplenomegaly, haemolytic anaemia), laboratory features (low levels of immunoglobulins, normal to lowered CD4/CD8) and pathological differences (lymphoid hyperplasia), CVID-GLILD and sarcoidosis can be differentiated. The misdiagnosis of sarcoidosis in a patient with CVID and GLILD can lead to inappropriate treatment and increase the morbidity and mortality of the disorder [1, 6, 8].

Evidence-based treatment guidelines for the treatment of GLILD are lacking, but recently the British Lung Foundation/United Kingdom Primary Immunodeficiency Network released a consensus statement on managing GLILD [8]. First of all, they state that management should be led by a multidisciplinary team including immunologists and chest physicians. Once diagnosis is made, immunoglobulin replacement therapy should be optimised to standard guidelines before initiation of additional GLILD therapy, especially in stable and asymptomatic patients. Because disease progression can occur despite optimal immunoglobulin replacement, additional immunosuppressive therapy should be considered [17]. If patients are symptomatic, present with an abnormal or a still normal but deteriorating lung function, then corticosteroids are suggested as a first-line treatment [8]. However, there is growing evidence on the efficacy of the anti-CD20 monoclonal antibody rituximab in monotherapy as a first-line treatment for CVID-associated GLILD,

due to the B-cell hyperplasia being a main driving factor in GLILD [11, 13, 14, 18]. Extrapulmonary involvement (*e.g.* haemolytic anaemia) may also influence the decision for additional treatment. Second-line treatment, with or without steroids, consists of dual rituximab and azathioprine, and to a lesser extent mycophenolate, or rituximab in monotherapy [7, 8, 13, 19]. Stem cell transplantation has been performed in CVID patients with severe immune dysregulation leading to end-organ failure, of which a vast subgroup had predominant or accessory interstitial lung disease/GLILD. Despite a considerable mortality, all surviving patients had a complete or partial resolution of the condition they were transplanted for, making this a possible third-line option [20].

However, DNA sequencing should also be initiated early on, since what is allegedly termed CVID might in fact mask a monogenic PID (such as CTLA-4 deficiency or activated phosphoinositide 3-kinase delta syndrome) for which other targeted treatment options could be applied [21].

In our patient, panel-based and trio whole exome sequencing did not reveal a clear monogenic PID. After commencing immunoglobulin substitution and corticosteroids a rapid improvement of the anaemia and recovery of lung function occurred. However, the disease relapsed upon steroid tapering with progressive interstitial lung disease (figure 5) with varying lung function deterioration, development of non-cirrhotic portal hypertension and a transverse myelitis. Rituximab and mycophenolate were added, yet despite this treatment, multiple end-organ failure progressed and an allogenic stem cell transplantation (matched unrelated donor) was performed. Unfortunately, the patient succumbed due to grade 4 intestinal graft *versus* host disease, *Enterococcus faecium* sepsis

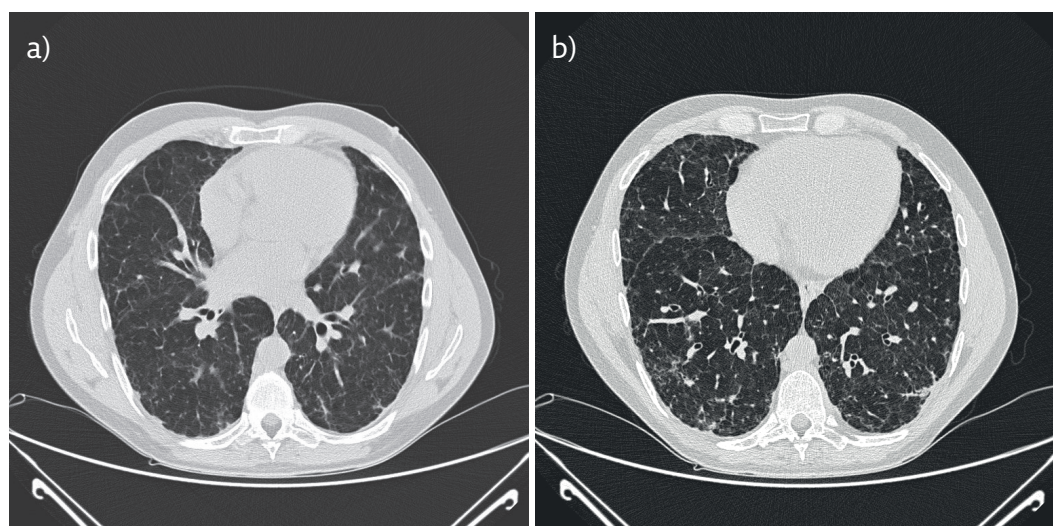


Figure 5 a) High-resolution computed tomography in inspiration during follow-up (interval: 9-years). b) Follow-up CT with disappearance of ground-glass opacities with progression towards a reticular interstitial pattern.

and disseminated Mucormycosis 3 months after the transplantation.

With this case, we want to emphasise that CVID is not only a disease with recurrent infections but has to be considered in pulmonary manifestations with heterogeneous radiological and histological presentations, such as GLILD.

Early recognition and prompt treatment and, in selected cases such as ours, an additional search for rare monogenic causes is necessary to avoid evolution to irreversible end-organ failure. Besides immunoglobulin substitution, the immunoproliferation can be treated with immunosuppressants.

Affiliations

Martijn Vandebotermert¹, Frederik Staels², Simone Giovannozzi², Michel Delforge³, Thomas Tousseyn⁴, Thomas Steelandt⁴, Annie Corveleyn⁵, Isabelle Meyts⁶, Johan Maertens³, Jonas Yserbyt¹, Rik Schrijvers²

¹Respiratory Medicine, University Hospitals Leuven, Leuven, Belgium. ²Dept of Microbiology, Immunology and Transplantation, Allergy and Clinical Immunology Research Group, KU Leuven, Leuven, Belgium. ³Dept of Haematology, University Hospitals Leuven, Leuven, Belgium. ⁴Dept of Pathology, University Hospitals Leuven, Leuven, Belgium. ⁵Center for Human Genetics, University of Leuven, Leuven, Belgium. ⁶Depts of Pediatrics, and Microbiology and Immunology, Laboratory for Inborn Errors of Immunity, KU Leuven, Leuven, Belgium.

Conflict of interest

None declared.

References

- Bouvy D, Mouthon L, Brillet P-Y, *et al*. Granulomatosis-associated common variable immunodeficiency disorder: a case-control study versus sarcoidosis. *Eur Respir J* 2013; 41: 115–122.
- Tanaka N, Kim JS, Bates CA, *et al*. Lung diseases in patients with common variable immunodeficiency: chest radiographic, and computed tomographic findings. *J Comput Assist Tomogr* 2006; 30: 828–838.
- Rosen Y. Pathology of sarcoidosis. *Semin Respir Crit Care Med* 2007; 28: 036–052.
- Bonilla FA, Barlan I, Chapel H, *et al*. International Consensus Document (ICON): Common variable immunodeficiency disorders. *J Allergy Clin Immunol Pract* 2016; 4: 38–59.
- Asano S. Granulomatous lymphadenitis. *J Clin Exp Hematop* 2012; 52: 1–16.
- Verbsky J, Routes J. Sarcoidosis and common variable immunodeficiency: similarities and differences. *Semin Respir Crit Care Med* 2014; 35: 330–335.
- Cinetto F, Scarpa R, Rattazzi M, *et al*. The broad spectrum of lung diseases in primary antibody deficiencies. *Eur Respir Rev* 2018; 27: 180019.
- Hurst JR, Verma N, Lowe D, *et al*. British Lung Foundation/ United Kingdom Primary Immunodeficiency Network Consensus Statement on the definition, diagnosis, and management of granulomatous-lymphocytic interstitial lung disease in common variable immunodeficiency disorders. *J Allergy Clin Immunol Pract* 2017; 5: 938–945.
- Gathmann B, Mahlaoui N, Gérard L, *et al*. Clinical picture and treatment of 2212 patients with common variable immunodeficiency. *J Allergy Clin Immunol* 2014; 134: 116–126.
- Fischer A, Provot J, Jais J-P, *et al*. Autoimmune and inflammatory manifestations occur frequently in patients with primary immunodeficiencies. *J Allergy Clin Immunol* 2017; 140: 1388–1393.
- Ng J, Wright K, Alvarez M, *et al*. Rituximab monotherapy for common variable immune deficiency-associated granulomatous-lymphocytic interstitial lung disease. *Chest* 2019; 155: e117–e121.
- Park JH, Levinson AI. Granulomatous-lymphocytic interstitial lung disease (GLILD) in common variable immunodeficiency (CVID). *Clin Immunol* 2010; 134: 97–103.
- Pecoraro A, Crescenzi L, Galdiero MR, *et al*. Immunosuppressive therapy with rituximab in common variable immunodeficiency. *Clin Mol Allergy* 2019; 17: 9.
- Maglione PJ, Gyimesi G, Cols M, *et al*. BAFF-driven B cell hyperplasia underlies lung disease in common variable immunodeficiency. *JCI Insight* 2019; 4: e122728.
- Bates CA, Ellison MC, Lynch DA, *et al*. Granulomatous-lymphocytic lung disease shortens survival in common variable immunodeficiency. *J Allergy Clin Immunol* 2004; 114: 415–421.
- Park JES, Beal I, Dilworth JP, *et al*. The HRCT appearances of granulomatous pulmonary disease in common variable immune deficiency. *Eur J Radiol* 2005; 54: 359–364.
- Stubbs A, Bangs C, Shillitoe B, *et al*. Bronchiectasis and deteriorating lung function in agammaglobulinaemia despite immunoglobulin replacement therapy: Progressive lung disease in agammaglobulinaemia. *Clin Exp Immunol* 2018; 191: 212–219.
- Tessarin G, Bondioni M, Rossi S, *et al*. Rituximab as a single agent for granulomatous lymphocytic interstitial lung disease in common variable immune deficiency. *J Invest Allergol Clin Immunol* 2019; 29: 470–471.
- Chase NM, Verbsky JW, Hintermeyer MK, *et al*. Use of combination chemotherapy for treatment of granulomatous and lymphocytic interstitial lung disease (GLILD) in patients with common variable immunodeficiency (CVID). *J Clin Immunol* 2013; 33: 30–39.
- Wehr C, Gennery AR, Lindemans C, *et al*. Multicenter experience in hematopoietic stem cell transplantation for serious complications of common variable immunodeficiency. *J Allergy Clin Immunol* 2015; 135: 988–997.
- de Valles-Ibáñez G, Esteve-Solé A, Piquer M, *et al*. Evaluating the genetics of common variable immunodeficiency: monogenetic model and beyond. *Front Immunol* 2018; 9: 636.