



REVIEW

Recent advances in pathogenesis, assessment, and treatment of atherosclerosis [version 1; referees: 3 approved]

J. David Spence

Stroke Prevention & Atherosclerosis Research Centre, Robarts Research Institute, Western University, London, ON, Canada

v1 First published: 28 Jul 2016, 5(F1000 Faculty Rev):1880 (doi: 10.12688/f1000research.8459.1)

Latest published: 28 Jul 2016, 5(F1000 Faculty Rev):1880 (doi: 10.12688/f1000research.8459.1)

Abstract

In recent years, there have been a number of advances in the pathogenesis and treatment of atherosclerosis and in assessing prognosis in carotid atherosclerosis. Risk stratification to improve vascular prevention by identifying patients most likely to benefit from intensive therapy is much improved by measuring carotid plaque burden. In patients with asymptomatic carotid stenosis, a number of modalities can be used to identify the 10-15% who could benefit from endarterectomy or stenting. Transcranial Doppler embolus detection, echolucency and ulceration on 3D ultrasound, intraplaque hemorrhage on magnetic resonance imaging (MRI), and reduced cerebrovascular reserve are useful already; new approaches including plaque texture on ultrasound and imaging of plaque inflammation and early calcification on positron emission tomography/computed tomography (PET/CT) are in development. The discovery that the intestinal microbiome produces vasculotoxic metabolites from dietary constituents such as carnitine in meat (particularly red meat) and phosphatidylcholine from egg yolk and other sources has revolutionized nutritional aspects of vascular prevention. Because many of these vasculotoxic metabolites are removed by the kidney, it is particularly important in patients with renal failure to limit their intake of red meat and egg yolk. A new approach to lowering low-density lipoprotein (LDL) cholesterol by blocking the action of an enzyme that destroys LDL receptors promises to revolutionize vascular prevention once less costly treatments are developed, and a new approach to vascular prevention—"treating arteries instead of risk factors"—shows promise but requires randomized trials. These advances all promise to help in the quest to prevent strokes in high-risk patients.

Open Peer Review

Referee Status:

	Invited Referees		
	1	2	3
version 1 published 28 Jul 2016			

F1000 Faculty Reviews are commissioned from members of the prestigious F1000 Faculty. In order to make these reviews as comprehensive and accessible as possible, peer review takes place before publication; the referees are listed below, but their reports are not formally published.

- 1 **Conrado Estol**, Heart and Brain Medicine Argentina
- 2 **Tasneem Naqvi**, Mayo Clinic USA
- 3 **Tanja Rundek**, University of Miami USA

Discuss this article

Comments (0)

Corresponding author: J. David Spence (dspence@robarts.ca)

How to cite this article: Spence JD. **Recent advances in pathogenesis, assessment, and treatment of atherosclerosis [version 1; referees: 3 approved]** *F1000Research* 2016, 5(F1000 Faculty Rev):1880 (doi: [10.12688/f1000research.8459.1](https://doi.org/10.12688/f1000research.8459.1))

Copyright: © 2016 Spence JD. This is an open access article distributed under the terms of the [Creative Commons Attribution Licence](https://creativecommons.org/licenses/by/4.0/), which permits unrestricted use, distribution, and reproduction in any medium, provided the original work is properly cited.

Grant information: The author(s) declared that no grants were involved in supporting this work.

Competing interests: J. David Spence In the past 2 years has received lecture honoraria/consulting fees from Bayer and Bristol Myers Squibb and has performed contract research with Pfizer, Bayer, Bristol Myers Squibb, Acasti Pharma, POM Wonderful, CVRx, AGA Medical, and Gore. He is an officer and shareholder of Vascularis Inc., a company seeking to market software for vascular risk reclassification based on measurement of carotid plaque burden.

First published: 28 Jul 2016, 5(F1000 Faculty Rev):1880 (doi: [10.12688/f1000research.8459.1](https://doi.org/10.12688/f1000research.8459.1))

Introduction

In recent years, there have been important advances in the pathogenesis and treatment of atherosclerosis and in assessing prognosis in carotid atherosclerosis. The effect of the intestinal microbiome on atherosclerosis has revolutionized thinking about diet¹ and about the role of renal failure in increasing cardiovascular risk. In the past, routine treatment with usual therapy for atherosclerosis has reduced cardiovascular risk in most trials by only ~9–30%², resulting in a residual risk of 70–80%^{3–6}. Recent advances in lipid-lowering therapy, based on a novel mechanism based on blocking the effects of an enzyme that destroys receptors for low-density lipoprotein (LDL) cholesterol, make it possible to lower LDL to a greater degree and in more patients than was previously possible⁷. Lifelong reduction of LDL resulting from a hereditary cause of low levels of LDL results in a reduction of coronary risk by ~95%^{8,9}, and a new approach to therapy based on “treating arteries instead of treating risk factors”¹⁰ reduced the very high risk in patients with asymptomatic carotid stenosis by more than 80%¹¹. Most patients (~90%) with asymptomatic carotid stenosis would be better treated by intensive medical therapy than by carotid endarterectomy (CEA) or carotid artery stenting (CAS)¹². Methods to identify the few (10–15%) who could benefit from intervention are being developed¹³. In this review, I focus on advances in the understanding of the role of the intestinal microbiome and renal impairment on atherosclerosis, measurement of carotid plaque burden, carotid ulceration and ulcer volume, plaque texture, and detection of microemboli by transcranial Doppler (TCD).

Advances in pathogenesis of atherosclerosis

Atherosclerosis may be thought of as a response to injury^{14–16}, related to flow disturbances that injure the endothelium¹⁷, followed by adhesion of platelets, penetration of macrophages into the subendothelium, inflammation¹⁸, oxidative stress, LDL oxidation, and proliferation of smooth muscle cells, similar to a scar in the artery wall. Risk factors identified in the Framingham Heart Study included hypertension, smoking, elevated LDL, diabetes, and left ventricular hypertrophy (essentially reflecting the integral of blood pressure over recent years). The importance of diet has been largely unappreciated, perhaps because lowering of fasting LDL with drugs such as statins has seemingly countered any effect of diet on fasting lipids. However, this misplaced focus on fasting lipids misses the key effects of diet, which occur during the post-prandial state¹⁹. A high-fat/high-cholesterol meal increases arterial inflammation^{20,21} and oxidative stress, and impairs endothelial function²², for several hours. Most of the day is spent in the post-prandial state, so diet is much more important than would be predicted by fasting LDL.

Several studies have shown that healthy lifestyle choices (not smoking, moderate alcohol intake, regular exercise, consuming a healthy diet, and maintaining a healthy weight) markedly reduce the risk of stroke. In the US Health Professionals Study and the Nurses’ Health study, persons who adopted all of these choices had an 80% reduction of stroke²³; Swedish men with coronary artery disease who did so also had an 80% reduction of recurrent myocardial infarction²⁴. The Cretan Mediterranean diet reduced cardiovascular events by 70% in secondary prevention²⁵ and reduced stroke by nearly half in high-risk primary prevention²⁶. It has been clear for many years that dietary cholesterol increases coronary risk²⁷.

Now there is a completely new window opening on the relationship between diet and atherosclerosis, relating to the intestinal microbiome¹.

Intestinal microbiome and diet

In recent years, it has become clear that an important interaction between diet and the intestinal microbiome brings into play additional metabolic factors that aggravate atherosclerosis beyond dietary cholesterol. This may help to explain the benefits of the Mediterranean diet. Hazen’s group from the Cleveland Clinic reported that phosphatidylcholine from egg yolk²⁸ and carnitine²⁹ from animal flesh (four times as much in red meat as in fish or chicken) are converted by intestinal bacteria to trimethylamine (the compound that causes uremic breath to smell fishy). Trimethylamine is oxidized in the liver to trimethylamine N-oxide (TMAO) (Figure 1), which causes atherosclerosis in animal models. In patients referred for coronary angiography, high levels of TMAO following a test dose of two hard-boiled eggs markedly increased risk. Patients in the top quartile of TMAO had a 2.5-fold increase in the 3-year risk of stroke, death, or myocardial infarction³⁰.

A key issue is that vegans who consumed L-carnitine did not produce TMAO because they did not have the intestinal bacteria that produce TMA from carnitine²⁹; this means that the intestinal microbiome is modifiable. A novel approach to treating atherosclerosis would be the eradication of harmful bacteria with antibiotics and recolonization by stool transplantation with beneficial bacteria. This is entirely analogous to the treatment of *Clostridium difficile* infection by “repopulation”³¹. Our group is studying that possibility.

Interaction with renal failure

Patients with renal failure have high levels of total homocysteine (tHcy), but this accounts for only ~20% of the effect of impaired renal function on carotid plaque³². Elevated levels of thiocyanate and asymmetric dimethylarginine (a nitric oxide antagonist) add further to the very high cardiovascular risk^{33,34} in renal failure; this is not new. What is recently recognized is that metabolic products of the intestinal microbiome are excreted in the urine, so patients with renal failure also have high levels of TMAO, which accelerate the decline of renal function and increase cardiovascular risk³⁵. Besides TMAO, other metabolic products of the intestinal microbiome that probably contribute to cardiovascular risk in renal failure include indoxyl sulfate, indole-3-acetic acid, p-cresyl sulfate³², and phenylacetylglutamine³⁶. Thus patients at risk of cardiovascular disease should limit their intake of meat and egg yolk not only because of the high cholesterol content but also because of the carnitine in meat (particularly red meat) and the phosphatidylcholine in egg yolk. This is particularly important in patients with renal failure.

Advances in treatment of atherosclerosis

Blocking the action of proprotein convertase subtilisin-kexin type 9

Inhibitors of the rate-limiting step in cholesterol synthesis, hydroxymethylglutarate CoA (HMG-CoA) reductase (statins), reduce fasting LDL and reduce cardiovascular events. Those effects are enhanced by combination with ezetimibe, a drug that blocks cholesterol absorption. However, many patients are intolerant of statins. Although there are many myths³⁷ regarding the adverse effects of statins, such as hepatotoxicity, nephrotoxicity,

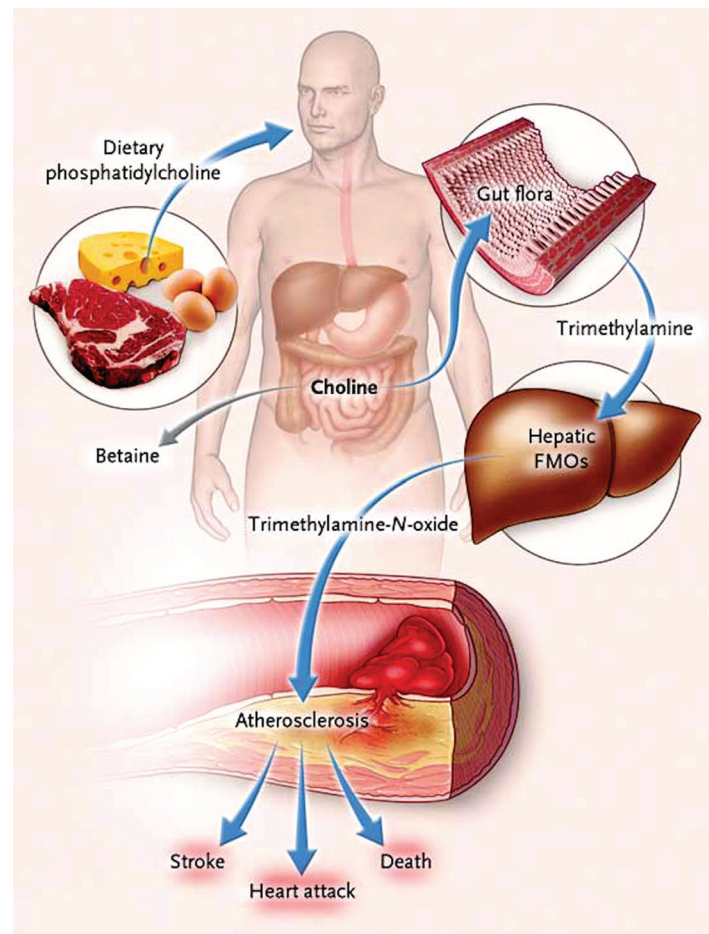


Figure 1. Pathways linking dietary phosphatidylcholine, intestinal microbiota, and incident adverse cardiovascular events. Ingested phosphatidylcholine (lecithin), the major dietary source of total choline, is acted on by intestinal lipases to form a variety of metabolic products, including the choline-containing nutrients glycerophosphocholine, phosphocholine, and choline. Choline-containing nutrients that reach the cecum and large bowel may serve as fuel for intestinal microbiota (gut flora), producing trimethylamine (TMA). TMA is rapidly further oxidized to trimethylamine N-oxide (TMAO) by hepatic flavin-containing monooxygenases (FMOs). TMAO enhances the accumulation of cholesterol in macrophages, the accumulation of foam cells in artery walls, and atherosclerosis, all factors that are associated with an increased risk of heart attack, stroke, and death. Choline can also be oxidized to betaine in both the liver and the kidneys. Dietary betaine can serve as a substrate for bacteria to form TMA and presumably TMAO. Reproduced by permission of the Massachusetts Medical Society from: Tang WHW, Wang Z, Levison BS, Koeth RA, Britt EB, Fu X, Wu Y, Hazen SL: Intestinal Microbial Metabolism of Phosphatidylcholine and Cardiovascular Risk. *N Engl J Med* 2013, 368(17): 1575–1584.

intracerebral hemorrhage, cataracts, and cognitive decline, true causally related adverse effects include myopathy and a slightly increased risk of diabetes. These probably depend mainly on impairment of mitochondrial function³⁷ by depletion of ubiquinone (coenzyme Q10), which is needed for mitochondrial function.

An entirely distinct approach to lowering LDL and reducing cardiovascular events that has recently become available is blocking the action of proprotein convertase subtilisin-kexin type 9 (PCSK9), an enzyme that breaks down LDL receptors. By preventing the breakdown of these receptors, and increasing their number and duration of effect, LDL and cardiovascular events are both lowered by ~50%^{38,39}. Present approaches to blocking the action of

PCSK9—monoclonal antibodies or RNA interference—are very (prohibitively) costly⁴⁰, but it is to be hoped that far less costly small molecules to achieve this end will be developed before long.

Treating arteries instead of treating risk factors

A different approach to reducing residual risk is to treat the actual burden of atherosclerosis⁴¹ instead of treating intermediate targets—risk factors such as level of blood pressure or LDL¹⁰. This paradigm was developed in response to the recognition that treating patients according to then current guidelines was failing half our patients: they had plaque progression, and their risk was twice that of patients with stable plaque or plaque regression, after controlling for coronary risk factors⁴². This approach, initiated

by our group in 2003, was found in 2010¹¹ to halve the proportion of patients with plaque progression (to a quarter), double the proportion of patients with regression of plaque (to half)¹⁰, reduce microemboli on TCD by three quarters, and reduce the very high risk of patients with asymptomatic carotid stenosis by over 80%¹¹: the 2-year risk of stroke fell from 8.8% to 1% and the 2-year risk of myocardial infarction from 7.6% to 1%. Efforts are underway to conduct randomized trials of usual care versus “treating arteries” using measurement of 3D plaque volume (Figure 2), the most sensitive method available to assess the effects of therapies on atherosclerosis^{43,44}.

Assessing prognosis in carotid atherosclerosis

Although it has been reasonably clear that patients with severe symptomatic carotid stenosis benefit from CEA or CAS, the periprocedural risk of stroke or death with CAS is approximately twice that with CEA. However, the risk of asymptomatic carotid stenosis with modern medical therapy has declined markedly in recent

years to ~0.5% per year^{11,45,46}, so it has even been suggested⁴⁷ that randomized trials in *symptomatic* stenosis should be repeated comparing intervention with intensive medical therapy. There is a major unwarranted controversy regarding the treatment of asymptomatic carotid stenosis. In the United States, ~90% of carotid intervention is for asymptomatic stenosis, even though 90% of patients would be better treated with intensive medical therapy¹². This is being justified by an invalid extrapolation from the medical risks in randomized trials conducted decades ago to modern risks with CEA and CAS. Although the most recent trials report that the risk of stroke or death after first deducting periprocedural risk is similar to that with modern intensive medical therapy (~0.5% per year), the risk with intervention is still much higher than the risk with medical therapy once the periprocedural risks are taken into account: ~3% with CAS and 1.5% with CEA. Furthermore, there are important caveats regarding the higher risk in real-world practice as opposed to the risks with carefully vetted interventionalists in randomized trials^{48,49}. There are huge discrepancies across the world in the

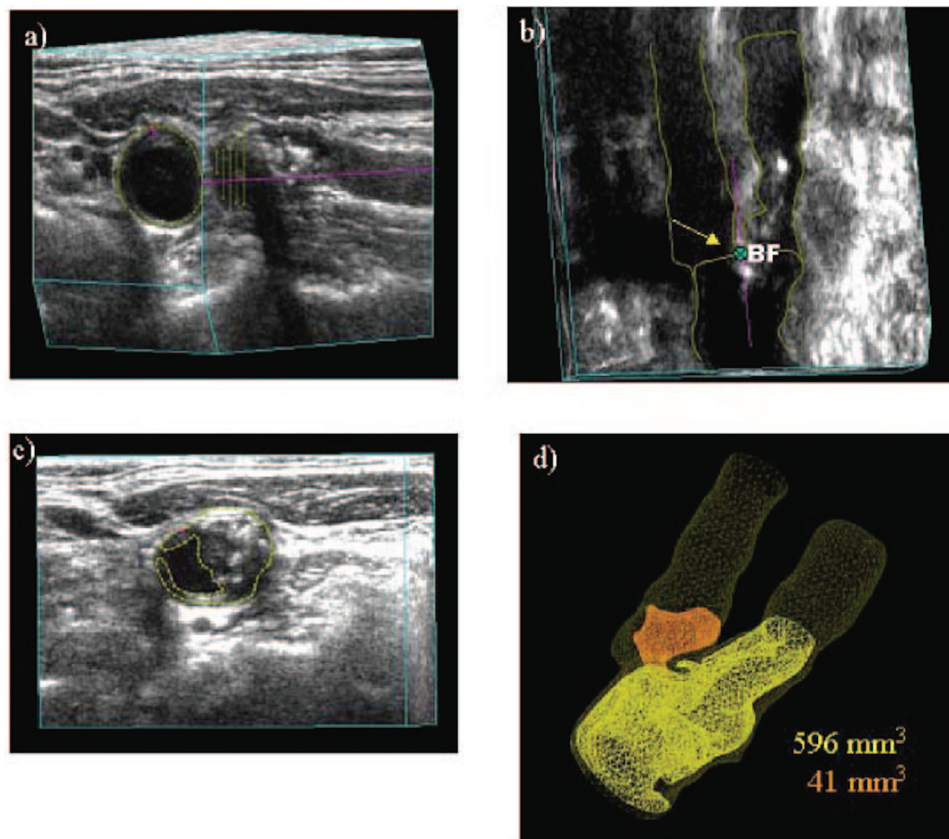


Figure 2. Procedure for determining plaque volumes from 3D ultrasound images. **a)** An approximate axis of the vessel is selected in a longitudinal view (colored line) and the internal elastic lamina and lumen boundary are outlined (yellow). **b)** Using the surfaces generated by the vessel contours and the 3D ultrasound image, the position of the bifurcation (BF; yellow arrow) is determined and marked. The axis of the vessel is selected based on the bifurcation point and marked along the branch as far as the plaque can be measured (colored line). This axis will be used as a reference for distance measurements. **c)** All plaques within the measurable distance are outlined, different colors being used for each separate plaque to aid in identification. **d)** Volumes are calculated for each plaque, and surfaces of the vessel wall and plaques are generated to better visualize the plaques in relation to the carotid arteries. Reproduced by permission of Wolters Kluwer from: Ainsworth CD, Blake CC, Tamayo A, Beletsky V, Fenster A, Spence JD: 3D ultrasound measurement of change in carotid plaque volume: a tool for rapid evaluation of new therapies. *Stroke* 2005, 36(9): 1904–1909.

proportion of carotid interventions performed for asymptomatic stenosis: 90% in the US, ~60% in Italy and Germany, ~15% in Canada and Australia (about right), and 0% in Denmark. These discrepancies call into question not only the advisability but also the ethics of routine intervention for asymptomatic stenosis, as practiced in the United States. The reasons for this practice do not bear scrutiny^{50,51}.

Approximately 10–15% of patients with asymptomatic stenosis could benefit from intervention, and fortunately there are methods available to identify them. Reduced cerebrovascular blood flow reserve is one approach that appears to be promising. In development are a number of other approaches based on imaging of vulnerable plaque, including intraplaque hemorrhage on magnetic resonance imaging (MRI) scans, neovascularity of plaques with contrast ultrasound, and plaque inflammation on positron emission tomography/computed tomography (PET/CT) scans¹³. Here, I will focus on the uses of ultrasound in assessing prognosis in patients with carotid atherosclerosis.

Measuring carotid plaque burden

Although widely regarded as “preclinical atherosclerosis”, carotid intima-media thickness (IMT) is a different phenotype. This issue is complicated by two different approaches to the measurement of IMT—with and without plaque thickness—the latter being a one-dimensional measurement of plaque in those participants with plaque). Then in studies in which plaque thickness is included, participants with and without plaque thickness are combined, conflating the issue⁵². It is increasingly clear that measuring carotid plaque burden is superior to measuring IMT, both for risk stratification and for assessment of effects of therapy⁵³. Plaque burden can be measured as total plaque area (TPA)⁴² (the sum of the areas of all plaques seen in the extracranial carotid arteries) or total plaque volume (TPV)⁵⁴. In the High Risk Plaque study, 3D plaque burden was highly correlated with coronary calcium, whereas IMT was not⁵⁵, and plaque burden predicted risk of cardiovascular events to a similar extent as coronary calcium⁵⁶. Often plaque volume is measured not as TPV but as the volume over a defined segment of the carotids, limited to a defined distance above and below the bifurcation. This approach has advantages for such purposes as assessing effects of therapy (simplicity, potential for automatic measurement) but may lose dynamic range, a potential issue with regard to prognostic value. Besides the issue of IMT not truly representing atherosclerosis, a key reason why IMT is a weak predictor of cardiovascular risk⁵⁷ is its narrow dynamic range: ~0.5 to 1.5 mm. The dynamic range of TPA is much greater—from 0 to ~1200 mm²; the range of TPV would be even greater. After adjustment for age, sex, blood pressure, smoking, serum cholesterol, diabetes, homocysteine, and treatment of blood pressure and cholesterol, TPA strongly predicted risk among patients attending a vascular prevention clinic: the 5-year risk of stroke, death, or myocardial infarction, by quartile of TPA, was 5.6%, 10.7%, 13.9%, and 19.5%. Plaque progression also increased risk; patients with plaque progression in the first year of follow up had twice the risk of those with stable plaque or plaque regression. These findings were substantiated in a population-based study in Tromsø, Norway^{58,59}. Myocardial infarction and stroke were both strongly predicted by TPA but not by IMT in the common carotid where there was no plaque. The annual change in IMT is too small in relation to the resolution of the method to permit measurement in time frames

that are clinically meaningful: the annual change is ~0.15 mm, and the resolution of the method is ~0.2–0.3 mm. A much more useful measurement in persons who do not have plaque would be to measure vessel wall volume (Figure 3)⁶⁰; this parameter amounts to a 3D measurement of the intima-media, has a much greater dynamic range, and unlike IMT, is sensitive to effects of therapy^{61,62}. Progression of IMT does not predict risk⁶³, even in large populations, whereas progression of 3D plaque volume predicted cardiovascular events in a small population of patients in our study⁶⁴.

Transcranial Doppler embolus detection

Perhaps the best validated method for identifying high-risk patients with asymptomatic carotid stenosis is TCD embolus detection^{12,65}. Figure 4 shows a microembolus in a patient with asymptomatic stenosis. Patients with asymptomatic carotid stenosis who had two or more microemboli in 1 hour of monitoring had a 1-year risk of stroke of 15.6%, indicating that they could benefit from CEA or CAS. The cost of a TCD machine is less than the cost of two CAS, and training and certification in TCD embolus detection can

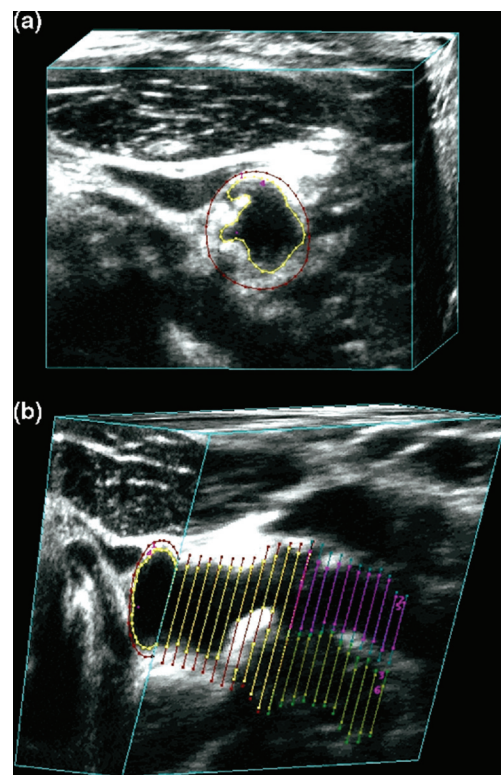


Figure 3. Vessel wall volume. Vessel wall volume segmentation. (a) The transverse view of the common carotid artery shows the vessel boundary outlined in red and the lumen boundary outlined in yellow. (b) The 3D ultrasound image volume is sliced longitudinally to reveal the vessel and lumen boundaries in the common, internal, and external carotid branches. The internal carotid artery vessel and lumen boundaries are shown in blue and pink, respectively. Reproduced by permission of Elsevier from: Egger M, Spence JD, Fenster A, Parraga G: Validation of 3d ultrasound vessel wall volume: an imaging phenotype of carotid atherosclerosis. *Ultrasound Med Biol* 2007, 33(6): 905–914.

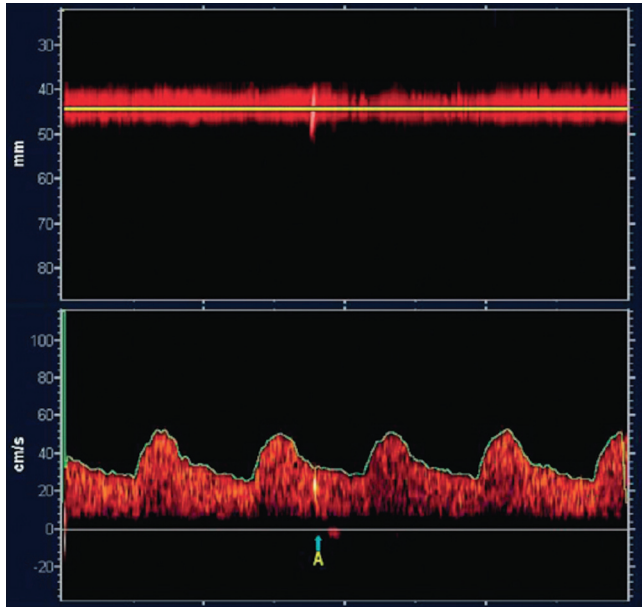


Figure 4. Transcranial Doppler embolus detection. Microembolus in a patient with asymptomatic carotid stenosis. The upper channel is an M-mode image of an embolus in the middle cerebral artery; the lower panel shows the high-intensity transit signal in the Doppler channel. Besides the visual appearance of the microembolus, a characteristic clicking sound is heard. Reproduced by permission of the Society for Vascular Ultrasound from: Spence JD. Transcranial Doppler: uses in stroke prevention. *The Journal for Vascular Ultrasound* 2015, 39(4): 183–187.

be obtained in a course of 3 or fewer days. Thus TCD embolus detection or some other procedure to identify the patient as being at a higher risk than that with intervention should be considered before patients undergo CAS or CEA for asymptomatic stenosis.

Plaque characteristics and prediction of risk

In patients with asymptomatic carotid stenosis, the presence of three or more ulcers in either or both carotid arteries carried a similar risk as the presence of microemboli: an 18% 3-year risk of stroke or death. Those with two or more microemboli had a 20% 3-year risk⁶⁶. By combining TCD embolus detection and detection of three or more ulcers, the proportion of patients with asymptomatic stenosis who could benefit from intervention was increased from 5% to 10%. In the Asymptomatic Carotid Emboli Study (ACES)⁶⁷, plaque echolucency at baseline increased the risk of ipsilateral stroke (hazard ratio [HR] 6.43, 95% confidence interval [CI] 1.36–30.44, P=0.019). A combination of plaque echolucency and presence of TCD microemboli markedly increased the risk of ipsilateral stroke (HR 10.61, 95% CI 2.98–37.82, P=0.0003). This association remained significant after controlling for risk factors, degree of carotid stenosis, and antiplatelet medication. Juxtaluminal black plaque (plaque or thrombus that is so echolucent that it can be seen only by observing a gap between the wall and the Doppler flow signal)⁶⁸, plaque echolucency, and plaque texture analysis of ultrasound⁶⁹ identified higher risk.

Even in patients without carotid stenosis, plaque characteristics predict cardiovascular risk. In a relatively small sample (349) of patients attending a vascular prevention clinic, followed for 5 years, the volume of ulcers (Figure 5) predicted risk of cardiovascular

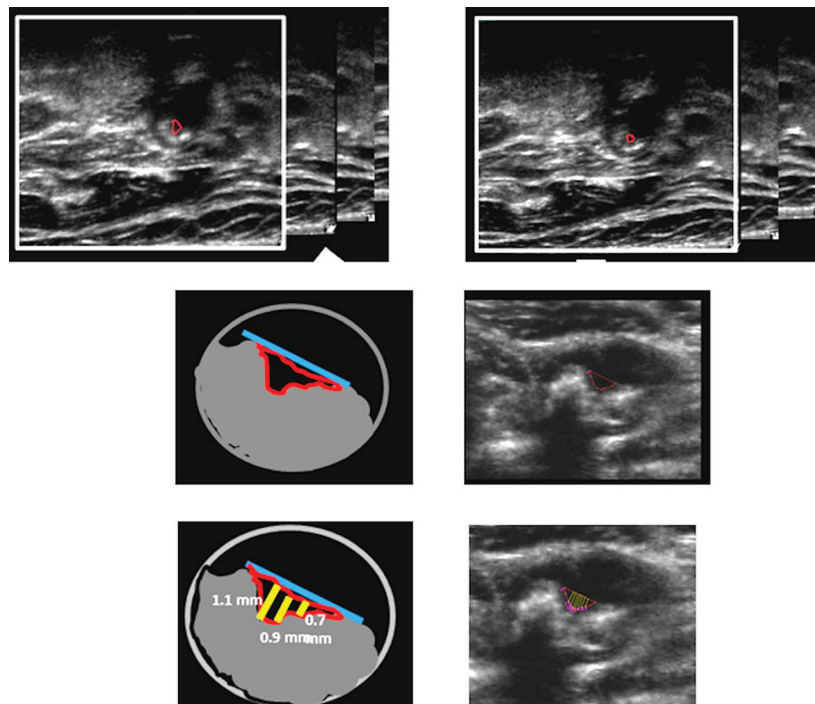


Figure 5. Carotid ulcer volume. Measurement of ulcer volume and ulcer depth. Contours of ulcers were traced and depth of ulcers measured in cross-sectional views. Each slice had a thickness of 1 mm; ulcer volume was computed from the sum of the volumes of all slices in which ulceration was traced. Reproduced by permission of Wolters Kluwer from: Kuk M, Wannarong T, Beletsky V, Parraga G, Fenster A, Spence JD: Volume of carotid artery ulceration as a predictor of cardiovascular events. *Stroke* 2014, 45(5): 1437–1441.

events⁷⁰. Patients with a total ulcer volume $\geq 5 \text{ mm}^3$ experienced a significantly higher risk of stroke, transient ischemic attack, or death ($P=0.009$) and of stroke/transient ischemic attack/death/myocardial infarction/revascularization ($P=0.017$). In the same patient population, elements of plaque texture identified from radiofrequency signals in ultrasound (Figure 6) predicted cardiovascular risk⁷¹.

Intraplaque hemorrhage on MRI⁷²⁻⁷⁴ appears promising as a method for identifying high-risk asymptomatic stenosis, as does imaging of plaque inflammation on PET/CT with fluorodeoxyglucose⁷⁵ and imaging of active calcification with sodium fluoride⁷⁶ (Figure 7). It seems likely that by combining several imaging modalities, the proportion of patients with asymptomatic stenosis who could be identified as being at high enough risk to warrant intervention might

be increased to ~15%. Just as it is inappropriate to perform CAS or CEA in all patients with asymptomatic stenosis, it is also inappropriate to intervene in none: ~10% of strokes are from carotid stenosis, and most patients were asymptomatic before the event. Modalities to identify the few who could benefit from intervention should be in more widespread use; indeed no patient with asymptomatic stenosis should be subjected to intervention without first being identified as being at a high enough risk of ipsilateral stroke to benefit from intervention.

Conclusion

Atherosclerosis is a complex process. Diet is much more important than most physicians suppose, and the intestinal microbiome has major effects on metabolic products derived from dietary constituents

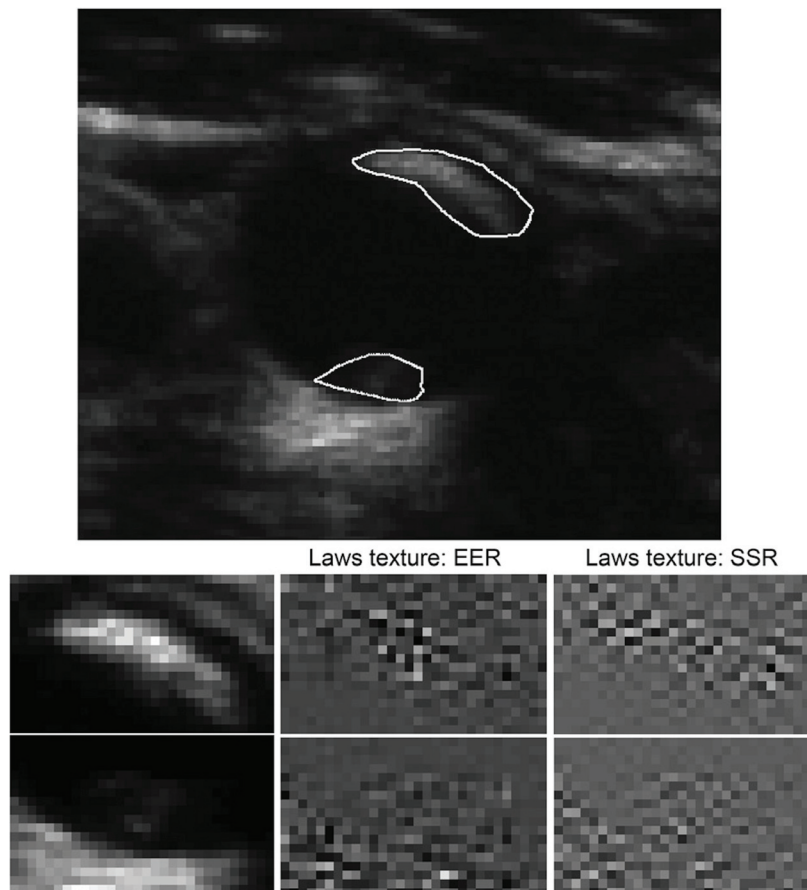


Figure 6. Carotid plaque texture. Texture for two plaques in the same vessel with a different appearance. In a total of 50 runs of sparse Cox regression (5× 10-fold cross-validation) on changes in texture, Laws edge-edge-ripple (EER) was selected in the model 49 times, and Laws spot-spot-ripple (SSR) 48 times. Reproduced by permission of Wolters Kluwer from: van Engelen A, Wannarong T, Parraga G, Niessen WJ, Fenster A, Spence JD, de Bruijne M: Three-dimensional carotid ultrasound plaque texture predicts vascular events. *Stroke* 2014, 45(9): 2695–2701.

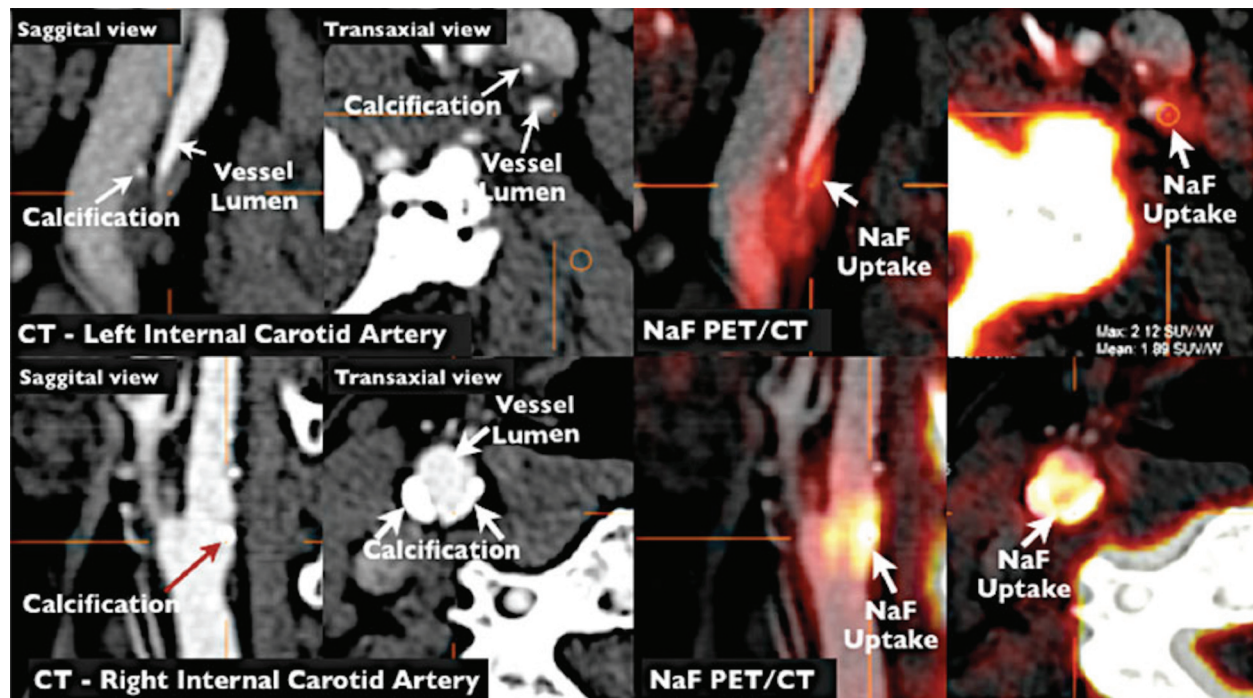


Figure 7. Imaging of vulnerable plaque by positron emission tomography/computed tomography (PET/CT). NaF PET/CT imaging of left and right internal carotid arteries of active calcification in a 72-year-old symptomatic patient evaluated at the University of Ottawa Heart Institute. Upper row: evidence of NaF uptake with small foci of calcification on CT in the left internal carotid symptomatic culprit vessel. There is a mismatch between the region of NaF uptake and calcification on CT. Lower row: evidence of calcium nodules with matched NaF uptake at the right internal carotid artery. Reproduced by permission of Springer from: Cocker MS, Mc Ardle AB, Spence JD, Lum C, Hammond RR, Ongaro DC, McDonald MA, Dekemp RA, Tardif JC, Beanlands RS: Imaging atherosclerosis with hybrid [18F]fluorodeoxyglucose positron emission tomography/computed tomography imaging: what Leonardo da Vinci could not see. *J Nucl Cardiol* 2012, 19(6): 1211–1225.

such as carnitine from meat and phosphatidylcholine from egg yolk. Avoidance of red meat and egg yolk is particularly important in patients with impaired renal function. New approaches to lowering LDL by blocking the effect of PCSK9, and a strategy of treating atherosclerosis directly instead of focusing on intermediate targets, show promise of reducing the residual risk that remains after current therapy. Most patients with asymptomatic carotid stenosis would be better treated with intensive medical therapy than with CEA or CAS. Microemboli on TCD, impaired cerebral blood flow reserve, juxtaluminal black plaque, echolucency, intraplaque hemorrhage on MRI, and ulceration on 3D ultrasound are ways to identify the 10–15% of patients with asymptomatic carotid stenosis who are at sufficiently high risk to benefit from intervention. Other approaches such as plaque texture on ultrasound and PET/CT imaging of inflamed plaque and early calcification will in future provide further evidence of their contribution to identifying high-risk asymptomatic carotid stenosis.

Abbreviations

CAS, carotid artery stenting; CEA, carotid endarterectomy; CI, confidence interval; HMG CoA, hydroxymethylglutarate CoA;

HR, hazard ratio; IMT, intima-media thickness; LDL, low-density lipoprotein; MRI, magnetic resonance imaging; PCSK9, proprotein convertase subtilisin-kexin type 9; PET/CT, positron emission tomography/computed tomography; TCD, transcranial Doppler; TMAO, trimethylamine N-oxide; TPA, total plaque area; TPV, total plaque volume.

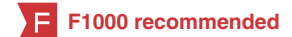Competing interests

J. David Spence In the past 2 years has received lecture honoraria/consulting fees from Bayer and Bristol Myers Squibb and has performed contract research with Pfizer, Bayer, Bristol Myers Squibb, Acaci Pharma, POM Wonderful, CVRx, AGA Medical, and Gore. He is an officer and shareholder of Vascularis Inc., a company seeking to market software for vascular risk reclassification based on measurement of carotid plaque burden.

Grant information

The author(s) declared that no grants were involved in supporting this work.

References



1. Spence JD: **Effects of the intestinal microbiome on constituents of red meat and egg yolks: a new window opens on nutrition and cardiovascular disease.** *Can J Cardiol.* 2014; **30**(2): 150–1.
[PubMed Abstract](#) | [Publisher Full Text](#)
2. Fox KM: **EUROpean trial On reduction of cardiac events with Perindopril in stable coronary Artery disease Investigators: Efficacy of perindopril in reduction of cardiovascular events among patients with stable coronary artery disease: randomised, double-blind, placebo-controlled, multicentre trial (the EUROPA study).** *Lancet.* 2003; **362**(9386): 782–8.
[PubMed Abstract](#) | [Publisher Full Text](#)
3. Heart Protection Study Collaborative Group: **MRC/BHF Heart Protection Study of cholesterol lowering with simvastatin in 20,536 high-risk individuals: a randomised placebo-controlled trial.** *Lancet.* 2002; **360**(9326): 7–22.
[PubMed Abstract](#) | [Publisher Full Text](#)
4. **F** Chen ZM, Jiang LX, Chen YP, *et al.*: **Addition of clopidogrel to aspirin in 45,852 patients with acute myocardial infarction: randomised placebo-controlled trial.** *Lancet.* 2005; **366**(9497): 1607–21.
[PubMed Abstract](#) | [Publisher Full Text](#) | **F1000 Recommendation**
5. **F** Ridker PM, Danielson E, Fonseca FA, *et al.*: **Rosuvastatin to prevent vascular events in men and women with elevated C-reactive protein.** *N Engl J Med.* 2008; **359**(21): 2195–207.
[PubMed Abstract](#) | [Publisher Full Text](#) | **F1000 Recommendation**
6. Yusuf S, Sleight P, Pogue J, *et al.*: **Effects of an angiotensin-converting-enzyme inhibitor, ramipril, on cardiovascular events in high-risk patients. The Heart Outcomes Prevention Evaluation Study Investigators.** *N Engl J Med.* 2000; **342**(3): 145–53.
[PubMed Abstract](#) | [Publisher Full Text](#)
7. Navarese EP, Kolodziejczak M, Schulze V, *et al.*: **Effects of Proprotein Convertase Subtilisin/Kexin Type 9 Antibodies in Adults With Hypercholesterolemia: A Systematic Review and Meta-analysis.** *Ann Intern Med.* 2015; **163**(1): 40–51.
[PubMed Abstract](#) | [Publisher Full Text](#)
8. Tall AR: **Protease variants, LDL, and coronary heart disease.** *N Engl J Med.* 2006; **354**(12): 1310–2.
[PubMed Abstract](#) | [Publisher Full Text](#)
9. **F** Cohen JC, Boerwinkle E, Mosley TH Jr, *et al.*: **Sequence variations in PCSK9, low LDL, and protection against coronary heart disease.** *N Engl J Med.* 2006; **354**(12): 1264–72.
[PubMed Abstract](#) | [Publisher Full Text](#) | **F1000 Recommendation**
10. Spence JD, Hackam DG: **Treating arteries instead of risk factors: a paradigm change in management of atherosclerosis.** *Stroke.* 2010; **41**(6): 1193–9.
[PubMed Abstract](#) | [Publisher Full Text](#)
11. **F** Spence JD, Coates V, Li H, *et al.*: **Effects of intensive medical therapy on microemboli and cardiovascular risk in asymptomatic carotid stenosis.** *Arch Neurol.* 2010; **67**(2): 180–6.
[PubMed Abstract](#) | [Publisher Full Text](#) | **F1000 Recommendation**
12. Spence JD, Tamayo A, Lowmie SP, *et al.*: **Absence of microemboli on transcranial Doppler identifies low-risk patients with asymptomatic carotid stenosis.** *Stroke.* 2005; **36**(11): 2373–8.
[PubMed Abstract](#) | [Publisher Full Text](#)
13. Paraskevas KI, Spence JD, Veith FJ, *et al.*: **Identifying which patients with asymptomatic carotid stenosis could benefit from intervention.** *Stroke.* 2014; **45**(12): 3720–4.
[PubMed Abstract](#) | [Publisher Full Text](#)
14. Haust MD, More RH, Bencosme SA, *et al.*: **Electron microscopic studies in human atherosclerosis extracellular elements in aortic dots and streaks.** *Exp Mol Pathol.* 1967; **6**(3): 300–13.
[PubMed Abstract](#) | [Publisher Full Text](#)
15. Ross R, Glomset JA: **The pathogenesis of atherosclerosis (second of two parts).** *N Engl J Med.* 1976; **295**(8): 420–5.
[PubMed Abstract](#) | [Publisher Full Text](#)
16. Ross R, Glomset JA: **The pathogenesis of atherosclerosis (first of two parts).** *N Engl J Med.* 1976; **295**(7): 369–77.
[PubMed Abstract](#) | [Publisher Full Text](#)
17. Spence JD, Perkins DG, Kline RL, *et al.*: **Hemodynamic modification of aortic atherosclerosis. Effects of propranolol vs hydralazine in hypertensive hyperlipidemic rabbits.** *Atherosclerosis.* 1984; **50**(3): 325–33.
[PubMed Abstract](#) | [Publisher Full Text](#)
18. Hansson GK: **Inflammation, atherosclerosis, and coronary artery disease.** *N Engl J Med.* 2005; **352**(16): 1685–95.
[PubMed Abstract](#) | [Publisher Full Text](#)
19. Spence JD: **Fasting lipids: the carrot in the snowman.** *Can J Cardiol.* 2003; **19**(8): 890–2.
[PubMed Abstract](#)
20. Ghanim H, Abuaysheh S, Sia CL, *et al.*: **Increase in plasma endotoxin concentrations and the expression of Toll-like receptors and suppressor of cytokine signaling-3 in mononuclear cells after a high-fat, high-carbohydrate meal: implications for insulin resistance.** *Diabetes Care.* 2009; **32**(12): 2281–7.
[PubMed Abstract](#) | [Publisher Full Text](#) | [Free Full Text](#)
21. Dandona P, Ghanim H, Chaudhuri A, *et al.*: **Macronutrient intake induces oxidative and inflammatory stress: potential relevance to atherosclerosis and insulin resistance.** *Exp Mol Med.* 2010; **42**(4): 245–53.
[PubMed Abstract](#) | [Publisher Full Text](#) | [Free Full Text](#)
22. Vogel RA, Corretti MC, Plotnick GD: **Effect of a single high-fat meal on endothelial function in healthy subjects.** *Am J Cardiol.* 1997; **79**(3): 350–4.
[PubMed Abstract](#) | [Publisher Full Text](#)
23. Chiuve SE, McCullough ML, Sacks FM, *et al.*: **Healthy lifestyle factors in the primary prevention of coronary heart disease among men: benefits among users and nonusers of lipid-lowering and antihypertensive medications.** *Circulation.* 2006; **114**(2): 160–7.
[PubMed Abstract](#) | [Publisher Full Text](#)
24. Akesson A, Larsson SC, Discacciati A, *et al.*: **Low-risk diet and lifestyle habits in the primary prevention of myocardial infarction in men: a population-based prospective cohort study.** *J Am Coll Cardiol.* 2014; **64**(13): 1299–306.
[PubMed Abstract](#) | [Publisher Full Text](#)
25. **F** de Lorgeril M, Salen P, Martin JL, *et al.*: **Mediterranean diet, traditional risk factors, and the rate of cardiovascular complications after myocardial infarction: final report of the Lyon Diet Heart Study.** *Circulation.* 1999; **99**(6): 779–85.
[PubMed Abstract](#) | [Publisher Full Text](#) | **F1000 Recommendation**
26. **F** Estruch R, Ros E, Salas-Salvado J, *et al.*: **Primary prevention of cardiovascular disease with a Mediterranean diet.** *N Engl J Med.* 2013; **368**(14): 1279–90.
[PubMed Abstract](#) | [Publisher Full Text](#) | **F1000 Recommendation**
27. Spence JD, Jenkins DJ, Davignon J: **Dietary cholesterol and egg yolks: not for patients at risk of vascular disease.** *Can J Cardiol.* 2010; **26**(9): e336–9.
[PubMed Abstract](#) | [Free Full Text](#)
28. Cohen DJ, Stolker JM, Wang K, *et al.*: **Health-related quality of life after carotid stenting versus carotid endarterectomy: results from CREST (Carotid Revascularization Endarterectomy Versus Stenting Trial).** *J Am Coll Cardiol.* 2011; **58**(15): 1557–65.
[PubMed Abstract](#) | [Publisher Full Text](#) | [Free Full Text](#)
29. **F** Koeth RA, Wang Z, Levison BS, *et al.*: **Intestinal microbiota metabolism of L-carnitine, a nutrient in red meat, promotes atherosclerosis.** *Nat Med.* 2013; **19**(5): 576–85.
[PubMed Abstract](#) | [Publisher Full Text](#) | [Free Full Text](#) | **F1000 Recommendation**
30. **F** Tang WH, Wang Z, Levison BS, *et al.*: **Intestinal microbial metabolism of phosphatidylcholine and cardiovascular risk.** *N Engl J Med.* 2013; **368**(17): 1575–84.
[PubMed Abstract](#) | [Publisher Full Text](#) | [Free Full Text](#) | **F1000 Recommendation**
31. Petrof EO, Gloor GB, Vanner SJ, *et al.*: **Stool substitute transplant therapy for the eradication of *Clostridium difficile* infection: 'RePOOPulating' the gut.** *Microbiome.* 2013; **1**(1): 3.
[PubMed Abstract](#) | [Publisher Full Text](#) | [Free Full Text](#)
32. Spence JD, Urquhart BL, Bang H: **Effect of renal impairment on atherosclerosis: only partially mediated by homocysteine.** *Nephrol Dial Transplant.* 2016; **31**(6): 937–44.
[PubMed Abstract](#) | [Publisher Full Text](#) | [Free Full Text](#)
33. Wheeler DC: **Cardiovascular disease in patients with chronic renal failure.** *The Lancet.* 1996; **348**(9043): 1673–4.
[Publisher Full Text](#)
34. Gansevoort RT, Correa-Rotter R, Hemmelgarn BR, *et al.*: **Chronic kidney disease and cardiovascular risk: epidemiology, mechanisms, and prevention.** *Lancet.* 2013; **382**(9889): 339–52.
[PubMed Abstract](#) | [Publisher Full Text](#)
35. Tang WH, Wang Z, Kennedy DJ, *et al.*: **Gut microbiota-dependent trimethylamine N-oxide (TMAO) pathway contributes to both development of renal insufficiency and mortality risk in chronic kidney disease.** *Circ Res.* 2015; **116**(3): 448–55.
[PubMed Abstract](#) | [Publisher Full Text](#) | [Free Full Text](#)
36. Poesen R, Claes K, Evenepoel P, *et al.*: **Microbiota-Derived Phenylacetylglutamine Associates with Overall Mortality and Cardiovascular Disease in Patients with CKD.** *J Am Soc Nephrol.* 2016. pii: ASN.2015121302.
[PubMed Abstract](#) | [Publisher Full Text](#)
37. Spence JD, Dresser GK: **Overcoming Challenges With Statin Therapy.** *J Am Heart Assoc.* 2016; **5**(1). pii: e002497.
[PubMed Abstract](#) | [Publisher Full Text](#) | [Free Full Text](#)
38. **F** Sabatine MS, Giugliano RP, Wiviott SD, *et al.*: **Efficacy and safety of evolocumab in reducing lipids and cardiovascular events.** *N Engl J Med.* 2015; **372**(16): 1500–9.
[PubMed Abstract](#) | [Publisher Full Text](#) | **F1000 Recommendation**
39. **F** Robinson JG, Farnier M, Krempf M, *et al.*: **Efficacy and safety of alirocumab in reducing lipids and cardiovascular events.** *N Engl J Med.* 2015; **372**(16): 1489–99.
[PubMed Abstract](#) | [Publisher Full Text](#) | **F1000 Recommendation**
40. Fitzgerald K, Frank-Kamenetsky M, Shulga-Morskaya S, *et al.*: **Effect of an RNA interference drug on the synthesis of proprotein convertase subtilisin/kexin type 9 (PCSK9) and the concentration of serum LDL cholesterol in healthy**

- volunteers: a randomised, single-blind, placebo-controlled, phase 1 trial. *Lancet*. 2014; **383**(9911): 60–8.
[PubMed Abstract](#) | [Publisher Full Text](#) | [Free Full Text](#)
41. Spence JD: Measurement of carotid plaque burden. *JAMA Neurol*. 2015; **72**(4): 383–4.
[PubMed Abstract](#) | [Publisher Full Text](#)
 42. Spence JD, Eliasziw M, DiCicco M, *et al.*: Carotid plaque area: a tool for targeting and evaluating vascular preventive therapy. *Stroke*. 2002; **33**(12): 2916–22.
[PubMed Abstract](#) | [Publisher Full Text](#)
 43. Spence JD: Time course of atherosclerosis regression. *Atherosclerosis*. 2014; **235**(2): 347–8.
[PubMed Abstract](#) | [Publisher Full Text](#)
 44. Ainsworth CD, Blake CC, Tamayo A, *et al.*: 3D ultrasound measurement of change in carotid plaque volume: a tool for rapid evaluation of new therapies. *Stroke*. 2005; **36**(9): 1904–9.
[PubMed Abstract](#) | [Publisher Full Text](#)
 45. Naylor AR: Time to rethink management strategies in asymptomatic carotid artery disease. *Nat Rev Cardiol*. 2011; **9**(2): 116–24.
[PubMed Abstract](#) | [Publisher Full Text](#)
 46. Marquardt L, Geraghty OC, Mehta Z, *et al.*: Low risk of ipsilateral stroke in patients with asymptomatic carotid stenosis on best medical treatment: a prospective, population-based study. *Stroke*. 2010; **41**(1): e11–7.
[PubMed Abstract](#) | [Publisher Full Text](#)
 47. Chaturvedi S, Rothwell PM: Stroke risk with symptomatic carotid stenosis: The future is not what it used to be. *Neurology*. 2016; **86**(6): 494–5.
[PubMed Abstract](#) | [Publisher Full Text](#)
 48. **F** Paraskevas KI, Kalmykov EL, Naylor AR: Stroke/Death Rates Following Carotid Artery Stenting and Carotid Endarterectomy in Contemporary Administrative Dataset Registries: A Systematic Review. *Eur J Vasc Endovasc Surg*. 2016; **51**(1): 3–12.
[PubMed Abstract](#) | [Publisher Full Text](#) | [F1000 Recommendation](#)
 49. Spence JD, Naylor AR: Endarterectomy, Stenting, or Neither for Asymptomatic Carotid-Artery Stenosis. *N Engl J Med*. 2016; **374**(11): 1087–8.
[PubMed Abstract](#) | [Publisher Full Text](#)
 50. Naylor AR, Gaines PA, Rothwell PM: Who benefits most from intervention for asymptomatic carotid stenosis: patients or professionals? *Eur J Vasc Endovasc Surg*. 2009; **37**(6): 625–32.
[PubMed Abstract](#) | [Publisher Full Text](#)
 51. Spence JD: Management of Patients with an Asymptomatic Carotid Stenosis—Medical Management, Endovascular Treatment, or Carotid Endarterectomy? *Curr Neurol Neurosci Rep*. 2016; **16**(1): 3.
[PubMed Abstract](#) | [Publisher Full Text](#)
 52. Inaba Y, Chen JA, Bergmann SR: Carotid plaque, compared with carotid intima-media thickness, more accurately predicts coronary artery disease events: a meta-analysis. *Atherosclerosis*. 2012; **220**(1): 128–33.
[PubMed Abstract](#) | [Publisher Full Text](#)
 53. Spence JD: Carotid plaque measurement is superior to IMT invited editorial comment on: carotid plaque, compared with carotid intima-media thickness, more accurately predicts coronary artery disease events: a meta-analysis—Yoichi Inaba, M.D., Jennifer A. Chen M.D., Steven R. Bergmann M.D., Ph.D. *Atherosclerosis*. 2012; **220**(1): 34–5.
[PubMed Abstract](#) | [Publisher Full Text](#)
 54. Spence JD, Parraga G: Three-Dimensional Ultrasound of Carotid Plaque. *Neuroimaging Clin N Am*. 2016; **26**(1): 69–80.
[PubMed Abstract](#) | [Publisher Full Text](#)
 55. Sillesen H, Muntendam P, Adourian A, *et al.*: Carotid plaque burden as a measure of subclinical atherosclerosis: comparison with other tests for subclinical arterial disease in the High Risk Plaque Biolmage study. *JACC Cardiovasc Imaging*. 2012; **5**(7): 681–9.
[PubMed Abstract](#) | [Publisher Full Text](#)
 56. Baber U, Mehran R, Sartori S, *et al.*: Prevalence, impact, and predictive value of detecting subclinical coronary and carotid atherosclerosis in asymptomatic adults: the Biolmage study. *J Am Coll Cardiol*. 2015; **65**(11): 1065–74.
[PubMed Abstract](#) | [Publisher Full Text](#)
 57. **F** Den Ruijter HM, Peters SA, Anderson TJ, *et al.*: Common carotid intima-media thickness measurements in cardiovascular risk prediction: a meta-analysis. *JAMA*. 2012; **308**(8): 796–803.
[PubMed Abstract](#) | [Publisher Full Text](#) | [F1000 Recommendation](#)
 58. Johnsen SH, Mathiesen EB, Joakimsen O, *et al.*: Carotid atherosclerosis is a stronger predictor of myocardial infarction in women than in men: a 6-year follow-up study of 6226 persons: the Tromsø Study. *Stroke*. 2007; **38**(11): 2873–80.
[PubMed Abstract](#) | [Publisher Full Text](#)
 59. Mathiesen EB, Johnsen SH, Wilsgaard T, *et al.*: Carotid plaque area and intima-media thickness in prediction of first-ever ischemic stroke: a 10-year follow-up of 6584 men and women: the Tromsø Study. *Stroke*. 2011; **42**(4): 972–8.
[PubMed Abstract](#) | [Publisher Full Text](#)
 60. Egger M, Spence JD, Fenster A, *et al.*: Validation of 3D ultrasound vessel wall volume: an imaging phenotype of carotid atherosclerosis. *Ultrasound Med Biol*. 2007; **33**(6): 905–14.
[PubMed Abstract](#) | [Publisher Full Text](#)
 61. Krasinski A, Chiu B, Spence JD, *et al.*: Three-dimensional ultrasound quantification of intensive statin treatment of carotid atherosclerosis. *Ultrasound Med Biol*. 2009; **35**(11): 1763–72.
[PubMed Abstract](#) | [Publisher Full Text](#)
 62. Shai I, Spence JD, Schwarzfuchs D, *et al.*: Dietary intervention to reverse carotid atherosclerosis. *Circulation*. 2010; **121**(10): 1200–8.
[PubMed Abstract](#) | [Publisher Full Text](#)
 63. Lorenz MW, Polak JF, Kavousi M, *et al.*: Carotid intima-media thickness progression to predict cardiovascular events in the general population (the PROG-IMT collaborative project): a meta-analysis of individual participant data. *Lancet*. 2012; **379**(9831): 2053–62.
[PubMed Abstract](#) | [Publisher Full Text](#) | [Free Full Text](#)
 64. **F** Wannarong T, Parraga G, Buchanan D, *et al.*: Progression of carotid plaque volume predicts cardiovascular events. *Stroke*. 2013; **44**(7): 1859–65.
[PubMed Abstract](#) | [Publisher Full Text](#) | [F1000 Recommendation](#)
 65. **F** Markus HS, King A, Shipley M, *et al.*: Asymptomatic embolisation for prediction of stroke in the Asymptomatic Carotid Emboli Study (ACES): a prospective observational study. *Lancet Neurol*. 2010; **9**(7): 663–71.
[PubMed Abstract](#) | [Publisher Full Text](#) | [F1000 Recommendation](#)
 66. Madani A, Beletsky V, Tamayo A, *et al.*: High-risk asymptomatic carotid stenosis: ulceration on 3D ultrasound vs TCD microemboli. *Neurology*. 2011; **77**(8): 744–50.
[PubMed Abstract](#) | [Publisher Full Text](#)
 67. Topakian R, King A, Kwon SU, *et al.*: Ultrasonic plaque echolucency and emboli signals predict stroke in asymptomatic carotid stenosis. *Neurology*. 2011; **77**(8): 751–8.
[PubMed Abstract](#) | [Publisher Full Text](#)
 68. Kakkos SK, Griffin MB, Nicolaides AN, *et al.*: The size of juxtaluminal hypochoic area in ultrasound images of asymptomatic carotid plaques predicts the occurrence of stroke. *J Vasc Surg*. 2013; **57**(3): 609–618.e1; discussion 617–8.
[PubMed Abstract](#) | [Publisher Full Text](#)
 69. Kakkos SK, Nicolaides AN, Kyriacou E, *et al.*: Computerized texture analysis of carotid plaque ultrasonic images can identify unstable plaques associated with ipsilateral neurological symptoms. *Angiology*. 2011; **62**(4): 317–28.
[PubMed Abstract](#) | [Publisher Full Text](#)
 70. Kuk M, Wannarong T, Beletsky V, *et al.*: Volume of carotid artery ulceration as a predictor of cardiovascular events. *Stroke*. 2014; **45**(5): 1437–41.
[PubMed Abstract](#) | [Publisher Full Text](#)
 71. van Engelen A, Wannarong T, Parraga G, *et al.*: Three-dimensional carotid ultrasound plaque texture predicts vascular events. *Stroke*. 2014; **45**(9): 2695–701.
[PubMed Abstract](#) | [Publisher Full Text](#)
 72. Altaf N, Daniels L, Morgan PS, *et al.*: Detection of intraplaque hemorrhage by magnetic resonance imaging in symptomatic patients with mild to moderate carotid stenosis predicts recurrent neurological events. *J Vasc Surg*. 2008; **47**(2): 337–42.
[PubMed Abstract](#) | [Publisher Full Text](#)
 73. Altaf N, Morgan PS, Moody A, *et al.*: Brain white matter hyperintensities are associated with carotid intraplaque hemorrhage. *Radiology*. 2008; **248**(1): 202–9.
[PubMed Abstract](#) | [Publisher Full Text](#)
 74. Singh N, Moody AR, Gladstone DJ, *et al.*: Moderate carotid artery stenosis: MR imaging-depicted intraplaque hemorrhage predicts risk of cerebrovascular ischemic events in asymptomatic men. *Radiology*. 2009; **252**(2): 502–8.
[PubMed Abstract](#) | [Publisher Full Text](#)
 75. Rudd JH, Warburton EA, Fryer TD, *et al.*: Imaging atherosclerotic plaque inflammation with [¹⁸F]-fluorodeoxyglucose positron emission tomography. *Circulation*. 2002; **105**(23): 2708–11.
[PubMed Abstract](#) | [Publisher Full Text](#)
 76. Cocker MS, Mc Ardle B, Spence JD, *et al.*: Imaging atherosclerosis with hybrid [¹⁸F]fluorodeoxyglucose positron emission tomography/computed tomography imaging: what Leonardo da Vinci could not see. *J Nucl Cardiol*. 2012; **19**(6): 1211–25.
[PubMed Abstract](#) | [Publisher Full Text](#) | [Free Full Text](#)

Open Peer Review

Current Referee Status:



Editorial Note on the Review Process

F1000 Faculty Reviews are commissioned from members of the prestigious **F1000 Faculty** and are edited as a service to readers. In order to make these reviews as comprehensive and accessible as possible, the referees provide input before publication and only the final, revised version is published. The referees who approved the final version are listed with their names and affiliations but without their reports on earlier versions (any comments will already have been addressed in the published version).

The referees who approved this article are:

Version 1

- 1 **Tanja Rundek**, Department of Neurology, Miller School of Medicine, University of Miami, Coral Gables, FL, USA
Competing Interests: No competing interests were disclosed.
- 2 **Tasneem Naqvi**, Echocardiography Laboratories, Mayo Clinic, Scottsdale, AZ, USA
Competing Interests: No competing interests were disclosed.
- 3 **Conrado Estol**, Heart and Brain Medicine, Buenos Aires, Argentina
Competing Interests: No competing interests were disclosed.