

Inflammatory pseudotumor of spleen

Parvin Rajabi, Hasan Noorollahi¹, Mohsen Hani, Marzie Bagheri

Departments of Pathology and ¹Surgery, Isfahan University of Medical Sciences, Isfahan, Iran

Abstract

Inflammatory pseudotumor (IPT) is an uncommon tumor and its occurrence in spleen is rare. This tumor is composed of proliferation of spindle cells of unknown origin and etiology that mimic other tumors at clinical and histological evaluation. The most surmising etiology is Epstein Barr virus (EBV) and the most suspected origin is myofibroblasts, hence its synonym is “inflammatory myofibroblastic tumor.”

The clinical appearance of tumor is related to its location but the most ones are abdominal pain, fever and weight loss. Surgical removal for this lesion is treatment of choice and there is few reported case with recurrence and metastasis.

Herein we report a 63-year-old female patient with and abdominal discomfort that primary paraclinical investigations had been showed splenic mass and therefore surgical treatment was performed for her.

Microscopic examination suggest some different diagnosis such as IPT, thus immunohistochemical staining was perform to confirm the diagnosis and rule out the others.

Key Words: Immunohistochemical staining, inflammatory pseudotumor, spleen

Address for correspondence:

Dr. Mohsen Hani, Department of Pathology, Isfahan University of Medical Sciences, Isfahan, Iran. E-mail: dr.mohsenhani@yahoo.com

Received: 26.03.2012, Accepted: 03.03.2013

INTRODUCTION

Inflammatory pseudotumor (IPT) is a lesion of unknown etiology that neoplastic or benign nature of this lesion is under debate. There are many afflicted organs that have been reported such as orbit, spinal meninges, digestive system, heart, soft-tissues, mesothelial membranes, respiratory tract, bladder, lymph nodes, liver, and spleen but lung is predilection site.^[1-4]

Pathogenesis of IPT is unclear, some researchers have been clarified relationship between Epstein Barr

virus (EBV) and this tumor but others did not. Some investigators postulated the hypothesis of vascular, traumatic and immunologic cause for this tumor and also because of existence of chromosomal abnormality the neoplastic nature of IPT was suspected.^[5,6]

IPT often present as well circumscribed mass and is composed of inflammatory cells and lymphocytes (mainly plasmacells) in a fibroblastic stroma. Someren subdivided this lesion into 3 histopathological subtypes: Xanthogranuloma type, plasma cell granuloma type, and sclerosing pseudotumor. Various combination of these tree type may be seen together in same lesion.^[3,6] because of this various doubtful histologic appearance the additional study such as Immunohistochemistry (IHC) must be performed to confirm the diagnosis, but IHC not always provide constant result.

In this paper we report a case of splenic IPT and review IHC and clinicohistopathological finding of some literature.

Access this article online	
Quick Response Code:	Website: www.advbiores.net
	DOI: 10.4103/2277-9175.124679

Copyright: © 2014 Rajabi. This is an open-access article distributed under the terms of the Creative Commons Attribution License, which permits unrestricted use, distribution, and reproduction in any medium, provided the original author and source are credited.

How to cite this article: Rajabi P, Noorollahi H, Hani M, Bagheri M. Inflammatory pseudotumor of spleen. Adv Biomed Res 2014;3:29.

CASE REPORT

A 63-year-old woman was admitted in our clinic with abdominal discomfort. She complained of upper left quadrant abdominal pain from 2 years ago. She had past history of nephrolithiasis that was treated by extracorporeal shock wave about 2 years ago; she was a known case of uncontrolled diabetes mellitus and had several resorts to cardiologists for transient chest and abdominal pain. Her paraclinical findings were as follow: Fasting blood sugar was 269 mg/dl, HbA1c was 9.1, T3, T4, Thyroid stimulating hormone, Aspartate transaminase, Alanine aminotransferase, Alkaline phosphatase, Creatinine and Blood urea nitrogen was normal and Hb was 11.9 g/dl. There was no any contributory finding in initial physical examination, so she referred to radiologist for abdominal ultrasonography.

Ultrasonographic investigation revealed hypoechogenic solid mass at inferiomedial pole of spleen that measured 83 mm × 82 mm × 70 mm and cortical cyst of right kidney, thus furthermore abdominal computed tomography (CT) scan was done for her. On CT-scan examination the hypodense mass was shown at central portion of spleen that induced marginal bulging [Figure 1]. There was no calcification and remarkable enhancement. Liver density was low due to fatty change. Other organs were normal there was no lymphadenopathy. With such findings the different diagnosis was primary tumor of spleen, hamartoma and single metastasis, so splenectomy was advised.

On surgical operation the spleen with peripheral lymph nodes were removed and send to pathologist.

On macroscopic examination, spleen measured 13 × 9 × 7 cm and weighted 370 g. After sectioning a well circumscribed bulging brown colored mass, 8 cm in greatest diameter was identified with softer consistency than splenic tissue [Figure 2].

On microscopic examination, the mass showed diffuse infiltration of fibroblasts and inflammatory cells mainly composed of lymphocytes, significant number of plasma cells, some histiocytes and neutrophils [Figure 3]. Lymph nodes showed follicular hyperplasia with some hemosiderin pigment deposition. This feature was consistent with IPT. For rule out the Hodgkin's lymphoma immunohistochemical study was recommended. The common panel for hodgkin's cells are cluster of differentiation 15 (CD 15) and CD30 positivity but in IPT the background CD3 and CD20 positive lymphocytes are only exist.

In immunohistochemical staining the CD15, CD30 and anaplastic lymphoma kinase (ALK1) were negative, CD3 and CD20 were positive in few background inflammatory cells thus Hodgkin's lymphoma was ruled out [Figure 4].

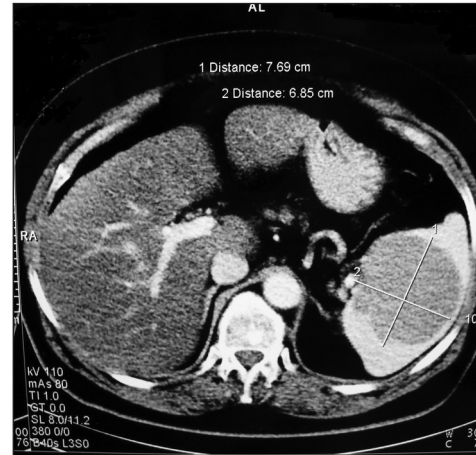


Figure 1: Hypodense splenic mass

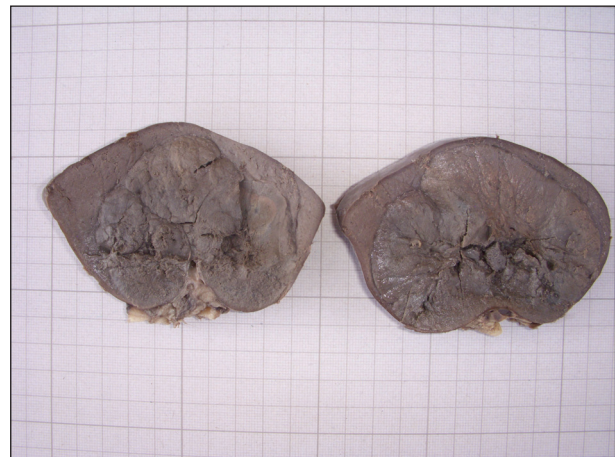

Figure 2: Well circumscribed bulging brown colored mass

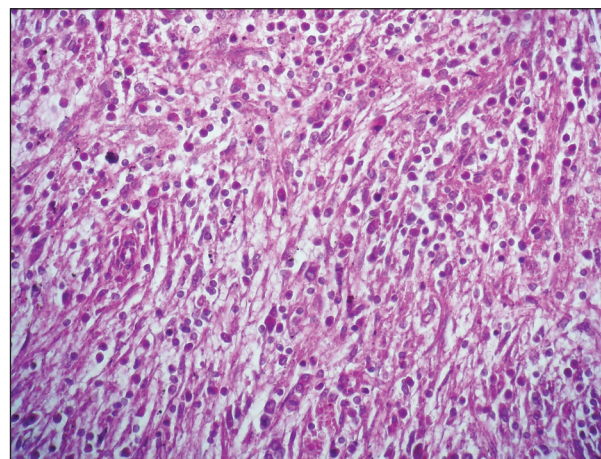


Figure 3: Diffuse infiltration of fibroblasts and inflammatory cells

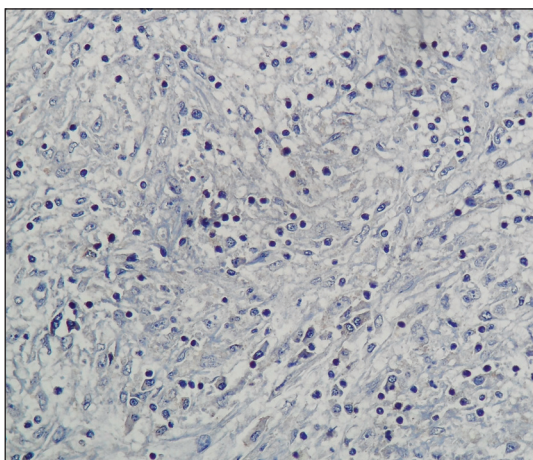


Figure 4: Anaplastic lymphoma kinase 1 is negative in myofibroblastic cells

DISCUSSION

Primary benign splenic tumors are rare and are about 0.007% in prevalence. Among them hamartomas, hemangiomas, and lymphangiomas are more common and IPT seldom have been seen.^[6,7]

This lesion often occurs in adults but there are reported cases of childhood affliction, the ages of patients range from 19 years to 91 years old. This lesion insidiously progresses until it lets out non-specific symptoms or becomes apparent in workup of other extrasplenic conditions.^[5,7,8] The common presentation of the lesion are abdominal pain, fever, weight loss, anemia, thrombocytosis, polyclonal hypergammaglobulinemia, elevated ESR, hypercalcemia and leukocytosis.^[2,5,6,9] This lesion sometimes has synchronous or asynchronous occurrence with other diseases such as: Renal cell carcinoma, adenocarcinoma of colon, cholecystitis, ductal carcinoma of breast, gastric banding for obesity and abscess.^[5,7,10]

In our 63-year-old patient the symptom was abdominal pain since 2 years ago. Abdominal discomfort began when extracorporeal shock wave treatment was done for her nephrolithiasis. Patient's pain became more localized to left side when the lesion was discovered on ultrasonography.

On macroscopic examination IPT are non-encapsulated, well circumscribed, multiple or single firm mass with tan or yellow white cut surface sometimes contain necrotic or hemorrhagic area. This variegated color is due to necrosis, hemorrhage, and cellular infiltration.^[2,9,11]

On microscopic examination IPT show proliferation of bland spindle cells admixed with variable

inflammatory cells. Three patterns of growth may exist, a cellular compact spindle cell pattern, a hypocellular collagenous pattern and xanthogranulomatous pattern.^[5,11] Inflammatory cells include polymorphonuclear leukocyte, plasma cells, histiocytes and lymphocytes. The majority of these lymphocytes are T cells, with fewer numbers of B cells.^[1] Coagulative necrosis with neutrophilic infiltration is located centrally in most patients.^[12]

On immunohistochemical study, the myofibroblastic spindle cells can be positive for vimentin (99%), smooth muscle actin (92%), muscle-specific actin (92%), desmin (69%), cytoplasmic ALK (50%), cytokeratin (36%), CD68 (KP-1) (24%), and CD30 (Ki-1) (6%).^[13] The positivity of ALK is related to the site of tumor and the reticuloendothelial organ such as spleen and lymph nodes are negative for these markers.^[14,15]

In our experience, the spindle cells were negative for CD15, CD30 and ALK1. The background lymphocyte was composed of CD3 and CD20 positive cells.

Because of the variable immunophenotype patterns seen in hepatic and splenic IPTs some authors theorized that IPT are derived from common mesenchymal cells that can differentiate to myofibroblasts (with actin expression) or follicular dendritic cells (with CD 21 expression) or even could be undifferentiated (with CD 68 and vimentin expression), nevertheless the nature of spindle cells are often myofibroblast and immunohistochemical staining and electron microscopic studies confirm it.^[1,2,5]

The pathogenesis of IPT is under debate, IHC staining and *in situ* hybridization reveal a relationship between viral infection such as EBV and Human Herpes Virus 8 (HHV-8) and this lesion. Although it has been reported that EBV RNA was detected in 41.2% of cases at all but the prevalence of EBV positive lesion and type of infected cells depend on the site of affliction, for example the incidence of EBV infection in spleen and liver is greater than lymph node and the spindle cells are infected in liver and spleen but lymphocytes are infected in lymph node. It seems that the spindle cells that are infected in spleen exhibit follicular dendritic markers more often than myofibroblastic markers.^[1,5,16,17]

Some studies revealed chromosomal rearrangement involving 2p23 and others showed EBV

monoclonality of IPT that indicate neoplastic nature of this lesion.^[1,2] because IPT are sometimes concomitance with other disease some authors propound vascular, traumatic, immunologic and inflammatory etiology (such as elevated interleukin 2 (IL 2) and IL1).^[2,3,9]

On ultrasonography, lesion reveal heterogeneous, hypo-, iso- or hyperechogenic mass.^[3,10]

On CT scan, mass appear as ill-define hypo attenuating lesion with or without calcification and only moderate degree of enhancement with variety pattern may be seen follow administration of contrast medium. Sometime On delay phase there is peripheral area of iso- or hyper attenuated pattern.^[3,10] It seems that cellular pattern denote radiologic findings and there is no characteristic appearance because of different microscopic pattern.^[10] Hypoechoenicity and low attenuation on CT correspond to cellular area. Hypoattenuated area maybe due to extravasation of contrast media in edematous field.^[10] In our case, the tumor was cellular that compatible with hypodensity on CT scan.

On Magnetic resonance imaging (MRI), IPTs are typically iso or hypointense on T1-weighted image but T2 signal is variable depending on cellularity and fibrosis that cause hyperintensity or hypointensity respectively. Dynamic gadolinium enhance inspection reveal early peripheral arterial enhancement with central stellate T2 low signal and delayed progressive enhancement. These findings has been reported to be strongly suggestive of this entity. An (superparamagnetic iron oxide) contrast agent accumulate in splenic reticuloendothelial cells and decrease signal intensity on T2 thus MRI examination with this agent result in increased signal intensity of IPT relative to normal splenic tissue.^[8,9]

The IPTs usually treat with surgical operation. Overall prognosis is good but there are reported cases of aggressive behaviors. Some authors reported 11% prevalence of aggressiveness and metastasis in extra-pulmonary cases and others described the lesion as a benign, non-metastasizing proliferation of myofibroblasts with potential recurrence and persistent local growth, similar to fibromatoses, but World Health Organization classification places inflammatory myofibroblastic tumors in an intermediate category (rarely metastasizing, <5%) between benign and malignant.^[18-20] Aggressive IPTs are related to the site, multinodularity and vicinity of vital structure. Malignant transformation IPT demonstrates

vesicular nuclei, prominent nucleoli and mitosis. Some studies have shown that abdominal and sinonasal tumors have more aggressive behavior.^[2] In our case, the tumor had no atypical cells and mitosis; there was no metastases or local invasion, and there was no recurrence of tumor on 1-year follow-up.

REFERENCES

- Lewis JT, Gaffney RL, Casey MB, Farrell MA, Morice WG, Macon WR. Inflammatory pseudotumor of the spleen associated with a clonal Epstein-Barr virus genome. Case report and review of the literature. *Am J Clin Pathol* 2003;120:56-61.
- Ozkal S, Atila K, Kargi A, Sokmen S, Yorukoglu K. Inflammatory myofibroblastic tumor of the spleen: a case report. *Asian Pac J* 2004;1:22-5.
- Chen WH, Liu TP, Liu CL, Tzen CY. Inflammatory pseudotumor of the spleen. *J Chin Med Assoc* 2004;67:533-6.
- Hassan KS, Cohen HI, Hassan FK, Hassan SK. Unusual case of pancreatic inflammatory myofibroblastic tumor associated with spontaneous splenic rupture. *World J Emerg Surg* 2010;5:28.
- Neuhauser TS, Derringer GA, Thompson LD, Fanburg-Smith JC, Aguilera NS, Andriko J, *et al.* Splenic inflammatory myofibroblastic tumor (inflammatory pseudotumor): A clinicopathologic and immunophenotypic study of 12 cases. *Arch Pathol Lab Med* 2001;125:379-85.
- Noguchi H, Kondo H, Shiraiwa M, Monobe Y. Inflammatory pseudotumor of spleen: A case report. *Jpn J Clin Oncol* 2000;30:196-20.
- Yarmohammadi H, Nakamoto D, Faulhaber PF, Miedler J, Azar N. Inflammatory pseudotumor of the spleen: Review of clinical presentation and diagnostic methods. *J Radiol Case Rep* 2011;5:16-22.
- Silva AC. AJR Teaching File: Enlarging splenic mass after nephrectomy. *AJR Am J Roentgenol* 2006;186:S449-51.
- Hsu CW, Lin CH, Yang TL, Chang HT. Splenic inflammatory pseudotumor mimicking angiosarcoma. *World J Gastroenterol* 2008;14:6421-4.
- Bruyeer E, Ramboer K. Multiple inflammatory pseudotumors of the liver and spleen. *JBR-BTR* 2010;93:122-3.
- Bhatt S, Simon R, Dogra VS. Radiologic-pathologic conferences of the university of Rochester School of Medicine: Inflammatory pseudotumor of the spleen. *AJR Am J Roentgenol* 2008;191:1477-9.
- Edoute Y, Roguin A, Gallimidi Z, Ben-Izhak O, Nagachandran P, Ben-Ami H. Splenic inflammatory pseudotumor mimicking primary splenic malignancy. *Haematologica* 1999;84:765-6.
- Oshiro H, Nomura M, Yamanaka S, Watanabe S, Inayama Y. Splenic inflammatory pseudotumor (inflammatory myofibroblastic tumor). *J Clin Exp Hematop* 2007;47:83-8.
- Kutok JL, Pinkus GS, Dorfman DM, Fletcher CD. Inflammatory pseudotumor of lymph node and spleen: An entity biologically distinct from inflammatory myofibroblastic tumor. *Hum Pathol* 2001;32:1382-7.
- Qi-xing G, Qin-he F, Zhi-shao Z, Zhi-hong Z, Mei-ning Y, Zhen W, *et al.* Inflammatory pseudotumor-like follicular dendritic cell tumor of spleen. *Chin J Pathol* 2008;37:34-5.
- Rosenbaum L, Fekrazad MH, Rabinowitz I, Vasef MA. Epstein-Barr virus-associated inflammatory pseudotumor of the spleen: Report of two cases and review of the literature. *J Hematop* 2009;2:127-31.
- Gómez-Román JJ, Sánchez-Velasco P, Ocejó-Vinyals G, Hernández-Nieto E, Leyva-Cobián F, Val-Bernal JF. Human herpesvirus-8 genes are expressed in pulmonary inflammatory myofibroblastic tumor (inflammatory pseudotumor). *Am J Surg Pathol* 2001;25:624-9.

18. Meis JM, Enzinger FM. Inflammatory fibrosarcoma of the mesentery and retroperitoneum. A tumor closely simulating inflammatory pseudotumor. *Am J Surg Pathol* 1991;15:1146-56.
19. Coffin CM, Watterson J, Priest JR, Dehner LP. Extrapulmonary inflammatory myofibroblastic tumor (inflammatory pseudotumor). A clinicopathologic and immunohistochemical study of 84 cases. *Am J Surg Pathol* 1995;19:859-72.
20. Fletcher CD, Unni KK, Merterns F. World Health Organization Classification of Tumors: Pathology and Genetics of Tumours of Soft Tissue and Bone. Lyon: IARC Press; 2002.

Source of Support: Nil, **Conflict of Interest:** None declared.