

# Posterolateral Arthrodesis in Lumbar Spine Surgery Using Autologous Platelet-Rich Plasma and Cancellous Bone Substitute: An Osteoinductive and Osteoconductive Effect

Roberto Tarantino<sup>1</sup> Pasquale Donnarumma<sup>1</sup> Cristina Mancarella<sup>1</sup> Marika Rullo<sup>2</sup> Giancarlo Ferrazza<sup>3</sup>  
Gianna Barrella<sup>3</sup> Sergio Martini<sup>4</sup> Roberto Delfini<sup>1</sup>

<sup>1</sup>Department of Neurosurgery, "Sapienza" University of Rome, Rome, Italy

<sup>2</sup>Department of Psychology of Developmental and Socialization Processes, "Sapienza" University of Rome, Rome, Italy

<sup>3</sup>Department of Hematology, "Sapienza" University of Rome, Rome, Italy

<sup>4</sup>Department of Neuroradiology, "Sapienza" University of Rome, Rome, Italy

Address for correspondence Pasquale Donnarumma, MD, Department of Neurosurgery, "Sapienza" University of Rome, Viale del Policlinico 115, 00161 Rome, Italy  
(e-mail: dott.pasquale.donnarumma@gmail.com).

Global Spine J 2014;4:137–142.

## Abstract

**Study Design** Prospective cohort study.

**Objectives** To analyze the effectiveness and practicality of using cancellous bone substitute with platelet-rich plasma (PRP) in posterolateral arthrodesis.

**Methods** Twenty consecutive patients underwent posterolateral arthrodesis with implantation of cancellous bone substitute soaked with PRP obtained directly in the operating theater on the right hemifield and cancellous bone substitute soaked with saline solution on the right.

**Results** Computed tomography scans at 6 and 12 months after surgery were performed in all patients. Bone density was investigated by comparative analysis of region of interest. The data were analyzed with repeated-measures variance analyses with value of density after 6 months and value of density after 12 months, using age, levels of arthrodesis, and platelet count as covariates. The data demonstrated increased bone density using PRP and heterologous cancellous block resulting in an enhanced fusion rate during the first 6 months after surgery.

**Conclusions** PRP used with cancellous bone substitute increases the rate of fusion and bone density joining osteoinductive and osteoconductive effect.

## Keywords

- ▶ PRP
- ▶ posterolateral arthrodesis
- ▶ cancellous bone
- ▶ bone substitute

## Introduction

Arthrodesis is the conclusive target of vertebral fixation. Posterolateral fusion is commonly used in lumbar spine surgery. It consists of fusion between two adjacent vertebrae across the lamina and transverse processes.<sup>1</sup> Fusion depends on host and surgical factors including the selection of an

appropriate graft. Iliac crest autograft has long been considered the gold standard for bone graft procedures. However, its use is associated with significant disadvantages including insufficient availability, donor site pain, increased operative time, increased estimated blood loss, and longer hospital stay.<sup>2</sup> Many autologous or heterologous bone substitutes

received  
January 26, 2014  
accepted after revision  
April 7, 2014  
published online  
May 3, 2014

© 2014 Georg Thieme Verlag KG  
Stuttgart · New York

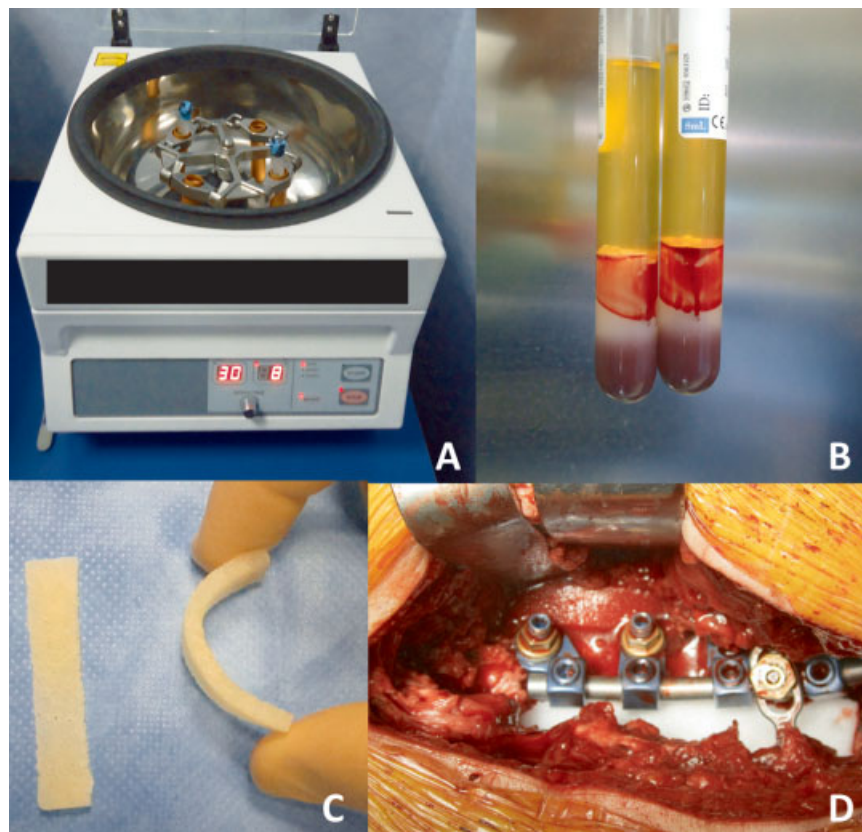
DOI <http://dx.doi.org/10.1055/s-0034-1376157>.  
ISSN 2192-5682.

are used to reach fusion. Currently, there are over 200 different commercial types of bone graft extenders, enhancers, and substitutes available from which to choose.<sup>3</sup> The objective is to find an osteoinductive and osteoconductive substrate that is also safe and easy to apply. The efficacy of platelet-rich plasma (PRP) as an osteoinductive material has been studied by several authors.<sup>4-6</sup> Preliminary results about using PRP in posterolateral fusion have been encouraging.<sup>7</sup> In this article, we analyze the effectiveness and practicality of using an heterologous cancellous bone substitute with autologous PRP obtained directly in the operating theater.

## Materials and Methods

We evaluated 20 consecutive patients who underwent posterior decompression, vertebral fixation with pedicle screws, and posterolateral fusion from January 2012 to January 2013 at the department of Neurological and Neurosurgical Sciences of "Sapienza" University of Rome. Written consent was obtained from all participating patients. The inclusion criteria were degenerative or traumatic lumbosacral spine disease and normal platelet count ( $150$  to  $450 \times 10^6/\mu\text{L}$ ). The exclusion criteria were previous lumbosacral surgery, fixation involving dorsal vertebrae, neoplastic disease, blood dyscrasias, and abnormal platelet count. The following method was used: cancellous bone substitute ( $25 \times 50 \times 30$  mm) soaked with autologous PRP was implanted on the right hemifield

and cancellous bone substitute ( $25 \times 50 \times 30$  mm) soaked with saline solution on the left hemifield. TecnoSS (Torino, Italy) SP-Block Soft BS7E ( $25 \times 50 \times 30$  mm) was used as a bone substitute. It consists of a rigid heterologous cancellous collagenated bone block of equine origin. If hydrated with saline solution for 5 to 10 minutes, it becomes flexible and malleable. Each block was enough to cover two levels of arthrodesis unilaterally. Autologous PRP was obtained in the operating theater by taking peripheral venous blood from the patient. The Regen system (RegenLab, Lausanne, Switzerland) was used, consisting of an 8-mL patented test tube Regen THT-SP and a Regen centrifuge (H19-F Regen Centrigel) placed directly in the operating theater. The test tube containing  $3 \pm 0.1$  g of polyester gel and  $1 \pm 0.05$  mL of sodium citrate solution was centrifuged for 8 minutes at 3,100 rpm (1,500 g). This removes 95 to 100% of total red blood cells, with 80% of white blood cells and a platelet concentration between  $2.5$  and  $4.5 \times 10^6/\mu\text{L}$  remaining. After centrifugation, the content was divided into red blood cells below the filter at the base of the tube and PRP with buffy-coat superiorly. Platelets were suspended in plasma while shaking the tubes. The product was then ready for use. Each tube contained  $\sim 4.5$  mL of PRP, immediately available for application and enough to cover about two levels of arthrodesis unilaterally. The contact of the PRP with the porosity of the cancellous bone substitute and the addition of 2 mL of calcium gluconate favored the activation of the coagulation



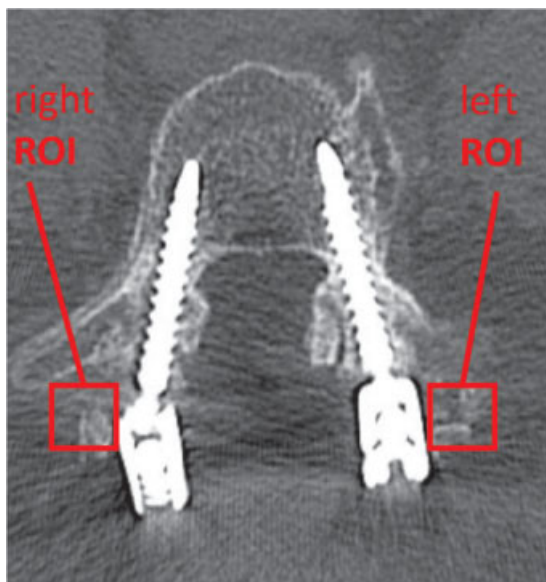
**Fig. 1** (A) Centrifuge placed in the operating room. (B) After centrifugation, red blood cells trapped below the filter of gel content at the base of the tube. The upper portion is divided in the platelet-rich plasma and in the upper buffy-coat; (C) bone block; (D) intraoperative picture.

cascade and platelet activation (►Fig. 1). Investigations into bone density were obtained by comparative analysis of region of interest (ROI) on computed tomography (CT) scan images. A square area 0.4 cm in size (ROI) is traced over the axial CT scan across the lamina and transverse processes. The electronic calculation of the mean pixel content (bidimensional unit of measurement) can be done in Hounsfield units (HUs). The numerical value obtained is the average of the densitometric values of the pixels contained in the area; HU = 0 corresponds to water, -1,000 to air, and +1,000 to cortical bone.

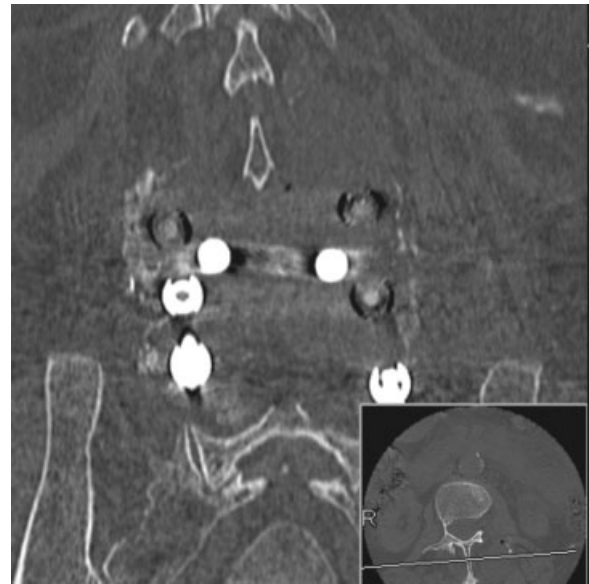## Results

The 20 patients included 8 males and 12 females with mean age = 70 (standard deviation [SD] = 10.9). They were operated on for 15 lumbar stenosis and 5 lumbar body fractures. The platelet count in the whole blood varied between 173 and  $390 \times 10^6/\text{mL}$ . A CT scan 6 and 12 months after surgery was performed in all patients (►Figs. 2 and 3). Investigations into bone density were obtained by comparative analysis of ROI (►Table 1). The data were analyzed with two repeated-measures variance analyses with value of density after 6 months and value of density after 12 months as factors (density on the right hemifield versus density on the left hemifield) using age, levels of arthrodesis, and platelet count (in the whole blood) as covariates.

The main effect of value of density after 6 months was significant ( $F(1,19) = 5.522, p < 0.05$ ); the value of density on the right hemifield after 6 months was significantly different from the value of the density on the left hemifield (mean = 830.353 [SD 61.8] for the right hemifield versus mean = 632.890 [SD 59.5] for the left hemifield). The post hoc mean comparison showed that the value of density on the right hemifield was significantly greater than the value of



**Fig. 2** Region of interest (ROI) analysis on computed tomography scan 6 months after surgery.



**Fig. 3** Coronal computed tomography scan 6 months after surgery.

density on the left hemifield after 6 months ( $\Delta = 197.463; F(1,19) = 43, p < 0.001$ ). The interaction with age was marginally significant ( $F(1,19) = 3.700, p = 0.72$ ); the interaction between the levels ( $F(1,19) = 2.070, p = 0.169$ ) and the platelet count ( $F(1,19) = 0.64, p = 0.804$ ) was not significant, which suggests no effects of these variables on results.

These data demonstrate increased bone density using PRP and heterologous cancellous block in the first 6 months after surgery (►Fig. 4).

The analysis of variance on the value of the density after 12 months showed that at this time no significant difference was observed in the two hemifields ( $F(1,19) = 1.100, p = 0.310$ ). In fact, the mean of the value of the density on the right hemifield was 871.810 versus 837.011 of the left hemifield after 12 months ( $\Delta = 34.79; F(1,19) = 0.665, p = 0.426$ ). Also in this case, no interaction between the covariates of age ( $F(1,19) = 0.573, p = 0.460$ ), levels ( $F(1,19) = 1.407, p = 0.253$ ), and platelet count ( $F(1,19) = 0.117, p = 0.737$ ) was observed. No correlation between bone density and preoperative platelet count was observed.

## Discussion

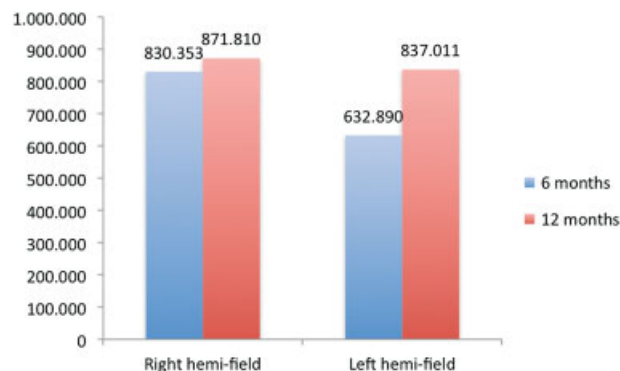
Posterolateral arthrodesis is a fusion between two adjacent vertebrae across the lamina and transverse processes.<sup>1</sup> Many autologous or heterologous bone substitutes are generally used as an implantation to reach fusion.<sup>3</sup> The objective is to find an osteoconductive and osteoinductive substrate that is also safe and easy to apply. The bone substitute is a heterologous cancellous collagenated bone block of equine origin. It acts as an osteoconductive scaffold. Collagen binding to fibronectin promotes the anchorage of mesenchymal stem progenitors, on which it exerts its chemotactic action and induces differentiation into osteoblasts. It has a rigid and malleable consistency and maintains the original graft

**Table 1** Comparative analysis of ROI on CT scan at 6 and 12 months: presurgical platelet count on whole blood

Patients	Age/sex	Etiology	Levels	6 mo		12 mo		Platelet count ( $\times 10^6$ /mL)
				Right	Left	Right	Left	
1	71 F	Degenerative	2	428.65	321.66	520.66	367.93	198
2	62 F	Degenerative	3	567.64	342.87	689.96	542.34	228
3	80 F	Degenerative	3	630.90	340.45	930.97	745.45	184
4	44 F	Traumatic	2	1,232.76	720.87	1,274.12	1,003.56	173
5	75 M	Degenerative	3	830.45	785.56	961.34	1,291.98	254
6	56 F	Degenerative	4	608.34	417.76	839.23	901.78	222
7	80 F	Traumatic	1	480.67	321.08	490.76	380.09	299
8	72 M	Traumatic	2	745.65	521.46	930.26	767.03	301
9	68 F	Degenerative	3	785.94	542.47	789.86	647.24	274
10	80 M	Degenerative	3	1,030.90	740.36	929.27	785.50	179
11	78 M	Degenerative	2	1,256.36	930.03	978.12	1,287.46	247
12	76 F	Degenerative	3	901.69	953.35	927.74	1,273.48	133
13	51 M	Traumatic	4	709.34	453.76	837.28	901.28	285
14	80 F	Degenerative	2	506.67	432.08	364.46	375.38	230
15	59 F	Degenerative	3	768.65	567.12	543.76	590.09	366
16	61 M	Traumatic	1	1,312.35	1,178.73	1,374.12	1,304.32	392
17	75 M	Degenerative	2	1,298.85	830.45	1,291.56	961.34	289
18	83 F	Degenerative	4	344.24	367.35	532.77	428.83	188
19	73 M	Degenerative	2	1,121.60	978.34	1,187.46	1,089.93	186
20	76 F	Degenerative	3	945.11	912.04	1,042.51	1,095.21	215

volume from 6 to 18 months from application. This is particularly important to allow the rapid development of the bony bridge between the transverse processes. This also reduce the risk of pseudarthrosis and nonunion present in arthrodesis performed with other substitutes.<sup>8</sup> Moreover, cancellous bone substitute can be used also in association with autologous bone graft (laminectomy bone chips); future investigations to analyze this option are necessary.

In this study, we included both patients with degenerative conditions and patients who experienced trauma. Because posterior elements are intact in vertebral body fractures, the

**Fig. 4** Bone density between the left and the right hemifields at 6 and 12 months.

cohort of patients is homogeneous. We excluded patients with tumor because we do not routinely perform posterolateral arthrodesis. Fusion was assessed with computerized analysis of ROI, a square area 0.4 cm in size traced over the axial CT scan across the lamina and transverse processes. It is important to emphasize that the numerical value obtained from this measurement is the average of the densitometric values of the pixels contained in the area studied. We did not notice high-density areas that could be hypertrophic pseudarthrosis. PRP has an osteoinductive effect increasing the bone regeneration and production.<sup>9,10</sup> This is due to the action of growth factors released by platelets upon activation. Platelets are a potential source of multiple autologous growth factors, and proteins are involved in the physiologic processes of healing and tissue regeneration. The products rich in platelets have the goal to replace the blood clot with a preparation enriched in platelets that, once activated, secrete large amounts of proteins and growth factors (platelet-derived growth factor, epidermal growth factor, transforming growth factor- $\beta$ , vascular endothelial growth factor, insulin-like growth factor 1). They exert mitogenic action on osteoblasts and induce the differentiation of mesenchymal stem progenitors into osteoblasts.<sup>11</sup> Autologous PRP can be obtained directly in the operating theater. This method is faster and immediately available to the surgeon.

PRP has to be prepared to effectively separate the platelets from red blood cells, taking care not to damage the platelets.



This method is important because the growth factors contained within the platelet  $\alpha$ -granules are activated at the same time that the granules themselves merge with membrane platelet.<sup>12-14</sup> The properties of the PRP in tissue repair have already been documented in numerous studies. Therefore, the molecular mechanisms through which the growth factors stimulate repair are complex and depend on the different types of tissues and types of cells that receive the messages.<sup>15</sup> PRP is obtained by platelet sequestration and concentration. The exact relationship between the platelet count and the concentration of growth factors remains unclear. No correlation between bone density and whole blood platelet count was found in our series. Several in vitro studies seem to point out that the content of platelet growth factors is quite variable among individuals and is not necessarily proportional to the platelet count.<sup>16</sup> PRP is an autologous product and is completely safe for the patient. Moreover, it promotes leukocyte chemotaxis and has antibacterial effect and also increases tissue repair and remodeling.<sup>16</sup> Several studies demonstrated that iliac crest autograph is the gold standard for bone graft procedures including posterolateral fusion.<sup>2,3</sup> As its use is associated with significant disadvantages (including insufficient availability, donor site pain, increased operative time, increased estimated blood loss, longer hospital stay), many surgeons prefer to use heterologous bone substitutes even if it is proved that their validity is lower. In this study, we are testing an alternative option that appears to be effective and safe. The validity of our method has not been compared with autograph, but the technique can be improved in the future.

## Conclusions

PRP used with cancellous bone substitute increases the speed of bone production in posterolateral arthrodesis joining osteoinductive and osteoconductive effect. Autologous PRP can be produced directly in the operative theater. The preparation is very quick and can be made also during surgery. This method is a safe and effective alternative option to the common bone substitutes.

## Disclosures

None

## References

- Gibson JN, Grant IC, Waddell G. The Cochrane review of surgery for lumbar disc prolapse and degenerative lumbar spondylosis. *Spine (Phila Pa 1976)* 1999;24(17):1820-1832
- Glassman SD, Carreon LY, Djurasovic M, et al. RhBMP-2 versus iliac crest bone graft for lumbar spine fusion: a randomized, controlled trial in patients over sixty years of age. *Spine (Phila Pa 1976)* 2008; 33(26):2843-2849
- Park JJ, Hershman SH, Kim YH. Updates in the use of bone grafts in the lumbar spine. *Bull Hosp Jt Dis* (2013) 2013;71(1):39-48
- Acebal-Cortina G, Suárez-Suárez MA, García-Menéndez C, Moro-Barrero L, Iglesias-Colao R, Torres-Pérez A. Evaluation of autologous platelet concentrate for intertransverse lumbar fusion. *Eur Spine J* 2011;20(Suppl 3):361-366
- Lee JH, Chang BS, Jeung UO, Park KW, Kim MS, Lee CK. The first clinical trial of beta-calcium pyrophosphate as a novel bone graft extender in instrumented posterolateral lumbar fusion. *Clin Orthop Surg* 2011;3(3):238-244
- Tsai CH, Hsu HC, Chen YJ, Lin MJ, Chen HT. Using the growth factors-enriched platelet glue in spinal fusion and its efficiency. *J Spinal Disord Tech* 2009;22(4):246-250
- Landi A, Tarantino R, Marotta N, et al. The use of platelet gel in postero-lateral fusion: preliminary results in a series of 14 cases. *Eur Spine J* 2011;20(Suppl 1):S61-S67
- Motomiya M, Ito M, Takahata M, et al. Effect of hydroxyapatite porous characteristics on healing outcomes in rabbit posterolateral spinal fusion model. *Eur Spine J* 2007;16(12):2215-2224
- Bose B, Balzarini MA. Bone graft gel: autologous growth factors used with autograft bone for lumbar spine fusions. *Adv Ther* 2002; 19(4):170-175
- Jenis LG, Banco RJ, Kwon B. A prospective study of autologous growth factors (AGF) in lumbar interbody fusion. *Spine J* 2006; 6(1):14-20
- Dohan Ehrenfest DM, Rasmusson L, Albrektsson T. Classification of platelet concentrates: from pure platelet-rich plasma (P-PRP) to leucocyte- and platelet-rich fibrin (L-PRF). *Trends Biotechnol* 2009;27(3):158-167
- Ferrara N, Gerber HP, LeCouter J. The biology of VEGF and its receptors. *Nat Med* 2003;9(6):669-676
- Sundman EA, Cole BJ, Fortier LA. Growth factor and catabolic cytokine concentrations are influenced by the cellular composition of platelet-rich plasma. *Am J Sports Med* 2011;39(10): 2135-2140
- Vaccaro AR, Sharan AD, Tuan RS, et al. The use of biologic materials in spinal fusion. *Orthopedics* 2001;24(2):191-197, quiz 198-199
- Mazzucco L, Balbo V, Cattana E, Guaschino R, Borzini P. Not every PRP-gel is born equal. Evaluation of growth factor availability for tissues through four PRP-gel preparations: Fibrinet, RegenPRP-Kit, Plateltex and one manual procedure. *Vox Sang* 2009;97(2): 110-118
- Brew EC, Mitchell MB, Harken AH. Fibroblast growth factors in operative wound healing. *J Am Coll Surg* 1995;180(4):499-504