

# A 70° Arthroscope Provides Better Visualization of the Medial Side of the Elbow Than a 30° Arthroscope



Valerio Monteleone, M.D., Valeria Vismara, M.D., Simone Cassin, M.D.,  
Francesco Luceri, M.D., Carlo Zaolino, M.D., Chandan Kulkarni, M.D.,  
Pietro Simone Randelli, M.D., and Paolo Arrigoni, M.D.

**Purpose:** To assess and quantify the improvement in visualization of humeral insertion of the medial collateral ligament (MCL) using a 70° scope compared with a 30° scope during elbow arthroscopy. **Methods:** Twenty patients undergoing elbow arthroscopy for different pathologic conditions were enrolled in this single-center study. Visualization of the medial gutter of the elbow was evaluated by using both the 70° and the 30° scope. During the procedure, a needle was inserted at 45° with respect to the axis of the forearm, directed toward the intra-articular humeral emergence of the MCL. Four areas were established: the body (Z1), the lanceolate part (Z2), the tip of the needle (Z3), and the medial portion of the trochlea (Z4). The visible areas during arthroscopy using 2 different scopes were collected. **Results:** The 70° scope allowed the detection of the first 3 areas in all patients (Z1, Z2, and Z3) and the visualization of the last area (Z4) in 19 patients (95%). On the other hand, the 30° scope allowed the detection of Z1 in 85% of patients, Z2 in 60% of patients, and Z3 in only 5% of patients. The medial portion of the trochlea was never visualized with the 30° scope. These findings were statistically significant. **Conclusions:** The 70° scope improves visualization of the medial elbow compartment during elbow arthroscopy compared to the 30° scope, enhancing the extent of joint visualization and potentially permitting the detection of otherwise missed injuries in the difficult-to-reach areas of the joint. **Level of Evidence:** Level II, diagnostic, prospective, cohort study.

Most elbow injuries, particularly the ones that involve the medial collateral ligament (MCL), are challenging injuries, even for expert surgeons. Although elbow surgical release was originally designed as an open surgery, arthroscopy has been predominantly performed in the past few years for treating elbow injuries. This is due to the minimally invasive

approach of arthroscopy, limited surgery time, lower risk of postprocedural infections, lower risk of bleeding, and shorter postsurgery recovery.<sup>1,2</sup>

However, MCL total visualization during elbow arthroscopy remains a goal to achieve.<sup>3</sup> Less than half of the MCL is visible with a 30° arthroscope from a standard posterior portal. There have been no studies reporting an objective improvement in arthroscopic visualization of the medial gutter using a 70° scope, positioned in the anterolateral portal, located 1.5 to 2 cm proximal and 1 cm anterior to the lateral epicondyle.

Elbow arthroscopy has been considered for years a challenging procedure, given the minimal joint space and the proximity of critical neurovascular structures.<sup>4</sup> Nonetheless, elbow arthroscopy is still regarded as a technique with a long learning curve,<sup>5</sup> and previous studies reported a higher complication rate in patients undergoing elbow arthroscopy than in patients undergoing knee or shoulder arthroscopy.<sup>6</sup>

A 70° arthroscope allows the surgeon to have a frontal view of the hardly approachable parts of the elbow joint<sup>7</sup> in contrast to the side view offered by the 30° scope.<sup>8</sup>

From Clinica Ortopedica, ASST Centro Specialistico Ortopedico Traumatologico Gaetano Pini-CTO, Milan, Italy (V.M., F.L., C.Z., C.K., P.S.R., P.A.); Scuola Di Specializzazione in Ortopedia e Traumatologia Università Degli Studi Di Milano, Milan, Italy (V.V., S.C.); Laboratory of Applied Biomechanics, Department of Biomedical Sciences for Health, Università Degli Studi Di Milano, Milan, Italy (P.S.R.); and Research Center for Adult and Pediatric Rheumatic Diseases (RECAP-RD), Department of Biomedical Sciences for Health, Università Degli Studi Di Milano, Milan, Italy (P.S.R.).

V.M. and V.V. contributed equally to the work. P.S.R. and P.A. contributed equally to the work.

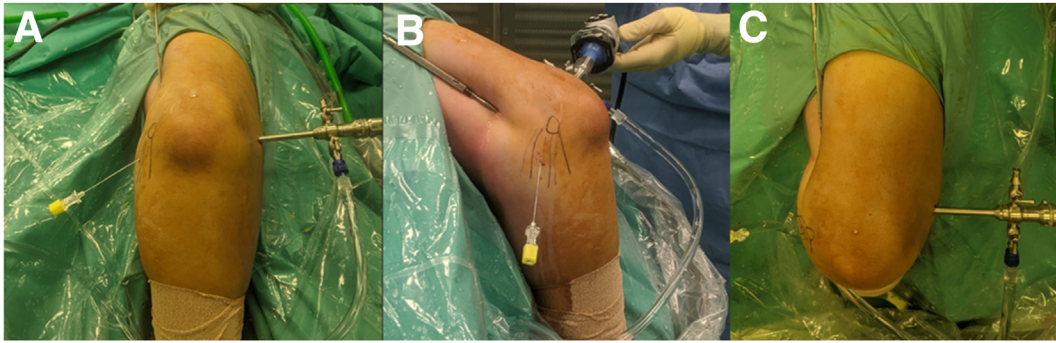
Received May 17, 2023; accepted December 14, 2023.

Address correspondence to Paolo Arrigoni, M.D., ASST Pini-CTO, Piazza Cardinale Andrea Ferrari 1–20122 Milan, Italy. E-mail: [arrigoni.p@gmail.com](mailto:arrigoni.p@gmail.com)

© 2024 Published by Elsevier Inc. on behalf of the Arthroscopy Association of North America. This is an open access article under the CC BY-NC-ND license (<http://creativecommons.org/licenses/by-nc-nd/4.0/>).

2666-061X/23651

<https://doi.org/10.1016/j.asmr.2023.100865>



**Fig 1.** Representation of the arthroscopic setting from frontal, medial, and superior views, achieved with the patient in the lateral decubitus position. The arthroscope is introduced into the right elbow through the anterolateral portal, located 1.5 to 2 cm proximal and 1 cm anterior to the lateral epicondyle. The medial gutter is visualized from this point of view. A spinal needle (18 gauge, yellow) is later inserted with an 45° inclination to the forearm, slightly posterior to anterior relative to the surgical position of the patient, directed toward the intra-articular humeral emergence of the medial collateral ligament.

We previously reported the advantages of using this kind of scope to allow extensor carpi radialis brevis tendon release with preservation of the radial lateral collateral ligament.<sup>9</sup>

The purpose of this study was to assess and quantify the improvement in visualization of the humeral insertion of the MCL using a 70° scope compared with a 30° scope during elbow arthroscopy. Our hypothesis is that the 70° lens allows a better direct visualization of medial structures of the elbow than a 30° scope.

## Materials and Methods

### Patient Population

Patients who underwent arthroscopic elbow surgery from March 2022 to December 2022 and did not present any abnormalities of the medial gutter were considered eligible for this study.

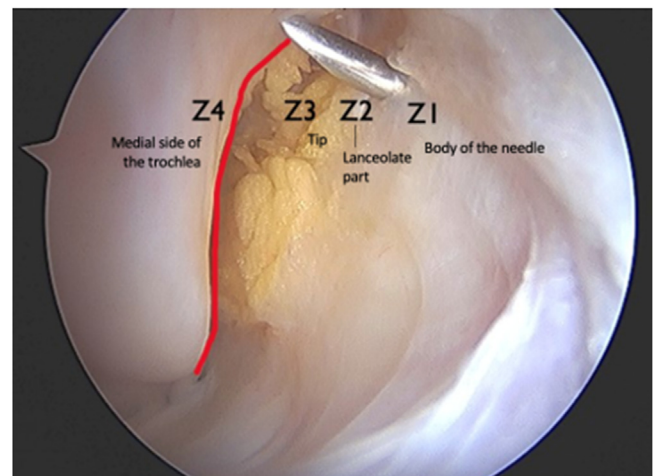
Twenty consecutive patients were excluded because they had conditions that would alter the anatomy of the elbow joint, major stiffness (maximal range of motion of 60°) due to large osteophytes, or large heterotopic ossifications and previous fracture and dislocation. All patients with neurologic disorders of the affected arm, impaired sensation, and paralysis were also excluded. Patients with a loss of flexion and/or extension of 30° were excluded from the study, too. Elbow stiffness and neurologic conditions were assessed during preoperative physical examination. The presence of dislocation, fractures, and other disease was evaluated by radiologic imaging and by patients' medical history.

### Description of the Surgical Technique

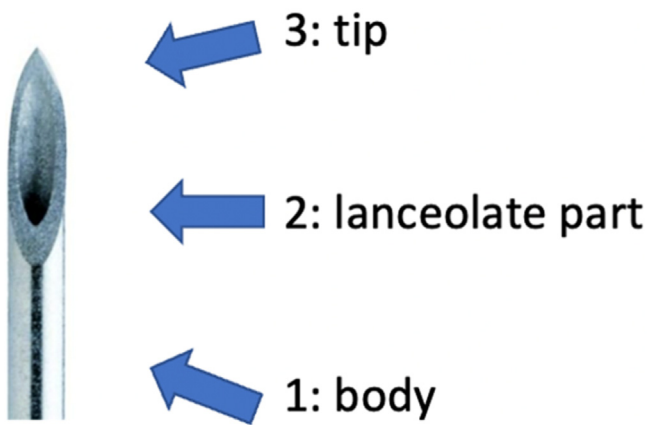
During the procedure, the patient was put in a modified lateral decubitus position, with the operative arm at 100° of flexion/90° of abduction at the level of the shoulder by an arm holder. The elbow stood in 90° of flexion, with the forearm hanging free to gravity. A

tourniquet was then positioned at the axilla and inflated to 250 mm Hg.

The arthroscope was introduced into the elbow through the anterolateral portal, located 1.5 to 2 cm proximal and 1 cm anterior to the lateral epicondyle. The MCL features were evaluated using the 70° scope first and then the 30° scope; the main arthroscopic procedures were performed using the 30° scope.<sup>7-9</sup> A spinal needle (18 gauge) was later inserted with an inclination of 45° with respect to the forearm, from slightly posterior to anterior relative to the surgical position of the patient, directed toward the intra-articular humeral emergence of the MCL (Fig 1).



**Fig 2.** Arthroscopic visualization of the medial gutter of the right elbow using the 70° scope in the anterolateral portal, after needle insertion. Identification of 4 different areas according to the possibility of seeing the different parts of the needle: Z1, body of the needle; Z2, lanceolate part of the needle; Z3, tip of the needle; or Z4, the medial side of the trochlea.



**Fig 3.** Graphical representation highlighting the different parts of the needle: (1) body, (2) lanceolate part, and (3) tip.

Four areas were identified according to the possibility of seeing different parts of the needle up to the medial trochlea: the body (Z1), the lanceolate part (Z2) and the tip (Z3), and the medial portion of the trochlea (Z4). The visible areas were detected during arthroscopy (Figs 2-3).

All 20 procedures were performed and documented by a single surgeon (P.A.) with extensive experience in elbow arthroscopy.

The patients analyzed in our study were selected for surgery for different clinical reasons. Their pathology did not obstruct measurements in any way.

The detection of the visible part of the needle of each arthroscopic procedure was carried out through mutual agreement by the surgical team (an orthopaedic surgeon trained in shoulder and elbow surgery and 2 other observers [V.V., V.M.]).

Institutional review board approval was obtained before we began the investigation, and written informed consent was obtained from patients.

### Statistical Analysis

Patients' characteristics and visualization rates are reported as numbers (percentages) or median (minimum-maximum), as appropriate.

Unpaired *t* tests were conducted for every group of measurements comparing 70° scope and 30° scope visualization. Significance level was set at  $P < .05$ .

A preliminary analysis was conducted on findings obtained on 6 measurements using the 70° and 30° scopes. Based on this data analysis, with a desired power of 80% and a significance level of 5% (2-sided comparison of proportions), a sample size of 20 different measurement was considered sufficient for arthroscopic evaluation of the medial gutter with both 30° and 70° scopes.

### Results

The 20 included patients (30% female) had a mean age of 50 years (range, 18-66 years). Arthroscopic evaluation of the medial gutter with both the 30° and 70° scopes was carried out in all patients during previous surgical procedures (Figs 4-5). The detection of different areas of the needle (Z1 to Z4) was reported in all surgical interventions.

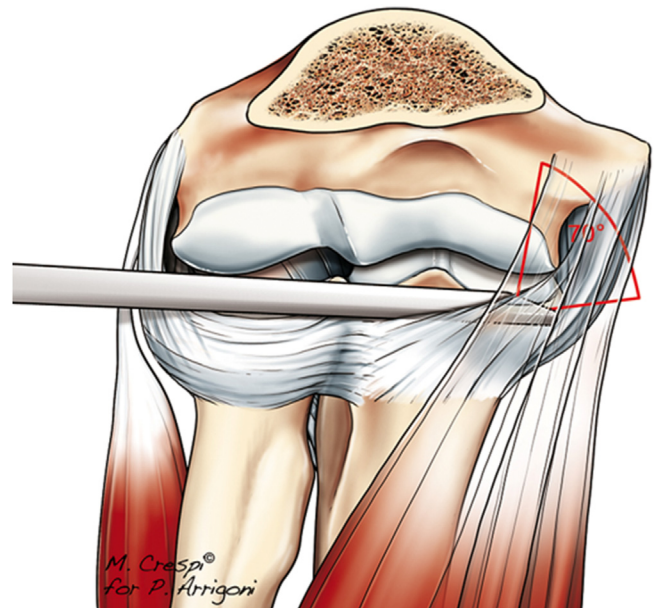
The 30° scope allowed the detection of Z1 (needle body) in 17 (85%) patients, Z2 (lanceolate part) in 12 (60%) patients, and Z3 (needle tip) in only 1 (5%) patient. The last area (Z4, the medial portion of trochlea) was not detected in any patients. The 70° scope, on the other hand, allowed the detection of the first 3 areas in all patients (Z1, Z2, and Z3; 20 patients, 100%) and visualization of the last area (Z4) in 19 patients (95%) (Fig 6).

A statistically significant difference was found when comparing the visualization of all different areas (Z1 to Z4) using the 30° and 70° scopes according to an unpaired *t* test assuming unequal variances (Table 1), by assuming a dichotomous variable (0 = not visualized, 1 = visualized).

### Discussion

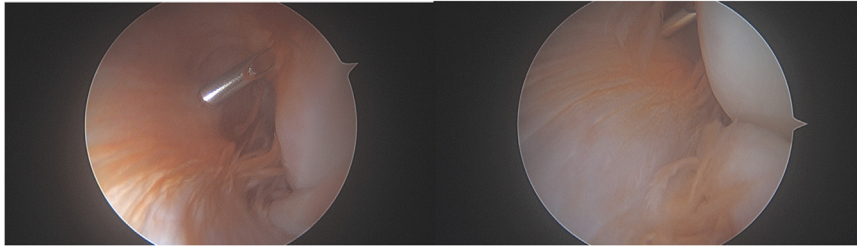
In this study, the visualization of the whole needle was achieved in most patients (100% for Z1, Z2, and Z3 and 95% for Z4), proving the advantage of the 70° scope.

By achieving the direct visualization of these difficult-to-reach parts of the elbow joint, the 70° scope may



**Fig 4.** Graphic representation showing the positioning of the 70° arthroscope within the right elbow joint via the anterolateral portal looking toward the medial gutter.





**Fig 5.** Arthroscopic visualization of the medial gutter of the right elbow using the 30° scope (left) and the 70° scope (right) in the same patient with the scope in the anterolateral portal and a spinal needle inserted with an 45° inclination to the forearm, slightly posterior to anterior relative to the surgical position of the patient, directed toward the intra-articular humeral emergence of the medial collateral ligament. During visualization, the needle is left in the same spot.

detect injuries that would otherwise be missed, like ligamentous and capsular avulsions. In this context, the potential utility of the 70° scope emerges as a compelling tool, poised for growing adoption in the future and integration into standard surgical practices.

Complete visualization of the joint is a substantial advantage in the challenging setting of elbow arthroscopy, given the small space the joint offers.

A possible consequence of implementing this new tool could be to finally shorten the long learning curve now associated with elbow arthroscopy.

The MCL is an important primary stabilizer of the elbow; MCL lesions usually occur at its pivoting point, meaning at its insertion on the humerus.<sup>3</sup> According to our findings, this area seems to be better visualized with the 70° scope than the 30° scope, suggesting that ligamentous repair or reconstruction could be better performed with the 70° scope. The anatomic study results by Kwak et al.<sup>3,10</sup> also suggest that less than 50% of the MCL could be visualized arthroscopically with the 30° scope and that the posterior bundle was rarely visualized. Of course, triangulation with a 70° scope is more challenging and requires practice for those who are not familiar with its use.

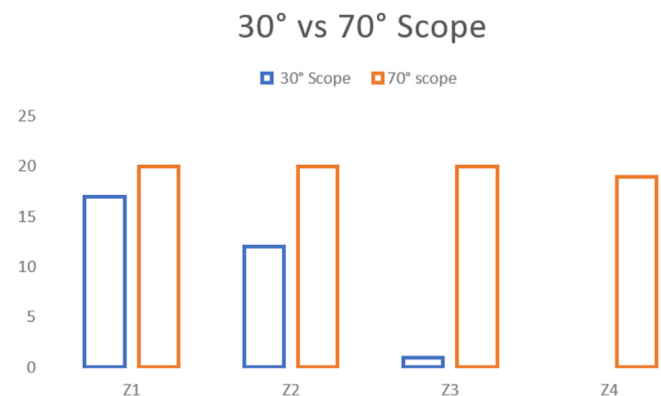
Ligamentous laxity or injury due to a traumatic event often leads to elbow instability.<sup>11,12</sup> Many mechanisms of injury have been identified: posterolateral rotatory instability, posteromedial rotatory instability, valgus or varus stress, or direct posterior blunt trauma.<sup>13</sup> Whereas simple elbow instabilities are characterized only by a ligamentous type of injury, complex elbow instabilities are also associated with fracture of the radial head, the coronoid process, or the olecranon process of the ulna.<sup>13</sup> In these cases, the surgeon is often more focused on the repair of the bony components, and this could lead to an underestimation of the ligamentous injuries.<sup>14,15</sup> Moreover, ultrasound and/or magnetic resonance imaging (MRI) evaluation of the ligaments could be challenging, especially right after a traumatic event.<sup>16,17</sup> Arthro-MRI or arthro-computed tomography has higher sensitivity but is less readily

available in case of ligamentous injury after acute instability.<sup>18</sup> Also, clinical misjudgment and/or failing treatments could lead to chronic elbow instability.<sup>19,20</sup> This clinical evidence suggests that an arthroscopic evaluation of the elbow in the acute phase could help physicians to better understand and quantify the injury pattern and the damage, taking into account both bony and ligamentous components.<sup>4</sup>

Open procedures for ligamentous repair or reconstruction have been described and frequently associated with ulnar nerve and muscle damage.<sup>10</sup> To date, no arthroscopic technique has been described, especially due to the difficulty in visualizing the MCL insertion. The use of the 70° scope may allow these limitations to be overcome and increase the number of arthroscopic indications.

### Limitations

This study has some limitations; mainly, using a needle as a landmark was arbitrary and based on our



**Fig 6.** The blue plot represents the ability to see the different zones (Z1 to Z4) using the 30° arthroscope, while the orange plot represents the ability to see the different zones (Z1 to Z4) using the 70° arthroscope. Z3 and Z4 are more likely to be seen with the 70° scope compared to the 30° scope. The medial portion of the trochlea could never be visualized with the 30° scope.

**Table 1.** P Values of Differences Between the Visualization of All Distinct Areas (Z1 to Z4) Using the 30° and 70° Scopes According to Unpaired *t* Test Assuming Unequal Variances, by Assuming a Dichotomous Variable (0 = Not Visualized, 1 = Visualized)

	Zone 1	Zone 2	Zone 3	Zone 4
Mean 30° scope	0.85	0.6	0.05	0
Mean 70° scope	1	1	1	0.95
P value	.04140692	.00104741	4.0373E-14	4.0373E-14

team experience. In addition, the 70° scope is not always available, and its use adds cost in terms of equipment and time to switch out scopes.

### Conclusions

The 70° scope improves visualization of the medial elbow compartment during elbow arthroscopy compared to the 30° scope, enhancing the extent of joint visualization and potentially permitting the detection of otherwise missed injuries in the difficult-to-reach areas of the joint.

### Disclosure

The authors report no conflicts of interest in the authorship and publication of this article. Full ICMJE author disclosure forms are available for this article online, as [supplementary material](#).

### Acknowledgment

The authors acknowledge support from the University of Milan through the APC initiative.

### References

- Treuting R. Minimally invasive orthopedic surgery: Arthroscopy. *Ochsner J* 2000;2:158-163.
- Guerra E, Marinelli A, Tortorella F, et al. Elbow arthroscopy for the treatment of radial head fractures: Surgical technique and 10 years of follow up results compared to open surgery. *J Clin Med* 2023;12:1558.
- Kwak JM, Kholinne E, Sun Y, et al. Arthroscopic visualization of the medial collateral ligament of the elbow. *J Shoulder Elb Surg* 2019;28:2232-2237.
- Camp CL, Degen RM, Sanchez-Sotelo J, et al. Basics of elbow arthroscopy part I: Surface anatomy, portals, and structures at risk. *Arthrosc Tech* 2016;5:e1339-e1343.
- Luceri F, Arrigoni P, Barco R, et al. Does sawbone-based arthroscopy module (SBAM) can help elbow surgeons? *Indian J Orthop* 2021;55:182-188 (suppl 1).
- Keyt LK, Jensen AR, O'Driscoll SW, et al. Establishing the learning curve for elbow arthroscopy: Surgeon and trainee perspectives on number of cases needed and optimal methods for acquiring skill. *J Shoulder Elb Surg* 2020;29:e434-e442.
- Arrigoni P, Luceri F, Cucchi D, et al. Reliability of anterior medial collateral ligament plication of the elbow. *Musculoskelet Surg* 2018;102:85-91 (suppl 1).
- Bedi A, Dines J, Dines DM, et al. Use of the 70° arthroscope for improved visualization with common arthroscopic procedures. *Arthroscopy* 2010;26:1684-1696.
- Arrigoni P, Fossati C, Zottarelli L, et al. 70° frontal visualization of lateral compartment of the elbow allows extensor carpi radialis brevis tendon release with preservation of the radial lateral collateral ligament. *Arthroscopy* 2014;30:29-35.
- Rahman RK, Levine WN, Ahmad CS. Elbow medial collateral ligament injuries. *Curr Rev Musculoskelet Med* 2008;1:197-204.
- Safran MR, Baillargeon D. Soft-tissue stabilizers of the elbow. *J Shoulder Elb Surg* 2005;14:179S-185S (suppl).
- Wilps T, Kaufmann RA, Yamakawa S, et al. Elbow biomechanics: Bony and dynamic stabilizers. *J Hand Surg Am* 2020;45:528-535.
- Karbach LE, Elfar J. Elbow instability: Anatomy, biomechanics, diagnostic maneuvers, and testing. *J Hand Surg Am* 2017;42:118-126.
- Luceri F, Cucchi D, Rosagrata E, et al. Novel radiographic indexes for elbow stability assessment: Part A—cadaveric validation. *Indian J Orthop* 2021;55:336-346 (suppl 2).
- Luceri F, Cucchi D, Rosagrata E, et al. Novel radiographic indexes for elbow stability assessment: Part B—preliminary clinical study. *Indian J Orthop* 2021;55:347-358 (suppl 2).
- Kane SF, Lynch JH, Taylor JC. Evaluation of elbow pain in adults. *Am Fam Physician* 2014;89:649-657.
- Sutterer BJ, Boettcher BJ, Payne JM, et al. The role of ultrasound in the evaluation of elbow medial ulnar collateral ligament injuries in throwing athletes. *Curr Rev Musculoskelet Med* 2022;15:535-546.
- Mak S, Beltran LS, Bencardino J, et al. MRI of the annular ligament of the elbow: Review of anatomic considerations and pathologic findings in patients with posterolateral elbow instability. *AJR Am J Roentgenol* 2014;203:1272-1279.
- Marinelli A, Graves BR, Bain GI, et al. Treatment of elbow instability: State of the art. *J ISAKOS Jt Disord Orthop Sport Med* 2021;6:102-115.
- Cheung EV. Chronic lateral elbow instability. *Orthop Clin North Am* 2008;39:221-228. vi-vii.