

## Letter to the Editor

Emilio Guirao-Arrabal<sup>1</sup>  
César García-López<sup>2</sup>  
Francisco Anguita-Santos<sup>1</sup>  
Javier de la Cruz-Sabido<sup>3</sup>  
Natalia Chueca<sup>4</sup>  
Elena Ruiz-Escolano<sup>5</sup>  
Luis Aliaga-Martínez<sup>6</sup>  
Pilar Giner-Escobar<sup>6</sup>  
Ángel Ceballos-Torres<sup>6</sup>

# Disseminated aspergillosis in an immunocompetent patient treated with corticosteroids: value of PCR for diagnosis

<sup>1</sup>Infectious Diseases Unit. Hospital Universitario San Cecilio. Granada. Spain

<sup>2</sup>Pathology Unit. Hospital Universitario San Cecilio. Granada. Spain

<sup>3</sup>Neurosurgery Unit. Hospital Universitario Virgen de las Nieves. Granada. Spain

<sup>4</sup>Microbiology Unit. Hospital Universitario San Cecilio. Granada. Spain

<sup>5</sup>Gastroenterology Unit. Hospital Universitario San Cecilio. Granada. Spain

<sup>6</sup>Internal Medicine Unit. Hospital Universitario San Cecilio. Granada. Spain

### Article history

Received: 24 October 2018; Revision Requested: 17 December 2018; Revision Received: 3 February 2019; Accepted: 6 February 2019

Sir,

Gastrointestinal tract is commonly affected in disseminated aspergillosis that initiates as lung disease and spreads hematogenously, but primary gastrointestinal aspergillosis has seldom been reported [1, 2]. *Aspergillus* spores do not survive under unfavourable conditions in the gastrointestinal tract, unless gastrointestinal mucosa is disrupted like in large ulcers in chemotherapy-related mucositis in neutropenic patients [1].

We present the clinical case of a 73-year-old woman diagnosed with celiac disease 9 years earlier, on chronic treatment with lansoprazole for hiatal hernia and untreated *Helicobacter pylori*. She started with diffuse abdominal pain and constipation and several explorations were performed: a colonoscopy that was normal; an abdominal computed tomography (CT) that showed dilation of small bowel loops suggestive of an obstructive process; and an enteroscopy that took a biopsy of jejunum that showed intestinal mucosa with intraepithelial lymphocytosis and granulation tissue with extrinsic large bacterial and hyphae aggregates. The patient started thereafter with blood-stained watery diarrhea and was finally initiated with 40 mg daily oral prednisone for 5 weeks for clinical suspicion of inflammatory bowel disease. She was then readmitted to the hospital and a resection of the obstructed ileal loop was performed and sent for a pathological study that reported an ulcerative mucosa and necrotizing granulomatous inflammation. *Mycobacterium tuberculosis* PCR was negative.

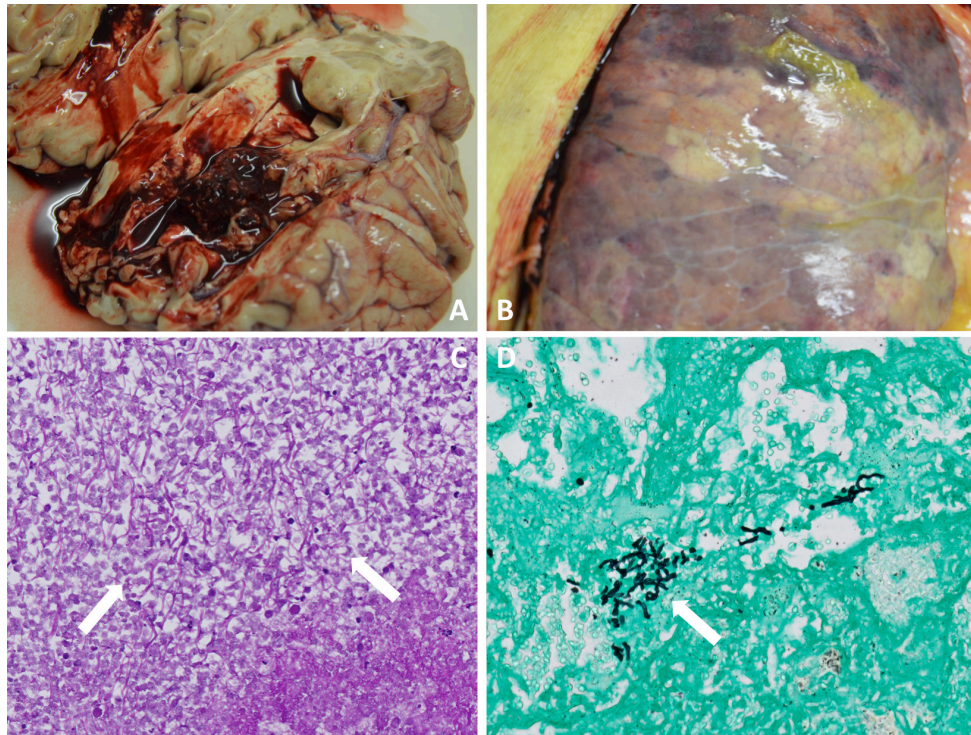
The patient suffered a confusional syndrome and acute right hemiparesis. A brain-CT scan was performed, showing an extensive hypodense area in left basal nuclei, external and internal capsules with cerebral edema. A brain-magnetic resonance imaging (MRI) scan suspected a brain tumor with severe

vasogenic edema as the first possibility. A stereotaxic biopsy of the lesion was consistent with an acute abscess. Cultures for bacteria and fungi, and *M. tuberculosis* culture and PCR were all negative but the patient was empirically started on linezolid, rifampin, isoniazid, and meropenem to treat both bacteria and mycobacteria possibilities. Brain abscess biopsy samples were sent to our referral laboratory and yielded a positive result for *Aspergillus fumigatus* PCR, and negative results for *Aspergillus terreus*, *Aspergillus flavus*, *M. tuberculosis*, *Tropheryma whipplei*, *Acanthamoeba*, *Toxoplasma gondii*, and *Leishmania* spp. Thus the treatment was changed to intravenous voriconazole and liposomal amphotericin B. The possibility of a surgical intervention was ruled out because of the severe deterioration of the patient. The patient progressively worsened and finally died from respiratory failure. A necropsy was performed reporting a hemorrhagic, necrotizing and diffuse bilateral pneumonia, a hemorrhagic and necrotic left parieto-temporal brain lesion and a necrotic granulomatous inflammation in ileum and jejunum with a lymphadenopathic conglomerate. Hyphae aggregates were found in all affected tissues (figure 1). *A. fumigatus* PCR were positive in brain, jejunum and lung samples. Definitive diagnosis: disseminated aspergillosis.

Risk factors for invasive aspergillosis (IA) include: prolonged neutropenia, allogenic hematopoietic stem cell transplant, solid organ transplant recipients, corticosteroid use, advanced AIDS, and those with chronic granulomatous disease [3]. Meersseman reported a 6.3% of patients with IA not fitting these classical risk factors; some of them could be explained just because they were receiving corticosteroids [4].

Corticosteroids impair macrophage killing of *Aspergillus* spores and mononuclear cell killing of *Aspergillus* hyphae. Meersseman has suggested that even a 3-week course of corticosteroids could be an additional risk factor for IA in the setting of previous lung disease or critically ill patients [4]. Tramsen also demonstrated in vitro that methylprednisolone significantly increases the rate of apoptosis, decreases the rate of proliferation of anti-*Aspergillus* TH1 cells, and reduces IFN- $\gamma$

Correspondence:  
Emilio Guirao-Arrabal.  
Infectious Diseases Unit. Hospital Universitario San Cecilio. Avenida de la Investigación, s/n.  
18016 Granada. Spain.  
E-mail: emilio.guirao@gmail.com



**Figure 1** | A: Necrotizing-hemorrhagic brain lesion (macroscopic view); B: Augmented consistency and hemorrhagic areas in the surface of the right lung (macroscopic view); C: Periodic acid-schiff staining demonstrating hyphae aggregates (arrows); D: Lung tissue with hyphae aggregates (Grocott's methenamine silver stain) (arrow).

production, which play a key role in *Aspergillus* infection control [5].

Disseminated aspergillosis usually originates in the lung but primary gastrointestinal aspergillosis has also been reported. The sequence of events in our patient led us to think that a primary gastrointestinal aspergillosis was a possibility but we could not rule out a primary pulmonary infection that subsequently spread to the jejunum, brain and so on. We cannot prove whether a pulmonary or a jejunal infection originated a disseminated aspergillosis in our patient but both options are plausible.

Although treatment with corticoids could explain the extension to other organs of a possible primary pulmonary or gastrointestinal aspergillosis in our patient, it is not clear why she initially developed this process. Proton pump inhibitor treatment might have inhibited gastric acid production and decreased the degradation of *Aspergillus* spores, but the invasion of the small intestine could only be explained by the presence of previous mucous lesions in the intestinal mucosa probably related to the *Helicobacter pylori* infection. Primary intestinal aspergillosis has been reported in the context of intestinal mucous barrier disruption specially by chemotherapy-related mucositis [1, 2]. Our patient had no risk factors to

develop a primary pulmonary aspergillosis but the respiratory tract can be colonized even in healthy individuals.

An interesting aspect is that the diagnosis could not be made until the brain biopsy was sent for a PCR analysis. The anatomopathological findings of aspergillosis could probably differ between immunosuppressed and non-immunosuppressed patients treated with corticosteroids. Some murine models have found differences between both processes in invasive pulmonary aspergillosis. Balloy et al found an exacerbated inflammatory response in mice treated with corticosteroids, leading to high levels of polymorphonuclear cell recruitment. These exacerbated inflammatory response led to large foci of pneumonia and exudative bronchiolitis with small number of *A. fumigatus*. In contrast, numerous hyphae of *A. fumigatus*, and few bronchiolitis and diffuse pneumoniae were observed in chemotherapy-treated mice [6]. These authors also found low levels of galactomannan in corticoids-treated mice. Accordingly, our patient had a negative galactomannan determination.

Our patient developed an initial gut aspergillosis and a progressive disseminated and fatal infection. It can be deduced that the treatment with corticosteroids triggered the rapid progression of the infection. To our knowledge this is the first case of a so severe presentation in a non-immunosuppressed

patient being the corticosteroid treatment the only known risk factor that could possibly promote dissemination of the infection.

## FUNDING

None to declare

## CONFLICT OF INTERESTS

The authors declare no conflicts of interest.

## REFERENCES

1. Eggimann P, Chevolet J-C, Starobinski M, et al. Primary invasive aspergillosis of the digestive tract: report of two cases and review of the literature. *Infection* 2006; 34:333–8. doi: 10.1007/s15010-006-5660-0
2. Kontoyiannis DP, Mathur M, Chen Y-B, et al. Case records of the Massachusetts General Hospital. Case 13-2014. A 41-year-old man with fever and abdominal pain after stem-cell transplantation. *N Engl J Med*. 2014; 370:1637–46. doi: 10.1056/NEJMcp1305994
3. Patterson TF, Thompson GR, Denning DW, et al. Practice guidelines for the diagnosis and management of aspergillosis: 2016 update by the infectious diseases society of America. *Clin Infect Dis*. 2016; 63:e1–e60. doi: 10.1093/cid/ciw326
4. Meersseman W, Vandecasteele SJ, Wilmer A, et al. Invasive aspergillosis in critically ill patients without malignancy. *Am J Respir Crit Care Med*. 2004; 170:621–625. doi: 10.1164/rccm.200401-0930C
5. Tramsen L, Schmidt S, Roeger F, et al. Immunosuppressive compounds exhibit particular effects on functional properties of human anti-Aspergillus T<sub>H</sub>1 cells. *Infect Immun*. 2014; 82:2649–2656. doi: 10.1128/IAI.01700-14
6. Balloy V, Huerre M, Latgé J, et al. Differences in patterns of infection and inflammation for corticosteroid treatment and chemotherapy in experimental invasive pulmonary aspergillosis. *Infect Immun*. 2005; 73:494–503. doi: 10.1128/IAI.73.1.494-503.2005