



Case report

Undiagnosed chicken meat aspiration as a cause of difficult-to-ventilate in a boy with traumatic brain injury



Nazhan Afeef Mohd Ariff^a, Mohd Zulfakar Mazlan^{a,*}, Mohd Erham Mat Hassan^a, Praveena A/p Seevaunnamtum^a, Wan Fadzlina Wan Muhd Shukeri^a, Nik Abdullah Nik Mohamad^a, Shamsul Kamalrujan Hassan^a, Kamaruddin Jaalam^a, Mohamad Hasyizan Hassan^a, Sanihah Che Omar^a, Chandran Nadarajan^b, Irfan Mohamad^c

^a Department of Anaesthesiology and Intensive Care, Universiti Sains Malaysia Health Campus, 16150, Kota Bharu, Kelantan, Malaysia

^b Department of Radiology, Universiti Sains Malaysia Health Campus, 16150, Kota Bharu, Kelantan, Malaysia

^c Department of Otorhinolaryngology - Head & Neck Surgery, Universiti Sains Malaysia Health Campus, 16150, Kota Bharu, Kelantan, Malaysia

ARTICLE INFO

Keywords:

Foreign body
Aspiration
Chicken meat
Difficult ventilation

ABSTRACT

Introduction: Bronchoscopy is a commonly used procedure in the context of aspiration in the Intensive Care Unit setting. Despite its ability to remove mucus plug and undigested gastric contents, aspiration of gastric content into the trachea is one of the most feared complications among anesthesiologist.

Discussion: The scenario is made worst if the aspiration causes acute hypoxemic respiratory failure immediately post intubation. However, in the event of desaturation, the quick decision to proceed with bronchoscopy is a challenging task to the anesthesiologist without knowing the causes.

Case presentation: We present a case of a 12-year-old boy who had a difficult-to-ventilate scenario post transferring and immediately connected to ventilator in operation theatre (OT) from portable ventilator from the emergency department. She was successfully managed by bronchoscopy.

Conclusion: Special attention should be given to the difficult-to-ventilate scenario post intubation of traumatic brain injury patient prior to operation. Prompt diagnosis and bronchoscope-assisted removal of foreign body was found to be a successful to reduce morbidity and mortality.

1. Introduction

Difficult ventilation commonly occurs in the Intensive Care Unit (ICU) amongst patients with severe acute exacerbation bronchial asthma, Acute Respiratory Distress Syndrome (ARDS) and aspiration pneumonia. However, the occurrence of such cases in the operation theatre is extremely rare and potentially fatal. The most common causes are blockage of the endotracheal tube (ETT) with thick secretion and bronchospasm due to allergic reaction to drugs. However other life threatening condition such as foreign body aspiration, tension pneumothorax, acute pulmonary edema, and endobronchial intubation need to be excluded. The bronchoscopy-assisted removal of foreign body has 99.9% success rate [1]. However the indication of bronchoscopy need to be well justified prior to the procedure to avoid life-threatening complication of bronchoscopy. Most of the complication occurs during emergency procedure and it was associated with prolonged duration, presence of dense granulation tissue and types of foreign body such

prayer beads and ball point pen lid [2]. Therefore the bronchoscopy procedure needs to be performed by trained personnel [2].

2. Case report

A 12-year-old boy weight 40 kg with a history of childhood bronchial asthma had involved in a motor vehicle accident and was found unconscious by the road side. He was diagnosed as severe traumatic brain injury with traumatic subarachnoid hemorrhage and interhemispheric subdural hemorrhage. The Glasgow Comma Scale (GCS) on arrival at Emergency Department was E₁V₁M₃ both pupils were 2mm reactive. He was intubated following Intravenous (IV) Fentanyl 50mcg, IV Midazolam 2mg and IV Suxamethonium 50mg with Endotracheal Tube (ETT) 6.0mm internal diameter (ID), anchored at 16cm. He was sedated and ventilated and his vital signs were stable. The intubation procedure was uneventful. The chest radiograph showed bilateral heterogeneous opacities at the middle and lower zones at both sides of the

* Corresponding author. Department of Anesthesiology and Intensive Care, School of Medical Sciences, Health Campus, Universiti Sains Malaysia, 16150, Kubang Kerian, Kelantan, Malaysia.

E-mail address: zulfakar@usm.my (M.Z. Mazlan).

<https://doi.org/10.1016/j.rmcr.2018.01.001>

Received 7 December 2017; Received in revised form 31 December 2017; Accepted 3 January 2018

2213-0071/ © 2018 The Authors. Published by Elsevier Ltd. This is an open access article under the CC BY-NC-ND license (<http://creativecommons.org/licenses/by-nc-nd/4.0/>).

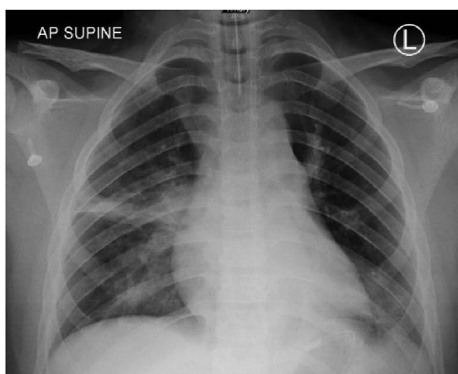


Fig. 1. Chest radiograph before bronchoscopy showed an intubated patient with hyperlucency of the left hemithorax with segmental collapse of the left lower lobe. No radioopaque lesion noted within the bronchus. There were consolidative changes in the perihilar region of the right middle and lower zones.

lungs (Fig. 1). He was subjected for urgent frontal craniotomy.

In the operation theatre, IV Rocuronium 50mg was given. Upon connecting to the ventilator with Volume Control (VC) mode, the generated tidal volume was only at 200ml with poor chest compliance. On auscultation, there was reduced air entry on the left side with minimal rhonchi with basal crepitation. There were a lot of food particles presence and required 5 times suctioning's until the secretion is able to suck it out. The SpO₂ had improved from 80% to 95% after suctioning with generated tidal volume of 250ml (4ml/kg). However it was not sustainable and the patient desaturated again to 80%.

An urgent bronchoscopy was ordered to exclude the possibility of aspiration material blocking the airway. The ETT was change to a size 7.0mm ID for adult bronchoscope to be able to pass through. The grasper was used to remove the food chunk. The adult bronchoscopy size 5.5mm was introduced and there was a chicken meat about 3 cm × 1 cm noted and removed from the left main bronchus near the carina (Fig. 3). The foreign body was then removed and the saturation picked up immediately to 100%. Throughout the procedure the patient was stable hemodynamically.

The ventilation immediately improved. The operation went smoothly and the patient was sent to the Neuro Intensive Care Unit post-operatively for weaning. Intravenous Dexamethasone 0.2 mg/kg for three doses was given to him prior to extubation. The repeat chest radiograph post-operatively showed increased in broncho vascular markings with minimal heterogeneous opacity at the right middle zone (Fig. 2). He was then discharged to the general ward on the subsequent

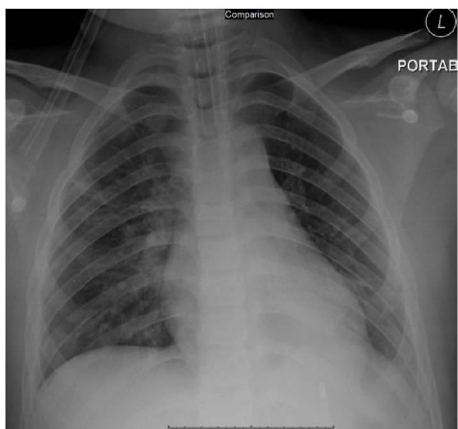


Fig. 2. Chest radiograph post-bronchoscopy showed improvement of the air trapping in the left hemithorax evidence by reduction of the hyperlucency. There is also increase aeration of the left lower lobe. Consolidative changes in the perihilar region of bilateral lower and middle zones.

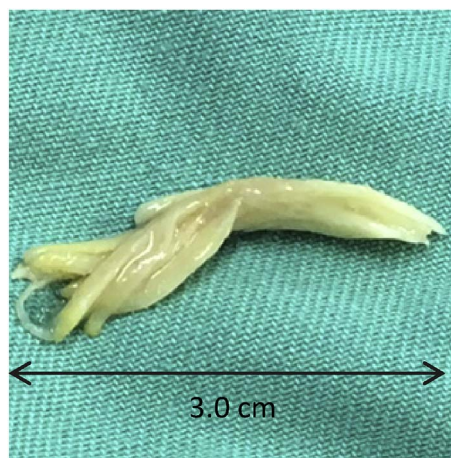

Fig. 3. The piece of chicken meat removed via bronchoscope.

day and to home after one week of hospitalization.

3. Discussion

Difficult ventilation is defined as inability to maintain good oxygenation by trained anesthesiologist. It can be further divided into cannot ventilate during mask ventilation and cannot ventilate via endotracheal tube. The causes of difficult ventilation in emergency setting operation theatre include bronchospasm, anaphylaxis, foreign body aspiration, tension pneumothorax, and pulmonary edema. In an intubated patient with high peak airway pressure, the kinked, blocked ETT or circuit should be added in the list and excluded immediately following desaturation of SpO₂.

Aspiration of foreign body such as food particles is difficult to diagnose without history and typical symptoms of obstructed airway in a ventilated patient. Moreover, the chest radiograph can be normal in 27% of the cases [3]. The common finding on chest radiograph in a patient with suspected foreign body aspiration was air trapping 47%, radiopaque foreign body 16%, atelectasis 9%, pneumonia infiltrates 4% and pneumomediastinum 1% [3]. Undiagnosed aspiration will results in aspiration pneumonitis or aspiration pneumonia eventually lead to ARDS [4].

In this situation, a quick and prompt decision is required to avoid tissue hypoxia. The team has to be informed and crisis needs to be declared. In our case, the patient was given 100% oxygen however the condition was not improved. The patient circuit was disconnected from the ETT to release the auto peep. The patient was given 6 puff of MDI salbutamol looking at the possibility of bronchospasm in view of no air entry on both side of the lung upon auscultation. Upon manual ventilation, the patient saturation still dropping and prompt decision to change the ETT was commenced. There was no ETT blockage to suggest. There was still no air entry on both sides of the lungs despite of new ETT.

Clinically the patient looked cyanosed as the saturation was still below 70% for almost 5 minutes. At that time, tension pneumothorax, pulmonary edema and severe anaphylaxis cannot be ruled out. In view of persistent desaturation and unable to maintain saturation above 88%, the decision was to proceed with urgent bronchoscopy.

The presence of foreign body obstructing the airway and impairing ventilation can occur at any time either in intensive care setting or in operation theatre. The decision to perform bronchoscopy can be crucial yet controversial. It needs to be etiology driven and action must be taken immediately [5]. Aspiration of foreign body is uncommon but can possibly cause death. In emergency cases, the success rate of foreign body removal by bronchoscope can be as high as 90% if it was diagnosed accurately [6,7]. However 2.5% of the cases in which the foreign

body more in a peripheral location need thoracotomy for their removal [4]. Most of the foreign body was found mainly at the right (33%) and left (27%) main bronchus [1]. In our case, the foreign body was found at the left main bronchus. This is possible because of the transportation and positioning prior to the operation.

The types of foreign body can be divided into radio opaque and radiolucent. The most common radiolucent foreign body reported were nut (36%), seeds (28%) other types of food (13%), plastic object, bean, popcorn, wood and crayon [1]. Therefore normal radiograph findings could not rule out the foreign body. Removal of foreign body via bronchoscope is not without complication. The most serious complication that has been reported was uncontrolled bleeding, lacerated trachea and lacerated vocal cord [1]. Apart from bronchoscopy technique removal of foreign body; the use of bronchial blocker tube has been reported to be used along the fiberoptic bronchoscope as an adjunct [7]. Undiagnosed or missed diagnosed foreign body aspirate can be detrimental as hypoxia can lead multiple organ sequelae and among them is cardiac arrest [8].

In our case, the period of hypoxia was brief and was managed early. Luckily the patient recovered and extubated well post operatively in the intensive care unit. Weaning of ventilation post aspiration of foreign body depend on several prerequisites. For example, the risk of recurrent chest infection, recurrent lung abscess, asphyxia or worse, death can be delayed as the result of chemical pneumonitis or delayed chest infection due to the acidity of the aspiration of gastric content or particulate aspiration that is difficult to be removed even by bronchoscope. ⁷ If there are no signs of lung injuries or infection, immediate or rapid lung recovery may take place and patient can be weaned off from the ventilator support immediately just after 24 hours as in our case.

4. Conclusion

Foreign body aspiration needs to be considered as one of the causes of difficult-to-ventilate scenario intraoperatively. Prompt diagnosis and removal of chicken meat foreign body is essential to reduce morbidity and mortality. Bronchoscope-assisted removal of foreign body was found to be successful.

Conflicts of interest

None.

Source of funding

This research did not receive any specific grant from funding agencies in the public, commercial, or not-for-profit sectors. However, the publication fee is funded by USM short term grant 304/ppsp/61313186.

Declaration and verification

This case report has not been published previously, is not under consideration for publication elsewhere, and has been approved for submission by all authors and the institutional affiliate.

Appendix A. Supplementary data

Supplementary data related to this article can be found at <http://dx.doi.org/10.1016/j.rmcr.2018.01.001>.

References

- [1] J.T. Zerella, M. Dimler, L.C. McGill, K.J. Pippus, Foreign body aspiration in children: value of radiography and complications of bronchoscopy, *J. Pediatr. Surg.* 33 (11) (1998 Nov 1) 1651–1654.
- [2] A.O. Ciftci, M. Bingöl-Koloğlu, M.E. Şenocak, F.C. Tanyel, N. Büyükpamukçu, Bronchoscopy for evaluation of foreign body aspiration in children, *J. Pediatr. Surg.* 38 (8) (2003 Aug 31) 1170–1176.
- [3] H.K. Tan, K. Brown, T. McGill, M.A. Kenna, D.P. Lund, G.B. Healy, Airway foreign bodies (FB): a 10-year review, *Int. J. Pediatr. Otorhinolaryngol.* 56 (2) (2000 Dec 1) 91–99.
- [4] K. Raghavendran, J. Nemzek, L.M. Napolitano, P.R. Knight, Aspiration-induced lung injury, *Crit. Care Med.* 39 (4) (2011 Apr) 818.
- [5] O. Soysal, A. Kuzucu, H. Ulutas, Tracheobronchial foreign body aspiration: a continuing challenge, *Otolaryngol. Head and Neck Surg.* 135 (2) (2006 Aug) 223–226.
- [6] O.A. Abdulmajid, A.M. Ebeid, M.M. Motaweh, I.S. Kleibo, Aspirated foreign bodies in the tracheobronchial tree: report of 250 cases, *Thorax* 31 (6) (1976 Dec 1) 635–640.
- [7] T. Paradis, M. Wollenberg, B. Tieu, Extraction of a large central airway foreign body using flexible bronchoscopy combined with an endobronchial blocker, *Case Rep Surg* 2016 (2016 May 4).
- [8] M. Kashif, H.R. Talib Hashmi, M. Khaja, Early recognition of foreign body aspiration as the cause of cardiac arrest, *Case Rep Critical Care* 2016 (2016 Feb 23).