

Structural grafts and suture techniques in functional and aesthetic rhinoplasty

Abstract

Rhinoplasty has undergone important changes. With the advent of the open structure approach, requirements for structural grafting and direct manipulation of the cartilaginous skeleton through suture techniques have increased substantially. The present review analyzes the current literature on frequently referenced structural grafts and suture techniques. Individual techniques are described and their utility is discussed in light of available studies and data.

Keywords: rhinoplasty, grafts, transplants, augmentation, suture techniques

Holger G. Gassner¹

1. Plastische Gesichtschirurgie, Universitätsklinik und Poliklinik für Hals-Nasen-Ohrenheilkunde, Kopf- und Halschirurgie, Universität Regensburg, Germany

1 Introduction

With the advent of the open technique, rhinoplasty has undergone tectonic changes. Most physiologic, biomechanical and aerodynamic implications of the open approach differ so substantially from the endonasal technique that it appears justified to categorize open rhinoplasty as a different operation rather than a different surgical approach. More complete dissection, disruption of skeletal support mechanisms, and postsurgical scar formation call for a reconstructive rather than corrective approach to the open procedure. Reconstruction of the skeletal support is almost uniformly achieved by suture and grafting techniques, and the emergence of a large number of publications on such techniques has paralleled a shift from closed to open structure rhinoplasty in recent years.

The author has been asked to provide an overview over the current state of science and literature on established suture and grafting techniques. Specifically, techniques applied in rhinoplasty

- to alter the external contour of the nose,
- to modify its skeletal support, and
- to address the function of the nasal valves

are to be addressed. Techniques and maneuvers primarily associated with septoplasty and reconstructive techniques after tissue loss are to be excluded. Emphasis is to be placed on presentation and discussion of recent developments and currently established techniques, while a detailed analysis of the origins and historical developments of the various techniques would be beyond the scope of this publication.

2 Graft sources

The quest for the ideal grafting material in rhinoplasty is as old as the operation itself. Features of an optimal material would include:

- Biocompatibility, minimal risk of immunologic response
- Structural resilience and recoil physiologic and stable over time
- Easily availability in abundant volume
- Minimal cost
- No donor site morbidity
- Availabilities in preformed shapes

Five major categories are used to differentiate the source of the graft: Autografts from the same individual, isografts from a monozygotic twin, allogenic transplants (synonyms: allograft, homograft) from another donor of the same species, xenografts from a different species, and alloplastic or synthetic grafts made of non biological material. The important distinction between the terms allogenic transplant (allograft) and alloplastic material should be noted [1], [2], [3].

2.1 Autografts

2.1.1 Septal cartilage

Septal cartilage is the most frequently used autograft in rhinoplasty for its ease of harvest, ready availability, straight and stable structure [4], [5]. Compositional analysis indicates it consists of 78% water, 8% collagen, 3% sulphated glycosaminoglycan and contains 25 mio cells per gram [6]. Its biomechanical properties have been studied extensively, including modulus of elasticity [7], strength of lining layers [8], and its predictable warping effect after scoring [9], [10]. Approaches for harvest in-

clude the hemitransfixion, full transfixion and open approach. Methods of preparing sliced, diced, split and otherwise fashioned grafts for rhinoplasty are discussed in the respective sections below.

2.1.2 Conchal cartilage

Conchal cartilage frequently represents the first alternative graft source for a nose depleted of septal cartilage. Its advantages include low morbidity, relatively large graft volume and resistance to resorption [11], [12], [13]. Draw backs comprise its tendency to calcify with more advanced age and its unfavourable three dimensional shape. While the cymba conchae provides a relatively straight and flat graft, the remainder of the concha is more distorted and thus not ideally suited for straight applications. The entire concha may be straightened by measured scoring of the transplant and suture-fixation of a PDS foil, as illustrated in Figure 1. Approaches for harvest include an anterior incision along the postauricular sulcus of the conchal base and an incision along the retroauricular sulcus.

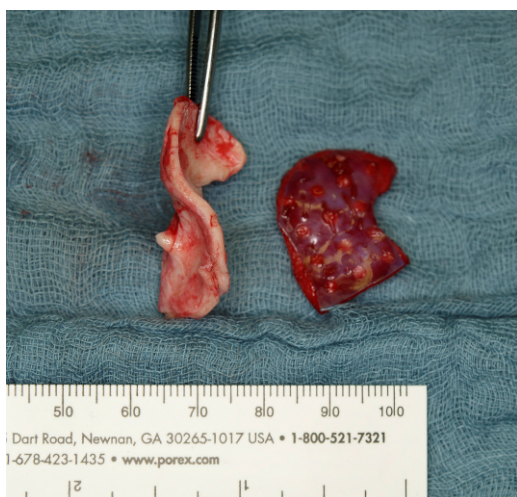

Figure 1: PDS foil is utilized to straighten curved conchal cartilage (right); unprepared contralateral cartilage shown on the left.

2.1.3 Composite grafts

Composite grafts consist of two or more types of tissue. Koenig described the use of composite grafts harvested from the ear, typically helical rim or cymba conchae [14]. The anterior skin is usually left adherent to the concave aspect of the graft. Closure may be primary or through a posterior auricular skin island flap. Indications include alar retraction, alar notching, external nasal valve collapse, and asymmetries including cleft rhinoplasty [15]. Constantian reviewed 100 revision rhinoplasties with implantation of conchal composite grafts in different orientations along the alar rim. Cosmetic outcome was favourable, and donor site morbidity was acceptable with 3/100 minor revisions required [16]. Rettinger et al. showed that transplantation of composite graft to the ala improves results in cleft rhinoplasty [17].

2.1.4 Tragal cartilage

The harvest of tragal cartilage is less frequently reported, although retrospective reports list multiple advantages, including its relative ease of harvest, minimal donor site morbidity and straight shape with dimensions up to 1.5x1.5 cm [18], [19], [20], [21]. Harvest is described through a tragal rim or a retrotragal incision, dissection in a subperichondrial and supraperichondrial plane and removal with the lateral tragal rim left intact to maintain projection.

2.1.5 Costal cartilage and bone

The use of costal cartilage to correct the saddle nose deformity was described by Mangold [22]. It is frequently used for revision of the cartilage depleted nose. Abundant volume, relative ease of harvest and the ability to spare septal cartilage are named as advantages. Based on long term retrospective data, Riechelmann et al. and others list autologous costal cartilage as the graft of choice to reconstruct severe and complicated saddle nose deformities [23], [24], [25]. Important limiting aspects of costal cartilage grafts include donor site morbidity and risk of warping. Multiple studies have shown that the risk of warping is reduced when larger and concentrically carved central segments of cartilage are utilized [26], [27], [28], [29], [30]. Further techniques to prevent warping include the use of an osseocartilaginous composite graft and the application of the laminated beam technique, as discussed in the section "3.6.2 Dorsal augmentation graft".

2.1.6 Calvarial bone grafts

The reconstruction of saddle nose deformities may call for a calvarial bone graft, which is typically harvested from the outer table of the temporal fossa. Advantages of this graft material include the lack of an externally visible scar and its remarkable resistance to resorption. Moreover it can be harvested with little risk. Romo et al. observed one seroma and no other complications in 17 patients with follow up between 1 and 5 years, other studies with long term follow up show a similar safety profile [31], [32]. Preferred donor areas include the temporal fossa, harvest is through a trichophytic incision. The outer table is removed with a sagittal saw after a trough has been drilled around the transplant.

2.1.7 Preserved autologous cartilage

Preservation of autologous cartilage may be utilized in order to avoid the morbidity of cartilage harvest in revisional procedures [33], [34], [35]. Methods of preservation include refrigeration, freezing, and storage in preservative solution [36], [37]. Wong et al. report preservation of septal cartilage in 70% isopropyl alcohol in over 300 primary rhinoplasties. These authors advocate use of the preserved grafts for non load bearing placement and to camouflage contour irregularities in revision surgery.

Guyuron compared 136 fresh grafts with 117 frozen in a saline and antibiotic solution. Success rates with a median follow up of 45 months were comparable between the two groups (87.5% fresh, 85.5% preserved, both groups were crushed at the time of implantation). These authors feel the use of preserved cartilaginous autografts is justified on the basis of their data. In many western countries important medicolegal aspects must be considered and the standards of hygiene and storage must be met before the use of autologous implants is considered.

2.2 Allografts

2.2.1 Irradiated rib

The use of irradiated rib grafts is discussed controversially. While some authors claim it is associated with higher rates of resorption and warping, a number of experimental and clinical studies suggest that irradiated and autologous rib grafts exhibit comparable complication rates. These data are discussed in the section "3.6.2 Dorsal augmentation graft".

2.2.2 Acellular cadaveric dermis

Acellular cadaveric dermis (Allo Derm, LifeCell Corporation, Branchburg, NJ, USA) is advocated for camouflage and augmentation. This soft material is harvested from cadavers and is available in various thicknesses and sizes. Its cellular and antigenic elements are removed in order to minimize the risk of infectious and immunologic complications. Experimental and initial clinical resorption rates up to 50% are reported. Delayed resorption appears not to be relevant [38], [39], [40], [41]. No report of severe virus or prion mediated infection has been identified in the western literature, although this remains a theoretical risk for all allogenic implants [42]. Alloderm is dried before packaging and requires rehydration before implantation. Sherris omits the rehydration and takes advantage of the easier handling characteristics when implanting the stiffer dried implant. Rehydration and softening then occur in vivo [43].

2.3 Xenografts

2.3.1 Lyophilized bovine pericardium

The use of xenografts, such as lyophilized bovine pericardium, is infrequently reported. Animal studies suggest usefulness for septal perforation repair and resorption rates comparable with other soft tissue implants [44], [45]. Its role for camouflage or augmentation in rhinoplasty is limited and usually reserved for cases in which autologous material is not easily available.

2.4 Synthetic material

2.4.1 Silicone

Silicone has largely been abandoned as an implant material in rhinoplasty in western countries. Few favourable studies have been increasingly outweighed by reports on complications, predominantly infection and extrusion [46], [47], [48], [49]. The extrusion rate of silicon appears to be twice that of Gore Tex[®] and Medpor[®], which have become the preferred choice for synthetic nasal augmentation material [50].

2.4.2 Expanded polytetrafluoroethylene (Gore Tex[®])

Gore Tex[®] is a microporous framework of polytetrafluoroethylene nodules and fibrils. This relatively soft and pliable white implant material is used in various thickness for camouflage and augmentation in rhinoplasty [51], [52]. Its average pore size of 22 µm allows for limited tissue ingrowth [53], [54]. Initial thickness is reduced in vivo by 29% [55]. The most important complication associated with Gore Tex[®] implants is infection, requiring removal. The incidence of this complication is reported in large series between 1.2% and 5.4%. Revision procedures are associated with higher infection rates than primary operations [56], [57]. A meta analysis of 769 cases identified infection in 2.6%. Preferred sites for implantation are the dorsum, lateral nasal sidewall and premaxilla. Implantation in mobile parts of the nose, and in areas with thin soft tissue cover may be associated with higher complication rates [58].

2.4.3 Polyethylene terephthalate (Dacron[®])

Dacron[®] or polyethylene terephthalate implants have been developed for use in cardiovascular surgery and are available in two variants. The "Cooley" fabric is a tight, nonresorbable multifilament sheet, "Mersilene" is the looser mesh form. The indications for these soft implants resemble those of Gore Tex[®] implants. In a retrospective review of rhinoplasty patients, infection rates with subsequent explantation of the material were reported in 6.6% of 136 patients for Dacron and 8.2% of 98 patients for Mersilene [59], [60]. In light of these data Gore Tex[®] may be a more preferable choice over Dacron[®] for implantation in rhinoplasty.

2.4.4 Porous polyethylene (Medpor[®])

Medpor (Porous polyethylene, Porex Surgical, Newnan, GA, USA) has been introduced in 1993 as an alternative synthetic grafting material in rhinoplasty [61]. An advantage over established synthetic materials, such as silicone, is its porous structure, which allows tissue integration [62], [63], [64]. Its use has been expanded to structural grafting of the mobile lower third of the nose [65], [66]. Critics claim that the relatively rigid structure of the

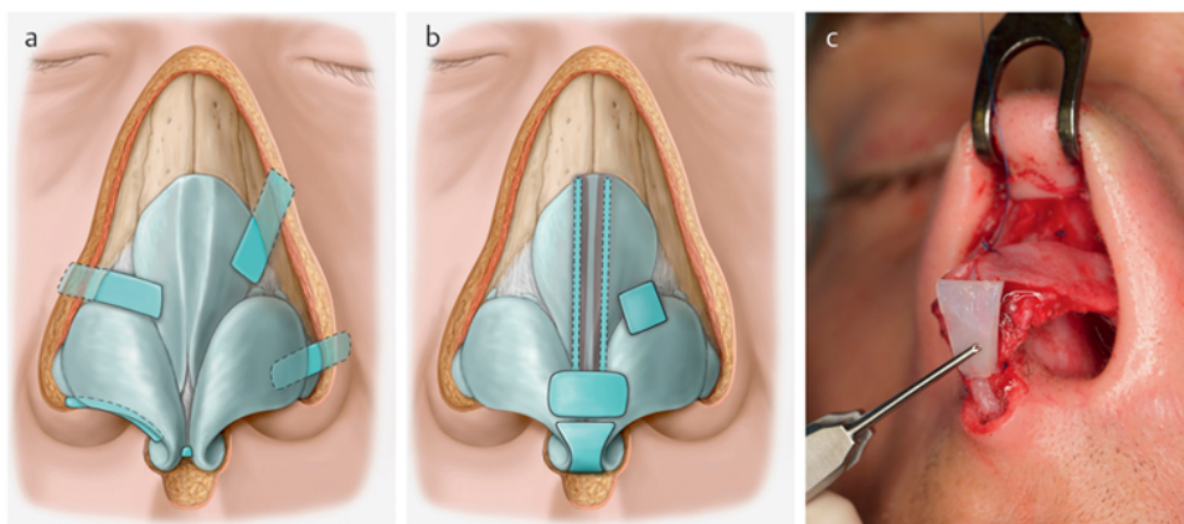


Figure 2: Overview over commonly placed structural grafts. a) from top to bottom: Vertical alar batten graft, horizontal alar batten graft, alar strut graft, alar rim graft, columellar strut graft. b) from top to bottom: Paired spreader grafts, cap graft, shield-type tip graft.

material predisposes it to extrusion, especially when implanted under thin soft tissue cover and in mobile parts of the nose [67]. Proponents argue that the lack of donor site morbidity, availability in preformed shape and good tissue compatibility make it a viable alternative with an acceptable extrusion rate. Peled et al. presented a meta analysis of over 4000 patients and compared silicone, Gore Tex® and MedPor® implants. Extrusion rate was 6.5% for silicone and 3.1% for the other two materials. These authors conclude that the use of Medpor implants is justified when autologous material is insufficient or unavailable [68].

2.4.5 Titanium

The use of Titanium for osteosynthesis in the craniofacial skeleton has shown long term stability with stable fixation. Its use for transplantation in the nose seems counterintuitive, especially in the mobile parts of the nasal tip. However unpublished data seem to suggest that implantation of a titanium device may be useful to correct nasal valve collapse, as described in the section “3.3.4 Titanium nasal valve implant” [69], [70].

3 Grafting techniques

Most grafting techniques presented in the following section represent modifications of techniques described by pioneers of rhinoplasty like Jacques Joseph. A discussion of all reported modifications would be beyond the scope of this paper. The author has made every effort to include the most frequent techniques in the literature. In general, autologous cartilage is the primary grafting material used, and the effects of different grafting material is only addressed if substantiated by good data.

3.1 Grafting techniques to reconstruct the base and pedestal

As Toriumi points out in his excellent discourses, the structural support of the pedestal or central column of the nose must be established before aesthetic contouring of the tip and functional correction of the valves occurs [71]. Detailed analysis of the length of the upper lip and caudal septum, the shape of the nasolabial angle and the length and structure of the medial crura is required for selection of the appropriate technique.

3.1.1 Columellar strut

The straight columellar strut graft, as included in Figure 2a, is placed between the medial crura and suture fixated to improve support. It may also straighten a too round columella and aid in modifying columellar show. The graft should not extend to the nasal spine to avoid a clicking sensation with motion, or it may be suture fixated to the nasal spine or a prespinal transplant for further stability and modification of the nasolabial angle [71]. An extended columellar strut may articulate with septocolumellar interposition grafts to better control tip rotation, as described in the section “3.3.6 Septocolumellar interposition graft”. Approaches include the closed interdomal and the open approach, dissection of a retrograde pocket through a hemitransfixion incision and an external approach through a stab incision at the base of the columella.

3.1.2 Caudal septal extension graft

Figures 3a–c show the effects of a caudal extension graft on columellar shape and tip projection. Indications for the caudal extension graft include a ptotic tip, short caudal septum, inadequate columellar show, acute nasolabial angle or a rounded columella [72]. The caudal extension graft is sutured side to side to the caudal

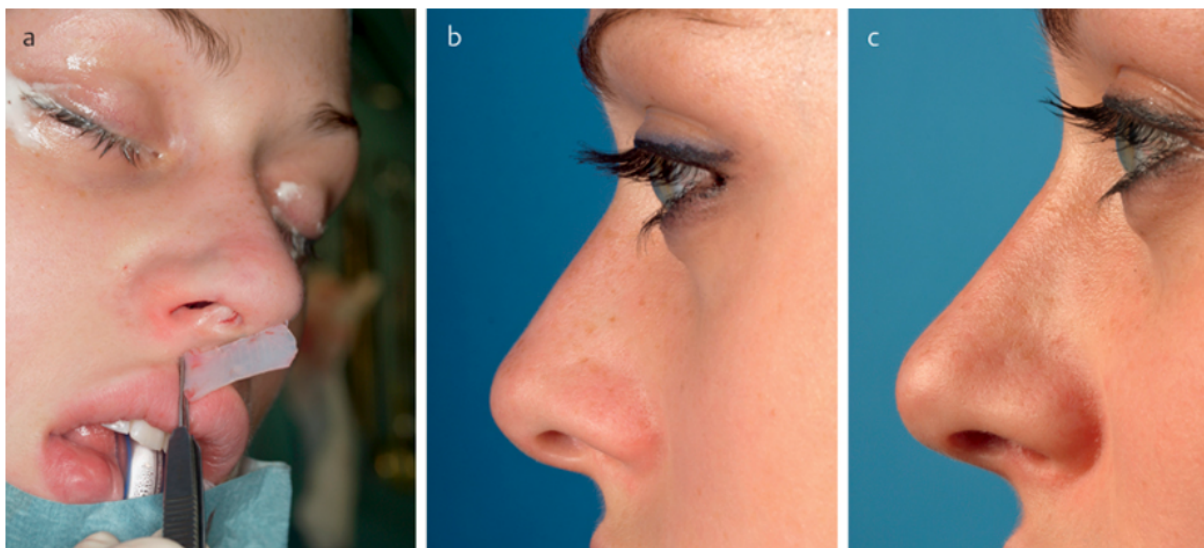


Figure 3: Possible effects of a caudal extension graft. a) Thinly shaped caudal extension graft of septal cartilage is sutured side to side to the caudal end of the septum and slides into an intercrural pocket. b) Preoperative image of rounded columella and slightly underprojected tip. c) Postoperative change resulting from placement of caudal extension graft.

septum and may be fixed to the convex side of a slightly deviated caudal end to correct minor deviations. Modifications include various degrees of overlap and different suture techniques. The graft may also be fixated end-to-end to the caudal edge of the septum and stabilized with extended spreader grafts [73], [74], [75]. The author prefers thinly shaped transplants to minimize columellar volume and optimize aesthetic outcome, as depicted in Figure 3a–c.

3.2 Grafting techniques to reconstruct the alar rim and external nasal valve

3.2.1 Alar rim graft

Alar rim grafts are placed in a pocket along the alar rim, as shown in Figure 2a. The placement of these grafts is nonanatomic, since they are situated in the typically cartilage-devoid fibromuscular alar soft tissues below the lower lateral cartilage. Indications for these grafts are both functional and aesthetic. As Toriumi points out, they may improve support for the external nasal valve and enhance contour by creating a defined ridge between the tip and alar lobule [76]. Measures of alar rim grafts have been reported in the range of 12 to 15 mm in length and 2 to 3 mm in width [77]. The author prefers curved grafts, if they can be crafted from deviated parts of the nasal septum or concha, as shown in Figure 4. Modifications of alar rim grafts may include substantially larger grafts and double- or triple-layered composite grafts to correct alar retraction. Prospective, randomized outcome trials on form and function of alar rim grafts have not been identified in the literature.

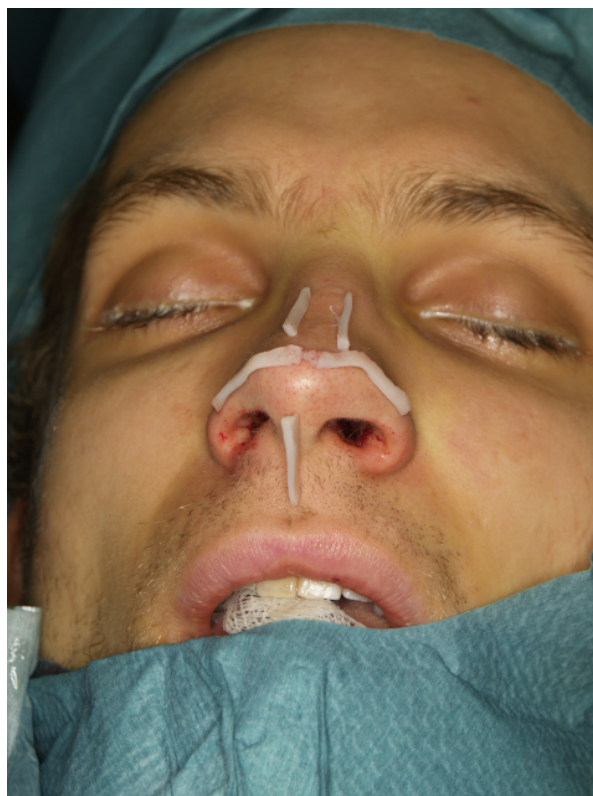

Figure 4: From top to bottom: Paired spreader grafts, alar rim grafts and a columellar strut graft, fashioned from septal cartilage. Note the curved alar rim grafts fashioned from a septal deviation.

3.2.2 The intercartilaginous graft

Gruber et al. describe an interpositional graft spanning from the caudal edge of the upper lateral cartilage to the cephalic aspect of the lower lateral cartilage. This graft, as depicted in Figure 2b may be placed to compensate for an over-rotated tip and retracted ala. It acts by pushing the lower lateral cartilage remnants into a lower, more

physiologic position. Care should be taken to free intervening scar tissue in the intercartilaginous area to allow for maximal distraction with placement of the graft. In a retrospective series of thirteen patients, ten satisfactory results and one requiring revision are reported; prospective data have not been identified in the literature [78]. This technique works particularly well when thinly shaved septal cartilage is fixated with triangular transcutaneous sutures to both the upper and lower lateral cartilages.

3.3 Grafting techniques to reconstruct the dysfunctional nasal valves and middle third

A clear cut anatomical distinction between the internal and external nasal valve makes didactic sense. However it must be noted that in clinical reality, a dysfunction of one or the other structure occurs rarely in isolation. Pathologies of the cartilaginous skeleton and surrounding soft tissues typically exhibit a mass effect and affect both structures, and so do techniques applied for their correction. In light of these considerations, no overzealous effort will be made in the following discussion to attribute specific techniques exclusively to the correction of one or the other nasal valve. Equally important to note is the important dual function of many techniques. Especially reconstructive techniques of the middle third of the nose affect form as well as function. Where relevant, both functional and aesthetic properties of these techniques are discussed in the following section.

3.3.1 Alar batten graft

Collapse predominantly of the internal nasal valve and alar pinching may be a result of overresection of the cephalic aspect of the lower lateral cartilage [79]. The alar batten graft has been described by Toriumi to correct these deformities [80]. Figure 2a depicts its placement, overlapping the caudal aspect of the upper lateral cartilage. In cases of severe valve collapse, the batten graft may extend past the bony rim of the piriform aperture for added stability and lateralization. In a retrospective review with a mean follow up of 5 years, Toriumi reported an improvement in nasal airway in 45/46 (98%) patients, other retrospective reports are equally favourable, prospective data were not identified [81]. One modification includes more substantial lateral overlap with the piriform aperture. We have reported a more vertical placement of the batten graft, based on the observation that the angle of the piriform aperture with the facial plane becomes more acute the higher the graft is placed. Care must be taken to shave the edges of the vertical batten graft paper thin to obviate visibility of the graft [82].

3.3.2 Alar strut graft

Gunter and André described the alar (or lateral crural) strut graft to correct the boxy nasal tip, malpositioned

lateral crura, alar rim retraction, alar rim collapse, and concave lateral crura. While the batten graft is placed on the outer surface of the lateral cartilages, the alar strut graft is suture fixated through an open structure approach to the undersurface of the lower lateral cartilage, as depicted in Figure 2b. This has an important theoretical biomechanical advantage, since the lower lateral cartilage is pushed outward and less volume should impact on the nasal valve area. After elevation of the vestibular skin, the graft is fixated to the undersurface of the lateral crus. In Gunter's retrospective review, 4 of 88 patients are reported with suboptimal functional or aesthetic results, one patient required revision [83]. André reported about 2/3 of patients with good functional and most patients with excellent cosmetic outcome [84].

The transvestibular approach, as described by Fuleihan, has been suggested as a less invasive alternative for placement of this graft. In the author's experience this approach has yielded excellent functional and aesthetic results with minimal dissection in properly selected patients, as depicted in Figure 5.

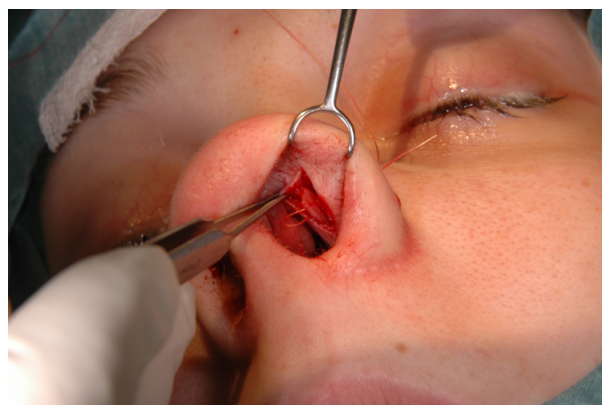


Figure 5: Placement of an alar strut graft through a transvestibular approach. The vestibular skin has been dissected off the undersurface of the lower lateral cartilage and an alar strut graft fashioned from septal cartilage is slipped into a pocket lateral to the piriform aperture and suture fixated with triangular mattress sutures.

3.3.3 Butterfly graft

Cook et al. popularized the butterfly graft to correct internal nasal valve deficiencies. This graft may be inserted through the open or the closed approach. It is placed over a groove in the anterior septum and suture fixated to the caudal edge of the upper lateral cartilages [85]. This fixation bends the graft in a convex fashion. The elastic properties of the graft are postulated to pull the upper lateral cartilages outwards and thus open the internal nasal valve. Cook et al. reported improved functional (90%) and cosmetic (89%) outcomes in a retrospective series of 90 patients [86]. Drawbacks of the butterfly graft include the risk of graft fracture and added volume over the anterior septal angle, which may interfere with both form and function.

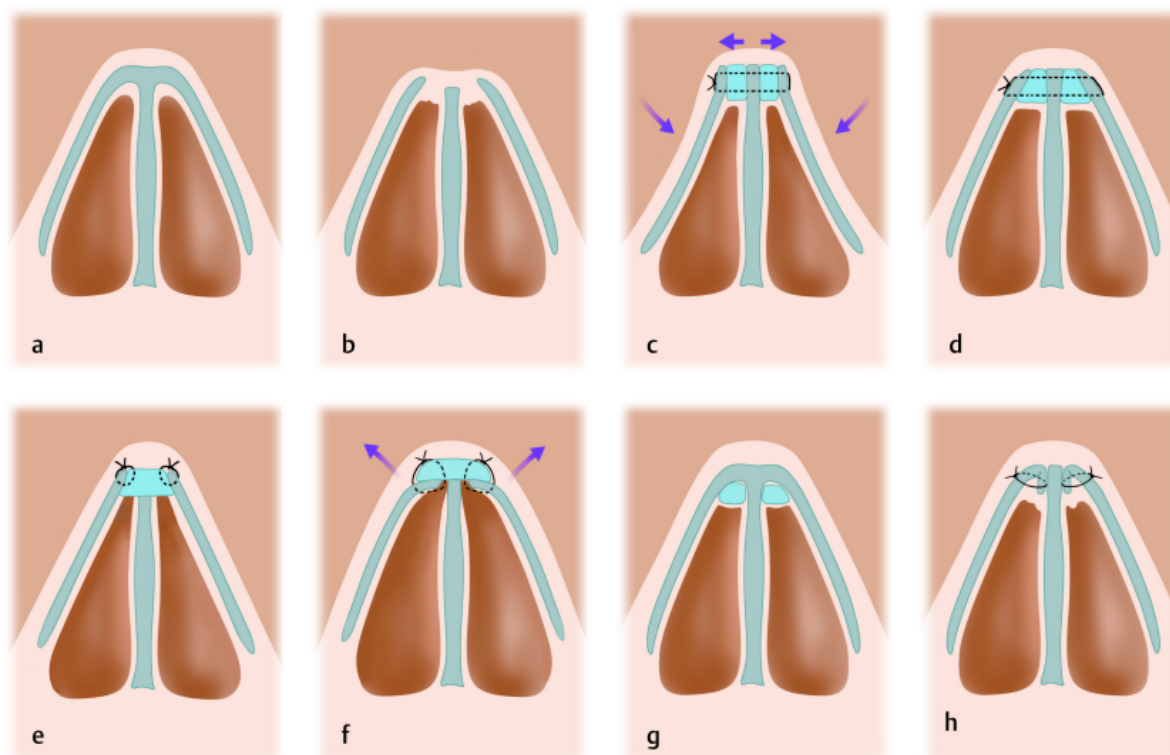


Figure 6: Various methods of middle vault reconstruction.

a) The upper lateral cartilages display a natural curvature at their transition to the septum. b) Separation of the upper lateral cartilage from the septum. c) Suture-fixation of a standard spreader grafts increases the nasal valve area, but reduces the nasal valve angle by rotating the upper lateral cartilages slightly inward. d) Spreader grafts with a trapezoid shape are better suited to reconstruct the nasal valve angle. e) Onlay spreader graft is suitable to correct nasal valve pathology and dorsal deficiencies at the same time. f) Modified dorsal onlay graft rotates upper lateral cartilages more markedly outward, but requires sufficient height of upper lateral cartilages for suture to the graft. g) Endonasal, submucosal placement of spreader grafts allows for correction of the middle third of the nose without separation of the upper lateral cartilage from the septum. h) Turn-in spreader graft utilizes medial most aspects of the upper lateral cartilage to fold on itself and act as spreader graft.

3.3.4 Titanium nasal valve implant

A Wengen et al. describe a titanium graft, which resembles the design of the butterfly graft. It is placed and suture fixated on top of the upper lateral cartilages. The concept of placing a rigid synthetic implant in the mobile part of the nose appears counterintuitive. However preliminary data seem to suggest that this implant may be well tolerated [69], [70]. Long term data are required to better assess these impressions.

3.3.5 Spreader graft

Proper reconstruction of the middle third of the nose is of paramount importance for the contour of the dorsum and the function of the nasal valves. Figure 6 depicts various grafting methods of the middle third. Spreader grafts are the most frequently reported graft placed in the middle third [87]. These rectangular grafts are sutured between the septum and the previously separated upper lateral cartilage, as depicted in Figure 2b, Figure 6a–c. For its straight and plane structure, septal cartilage is usually the preferred grafting material. Alternatives include other autologous cartilage and ethmoid bone [88]; the use of synthetic [89] and absorbable materials has

also been reported [90]. Its effect on the nasal valve area is two fold. The nasal valve area is widened by interposition of the graft, but the valve angle may also become more acute as the curved transition of the upper lateral cartilage with the septum becomes more parallel, as shown in Figure 6c. A spreader graft with a trapezoid cross section, as depicted in Figure 6d, restores the nasal valve angle in a more physiologic fashion, but this shape requires thicker cartilage, which is not consistently available. An elegant modification is the use of the upper lateral cartilage as an auto spreader graft. Instead of resecting the excess height of the upper lateral cartilage, this excess is scored and folded on itself, as depicted in Figure 6h [91]. André et al. describe the endonasal placement of a spreader graft in a submucosal pocket as detailed in Figure 6g. This technique does not require division of the upper lateral cartilage from the septum and is performed through the endonasal approach [92].

3.3.6 Septocolumellar interposition graft

Dyer et al. present the septocolumellar interposition graft, a longer version of a spreader graft, which is fixated in the typical fashion between the upper lateral cartilage and the septum. The septocolumellar interposition graft

is subsequently articulated with an extended columellar strut graft, either unilaterally or bilaterally. The length of the septocolumellar interposition graft may be varied to control tip rotation. This technique is in particular designed to lengthen the short nose and may be combined with additional tip grafting or camouflage techniques [93].

3.3.7 Onlay spreader graft and modified onlay spreader graft

In their excellent discourse on saddle nose deformities, Alsarraf and Murakami describe the onlay spreader graft [94]. As depicted in Figure 6e, the onlay spreader graft is an evolution of the established spreader graft. In order to more markedly correct the deficient dorsum and the collapsed valve, these authors position this horizontally oriented, boat shaped cartilaginous graft on top of the septum. The upper lateral cartilages are sutured side to side to the graft. This technique is excellently suited to reconstruct moderate saddle nose deformities with resultant valve dysfunction. If a sufficient height of the upper lateral cartilages is available, this technique may be modified to mattress-suture the upper lateral cartilages to the undersurface of the graft, thus rotating the upper lateral cartilages outward in an effort to further open the nasal valve angle [95].

3.4 Grafting techniques to correct the nasal tip

3.4.1 Shield type tip graft

Various grafting techniques to alter the shape of the nasal tip go back more than a century ago, and most currently utilized techniques represent modifications of long established maneuvers [96], [97]. The shield type tip graft has been reintroduced by Johnson and Toriumi with the increased popularity of the open structure rhinoplasty approach [98], [99]. This graft is suture fixated to the medial and intermediate crura of the lower lateral cartilages, as depicted in Figure 2b, c. It is usually fashioned from septum or other autologous cartilage, non-autologous materials are also described [100]. Its effects include modification of projection, rotation and tip definition. Associated complications include tip rigidity, migration and rotation of the graft. The term tombstone deformity describes a graft whose straight edges have become visible and resemble the appearance of a tombstone at the infratip lobule. Articulation of alar rim grafts with the corners of the shield graft has been suggested to soften contour and decrease visibility of the graft.

3.4.2 Extended columellar strut – tip graft

Pastorek et al. describe the endonasal placement of an extended columellar strut – tip graft to provide projection and to contour the nasal tip, as depicted in Figure 7. This elegant and minimally invasive technique is particularly suited to correct an overly rotated and underprojected

nasal tip. Even in cases of revision of a primary open rhinoplasty, this transplant may be placed endonasally and allows for efficient correction of the named deformities [101].

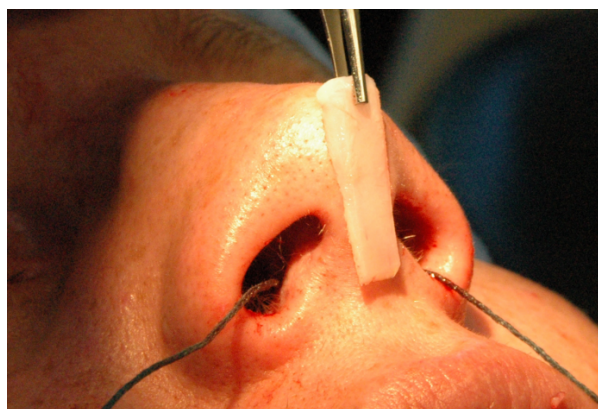


Figure 7: The extended columellar strut-tip graft is introduced into a pocket anterior to the medial crura and domes through a paracolumellar incision.

3.4.3 Cap graft

As shown in Figure 2b, the cap graft is placed on top of the domes with the intent to camouflage tip irregularities, decrease visible bifidity and increase projection. Asymmetries of tip contour can be corrected with asymmetrically shaped tip grafts. When only minor irregularities are to be corrected, soft grafts fashioned of fascia, perichondrium or crushed cartilage are utilized. Firmer grafts of autologous cartilage are precisely carved and the edges are very finely shaved to avoid contour show. These firmer grafts can generate a unitip appearance, which may produce an unnatural look, especially in thin skin patients [102].

3.5 Grafting techniques to camouflage dorsal contour irregularities

3.5.1 Fascia and SMAS grafts

Soft tissue grafts used to camouflage irregularities in rhinoplasty include deep temporal fascia, fascia lata and others. The use of deep temporal fascia is reported as a sole transplant or to cover cartilaginous and other grafts. Available clinical studies are limited by a lack of exact qualitative assessment criteria and other drawbacks of retrospective studies.

Reported resorption rates range around 20%, the use in primary rhinoplasty appears more predictable than in revision procedures [103], [104]. Baker showed that fascia retains its histological structure after implantation in humans [105].

The fibromuscular layer between the perichondrium and the subcutaneous fat of the nose has been referred to as the nasal SMAS [106]. Davis et al. advocate harvest of this layer in thick skin patients with poor tip definition. These authors report satisfactory long term graft preser-

vation when this tissue is reimplanted for camouflage [107].

3.5.2 Crushed, split, diced, and shaved cartilage

Crushed cartilage results from forceful compression of cartilage between flat surfaces or by treatment with a morselizing forceps. Reports on viability and resorption rate of crushed cartilage vary. Vervoerd-Verhoef et al. found only 10% to 30% of crushed chondrocytes to remain viable after reimplantation into rabbits [108]. Huizing reported more favourable resorption rates [109]. Rudderman et al. and other studies were consistent with Huizing's early findings and concluded that slight overcorrection is advisable to compensate for 20% to 30% volume-relevant resorption rates [110], [111], [112]. Cakmak et al. established reproducible criteria to stratify the degree of crushing into five categories. For instance, slightly and moderately crushed cartilage retain stability, while significantly and severely crushed cartilage bend with gravity. In an animal model, these authors showed that the degree of crushing correlates with short term viability, ranging from 55% for severely crushed cartilage to 90% for slightly crushed cartilage [113]. In a chart review by the same authors, the placement of 809 crushed cartilage grafts showed clinically relevant resorption for mildly or moderately crushed grafts in 2%, for significantly crushed grafts in 13%. In terms of placement, there was a non-significant trend towards more resorption over the dorsum than over the tip or sidewalls [114].

Shaved, split and diced cartilage grafts may be best suited to avoid the resorption that results at variable rates from crushing [115], [116], [117]. Careful splitting also increases reconstructive options and spares valuable septal cartilage. Excellent graft viability up to 100% of split cartilage is reported [114]. While shaved and split cartilage is preferred for these reasons, there are limitations to their use. Camouflage of irregularities, especially in the thin skin patient, calls for a softer and more pliable material.

Peer et al originally described the use of diced cartilage for dorsal augmentation. Interest in this method has resurged with the description of wrapping materials to better control its placement [118].

3.6 Grafting techniques to augment the nasal dorsum

3.6.1 Diced, wrapped cartilage

Erol et al. introduced the concept of diced, wrapped cartilage as a dorsal augmentation implant [119]. These authors use small fragments of autologous cartilage cut into cubicles of 0.5 mm to 1 mm width. The mass of diced cartilage is then wrapped in a single layer of Surgicel (Johnson & Johnson, New Brunswick, N.J.) and introduced through an endonasal incision into an adequately sized pocket over the dorsal deformity. The authors cite the ability to mold the implant in vivo as one of its major ad-

vantages and report favourable results in a large, retrospective series of patients. In an attempt to reproduce these results, Daniel observed a group of 22 patients augmented with the same technique. Daniel observed resorption in the majority of cases and halted this arm of their study. A subsequent group of patients augmented with diced cartilage wrapped in autologous temporalis fascia showed significantly improved results. This technique is illustrated in Figure 8. The authors were unable to identify a technical factor that could explain the differences between Erol's and their own results and recommend the use of deep temporal fascia for wrapping material as a conclusion of their study [120]. In another retrospective series, favourable outcomes are reported with Ergols technique, but with diced cartilage fashioned from irradiated homologous costal cartilage instead of autologous cartilage [121].

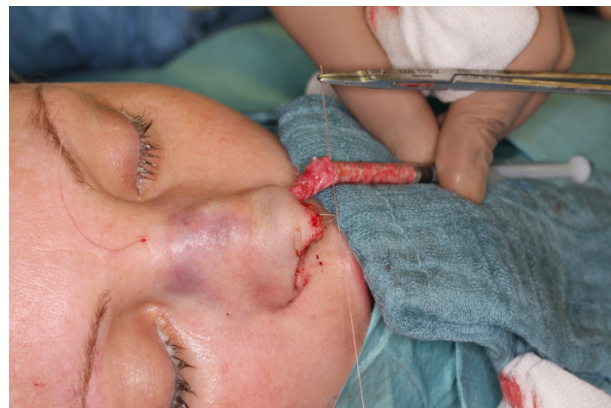

Figure 8: The modified “Turkish delight” graft is prepared: A tube of temporalis fascia is temporarily fixated over a cartilage filled syringe. The graft is subsequently completely introduced into the nose with the help of a guiding suture and filled with diced cartilage.

3.6.2 Dorsal augmentation graft

Severe saddle nose deformities frequently require augmentation with a solid block of cartilage and/or bone. The use of cartilaginous or osseocartilaginous rib grafts is frequently reported. As discussed in previous sections, warping is the main issue with this material.

Adams et al. showed that irradiation does not alter the rate of warping in vitro [122]. Murakami et al. present long term follow up data in a series of 18 patients. Warping occurred in 4 cases, but no resorption was observed [123]. Swanepoel and Fysh describe a remarkable technique of fashioning the dorsal implant from 2 mm strips of cartilage in a laminated fashion. These authors report no clinically evident warpage in 117 procedures over a 4 year period [124].

The transplant may also be fashioned from a composite graft of costal cartilage and bone, as shown in Figure 9. The osseous part may be screw fixated to a well prepared, osseoinductive recipient bed over the residual nasal bones. This reduces the risk of non-union, as shown by Sherris et al. [125]. The risk of warping of the graft is also minimized, as the effective length of cartilage susceptible

to warping is greatly reduced. Finally, the distal cartilaginous part of the rib graft is more flexible than a purely osseous graft, thus reducing the resulting stiffness of the nasal tip.

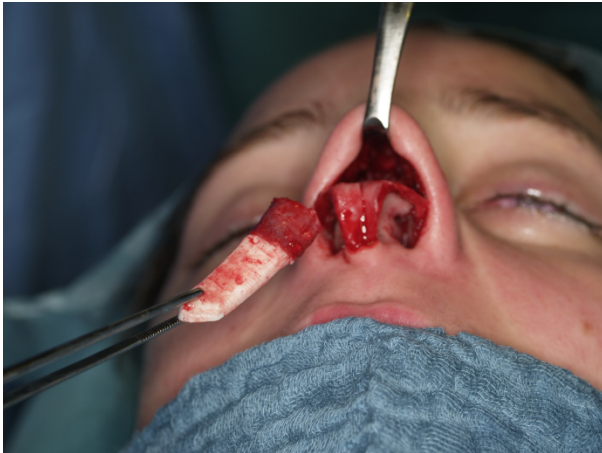

Figure 9: Composite graft of costal cartilage and bone is shaped as a dorsal implant. The osseous part may be screw fixated to an osseoinductive bed over the bony saddle. The limited length of the cartilaginous transplant reduces the risk of warping while maintaining some flexibility of the distal aspect of the graft.

The use of calvarial bone grafts avoids visible scarring over the chest. The graft itself is relatively thin and may require plate fixation to the glabellar bone for adequate tip projection. The resulting reconstruction becomes very rigid and is prone to fracture with trauma. Fabrication of an L-shaped dorsal implant by articulation with a columellar strut graft is frequently reported. Most authors prefer cartilage for the strut graft. They use permanent sutures and carve articulating links to lock the two grafts in place with each other.

Autologous material also seems to be preferred in the high risk patient. Congdon et al. report retrospective results in 13 patients who underwent saddle nose reconstruction for Wegener's granulomatosis. With a mean follow up of 59 months, 12/13 patients had a successful outcome, 2 revisions were required, one patient refused revision. Success of transplanted grafts was 5/6 of autologous rib, 3/4 of calvarial bone, 1/1 of composite auricular, iliac bone, conchal cartilage and septal bone, and 0/1 of irradiated rib and irradiated dura [126].

A vast number of alloplastic materials have been used historically for saddle nose reconstruction. Problems including extrusion and infection have resulted in abandonment of most materials. Modern compounds that have shown promising long term results include Gore Tex[®] and Medpor[®]. Extrusion with these materials in dorsal augmentation ranges around 3%. Emsen et al. compared results with autologous calvarial bone grafts in one centre with the results with alloplastic material in another. Of course, factors such as surgical technique and experience could not be controlled for. According to blinded assessments, overall aesthetic appearance was rated superior for the autologous graft group. However significant differ-

ences between the two groups in nasofacial and nasolabial angle suggest that placement technique may have differed between the two groups. The authors acknowledge these limitations in their conclusion and make no firm recommendation of one technique over the other [127].

4 Suture techniques

4.1 Considerations of suture material

The various suture and grafting maneuvers in rhinoplasty differ profoundly. While some suture techniques call for substantial strength to hold tissue under tension, other interpositional grafting techniques may require very little fixation.

Reported materials in rhinoplasty range from braided to monofilament, from resorbable to non-resorbable sutures and include 4-0 to 7-0 diameters. An ideal suture would cause minimal tissue reaction, display maximal durability, retain tension and would not migrate through cartilage or extrude through the external skin. For most structural grafts in open structure rhinoplasty, the use of 6-0 monofilament suture is reported, typically resorbable such as PDS[®] or Monocryl[®] and non-resorbable such as Prolene[®] or Nylon[®]. Studies to compare the properties of these sutures in rhinoplasty are scarce, but data extrapolated from other uses may be potentially applicable to graft fixation in rhinoplasty:

In segmental tracheal reconstruction, the resulting tensile strength of the healed anastomosis does not differ significantly among established resorbable suture materials (Vicryl[®], PDS[®], Monocryl[®]) [128]. Regardless of suture material and technique, the cartilaginous anastomosis achieves the strength of the uninjured trachea after an interval of a few weeks [129]. Similar to tracheal reconstruction, it has also been shown in the orthopaedic literature that cartilage can fuse with sufficient strength. On the other hand mobility and migration of cartilaginous grafts in rhinoplasty is a relevant problem, especially for tip grafts and for dorsal augmentation grafts. Sherris et al. conclude that osseocartilaginous costal augmentation grafts require rigid fixation to prevent non-union and mobility [130]. To date factors accurately predicting the quality and timing of secondary fusion of cartilaginous grafts in rhinoplasty can not be derived from the literature. Hence one may postulate that the longest lasting suture material should be utilized for graft fixation, unless other factors are of overriding importance.

Obviously there is substantial degradation of all resorbable suture materials [131], [132]. Among the non-resorbable suture materials, Prolene[®] seems to be the most stable material and retains its tensile strength in contrast to Nylon[®] even in acidic environments [133], [134]. The risk of extrusion of visible, colored non-resorbable suture material through the external skin is low, but certainly also deserves consideration.

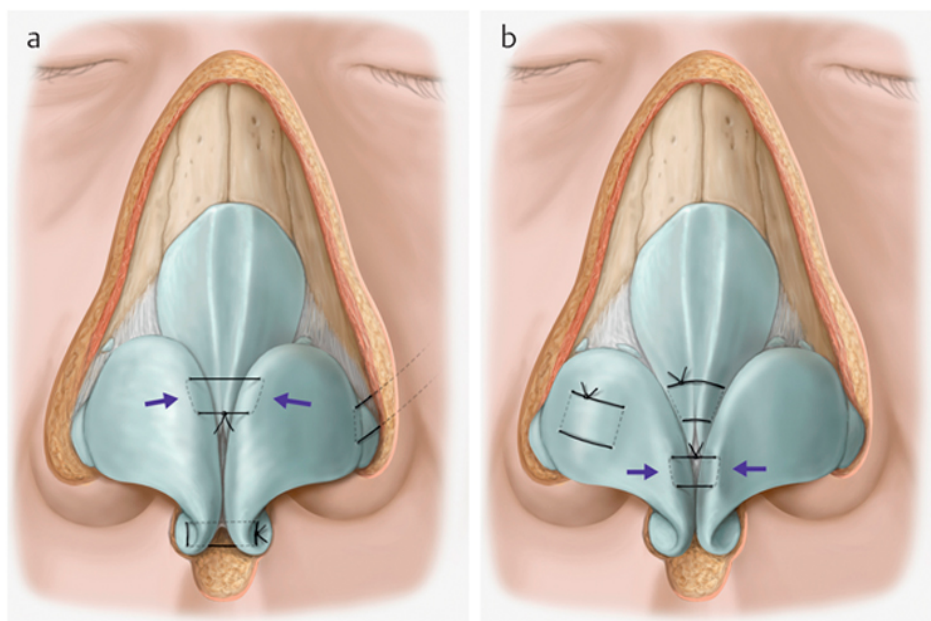


Figure 10: Frequently placed sutures. a) From top to bottom: High interdomal suture, flaring suture and middle crura suture. b) From top to bottom: Flaring suture, lateral crura suture, interdomal suture.

So at least two important questions remain to be answered before one may recommend a specific suture material for graft fixation. First: Which factors predict if and when grafted cartilage fuses to the surrounding tissue with a strength that makes additional suture stabilization over time unnecessary. And second, even if a suture retains its tensile strength long term, do the suture channels within the cartilage hold the tension as well, and to what degree is the suture rendered useless by migration?

This last question applies in particular to non-static suture techniques, which includes the lateral suspension suture. This technique relies on the suture material to maintain tension on the target tissue long term. One may recall one of the fundamental principles of surgery: Tissues can only be repositioned properly if they have been adequately mobilized and fixated with the least possible amount of tension in the new position. Otherwise the relentless elastic pull of the deformed tissue may cause migration of the suture material (the cheese wire effect) and render the maneuver ineffective over time. This important aspect deserves consideration when reviewing the literature on dynamic suture techniques.

4.2 Suture techniques to modify the columella and central pedestal

4.2.1 Tongue in groove suture

Variations of the tongue in groove suture have been described by pioneers of rhinoplasty, including Joseph and Rethi [135], [136]. After elevation of bilateral septal tunnels and dissection of an intercrural pocket, the medial crura are advanced and sutured to the caudal end of the septum. Kridel recommends the use of a 4-0 chromic gut suture on straight needle (SC 1) to set symmetric contour and dome height, Toriumi adds a 4-0 Nylon stitch to se-

cure the intermediate crus to the anterior septal angle [137], [138]. Based on retrospective data in 287 patients, Kridel concludes that 97% of disproportions of the nasal base can be corrected with this technique. Potential drawbacks of this technique include widening of the columella and stiffening of the nasal tip, which is further discussed in section “5 Discussion”.

4.2.2 Medial crura suture

Guyron describes the middle crura suture as a simple interrupted loop, as depicted in Figure 10a. It may be placed at variable heights between the medial crura, the knot may be buried. Based on personal observations, Guyron cites the following as functions of middle crura suture: approximation of the medial crura, narrowing of the columella, strengthening of nasal tip support, derotation of the lower lateral cartilages, and reduction of the interdomal distance [139]. Its effect on nasal tip support is rather limited.

4.3 Suture techniques to reconstruct the dysfunctional nasal valves

4.3.1 Flaring suture

The flaring suture is depicted in Figure 10b. As described by Park it may be used with or without spreader grafts to directly impact the nasal valve area [140]. When used in conjunction with spreader grafts, the upper lateral cartilage is separated from the septum and spreader grafts are inserted in the typical fashion [141]. Subsequently the caudal/lateral aspect of the upper lateral cartilage is grasped with a 4-0 Nylon suture in a vertical fashion. This area, typically hidden under the scroll of the lateral crus, is delivered with the help of an endonasally placed cotton

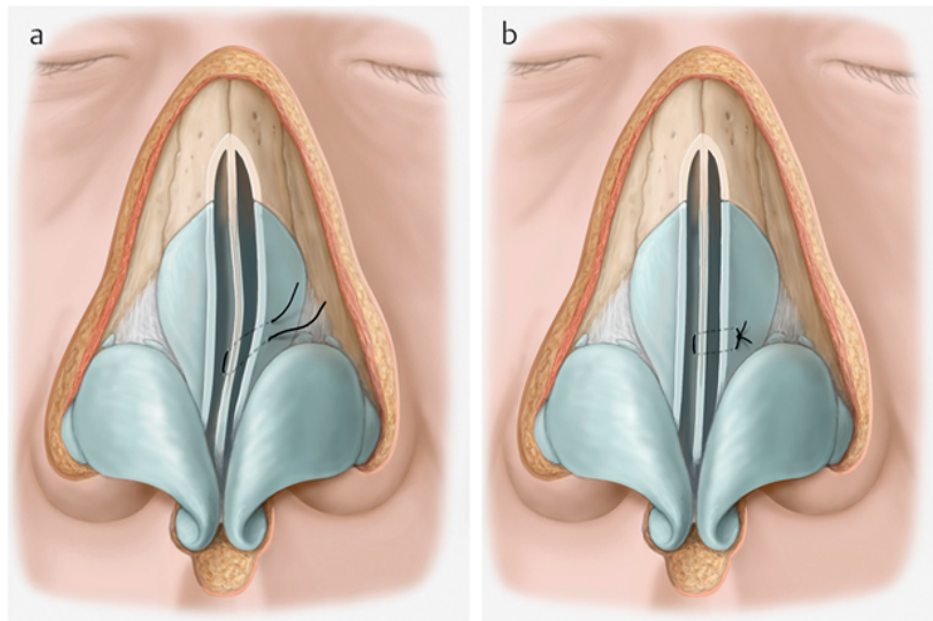


Figure 11: a) Mattress suture placed at different levels of the septum and the upper lateral cartilage. b) Deviations may be corrected by tying the knots. This suture may be utilized with or without the placement of a spreader graft.

tip applicator. The suture is passed on the contralateral side in the same fashion and is tied with moderate tension across the nasal dorsum, resulting in flaring of the upper lateral cartilages. Park reports subjective improvement in 20/20 patients. As discussed in section “4.1 Considerations of suture material”, sutures that permanently rely on tension to displace tissues may be rendered ineffective over time by migration. In this light, placement of the flaring suture may be more useful after the target tissue has been mobilized and repositioned, i.e. after the upper lateral cartilages have been separated from the septum. This theoretical consideration is supported by cadaveric data by Schlosser and Park, which demonstrate an added effect when spreader grafts and flaring sutures are combined [142].

4.3.2 Lateral suspension suture

Paniello et al. introduced the lateral suspension suture, as shown in Figure 10a [143]. This technique intends to lateralize the alar sidewall and to open the nasal valve. A buried loop of suture material grasps various aspects of the upper and lower lateral cartilages and is fixated with various methods to the infraorbital rim. Screw or bone anchor fixation appears to be preferred over suture fixation to the periosteum of the infraorbital rim. Access to the infraorbital rim may be through a transcutaneous or a transconjunctival incision. The important limitation of suture fixation under tension associated with this technique has been discussed in the section “Considerations of suture material”. Nuara presents longer term follow up data that suggest that this technique may lose efficacy over time [144]. In contrast Rooffe et al. present retrospective data to support this technique. These authors conclude that the technique is effective if the nasal and midfacial soft tissue are extensively undermined,

mobilized and fixated without tension in the new, more lateral position [145].

4.3.3 The middle third – considerations of suture techniques

The transition of the upper lateral cartilages and septum is a very delicate area. The large number of different grafting techniques depicted in Figure 6 illustrate the many options to treat this area. Attention to detail often determines the difference between good and excellent results. Suture fixation of spreader grafts is such an example. These mattress sutures can exhibit a pinching effect when placed too posterior (i.e. distant from the cut edge of the septum). These sutures can also be utilized to correct deviations of the middle third, as illustrated in Figures 11a, b. These mattress sutures are placed with or without spreader grafts and straighten the septum by passing the suture at different levels of the septum and upper lateral cartilage. The suture technique for the turn-in spreader graft also deserves mention. The first suture folds the upper lateral cartilage on itself after a scoring incision. This suture is tied relatively loosely so that the turned-over segment recreates the nasal valve angle. The second suture is placed very anterior to approximate the upper lateral cartilage – turn in spreader complex to the nasal septum. This is done close to the cut edge of the septum and the turned-over edge of the turn-in spreader in order to minimize the resulting valve angle.

4.4 Suture techniques to modify the nasal tip

4.4.1 Dome sutures

Varying terminology has been used to describe a mattress suture to accentuate the domal angle: intra-, transdomal or dome binding suture, as shown in Figure 12. In addition to the pinching effect on the dome, this suture may result in a less convex configuration as well as cranial or caudal rotation of the lateral crus [139]. Scoring of the cartilage may be performed to weaken the domes as an adjunctive procedure, especially in individuals with rigid lower lateral cartilages.

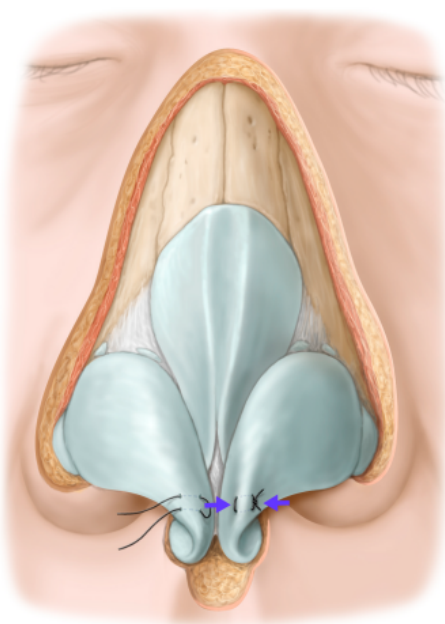


Figure 12: The interdomal suture defines and narrows the nasal tip.

The interdomal suture (syn: transdomal suture, double dome suture) may be placed through the open or the endonasal delivery approach, as shown in Figure 10a, b. This suture is placed after modifications of the individual domes are completed. It spans from one dome to another. Cited functions include stabilization and narrowing of the tip, increasing and lengthening of the lobule [139]. Various placements are recommended, including a high or posterior placement to preserve the natural divergence of the tip defining point and to avoid the unitip deformity [146]. This high placement, as shown in Figure 10a, has an important additional effect: It generates a more defined transition from the dorsum to the supratip. Its effects are carefully adjusted by tying the knot with variable tension. Another modification is described Perkins et al.: the alar spanning suture. After elevation of the vestibular skin, this suture is placed to span from the intermediate crus under the dome to the medial aspect of

the lateral crus. It exhibits a pinching effect and allows narrowing the tip more markedly [147].

4.4.2 The lateral crura suture

Tebbetts popularized a horizontal mattress suture placed to span the convexity of the lateral crura, which is shown in Figure 10b. Its function is similar to a Mustardé suture. Guyuron cites as an effect a decrease of the convexity of the lateral crus, alar retraction and caudal rotation of the domes. Other authors employ the suture to project the domes and to accentuate the transition from the dorsum to the supratip lobule and to reduce ballooning [139], [148].

4.4.3 The medial crura-septal suture

This mattress suture anchors the medial crura footplates to the caudal septum. A modification of the medial crura-septal suture is the septocolumellar suture, which anchors more anterior aspects of the medial crura to the caudal end of the septum [149]. With adequate dissection of an intercrural pocket, these sutures allow to slide the columella in a controlled fashion and thus modify tip projection. Added effects include narrowing and elevation of the columellar base and modification of columellar show.

4.4.4 The lower lateral crura turnover suture

The lower lateral crura turnover is a cartilage sparing technique to correct both alar contour and external valve function. A scoring incision is placed along the long axis of the lateral crus. The cephalic aspect of the lower lateral cartilage is dissected off the underlying vestibular skin, rotated 180° downwards and fixated to the caudal aspect of the lower lateral cartilage with mattress sutures. This represents a less invasive technique than lower lateral cartilage inversion or flip flop for the correction of concavities of the lower lateral cartilage. This technique may also be used instead of resection of the cephalic aspect of the lower lateral cartilage to reduce nasal tip volume and to rotate the nasal tip [150].

5 Discussion

Numerous reports on grafting and suture techniques have accompanied a shift towards the open approach. Most of these techniques represent modifications that have their roots in the early pioneers of facial plastic surgery – true innovations are rare. Before an overzealous attempt is made to value or rank these techniques according to published outcome data, important limitations with regards to the study of such techniques have to be considered. Changes after rhinoplasty result from soft tissue interactions of multiple combined maneuvers. Many techniques have important overlaps in form and function, and an analysis of a technique in isolation is virtually impossible. In addition, the effect of a specific maneuver in

rhinoplasty strongly depends on the quality of its execution. Certain grafts or sutures work well in one surgeon's hands, but not in another's. Finally, most studies designed to analyze individual techniques represent retrospective reports of a single surgeon's experience. Randomized, prospective studies with good evidence levels are largely lacking in rhinoplasty, which stands in stark contrast to other fields, such as head and neck oncology or otology [151]. Quality of outcome analysis represents another limitation to the study of rhinoplasty. Measures of cosmesis predominantly rely on subjective evaluation; measurements of function are not standardized and inconsistently reported. In order to augment the information that has been retrieved for the present report by analysis of individual, mostly retrospective studies, important trends from the literature were included with the present discussion. After review of the literature and careful consideration of the limitations mentioned above, the following interpretations are suggested:

An important trend concerns the middle third: Its reconstruction has long relied on the spreader graft as the workhorse transplant, but the functional value of the spreader graft is increasingly challenged. Alternative or additional maneuvers are recommended when nasal valve obstruction resulting from collapse of the middle vault is to be treated. The turn-in spreader graft and the onlay spreader graft appear to be emerging alternatives. With regards to the tip, dome division techniques and aggressive grafting of the nasal tip with a shield graft had become popular with the advent of the open approach and now seem to be fading because of unfavorable long term cosmetic outcome. Alternative techniques to alter the shape of the tip complex through sutures and internal grafts seem to be taking place, and efforts to preserve the anatomic continuity of the lower lateral cartilage are more prevalent. The septal extension graft appears to become increasingly accepted for the treatment of deficient nasal tip projection. Three additional grafting techniques deserve special mention, since they represent innovations and appear to have added particular value in recent years. First, the wrapped diced cartilage graft described by Erol and modified by Daniel is more and more accepted to improve dorsal irregularities and to augment saddle nose deformities. A relatively small volume of cartilage of lesser quality is sufficient for this graft, and in situ remodeling allows modification of its shape after placement. Second, the extended columellar strut – tip graft described by Pastorek is excellently suited for the endonasal correction of the overly rotated, underprojected tip. This graft can even be placed when an open approach was utilized for the primary operation. Third, the alar strut graft introduced by Gunter is increasingly utilized to correct ballooning of the lateral crura and collapse of the nasal valve. This graft adds no visible volume and enables effective repositioning of vertically maloriented lateral crura.

With the rise in grafting, suture techniques have also become more popular. A number of static sutures to stabilize the skeletal framework are firmly established.

The pre-spinal attachment suture secures the caudal septum to the anterior nasal spine, septocolumellar sutures maintain tip projection after various modifications of the tongue-in groove dissection, the high interdomal suture allows for excellent control of the supratip break. In terms of graft fixation, placement of Prolene® and Nylon® mattress sutures seem to be the most reliable method, with few long term complications noted. In recent years, a number of dynamic suture techniques have also been described. These intend to treat nasal valve collapse and include techniques such as the flaring suture and the dome spanning suture. As mentioned above, the current literature does not seem to suggest that any suture material can maintain long term elastic pull or tension in vivo. On close inspection, favorable reports on dynamic suture techniques may describe modifications that obviate the need to maintain permanent tension: The lateral suspension suture seems to work better if the soft tissue attachments to the piriform aperture have been released and the tissues of the midfacial have been advanced superolaterally. The flaring suture seems to be most effective when the connection between the upper lateral cartilages and the septum has been released and the upper lateral cartilages are allowed to fuse with the septum / spreader graft complex in a new position. With regards to approach, doubtlessly an important shift towards the open technique has taken place over the past three decades. Reductive techniques, such as excessive cephalic trim and lateral dome division were initially introduced with the open approach. With a growing understanding of their possible unfavorable long term effects, these have been largely replaced with more conservative techniques, including extensive lateral dissection and repositioning of the lower lateral cartilages, placement of alar strut grafts and tongue in groove techniques.

Despite the use of more conservative techniques, loss of tip support continues to ensue from the open approach and calls for extensive use of suture and grafting techniques. Insertion of a columellar strut and spreader grafts is frequent; placement of a caudal extension graft and alar strut grafts have also become more common, as well as addition of crushed cartilage to camouflage dorsal irregularities. This introduces important implications for the open approach: Septal cartilage, which remains straight over time and lends considerable support, may be depleted even with a primary rhinoplasty. With the increased demand, efforts to limit the harvest of septal cartilage have intensified, including the design of thinner, split grafts. The use of costal cartilage and alloplastic material is also more frequently reported, and some surgeons even recommend the use of costal cartilage in primary rhinoplasty. Reservations toward donor site morbidity, added surgical time and visible scarring seem to have softened and the use of alloplastic material is increasingly accepted.

Stringent selection criteria to guide the choice of approach do not exist; the surgeon is rather guided by personal philosophy, training and experience. An argument fre-

quently presented in favor of the open approach includes its minimal added morbidity, but available studies in that regard are scarce. Recently published data on the visibility of the transcolumellar scar deserve review [152]. Moreover some preliminary data suggest that nasal tips corrected with extensive grafting through the open approach may become unnaturally firm [153]. Further research efforts are certainly desirable to provide us with a better understanding of the limitations of the endonasal approach and the potential need to open the nose for placement of grafts and sutures in rhinoplasty. It will be interesting to note whether the recent trend towards conservative and cartilage sparing techniques will continue and eventually incorporate an equally conservative and soft tissue sparing access to the surgical field.

6 Conclusion

A large number of suture techniques and grafting maneuvers have been popularized with the advent of the open approach in rhinoplasty. The benefit of advanced grafting and suture techniques is widely acknowledged. Many of these techniques allow for aggressive correction of nasal valve deficiencies, precise sculpting of the nasal tip, and refined camouflage and augmentation of the dorsum. Because of these perceived advantages, a clear trend in favour of the open approach has emerged in recent years. However, research on the potential downsides of extensive grafting through the open approach is only beginning to emerge. Initial data suggest that alterations to the natural softness of the nasal tip may be profound. It will be interesting to note whether future research will aim at combining the benefits of advanced grafting and suture techniques with the more limited soft tissue disruption and reduced scar formation of the closed approach.

Acknowledgement

The author gratefully acknowledges Uwe Müller-Vogt and Thomas Kuehnelt for the diligent review of the manuscript; Markus Voll for the production of the illustrations and Johnson and Johnson for financing the figures.

References

1. Roche Lexikon Medizin. 5. Auflage. München: Urban Urban & Fischer Verlag, Elsevier; 2006.
2. Huizing EH, Mackay IS, Rettinger G. Reconstruction of the nasal septum and dorsum by cartilage transplants - autogeneic or allogeneic? *Rhinology*. 1989;27:5-10.
3. Helder AH, Huizing EH. Transplantation terminology in nasal surgery. *Rhinology*. 1986; 24:235-6.
4. Tardy ME Jr, Denny J 3rd, Fritsch MH. The versatile cartilage autograft in reconstruction of the nose and face. *Laryngoscope*. 1985;95:523-33. DOI: 10.1288/00005537-198505000-00003
5. Gunter JP, Rohrich RJ. External approach for secondary rhinoplasty. *Plast Reconstr Surg*. 1987;80:161-74. DOI: 10.1097/00006534-198708000-00001
6. Homicz MR, McGowan KB, Lottman LM, Beh G, Sah RL, Watson D. A compositional analysis of human nasal septal cartilage. *Arch Facial Plast Surg*. 2003;5:53-8. DOI: 10.1001/archfaci.5.1.53
7. Westreich RW, Courtland HW, Nasser P, Jepsen K, Lawson W. Defining nasal cartilage elasticity: biomechanical testing of the tripod theory based on a cantilevered model. *Arch Facial Plast Surg*. 2007 ;9:264-70. DOI: 10.1001/archfaci.9.4.264
8. Kim DW, Egan KK, O'Grady K, Toriumi DM. Biomechanical strength of human nasal septal lining: comparison of the constituent layers. *Laryngoscope*. 2005;115:1451-3. DOI: 10.1097/01.mlg.0000168579.94187.f6
9. ten Koppel PG, van der Veen JM, Hein D, van Keulen F, van Osch GJ, Verwoerd-Verhoef HL, Verwoerd CD. Controlling incision-induced distortion of nasal septal cartilage: a model to predict the effect of scoring of rabbit septa. *Plast Reconstr Surg*. 2003;111:1948-57. DOI: 10.1097/01.PRS.0000055427.13139.35
10. Murakami WT, Wong LW, Davidson TM. Applications of the biomechanical behavior of cartilage to nasal septoplasty surgery. *Laryngoscope*. 1982;92:300-9. DOI: 10.1288/00005537-198203000-00015
11. Mischkowski RA, Domingos-Hadamitzky C, Siessegger M, Zinser MJ, Zöller JE. Donor-site morbidity of ear cartilage autografts. *Plast Reconstr Surg*. 2008;121:79-87. DOI: 10.1097/01.prs.0000293879.46560.4c
12. Murrell GL. Auricular cartilage grafts and nasal surgery. *Laryngoscope*. 2004;114:2092-102. DOI: 10.1097/01.mlg.0000149440.20608.7c
13. Pirsig W, Pentz S, Lenders H. Repair of saddle nose deformity in Wegener's granulomatosis and ectodermal dysplasia. *Rhinology*. 1993; 31: 69-72.
14. Koenig F. Zur Deckung von Defekten der Nasenflügel. *Berl Klein Wschr*. 1902;39:137.
15. Tardy ME, Toriumi D. Alar retraction: composite graft correction. *Facial Plast Surg*. 1989 Winter; 6: 101-7. DOI: 10.1055/s-2008-1064716
16. Constantian MB. Indications and use of composite grafts in 100 consecutive secondary and tertiary rhinoplasty patients: introduction of the axial orientation. *Plast Reconstr Surg*. 2002; 110:1116-33. DOI: 10.1097/00006534-200209150-00018
17. Rettinger G, O'Connell M. The nasal base in cleft lip rhinoplasty. *Facial Plast Surg*. 2002; 18: 165-78. DOI: 10.1055/s-2002-33063
18. Jovacic S, Berghaus A. Autogenous auricular concha cartilage transplant in corrective rhinoplasty. Practical hints and critical remarks. *Rhinology*. 1991;29: 273 - 279.
19. Juri J, Juri C, Elias JC. Ear cartilage grafts to the nose. *Plast Reconstr Surg*. 1979;63: 377-382. DOI: 10.1097/00006534-197903000-00016
20. Ortiz-Monasterio, F. The use of cartilage grafts in primary aesthetic rhinoplasty. *Plast Reconstr Surg*. 1981;67: 597-605. DOI: 10.1097/00006534-198105000-00003
21. Toriumi DM. Autogenous graft are worth the extra time. *Arch Otolaryngol Head Neck Surg*. 2000;126: 562-564.
22. Denecke HJ, Meyer R. *Plastische Operationen an Kopf und Hals*. Bd. 1 Nasenplastik. Göttingen: Springer; 1964.
23. Riechelmann H, Rettinger G. Three-step reconstruction of complex saddle nose deformities. *Arch Otolaryngol Head Neck Surg*. 2004;130:334-8. DOI: 10.1001/archotol.130.3.334

24. Congdon D, Sherris DA, Specks U, McDonald T. Long-term follow-up of repair of external nasal deformities in patients with Wegener's granulomatosis. *Laryngoscope*. 2002;112:731-7. DOI: 10.1097/00005537-200204000-00025
25. Gurley JM, Pilgram T, Perlyn CA, Marsh JL. Long-term outcome of autogenous rib graft nasal reconstruction. *Plast Reconstr Surg*. 2001;108:1895-905. DOI: 10.1097/00006534-200112000-00007
26. Gibson T. Cartilage grafts. *Br Med Bull*. 1965;21:153.
27. Harris S, Pan Y, Peterson R, Stal S, Spira M. Cartilage warping: an experimental model. *Plast Reconstr Surg*. 1993;92:912-5. DOI: 10.1097/00006534-199310000-00018
28. Adams WP Jr, Rohrich RJ, Gunter JP, Clark CP, Robinson JB Jr. The rate of warping in irradiated and nonirradiated homograft rib cartilage: a controlled comparison and clinical implications. *Plast Reconstr Surg*. 1999;103:265-70. DOI: 10.1097/00006534-199901000-00042
29. Lopez MA, Shah AR, Westine JG, O'Grady K, Toriumi DM. Analysis of the physical properties of costal cartilage in a porcine model. *Arch Facial Plast Surg*. 2007 ;9:35-9. DOI: 10.1001/archfaci.9.1.35
30. Kim DW, Shah AR, Toriumi DM. Concentric and eccentric carved costal cartilage: a comparison of warping. *Arch Facial Plast Surg*. 2006 ;8:42-6. DOI: 10.1001/archfaci.8.1.42
31. Romo T 3rd, Jablonski RD. Nasal reconstruction using split calvarial grafts. *Otolaryngol Head Neck Surg*. 1992;107: 622-30.
32. Shipchandler TZ. Saddle nose deformity reconstruction with a split calvarial bone L-shaped strut. *Arch Facial Plast Surg*. 2008; 10: 305-11. DOI: 10.1001/archfaci.10.5.305
33. Sarnat BG, Laskin DM. Cartilage and cartilage implants. *Int Abstracts Surg*. 1954; 99: 521-41.
34. Rasi HB. The fate of preserved human cartilage. *Plast Reconstr Surg*. 1959; 24: 24-33. DOI: 10.1097/00006534-195907000-00004
35. Muhlbauer WD, Schmidt-Tintenmann U, Glaser M. Long-term behavior of preserved homologous rib cartilage in the correction of saddle nose deformity. *Br J Plast Surg*. 1971; 24: 325-333. DOI: 10.1016/S0007-1226(71)80085-1
36. Mikhelson NM. Homogenous cartilage in maxillofacial surgery. *Acta Chir Plast*. 1962; 4: 192-196.
37. Guyuron B, Friedman A. The role of preserved autogenous cartilage graft in septorhinoplasty. *Ann Plast Surg*. 1994; 32: 255-260. DOI: 10.1097/00000637-199403000-00005
38. Sclafani AP, Romo T 3rd, Jacono AA, McCormick S, Cocker R, Parker A. Evaluation of acellular dermal graft in sheet (AlloDerm) and injectable (micronized AlloDerm) forms for soft tissue augmentation. Clinical observations and histological analysis. *Arch Facial Plast Surg*. 2000;2:130-6. DOI: 10.1001/archfaci.2.2.130
39. Berghaus A, Stelter K. Alloplastic materials in rhinoplasty. *Curr Opin Otolaryngol Head Neck Surg*. 2006;14:270-7. DOI: 10.1097/01.moo.0000233599.14671.4a
40. Hwang K, Hwang JH, Park JH, Kim DJ, Shin YH. Experimental study of autologous cartilage, acellular cadaveric dermis, lyophilized bovine pericardium, and irradiated bovine tendon: applicability to nasal tip plasty. *J Craniofac Surg*. 2007;18:551-8. DOI: 10.1097/scs.0b013e3180534421
41. Gryskiewicz JM. Waste not, want not: the use of AlloDerm in secondary rhinoplasty. *Plast Reconstr Surg*. 2005; 116: 1999-04. DOI: 10.1097/01.prs.0000191180.77028.7a
42. Tobin HA, Karas NK. Lip augmentation using an alloderm graft. *Ann Plast Surg*. 1998; 41: 503-507.
43. Sherris DA. Personal communication.
44. Jasso-Victoria R, Olmos-Zuñiga JR, Gutierrez-cos LM, Sotres-Vega A, Manjarrez Velazquez JR, Gaxiola-Gaxiola M, Avila-Chavez A, Avendaño Moreno G, Santillan-Doherty P. Usefulness of bovine pericardium as interpositional graft in the surgical repair of nasal septal perforations (experimental study). *J Invest Surg*. 2003 ;16:209-17.
45. Hwang K, Hwang JH, Park JH, Kim DJ, Shin YH. Experimental study of autologous cartilage, acellular cadaveric dermis, lyophilized bovine pericardium, and irradiated bovine tendon: applicability to nasal tip plasty. *J Craniofac Surg*. 2007;18:551-8.
46. Straith RE. Five long-term case reports (average 15 years) of saddlenose correction using cast Silastic implants. *Plast Reconstr Surg*. 1991;88:1064-75. DOI: 10.1097/00006534-199112000-00019
47. Adams JS. Grafts and implants in nasal and chin augmentation. A rational approach to material selection. *Otolaryngol Clin North Am*. 1987;20:913-30.
48. Clark JM, Cook TA. Immediate reconstruction of extruded alloplastic nasal implants with irradiated homograft costal cartilage. *Laryngoscope*. 2002;112:968-74. DOI: 10.1097/00005537-200206000-00006
49. Tham C, Lai YL, Weng CJ, et al. Silicone augmentation rhinoplasty in an Oriental population. *Ann Plast Surg*. 2005; 54: 1-7. DOI: 10.1097/01.sap.0000141947.00927.49
50. Peled ZM, Warren AG, Johnston P, Yaremchuk MJ. The use of alloplastic materials in rhinoplasty surgery: a meta-analysis. *Plast Reconstr Surg*. 2008;121:85e-92e. DOI: 10.1097/01.prs.0000299386.73127.a7
51. Rothstein SG, Jacobs JB. The use of Gore-Tex implants in nasal augmentation operations. *ENTechnology*. 1989;40(42):40-45.
52. Stoll W. The use of polytetrafluoroethylene for particular augmentation of the nasal dorsum. *Aesth Plast Surg*. 1991;15:233-236. DOI: 10.1007/BF02273864
53. Hanel KC, McCabe C, Abbott WM, Fallon J, Megerman J. Current PTFE grafts: a biomechanical, scanning electron, and light microscopic evaluation. *Ann Surg*. 1982;195:456-63. DOI: 10.1097/00006558-198204000-00012
54. Bauer JJ, Salky BA, Gelernt IM, Kreef I. Repair of large abdominal wall defects with expanded polytetrafluoroethylene (PTFE). *Ann Surg*. 1987;206:765-9. DOI: 10.1097/00006558-198712000-00013
55. Jung YG, Kim HY, Dhong HJ, Park KN, Lee HJ, Lim YJ, Min JY. Ultrasonographic monitoring of implant thickness after augmentation rhinoplasty with expanded polytetrafluoroethylene. *Am J Rhinol Allergy*. 2009 ;23:105-10.
56. Conrad K, Gillman G. A 6-year experience with the use of expanded polytetrafluoroethylene in rhinoplasty. *Plast Reconstr Surg*. 1998;101:1675-1683. DOI: 10.1097/00006534-199805000-00040
57. Godin M, Waldman SR, Johnson CM. Nasal augmentation using Gore-Tex: a 10 year experience. *Arch Facial Plast Surg*. 1999;1:118-121. DOI: 10.1001/archfaci.1.2.118
58. Ham J, Miller PJ. Expanded polytetrafluoroethylene implants in rhinoplasty: literature review, operative techniques, and outcome. *Facial Plast Surg*. 2003;19:331-9. DOI: 10.1055/s-2004-815653
59. Fanous N, Samaha M, Yoskovitch A. Dacron implants in rhinoplasty: a review of 136 cases of tip and dorsum implants. *Arch Facial Plast Surg*. 2002 ;4:149-56. DOI: 10.1001/archfaci.4.3.149
60. Fanous N. Mersilene tip implants in rhinoplasty: a review of 98 cases. *Plast Reconstr Surg*. 1991;87:662-673. DOI: 10.1097/00006534-199104000-00009

61. Wellisz T. Clinical experience with the Medpor porous polyethylene implant. *Aesthetic Plast Surg.* 1993;17:339-44. DOI: 10.1007/BF00437109
62. Berghaus A. Porous polyethylene in reconstructive head and neck surgery. *Arch Otolaryngol Head Neck Surg.* 1985; 111:154-160.
63. Neel HB. Implants of Gore-Tex: comparisons with Teflon-coated polytetrafluorethylene carbon and porous polyethylene implants. *Arch Otolaryngol.* 1983; 109:427-433.
64. Romo T, Sclafani A, Sabini P. Use of porous high-density polyethylene in revision rhinoplasty and in the platyrrhine nose. *Aesthetic Plast Surg.* 1998;22:211-221. DOI: 10.1007/s002669900193
65. Gurlek A, Celik M, Fariz A, et al. The use of high-density porous polyethylene as a custom-made nasal spreader graft. *Aesthetic Plast Surg.* 2006; 30:34-41. DOI: 10.1007/s00266-005-0119-8
66. Mendelsohn M. Straightening the crooked middle third of the nose: using porous polyethylene extended spreader grafts. *Arch Facial Plast Surg.* 2005;7:74-80. DOI: 10.1001/archfaci.7.2.74
67. Cenzi R, Farina A, Zuccarino L, Carinci F. Clinical outcome of 285 Medpor grafts used for craniofacial reconstruction. *J Craniofac Surg.* 2005; 16:526-530. DOI: 10.1097/01.scs.0000168761.46700.dc
68. Peled ZM, Warren AG, Johnston P, Yaremchuk MJ. The use of alloplastic materials in rhinoplasty surgery: a meta-analysis. *Plast Reconstr Surg.* 2008;121:85e-92e. DOI: 10.1097/01.prs.0000299386.73127.a7
69. Berghaus A. Personal communication. 2009.
70. Wengen D. Personal communication. 2009.
71. Toriumi DM. New concepts in nasal tip contouring. *Arch Fac Plast Surg.* 2006;8(3):156-85. DOI: 10.1001/archfaci.8.3.156
72. Toriumi DM. Caudal septal extension graft for the correction of the retracted columella. *Op Tech Otolaryngol Head Neck Surg.* 1995; 6: 311-318. DOI: 10.1016/S1043-1810(05)80008-9
73. Tebbetts JB. *Primary Rhinoplasty: A New Approach to the Logic and the Techniques.* 1st ed. St. Louis: Mosby; 1998. pp. 458-460.
74. Guyuron B, Varghai A. Lengthening the nose with a tongue-and-groove technique. *Plast Reconstr Surg.* 2003;111:1533e9.
75. Han K, Jin HS, Choi TH, Kim JH, Son D. A biomechanical comparison of vertical figure-of-eight locking suture for septal extension grafts. *J Plast Reconstr Aesthet Surg.* 2010 ; 63(2):265-9. DOI: 10.1016/j.bjps.2008.08.038
76. Toriumi DM. Structure approach in rhinoplasty. *Facial Plast Surg Clin North Am.* 2005;13:93-113. DOI: 10.1016/j.fsc.2004.07.004
77. Rohrich RJ, Raniere J Jr, Ha RY. The alar contour graft: correction and prevention of alar rim deformities in rhinoplasty. *Plast Reconstr Surg.* 2002;109:2495-2505. DOI: 10.1097/00006534-200206000-00050
78. Gruber RP, Kryger G, Chang D. The intercartilaginous graft for actual and potential alar retraction. *Plast Reconstr Surg.* 2008;121:288e-296e. DOI: 10.1097/PRS.0b013e31816c3b9a
79. Millman B. Alar batten grafting for management of the collapsed nasal valve. *Laryngoscope.* 2002;112:574-9. DOI: 10.1097/00005537-200203000-00030
80. Toriumi DM, Josen J, Weinberger M, Tardy ME. Use of alar batten grafts for correction of nasal valve collapse. *Arch Otolaryngol Head Neck Surg.* 1997;123:802-808.
81. Becker DG, Becker SS. Treatment of nasal obstruction from nasal valve collapse with alar batten grafts. *J Long Term Eff Med Implants.* 2003;13:259-69. DOI: 10.1615/JLongTermEffMedImplants.v13.i3.100
82. Gassner H, Strutz J. *Plastische und rekonstruktive Chirurgie.* In: Strutz J, Mann W, Hrsg. *Praxis der HNO-Heilkunde, Kopf- und Halschirurgie.* 2. Auflage. Stuttgart, New York: Thieme; 2010. p. 750-76.
83. Gunter JP, Friedman RM. Lateral crural strut graft: technique and clinical applications in rhinoplasty. *Plast Reconstr Surg.* 1997;99:943-52. DOI: 10.1097/00006534-199704000-00001
84. André RF, D'Souza AR, Kunst HP, Vuyk HD. Sub-alar batten grafts as treatment for nasal valve incompetence; description of technique and functional evaluation. *Rhinology.* 2006;44:118-22.
85. Clark JM, Cook TA. The 'butterfly' graft in functional secondary rhinoplasty. *Laryngoscope.* 2002;112:1917-25. DOI: 10.1097/00005537-200211000-00002
86. Friedman O, Cook TA. Conchal cartilage butterfly graft in primary functional rhinoplasty. *Laryngoscope.* 2009;119:255-62. DOI: 10.1002/lary.20079
87. Clark JM, Cook TA. The 'butterfly' graft in functional secondary rhinoplasty. *Laryngoscope.* 2002;112:1917-25. DOI: 10.1097/00005537-200211000-00002
88. Sherris DA. Caudal and dorsal septal reconstruction: an algorithm for graft choices. *Am J Rhinol.* 1997 ;11:457-66. DOI: 10.2500/105065897780914910
89. Mendelsohn M. Straightening the crooked middle third of the nose: using porous polyethylene extended spreader grafts. *Arch Facial Plast Surg.* 2005 ;7:74-80. DOI: 10.1001/archfaci.7.2.74
90. Stal S, Hollier L. The use of resorbable spacers for nasal spreader grafts. *Plast Reconstr Surg.* 2000;106:922-928. DOI: 10.1097/00006534-200009040-00031
91. Byrd HS, Meade RA, Gonyon DL Jr. Using the autospreader flap in primary rhinoplasty. *Plast Reconstr Surg.* 2007;119:1897-902. DOI: 10.1097/01.prs.0000259196.02216.a5
92. André RF, Paun SH, Vuyk HD. Endonasal spreader graft placement as treatment for internal nasal valve insufficiency: no need to divide the upper lateral cartilages from the septum. *Arch Facial Plast Surg.* 2004 ;6:36-40. DOI: 10.1001/archfaci.6.1.36
93. Dyer WK 2nd. Nasal tip support and its surgical modification. *Facial Plast Surg Clin North Am.* 2004;12:1-13. DOI: 10.1016/j.fsc.2003.12.001
94. Alsarraf RI, Murakami CS. The Saddle Nose Deformity. *Facial Plast Surg Clin N Amer.* 1999;7:3030-310.
95. Gassner HG, Friedman O, Sherris DA, Kern EB. An alternative method of middle vault reconstruction. *Arch Facial Plast Surg.* 2006 ;8:432-5. DOI: 10.1001/archfaci.8.6.432
96. Behrbohm H, Briedigkeit W, Kaschke O. Jacques Joseph: father of modern facial plastic surgery. *Arch Facial Plast Surg.* 2008 ;10:300-3. DOI: 10.1001/archfaci.10.5.300
97. Kamer FM, Churukian MM. Shield graft for the nasal tip. *Arch Otolaryngol.* 1984;110:608-10.
98. Toriumi DM. New concepts in nasal tip contouring. *Arch Facial Plast Surg.* 2006 ;8:156-85. DOI: 10.1001/archfaci.8.3.156
99. Whitaker EG, Johnson CM Jr. The evolution of open structure rhinoplasty. *Arch Facial Plast Surg.* 2003;5:291-300. DOI: 10.1001/archfaci.5.4.291
100. Zijlker TD, Vuyk H. Cartilage grafts for the nasal tip. *Clin Otolaryngol Allied Sci.* 1993;18:446-58. DOI: 10.1111/j.1365-2273.1993.tb00612.x

101. Pastorek NJ, Bustillo A, Murphy MR, Becker DG. The extended columellar strut-tip graft. *Arch Facial Plast Surg.* 2005 ;7:176-84. DOI: 10.1001/archfaci.7.3.176
102. Toriumi DM. New concepts in nasal tip contouring. *Arch Facial Plast Surg.* 2006 ;8:156-85. DOI: 10.1001/archfaci.8.3.156
103. Miller TA. Temporalis fascia grafts for facial and nasal contour augmentation. *Plast Reconstr Surg.* 1988;81:524-33. DOI: 10.1097/00006534-198804000-00007
104. Guerrerosantos J. Temporoparietal free fascia grafts in rhinoplasty. *Plast Reconstr Surg.* 1984;74:465-75. DOI: 10.1097/00006534-198410000-00001
105. Baker TM, Courtiss EH. Temporalis fascia grafts in open secondary rhinoplasty. *Plast Reconstr Surg.* 1994;93:802-10. DOI: 10.1097/00006534-199404000-00023
106. Gassner HG, Rafii A, Young A, Murakami C, Moe KS, Larrabee WF Jr. Surgical anatomy of the face: implications for modern face-lift techniques. *Arch Facial Plast Surg.* 2008 ;10:9-19. DOI: 10.1001/archfaci.2007.16
107. Davis RE, Wayne I. Rhinoplasty and the Nasal SMAS augmentation Graft. *Arch Facial Plast Surg.* 2004;6:124-132. DOI: 10.1001/archfaci.6.2.124
108. Verwoerd-Verhof HL, et al. Histologic evaluation of crushed cartilage grafts in the growing nasal septum in young rabbits. *ORL J Otorhinolaryngol Relat Spec.* 1991; 53: 305-309. DOI: 10.1159/000276234
109. Huizing EH. Implantation and transplantation in reconstructive nasal surgery. *Rhinology.* 1974; 12: 93-106.
110. Breadon GE, Kern EB, Neel BH. Autografts of uncrushed and crushed bone and cartilage: experimental observations and clinical implications. *Arch Otolaryngol.* 1979; 105: 75-80.
111. Rudderman RH, Guyuron B, Mendelsohn G. The fate of noncrushed and crushed bone and autogenous cartilage in the rabbit model. *Ann Plast Surg.* 1994; 32: 255-260. DOI: 10.1097/00006537-199403000-00004
112. Guyuron B, Friedman A. The role of preserved autogenous cartilage graft in septorhinoplasty. *Ann Plast Surg.* 1994; 32: 255-260. DOI: 10.1097/00006537-199403000-00005
113. Cakmak O, Buyuklu F, Yilmaz Z, Sahin FI, et al. Viability of cultured human nasal septum chondrocytes after crushing. *Arch Facial Plast Surg.* 2005 ;7:406-9. DOI: 10.1001/archfaci.7.6.406
114. Cakmak O, Buyuklu F. Crushed cartilage grafts for concealing irregularities in rhinoplasty. *Arch Facial Plast Surg.* 2007 ;9:352-7. DOI: 10.1001/archfaci.9.5.352
115. Parker Porter J. Grafts in rhinoplasty: allogenic vs autogenous. *Arch Otolaryngol Head Neck Surg.* 2000; 126: 558-561.
116. Ishida LC, Ishida J, Henrique Ishida L, Passos AP, Vieira JC, Ferreira MC. Total reconstruction of the alar cartilages with a partially split septal cartilage graft. *Ann Plast Surg.* 2000;45:481-4. DOI: 10.1097/00006537-200045050-00003
117. Tarhan E, Cakmak O, Ozdemir BH, Akdogan V, et al. Comparison of AlloDerm, fat, fascia, cartilage, and dermal grafts in rabbits. *Arch Facial Plast Surg.* 2008 ;10:187-93. DOI: 10.1001/archfaci.10.3.187
118. Peer LA. Diced cartilage grafts. *Arch Otolaryngol.* 1943;28:196.
119. Erol OO. The Turkish delight: A pliable graft for rhinoplasty. *Plast Reconstr Surg.* 2000;105: 2229. DOI: 10.1097/00006534-200005000-00051
120. Daniel RK, Calvert JW. Diced cartilage grafts in rhinoplasty surgery. *Plast Reconstr Surg.* 2004;113:2156-71.
121. Velidedeoglu H, Demir Z, Sahin U, Kurtay A, Erol OO. Block and Surgicel-Wrapped Diced Solvent-Preserved Costal Cartilage Homograft Application for Nasal augmentation. *Plast Reconstr Surg.* 2005;115:2081-93. DOI: 10.1097/01.PRS.0000164674.91925.B9
122. Adams WP Jr, Rohrich RJ, Gunter JP, Clark CP, Robinson JB Jr. The rate of warping in irradiated and nonirradiated homograft rib cartilage: a controlled comparison and clinical implications. *Plast Reconstr Surg.* 1999;103:265-70. DOI: 10.1097/00006534-199901000-00042
123. Murakami CS, Cook TA, Guida RA. Nasal reconstruction with articulated irradiated rib cartilage. *Arch Otolaryngol Head Neck Surg.* 1991;117:327-30.
124. Swanepoel PF, Fysh R. Laminated dorsal beam graft to eliminate postoperative twisting complications. *Arch Facial Plast Surg.* 2007 ;9:285-9. DOI: 10.1001/archfaci.9.4.285
125. Sherris DA, Kern EB. The versatile autogenous rib graft in septorhinoplasty. *Am J Rhinol.* 1998 ;12:221-7. DOI: 10.2500/105065898781390136
126. Comgdon D. Long-term follow-up of repair of external nasal deformities in patients with Wegener's granulomatosis. *Laryngoscope.* 2002; 112: 731-7. DOI: 10.1097/00005537-200204000-00025
127. Emsen IM, Benlier E. Autogenous calvarial bone graft versus reconstruction with alloplastic material in treatment of saddle nose deformities: a two-center comparative study. *J Craniofac Surg.* 2008;19:466-75. DOI: 10.1097/SCS.0b013e3180690085
128. Friedman E, Perez-Atayde AR, Silvera M, Jonas RA. Growth of tracheal anastomoses in lambs. Comparison of PDS and Vicryl suture material and interrupted and continuous techniques. *J Thorac Cardiovasc Surg.* 1990;100:188-93.
129. Behrend M, Kluge E, Schüttler W, Klemphauer J. A comparison of interrupted and continuous sutures for tracheal anastomoses in sheep. *Eur J Surg.* 2002;168:101-6. DOI: 10.1080/11024150252884322
130. Sherris DA, Kern EB. The versatile autogenous rib graft in septorhinoplasty. *Am J Rhinol.* 1998 ;12:221-7. DOI: 10.2500/105065898781390136
131. LaBagnara J Jr. A review of absorbable suture materials in head & neck surgery and introduction of monocryl: a new absorbable suture. *Ear Nose Throat J.* 1995;74:409-15.
132. Bloom BS, Goldberg DJ. Suture material in cosmetic cutaneous surgery. *J Cosmet Laser Ther.* 2007;9:41-5. DOI: 10.1080/14764170601140062
133. Homsy CA, McDonald KE, Akers WW, Short C, Freeman BS. Surgical suture-canine tissue interaction for six common suture types. *J Biomed Mater Res.* 1968;2:215-30. DOI: 10.1002/jbm.820020205
134. Tomihata K, Suzuki M, Ikada Y. The pH dependence of monofilament sutures on hydrolytic degradation. *J Biomed Mater Res.* 2001;58:511-8. DOI: 10.1002/jbm.1048
135. Joseph J. Nasenplastik und sonstige Gesichtsplastik, nebst einem Anhang über Mammoplastik und einige weitere Operationen aus dem Gebiete der äußeren Körperplastik. Ein Atlas und Lehrbuch. Leipzig: Curt Kabitzsch; 1931.
136. Rethi A. Operation to shorten an excessively long nose. *Rev Chir Plast.* 1934; 2:85-87.
137. Kridel RWH, Scott BA, Foda HMT. The tongue-in-groove-technique in septorhinoplasty: a 10-year experience. *Arch Facial Plast Surg.* 1999; 1:246-256. DOI: 10.1001/archfaci.1.4.246
138. Toriumi DM. Structure approach in rhinoplasty. *Facial Plast Surg Clin North Am.* 2005;13:93-113. DOI: 10.1016/j.fsc.2004.07.004

139. Guyuron B, Behmand RA. Nasal Tip sutures part II: The interplays. Nasal tip sutures part II: the interplays. *Plast Reconstr Surg*. 2003;112:1130-45. DOI: 10.1097/01.PRS.0000076505.83375.74
140. Park SS. The flaring suture to ment the repair of the dysfunctional nasal valve. *Plast Reconstr Surg*. 1998;101:1120-2. DOI: 10.1097/00006534-199804040-00036
141. Schlosser RJ, Park SS. Functional nasal surgery. *Otolaryngol Clin North Am*. 1999;32:37-51. DOI: 10.1016/S0030-6665(05)70114-6
142. Schlosser RJ, Park SS. Surgery for the dysfunctional nasal valve. Cadaveric analysis and clinical outcomes. *Arch Facial Plast Surg*. 1999;1:105-10. DOI: 10.1001/archfaci.1.2.105
143. Paniello RC. Nasal valve suspension: an effective treatment for nasal valve collapse. *Arch Otolaryngol Head Neck Surg*. 1996;122:1342-1346.
144. Nuara MJ. Nasal valve suspension revisited. *Laryngoscope*. 2007;117: 2100-6. DOI: 10.1097/MLG.0b013e31814842cd
145. Roofe SB, Most SP. Placement of a lateral nasal suspension suture via an external rhinoplasty approach. *Arch Facial Plast Surg*. 2007;9:214-6. DOI: 10.1001/archfaci.9.3.214
146. Toriumi DM, Checcone MA. New concepts in nasal tip contouring. *Facial Plast Surg Clin North Am*. 2009;17:55-90. DOI: 10.1016/j.fsc.2008.10.001
147. Perkins S, Patel A. Endonasal suture techniques in tip rhinoplasty. *Facial Plast Surg Clin North Am*. 2009;17:41-54. DOI: 10.1016/j.fsc.2008.10.004
148. Tebbetts JB. Shaping and positioning the nasal tip without structural disruption: A new systematic approach. *Plast Reconstr Surg*. 1994;94: 61. DOI: 10.1097/00006534-199407000-00006
149. Tezel E, Numanoglu A. Septocolumellar suture in closed rhinoplasty. *Ann Plast Surg*. 2007;59:268-72. DOI: 10.1097/SAP.0b013e31802e0930
150. Janis JE. Lower lateral crural tur er flap in open rhinoplasty. *PRS*. 2009; 123: 1830-41.
151. Larrabee WF jr. More science - please. *Arch Facial Plast Surg*. 2008 ;10:8. DOI: 10.1001/archfacial.2007.6
152. Scheithauer M, Schulz M, Rettinger G. Qualität und Akzeptanz der Kolumella-Narbe nach offener Septorhinoplastik. 80. Jahresversammlung der Deutschen Gesellschaft für Hals-Nasen-Ohrenheilkunde, Kopf-und Halschirurgie, 20. - 24. Mai, Rostock.
153. Gassner HG, Remington WJ, Sherris DA. Quantitative study of nasal tip support and the effect of reconstructive rhinoplasty. *Arch Facial Plast Surg*. 2001 ;3:178-84. DOI: 10.1001/archfaci.3.3.178

Corresponding author:

Holger G. Gassner
 Plastische Gesichtschirurgie, Universitätsklinik und
 Poliklinik für Hals-Nasen-Ohrenheilkunde, Kopf- und
 Halschirurgie, Universität Regensburg, 93042
 Regensburg, Germany
 Info@DrGassner.eu

Please cite as

Gassner HG. *Structural grafts and suture techniques in functional and aesthetic rhinoplasty*. *GMS Curr Top Otorhinolaryngol Head Neck Surg*. 2010;9:Doc01. DOI: 10.3205/cto000065, URN: urn:nbn:de:0183-cto0000653

This article is freely available from

<http://www.egms.de/en/journals/cto/2011-9/cto000065.shtml>

Published: 2011-04-27

Copyright

©2011 Gassner. This is an Open Access article distributed under the terms of the Creative Commons Attribution License (<http://creativecommons.org/licenses/by-nc-nd/3.0/deed.en>). You are free: to Share – to copy, distribute and transmit the work, provided the original author and source are credited.