



Contents lists available at ScienceDirect

International Journal of Surgery Case Reports

journal homepage: www.casereports.com

Neuropraxia following resection of a retroperitoneal liposarcoma



Stevenson Tsiao, Nail Aydin*, Subhasis Misra

Texas Tech University Health Sciences Center, Department of Surgery, 1400 S. Coulter Street, Amarillo, TX 79106, United States

ARTICLE INFO

Article history:

Received 1 February 2017

Received in revised form 26 May 2017

Accepted 27 May 2017

Available online 1 June 2017

Keywords:

Neuropraxia

Retroperitoneal liposarcoma

Resection of liposarcoma

Case report

ABSTRACT

BACKGROUND: This is a unique case of neuropraxia of femoral nerve seen after resection of retroperitoneal liposarcoma which has not been reported before in the literature.

INTRODUCTION: Neuropraxia, a transient paralysis due to blockage of nerve conduction, commonly associated with athletes and orthopedic procedures, has not been previously reported as a complication following resection of retroperitoneal sarcoma.

CASE: This is an 81-year-old female who, on CT for evaluation of her atherosclerosis, was found to have an incidental right-sided retroperitoneal mass extending from the right renal capsule inferiorly through the inguinal canal. At this point, the patient reported mild right sided abdominal pain and right lower back pain, but reported no neuromotor deficits of the right lower extremity. Given the symptoms of the patient as well as the size, location and the density of the lesion, surgical intervention was pursued. On exploration, the lipomatous lesion, suggestive of liposarcoma, was invading the right genitofemoral nerve and ilioinguinal nerve which were sacrificed to ensure a complete oncologic resection. Following complete removal of the mass, she developed right side femoral nerve neuropraxia, suffering complete loss of motor function in the femoral distribution. Pathology revealed the mass to be a low grade liposarcoma.

DISCUSSION: The patient required only physical therapy and oral prednisone following surgery for treatment of the neuropraxia. She responded well and has regained significant neuromotor function of the affected limb. Cases presenting with post-resection neurological sequelae without any known intraoperative nerve injury may respond very well to conservative treatment. Hence, it is very important to collaborate with Neurology and Physical Therapy to achieve best possible outcome.

© 2017 The Author(s). Published by Elsevier Ltd on behalf of IJS Publishing Group Ltd. This is an open access article under the CC BY-NC-ND license (<http://creativecommons.org/licenses/by-nc-nd/4.0/>).

1. Introduction

An estimated 11930 cases of sarcoma were diagnosed in 2015, comprising less than 1% of all cancers diagnosed in the United States [1–3]. Of these, only approximately 10–20% are in the retroperitoneum [2], and a great subset of these will be diagnosed as liposarcomas. Typical complications following resection of such masses include bleeding (2–3%), infection (1–2%), and incomplete resection of the mass (20–40%) [4]. To our knowledge, neuropraxia, a transient paralysis due to blockage of nerve conduction, commonly associated with athletes and orthopedic procedures, has not been previously reported as a complication following resection of such a mass. In line with SCARE criteria, we present a case of neuropraxia following resection of a retroperitoneal liposarcoma [9].

2. Case presentation

This is an 81-year-old female who had an incidental finding of a large retroperitoneal mass on CT Angiography for evaluation of her atherosclerosis. On imaging, she was found to have a right sided large retroperitoneal mass measuring 11.3 cm × 7.8 cm × 6.2 cm extending from the renal capsule down to and through the inguinal canal into the femoral triangle (Figs. 1 and 2). The initial reading was consistent with a lipomatous lesion suggestive of a liposarcoma. At the time, patient reported only mild back pain with no known triggers and denied any neurological or neuromotor dysfunction. She also stated she had longstanding history of pain along the right midportion of the thigh, but relates this to a knee injury from many years ago. Otherwise, physical examination was normal. Initial workup included measurements of CEA, CA-125, and HCG for the possibility of an ovarian origin. Pelvic ultrasonography was also performed, and in addition to the negative results of the chemical markers for ovarian or adnexal origin, the patient was referred to the surgical oncology department. Her past medical history is significant for cardiovascular disease, a descending aortic aneurysm, previous myocardial infarction, left ventricular hypertrophy, angina, aortic and tricuspid valve disorders, glaucoma, hypertension, and hypothyroidism. She had significant smoking

* Corresponding author.

E-mail addresses: Stevenson.tsiao@gmail.com (S. Tsiao), Nail.aydin@ttuhsc.edu, nailaydin@gmail.com, naydin@icloud.com (N. Aydin), Subhasis.misra@ttuhsc.edu (S. Misra).

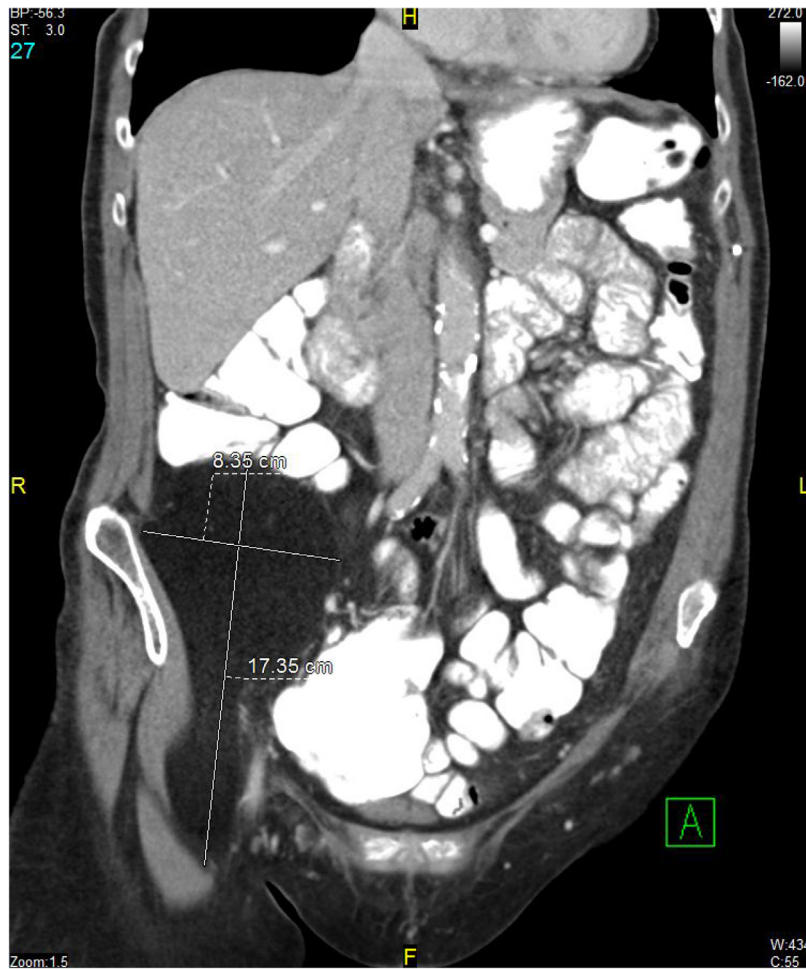


Fig. 1. Initial CT imaging of the mass, showing extension of the caudal tail into and through the inguinal canal.

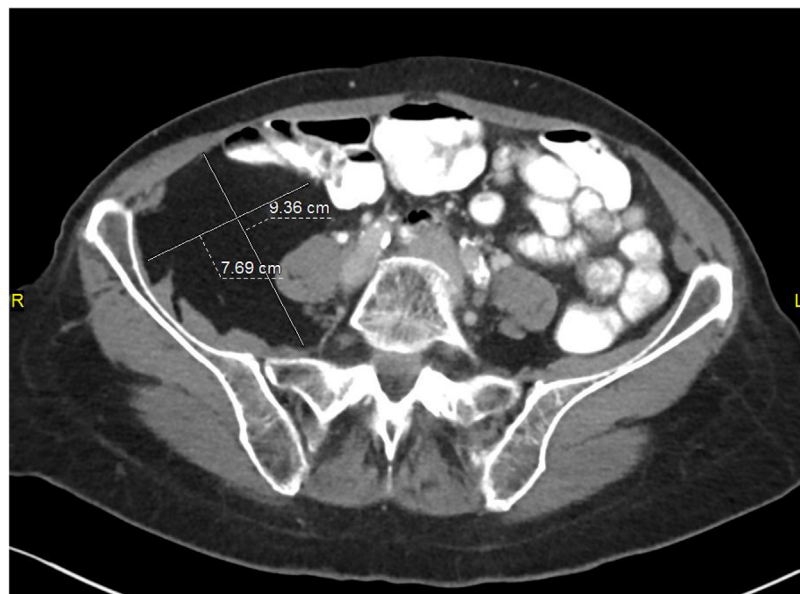


Fig. 2. Transverse image of the mass, showing anterior displacement of the psoas muscle and loops of bowel, consistent with a retroperitoneal, rather than intraperitoneal, mass.

history of 58 years pack-years. Surgical history is significant for past tonsillectomy and adenoidectomy, lipoma removal, hemorrhoidectomy, abdominal aortic aneurysm repair, and cataract

surgery. Family history is significant for breast and cervical cancer. The patient states she has up-to-date mammograms and colonoscopies, which she reports are both normal. Her physical exam was

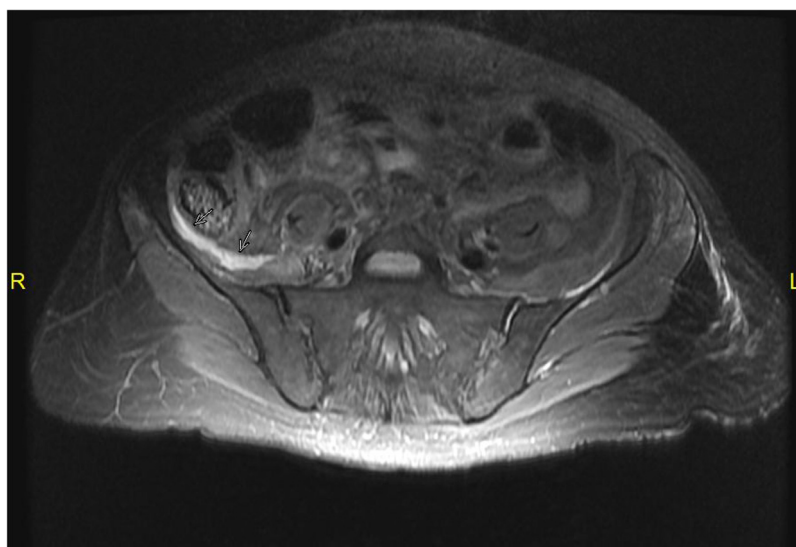


Fig. 3. Post-operative MRI, day 14, showing large fluid collection (marked by two solid arrows) overlying the right iliacus muscle.

unimpressive; abdomen was soft, non-tender, and non-distended. Surgical resection was recommended. On the day of the surgery, bilateral ureteral stents were placed under cystoscopy, and an exploratory laparotomy was performed. No signs of metastatic disease or other organ involvement was noted in the peritoneum. The right retroperitoneum was accessed by a medial visceral rotation, including a complete mobilization of the right colon and duodenum, and the entirety of the mass was then visualized. The mass, including the caudal extension, was freed with blunt dissection. The mass was dissected with great care, freed initially from the superior aspect, moving caudally. The right kidney, ureter, and IVC were completely skeletonized. Gerota's fascia, a portion of the inferior 1/3 of the psoas muscle, and portions of the genitofemoral nerve and ilioinguinal nerve were resected along with the mass and its capsule in its entirety. Careful blunt dissection was used throughout the case, especially in the area of the femoral nerve. The mass was removed en bloc without complication, with good visualization of the femoral nerve afterwards. The pathology was consistent with a stage I low grade liposarcoma without any metastatic disease. The case was discussed in tumor board and the consensus was to follow her clinically given her stage I disease with R0 resection and no evidence of systemic disease.

Following surgery, the patient was tolerating oral diet and was recovering well, other than complaining of difficulty flexing her right lower extremity at the hip and extending at the knee. She also lacked a patellar reflex. Motor ability of the ankle and foot were intact. These signs indicated a femoral nerve paralysis. Neurology was consulted to evaluate the patient's loss of aforementioned motor ability. She was found to have no cerebellar dysfunction and full motor control of the left lower extremity. Evaluation of the right lower extremity was significant. She was found to have 0/5 hip flexion and 0/5 knee extension with an absent knee jerk reflex. Additionally, all distal lower extremity muscle groups were intact, with 5/5 dorsiflexion, plantarflexion, inversion, and eversion of the foot, as well as an intact ankle jerk reflex bilaterally. All the evidence pointed towards an injury to the femoral nerve, but specific care was taken during surgery to avoid sharp dissection at the level of the inguinal canal and the nerve, and therefore transection of the nerve was highly unlikely. Diagnostic MRI performed on post-operative day 14 revealed a fluid collection $7 \times 6 \times 1$ cm with the anterior aspect of the right iliacus (Fig. 3) which under different circumstances could be worrisome for abscess, but given the patient's benign clinical presentation (afebrile, no leukocytosis)

this was more consistent with inflammation and post-operative changes rather than infectious in origin. At post-operative day (POD) 4, patient began having some increased muscle strength in the affected leg. She was referred for inpatient rehabilitation and aggressive physical therapy for two weeks, and experienced significant improvement in muscle strength and mobility. No other sequelae from the surgery were noted at that time. Prednisone was started POD 21 for inflammation and swelling in the inguinal canal. She was discharged to a skilled nursing facility on POD 22. Electromyogram (EMG) performed 8 weeks after surgery showed mild slowed conduction velocity and minimal femoral nerve response, unable to exclude demyelinating neuropathy. Following discharge, the patient was followed closely in clinic. She was still actively participating in a rehabilitation program. At her 6-week post-operative clinic visit, she was ambulating with minimal aid from a walker. She is continuously being followed for any metastases as an indicator for prognosis, since her age itself is already a poor prognostic factor [6]. To monitor for any local recurrence, it was recommended that the patient be seen every 6 months for the first two years, with CT imaging of the chest, abdomen, and pelvis to check for any metastasis. After these two years, annual CT exams up to 5 years is appropriate. She is also following with her neurology team for management of the neuropraxia, and is scheduled for another EMG 6 months from the date of operation. Her clinical follow ups revealed significant motor clinical improvement and so far, her imaging studies did not show any evidence of local or systemic recurrence.

3. Discussion

Extensive discussion was held with the patient to discuss treatment options, and it was eventually agreed that the best course of treatment would be surgical resection, given the potential for malignancy and recurrence, as well as the tumor's likely poor response rate to chemotherapy [5]. Five-year survival following an R0 resection of a large retroperitoneal liposarcoma was found to be 85.7% compared to R1 resection at 33.3% [6], while recurrence of the tumor for patients undergoing R1 or R2 resection was as high as 96.7% [7]. No tissue biopsy before the surgery was indicated to rule out other pathologies due to the fact that this tumor was a primary tumor in the absence of distant metastases, as well as the resectable appearance of the mass on imaging [8]. Given her social history, the patient was advised to quit smoking before the operation, and she

also underwent cardiac clearance and pulmonary function testing to assess her risk. Risks and benefits, as well as alternative treatment options were discussed, including but not limited to bleeding (3%), surgical site infection (2–5%), incomplete resection (R2, 5%), recurrence (40–50%), possible need for adjuvant therapy (>50%), hernias (20%), bowel resections, and bowel resection related risks such as anastomotic leaks, need for an ostomy, as well as reoperation. She expressed her understanding at this point and agreed to proceed with surgical therapy. CT evaluation of the patient that initially discovered the mass did not show evidence of distant metastasis. Additionally, the mass did not appear to arise from any retroperitoneal organ structure (e.g. pancreas, adrenals, kidney, or duodenum). The patient also presented without B-symptoms (fever, chills, night sweats), thus making lymphoma an unlikely diagnosis. A gastrointestinal stromal tumor (GIST), arising from the interstitial cells of Cajal (ICC) was also a possibility, given its incidence as the most common soft tissue sarcoma affecting the GI tract [7]. Given the findings that there were no appreciable metastases, and the resectable appearance of the tumor, there was no indication for a tissue biopsy before resection, even for GIST [7], and the decision was made to take the patient to surgery for complete excision, to spare her from undergoing a separate biopsy procedure before surgery. Few pathologies present as a large, uniform mass in the retroperitoneum. Fibroadenoma, fibrosarcoma, lipoma, and liposarcoma are the major constituents of a large, uniform, retroperitoneal mass. Consideration was also made for gynecological in origin, however pelvic ultrasonography, CA-125, CEA, and HCG were negative.

To the best of our knowledge, neuropraxia has not previously been reported as a complication of resecting large retroperitoneal sarcomas. Great care was taken in the operating room to preserve as many neural structures as possible. However due to the Neuropraxia following resection of a retroperitoneal liposarcoma, Page 7 of 9 involvement of the ilioinguinal and genitofemoral nerves, tributary branches of these structures were sacrificed out of necessity to achieve a proper oncologic resection. The ilioinguinal nerve, a branch of L1, serves primarily a sensory function to the upper medial thigh, mons pubis, and labia majora in females. The genitofemoral nerve, from the upper L1 and L2 segments of the lumbar plexus, serves as both the sensory and motor arms of the cremasteric reflex which is more applicable in males than females. Sacrificing either of these nerves should not have any residual motor deficit as seen in this patient. Flexion of the hip and extension of the knee is controlled by numerous muscles, primarily the psoas, iliacus, rectus femoris, and sartorius. Of these muscles, the latter three have innervations from the femoral nerve. Given the close proximity of the mass to the nerve in the inguinal canal, as well as trauma from the blunt dissection and removal of the mass from the femoral triangle, it is then most likely that the etiology of this patient's neuropraxia is from femoral nerve manipulation. Since neither sharp instruments nor bovie was used in the dissection of mass from the femoral canal, it is unlikely that the femoral nerve was permanently damaged. A conservative course of treatment was taken in response to the patient's neuropraxia. Physical therapy was the mainstay of treatment, and an MRI was performed on postoperative day 14 after surgical staples were removed. The fluid collection seen on MRI was initially read as a possible abscess, but the patient's presentation did not correlate with this finding. Further discussion between surgeon and radiologist concluded that the collection was more consistent with inflammation and postoperative changes, which is important to note as it saved the patient an additional invasive procedure to drain the fluid, possibly further endangering the nerves. With regards to clinical radiology, good clinical judgement must be employed for the best benefit of the patient. While initial CT imaging and initial pathology reported the mass as a lipoma, clinical judgement was more suggestive of a

liposarcoma, which necessitates more aggressive treatment. A second expert review of the pathology at an outside institution found the tumor to be a low grade liposarcoma. Additionally, had the team acted on the MRI report of an abscess, the patient would likely have been subjected to placement of a drain by interventional radiology, which exposes the patient to another source of infection, bleeding, and other complications. Good clinical judgement was also exercised in this case, correlating the patient's clinical presentation to the imaging report, intraoperative findings and details of the procedure, a thorough postoperative clinical evaluation and appropriate work up in collaboration with other specialties was necessary to diagnose and treat this patient conservatively without any invasive, painful, and costly treatments and interventions.

4. Conclusion

Neurologic complications after resection of retroperitoneal masses are rare. However, when they occur, they can be very demoralizing and debilitating. To our knowledge, neuropraxia associated with resection of retroperitoneal liposarcoma has never been published before. Given this mass's extent through the inguinal canal, great care during dissection and resection as well as preservation of the nervous structure in the area are of utmost importance to reduce the patient's overall level of post-operative morbidity. Good clinical judgement based on the pre, intra and postoperative findings dictates the treatment approach and the ultimate outcome. Cases presenting with post-resection neurological sequelae without any known intraoperative nerve injury may respond very well to conservative treatment. Hence, it is very important to collaborate with Neurology and Physical Therapy to achieve best possible outcome.

Conflicts of interest

There is no conflict of interest.

Sources of funding

There is no external funding for research.

Ethical approval

No ethical approval was required in this study.

Consent

Written informed consent was obtained from the patient for publication of this case report and accompanying images. A copy of the written consent is available for review by the Editor-in-Chief of this journal on request.

Authors contribution

Nail Aydin, MD1 study concept or design, writing the paper, Data analysis and interpretation and corrections.

Stevenson Tsiao, MD1: Data collection and writing the paper.

Subhasis Misra, MD1 Data analysis and interpretation.

Guarantor

Nail Aydin MD FACS.

References

- [1] R. Siegel, K. Miller, A. Jemal, Cancer statistics, CA: Cancer J. Clin. 65 (1) (2015) 5–29, <http://dx.doi.org/10.3322/caac.21254>.

- [2] I. Francis, Retroperitoneal sarcomas, *Cancer Imaging* 5 (1) (2005) 89–94, <http://dx.doi.org/10.1102/1470-7330.2005.0019>.
- [3] G. Porter, N. Baxter, P. Pisters, Retroperitoneal sarcoma, *Cancer* 106 (7) (2006) 1610–1616, <http://dx.doi.org/10.1002/cncr.21761>.
- [4] A. MacNeill, A. Gronchi, R. Miceli, et al., Postoperative Morbidity after radical resection of primary retroperitoneal Sarcoma, *Ann. Surg.* (2017) (Epub ahead of print, PMID: 28394870).
- [5] K. Gemici, İ. Buldu, T. Acar, et al., Management of patients with retroperitoneal tumors and a review of the literature, *World J. Surg. Oncol.* 13 (1) (2015), <http://dx.doi.org/10.1186/s12957-015-0548-z>.
- [6] M. Milone, L. Pezzullo, G. Salvatore, et al., Management of high-grade retroperitoneal liposarcomas: personal experience, *Updates Surg.* 63 (2) (2011) 119–124, <http://dx.doi.org/10.1007/s13304-011-0061-z>.
- [7] P. Li, X. Huang, L. Chen, N. Liu, Y. She, X. Zhao, Prognostic factors predicting the postoperative survival period following treatment for primary retroperitoneal liposarcoma, *Chin. Med. J. (Engl.)* 128 (1) (2015) 85, <http://dx.doi.org/10.4103/0366-6999.147822>.
- [8] N. Valsangkar, A. Sehdev, S. Misra, T. Zimmers, B. O'Neil, L. Koniaris, Current management of gastrointestinal stromal tumors: surgery, current biomarkers, mutations, and therapy, *Surgery* 158 (5) (2015) 1149–1164, <http://dx.doi.org/10.1016/j.surg.2015.06.027>.
- [9] R.A. Agha, A.J. Fowler, A. Saeta, I. Barai, S. Rajmohan, D.P. Orgill, The scare statement: consensus-based surgical case report, *Int. J. Surg.* 34 (2016) 180–186.

Open Access

This article is published Open Access at sciedirect.com. It is distributed under the [IJSCR Supplemental terms and conditions](#), which permits unrestricted non commercial use, distribution, and reproduction in any medium, provided the original authors and source are credited.