

**Parkinsonism: a rare manifestation of craniopharyngioma**Mansour Parvaresh<sup>1</sup>, Maziar Azar<sup>2</sup>, Hossein Ghalaenovi<sup>1</sup>, Arash Fattahi<sup>3</sup>

<sup>1</sup> Assistant Professor, Neurosurgery ward of Rasool-e-Akram Hospital Complex, Department of Neurosurgery, Iran University of Medical Science, Tehran, Iran

<sup>2</sup> Associate Professor, Neurosurgery ward of Rasool-e-Akram Hospital Complex, Department of Neurosurgery, Iran University of Medical Science, Tehran, Iran

<sup>3</sup> Medical Doctor, Resident of Neurosurgery, Neurosurgery ward of Rasool-e-Akram Hospital Complex, Department of Neurosurgery, Iran University of Medical Science, Tehran, Iran

**Type of article:** Case report**Abstract**

Craniopharyngioma is a non-glial, non-malignant intracranial tumor of ectodermal origin, which arises from a remnant of Rathke's pouch. This tumor accounts for 5.6 to 13% of intracranial tumors in children. This paper discusses a case of craniopharyngioma in a five-year-old boy. An MRI scan of his brain showed a huge sella and supra sella cystic-solid lesion that had invaded the prepontine and interpeduncular cisterns, filling of 3rd ventricle and hydrocephalus. The patient operated via interhemispheric subfrontal through lamina terminalis and the tumor dissected from all part of brain stem and total resection achieved. After surgery Parkinsonism was worse for 3 days and levodopa started for 3 days. Parkinsonism was gone and after one week levodopa discontinued. This case practically implied that decompression of mass effect of tumor on brain stem and short-term management with levodopa can improve Parkinsonism due to midline compressive brain tumors without basal ganglia involvement.

**Keywords:** craniopharyngioma, parkinsonism, brain stem**1. Introduction**

Craniopharyngioma is a non-glial and non-malignant (World Health Organization grade I) intracranial tumor of ectodermal origin, which arises from a remnant of Rathke's pouch (1, 2). Craniopharyngioma is a common brain tumor in children, and it is the most common non-glial brain tumor in children (3). This type of tumor accounts for 5.6 to 13% of intracranial tumors in children (4). Endocrine dysfunction is responsible for most of the signs and symptoms of this condition. A few reports of Craniopharyngioma that presented by generalized Parkinsonism were found in the literature (5). In the case described here, the patient had major symptoms that suggested Parkinsonism and hydrocephalus due to compression of the midbrain and the diencephalon.

**2. Case Presentation***2.1. Clinical presentation*

A five-year-old boy was referred to us for tremors and rigidity, mostly in the upper limbs and head, vomiting, polydipsia, and polyuria that began three month earlier. Our examination showed a macrocephaly (more than 97 percentile) and bilateral papilledema. Visual acuity was not reliable because of lack of cooperation and the tremor of

**Corresponding author:**

Dr. Hossein Ghalaenovi, Neurosurgery ward of Rasool-e-Akram Hospital Complex, Department of Neurosurgery, Iran University of Medical Sciences, Tehran, Iran. Tel: +98.9124623806, Fax: +98.64352228. Email: hghalaenovi@yahoo.com

Received: February 01, 2015, Accepted: April 26, 2015, Published: June 05, 2015

© 2015 The Authors. This is an open access article under the terms of the Creative Commons Attribution-NonCommercial-NoDerivs License, which permits use and distribution in any medium, provided the original work is properly cited, the use is non-commercial and no modifications or adaptations are made.

the head. Although tremor and rigidity usually occur in upper limbs and head in such cases, the lower limbs were also affected in this case. The results of other neurological examinations were normal.

#### 2.2. Past history

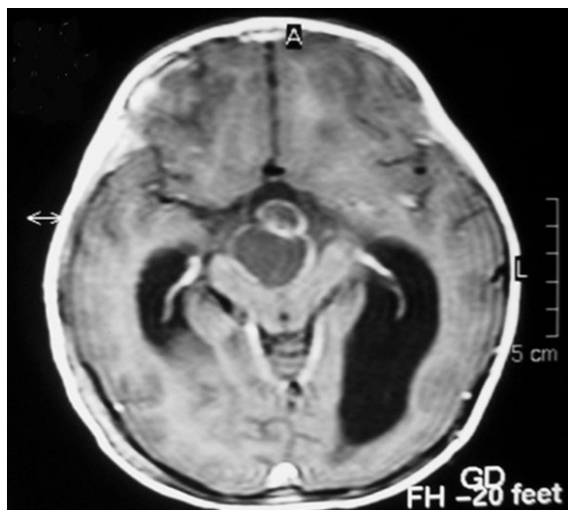
The patient in this case had no past history of any problems.

#### 2.3. Laboratory findings

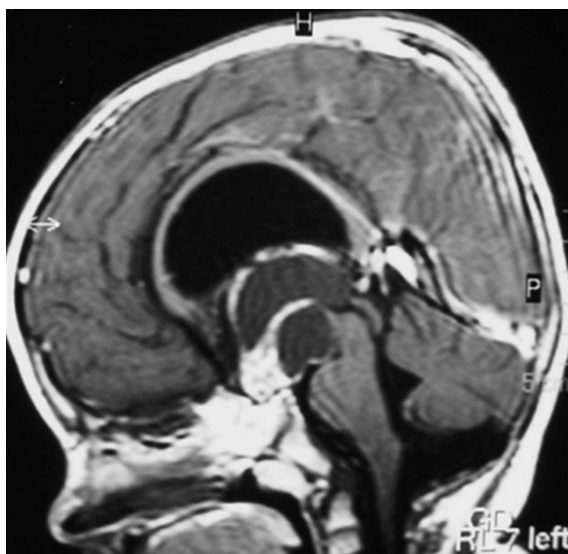
The laboratory findings showed a pituitary source of diabetes insipidus.

#### 2.4. Imaging

A CT scan of the brain showed a large sella and supra sellar lesion with calcification. An MRI scan of the brain showed a huge sella and supra sella cystic-solid lesion that had invaded the prepontine and interpeduncular cisterns, filling of 3<sup>rd</sup> ventricle and hydrocephalus. The injection of gadolinium showed some enhancement in different parts of the tumor (Figures 1 and 2).



**Figure 1.** Pre-operative axial MRI after the injection of gadolinium with partial enhancement: Widening of the cerebral peduncle in the midbrain and compressing of the brain stem can be seen.



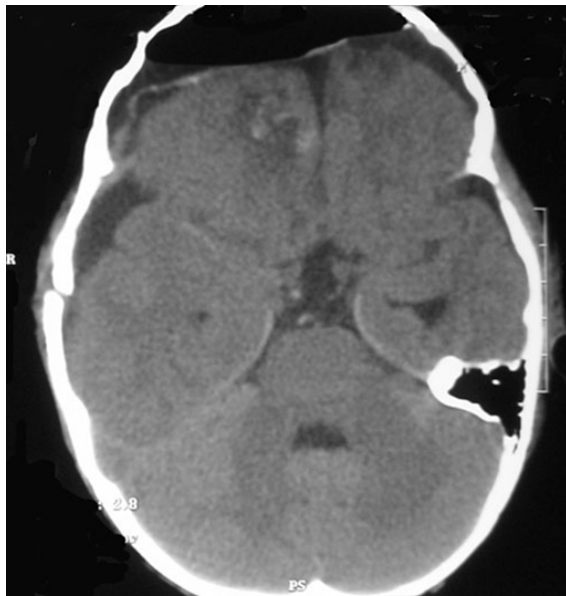
**Figure 2.** Preoperative, sagittal post-gadolinium injection MRI: The scan shows superior extension of the tumor with brainstem compression and displacement of the 3<sup>rd</sup> ventricle's floor.

### 2.5. Surgical intervention

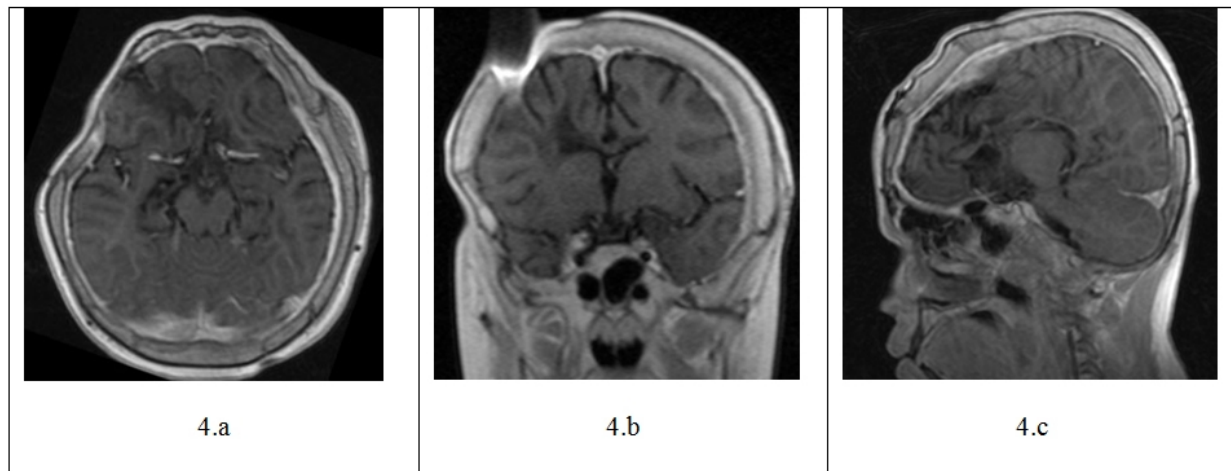
An operation was performed on the patient via entry through the interhemispheric subfrontal and the lamina terminalis, and the tumor was dissected from all parts of brain stem, achieving total resection.

### 2.6. Follow-up with the patient

After surgery, the patient's Parkinsonism was worse for three days, and the administration of levodopa was initiated. Within one week, the Parkinsonism was gone and levodopa was discontinued. Post-operative images showed total resection of the tumor and elimination of the compression of the brain stem (Figure 3). The follow-up physical examination showed no deficit and no presentation of Parkinsonism, and follow-up imaging 10 years after surgery showed that there was no recurrence (Figures 4a, 4b, and 4c).



**Figure 3.** Post-operative CT scan with no tumor residue and no compression of the brain stem



**Figure 4.** The follow up brain MRI with gadolinium injection, in axial(a), coronal(b) and sagittal views, showed no recurrence of the tumor

### 3. Discussion

Space-occupying lesions of brain, such as supratentorial and brainstem tumors, can produce secondary Parkinsonism (6, 7), but, in general, neoplasms are an uncommon cause of Parkinsonism (8-11). Between neoplasms, midline extrinsic tumors, such as craniopharyngiomas, are rarer than intrinsic and laterally-placed tumors (12). In the cases

addressed by Polyzoidis (1985) and in other literature, most patients with brain tumors and Parkinsonism have had meningiomas (5, 11, and 13).

When the symptoms and signs of craniopharyngioma occur in childhood, the presentation of this tumor with Parkinsonism is extremely rare. In the pertinent literature, only Voermans and coworkers reported a case of craniopharyngioma with delayed Parkinsonism, six months after radiotherapy. Their case was a 14-year-old female without symptoms of Parkinsonism at the initial manifestation, and they related this delayed tremor and rigidity to radiotherapy. They explained her situation as a dysfunction of the thalamus and globus pallidus due to focal encephalopathy resulting from post-radiation edema (14). Because our patient had an initial manifestation of secondary Parkinsonism and did not undergo radiotherapy, it is our opinion that other reasons must be considered to explain this association. Because this patient's tumor mainly compressed the midbrain and diencephalon, invaded the interpeduncular fossa, and divided the cerebral peduncles, we believe the pathology of Parkinsonism is rooted in the theory that states that the tumorous widening and compression of the midbrain, which contains the substantia nigra and dopaminergic system, can interfere with the dopaminergic system and cause Parkinsonism. Decompression may improve the symptoms and signs of this condition, allowing the patient to improve, as occurred in our patient. In our case, the patient's manifestations were bilateral and predominantly in the upper limbs. The pertinent literature indicates that secondary Parkinsonism usually has unilateral limb manifestations (13, 15, and 16). In Pramstaller's case report, the reason for the manifestation of bilateral Parkinsonism was a bilateral pallidal lesion (17). But, in our case, we think that the huge mass of the tumor in the midline location compressed the bilateral dopaminergic system and result in bilateral Parkinsonism without direct bilateral involvement of the basal ganglia.

Usually, secondary Parkinsonism due to brain tumors is not levodopa-responsive (5, 11). Dopamine agonists in Voermans' case resulted in minor improvement in the patient's motor functions, while, in our case, levodopa was administered postoperatively for one week, resulting in significant improvement in motor functions. Of course, it must be kept in mind that the improvement in our patient's motor functions could have been the result of the surgical decompression rather than the administration of levodopa.

#### **4. Conclusions**

We presented a rare case of craniopharyngioma presenting with secondary Parkinsonism. The importance of this case was that the Parkinsonism can be the major presentation of a patient with craniopharyngioma, although such an occurrence is rare. This case reminded us that the compression of the dopaminergic system in the brain stem can be responsible for Parkinsonism without direct basal ganglia involvement. It seems that relieving the pressure on the brain stem caused by the mass of the tumor and short-term management with levodopa can improve Parkinsonism in cases of midline compressive brain tumors without the involvement of the basal ganglia.

#### **Acknowledgment:**

This paper is published from the research for qualification of Dr. Arash Fattahi as a Neurological surgeon. The authors sincerely thank the staffs of Rasool-e-Akram hospital for their assistance in this study.

#### **Conflict of Interest:**

There is no conflict of interest to be declared.

#### **Authors' contributions:**

All of authors contributed to this project and article equally. All of authors read and approved the final manuscript.

#### **References**

1. Cohen M, Guger S, Hamilton J. Long term sequelae of pediatric craniopharyngioma - literature review and 20 years of experience. *Front Endocrinol (Lausanne)*. 2011; 2:81. doi: 10.3389/fendo.2011.00081 PMID: 22645511
2. Muller HL. Diagnostics, treatment, and follow-up in craniopharyngioma. *Front Endocrinol (Lausanne)*. 2011; 2:70. doi: 10.3389/fendo.2011.00070. PMID: 22654824
3. Bunin GR, Surawicz TS, Witman PA, Preston-Martin S, Davis F, Bruner JM. The descriptive epidemiology of craniopharyngioma. *J Neurosurg*. 1998 Oct; 89(4):547-51. doi: 10.3171/jns.1998.89.4.0547. PMID: 9761047
4. Schoenberg BS, Schoenberg DG, Christine BW, Gomez MR. The epidemiology of primary intracranial neoplasms of childhood. A population study. *Mayo Clin Proc*. 1976 Jan; 51(1):51-6. PMID:1249998

5. Yasuhara T, AT, Kambara H, Ichikawa T, Kurozumi K, Ono S, Miyoshi Y, Tokunaga K, Date I. Parkinsonism Related to Brain Tumors: A Case Report and Review of the Literature. *The Open Neurosurg J*. 2009; 2:4-7. doi: 10.2174/187652970090201004
6. Quinn N. Parkinsonism--recognition and differential diagnosis. *BMJ*. 1995 Feb 18; 310(6977):447-52. doi: 10.1136/bmj.310.6977.447. PMID: 7646647. PMCID: PMC2548823
7. Tolosa E, Wenning G, Poewe W. The diagnosis of Parkinson's disease. *Lancet Neurol*. 2006 Jan; 5(1):75-86. doi: 10.1016/S1474-4422(05)70285-4. PMID: 16361025
8. Choi KH, Choi SM, Nam TS, Lee MC. Astrocytoma in the third ventricle and hypothalamus presenting with parkinsonism. *J Korean Neurosurg Soc*. 2012 Mar; 51(3):144-6. doi: 10.3340/jkns.2012.51.3.144. PMID: 22639710. PMCID: PMC3358600
9. Duron E, Lazareth A, Gaubert JY, Raso C, Hanon O, Rigaud AS. Gliomatosis cerebri presenting as rapidly progressive dementia and parkinsonism in an elderly woman: a case report. *J Med Case Rep*. 2008; 2:53. doi: 10.1186/1752-1947-2-53. PMID: 18284707, PMCID: PMC2263063
10. Ho BL, Lieu AS, Hsu CY. Hemiparkinsonism secondary to an infiltrative astrocytoma. *Neurologist*. 2008 Jul; 14(4):258-61. doi: 10.1097/NRL.0b013e31816c43ea. PMID: 18617854
11. Polyzoidis KS, McQueen JD, Rajput AH, MacFadyen DJ. Parkinsonism as a manifestation of brain tumor. *Surg Neurol*. 1985 Jan; 23(1):59-63. doi: 10.1016/0090-3019(85)90161-2. PMID: 2981121
12. Bhatoe HS. Movement disorders caused by brain tumours. *Neurol India*. 1999 Mar; 47(1):40-2. PMID: 10339706
13. Husag L, Wieser HG, Probst C. [Extrapyramidal symptoms in meningiomas]. *Schweiz Arch Neurol Neurochir Psychiatr*. 1975; 116(2):257-79. PMID: 1153969
14. Voermans NC, Bloem BR, Janssens G, Vogel WV, Sie LT. Secondary parkinsonism in childhood: A rare complication after radiotherapy. *Pediatr Neurol*. 2006 Jun; 34(6):495-8. doi: 10.1016/j.pediatrneurol.2005.10.021. PMID: 16765832
15. Benincasa D, Romano A, Mastronardi L, Pellicano C, Bozzao A, Pontieri FE. Hemiparkinsonism due to frontal meningioma. *Acta Neurol Belg*. 2008 Mar; 108(1):29-32. PMID: 18575186
16. Krauss JK, Paduch T, Munding F, Seeger W. Parkinsonism and rest tremor secondary to supratentorial tumours sparing the basal ganglia. *Acta Neurochir (Wien)*. 1995; 133(1-2):22-9. doi: 10.1007/BF01404943. PMID: 8561031
17. Pramstaller PP, Salerno A, Bhatia KP, Prugger M, Marsden CD. Primary central nervous system lymphoma presenting with a parkinsonian syndrome of pure akinesia. *J Neurol*. 1999 Oct; 246(10):934-8. doi: 10.1007/s004150050485. PMID:10552241