



## Revision knee surgery techniques

Emmanuel Thienpont

- Revision total knee arthroplasty (rTKA) is a challenging, complex procedure. A comprehensive understanding of the anatomy, challenges and pitfalls is essential to achieve a good outcome for the patient.
- This review discusses the determinants of good outcomes of rTKA. These include, among other factors, the choice of the surgical approach, removal of the components, adequate reconstruction of the joint line and posterior condylar offset and the use of offset stems, as well as choosing the appropriate level of constraint.
- The modularity of many modern knee revision systems can help to address such issues as anatomical mismatch, gap balancing and malalignment.
- A well-planned surgical approach must be used in rTKA. A thorough understanding of related knee anatomy is essential.
- The incidence of joint-line elevation after rTKA is high. Contralateral radiographs, as well as algorithms based on the relationship between bony landmarks and the joint line, can help to reconstruct a physiological joint line during rTKA.
- Modularity added to systems, such as offset stems, are useful enhancements that may further improve the reconstruction of the anatomy.
- There are several options for managing the patella, with the best choice depending on the status of the patellar component and residual bone stock.

**Keywords:** revision total knee arthroplasty; replacement; surgical techniques

Cite this article: Thienpont E. Revision knee surgery techniques. *EFORT Open Rev* 2016;1: 233-238. DOI: 10.1302/2058-5241.1.000024.

### Introduction

Revision total knee arthroplasty (rTKA) is a challenging and complex procedure<sup>1,2</sup> from the initial surgical exposure to the component removal, bone stock restoration and implant selection.<sup>3,4</sup> As with primary TKA, the goals of rTKA are to achieve a well-aligned, well-balanced and pain-free

joint that has optimal patellofemoral articulation.<sup>2,5</sup> Here we discuss the different aspects of rTKA, highlighting the choices facing modern orthopaedic surgeons.

### Approaches in revision

Knee exposure in rTKA can be difficult, as dense scarring may penetrate into the deep fascial layers or even the underlying bone and may be accompanied by loss of elasticity or thickening of the capsular envelope. The latter – common in arthritic patients – may be worsened by TKA failure and guarding to avoid knee pain. The resultant limited stretching of the knee structures further reduces tissue elasticity. Infections, particulate debris and soft tissue trauma due to knee instability can also reduce tissue compliance.<sup>6</sup>

The risk of infection in rTKA is three to four times greater than that with primary TKA, due to the increased operative time, poor vascularisation of the tissues (soft as well as bone) resulting from multiple operations, previous wound-healing problems or scars and the increased age of the patients.<sup>6</sup> The risk of infection is even greater in immune-compromised patients and those with diabetes. Immune-compromised patients also have an increased risk of wound-healing complications, as well as skin sloughs due to the friable nature of their skin. Skin closure may consequently be difficult and often soft tissue coverage procedures are necessary.<sup>6</sup>

It is essential that a well-planned surgical approach is used in rTKA to avoid damaging important structures and achieve a good outcome,<sup>6,7</sup> which in turn requires a thorough understanding of related knee anatomy.<sup>7</sup> Special consideration must be given to conditions restricting the knee arc to less than 90° of flexion. It is also important not to compromise ligamentous support to both the tibiofemoral and patellofemoral articulations, as instability of either results in rTKA failure. By selecting the most appropriate exposure method, wound complications such as slough and/or iatrogenic knee instability can be avoided.<sup>6</sup>

There are a number of different exposures for stiff and scarred knees, the biggest challenge of all. The type of approach chosen by the surgeon should facilitate the joint reconstruction and not complicate it. Extended approaches to achieve wide exposure reduce surgical time and facilitate component removal, soft tissue balancing, bone reconstruction and long-stemmed component implantation.<sup>6</sup> However, sometimes simple excision of the scar tissue may

be enough to achieve adequate exposure.<sup>7</sup> Therefore, the surgeon involved in rTKA should have different options available in his surgical repertoire.

In the presence of one single previous incision, the skin incision for rTKA should incorporate previous incisions whenever possible. If there is more than one single previous incision, the most lateral one must be used. Whenever incorporation of a previous scar is not appropriate, there should be sufficient distance between the old and the new incisions. If only a part of a previous incision can be used, the intersection angle must be maximised and must be at least 60°. There should be at least a 2.5 cm to 8.0 cm skin bridge between the incisions. In the presence of multiple scars from surgeries that have been performed a long time previously, a mid-line approach is the least disruptive approach.<sup>8</sup>

#### *Medial parapatellar arthrotomy*

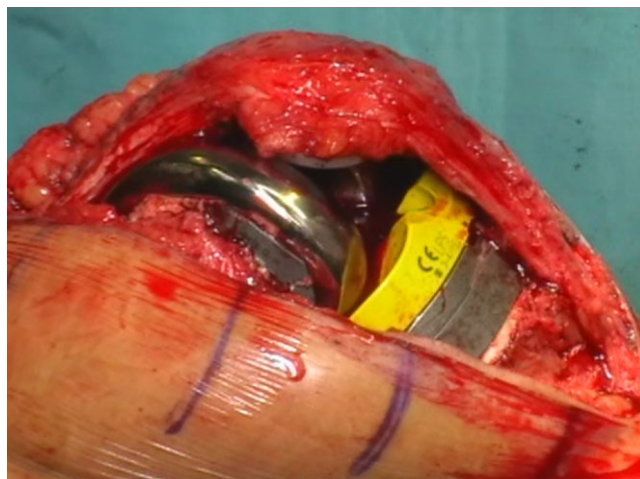
Medial parapatellar arthrotomy (Fig. 1) is the standard approach for rTKA and is used in more than 90% of cases. To achieve good visualisation, the incision should be extended more proximally into the quadriceps tendon, not within the boundaries of a minimally invasive technique. Caution should be applied to avoid compromising the patellar blood supply.

A deep medial dissection requires a medial release in extension, with the capsule removed under the extensor mechanism. The layer should be dissected bluntly and continued to the joint line to establish the medial gutter. This is repeated on the lateral side, with the pseudocapsule bluntly dissected, fibrous tissue removed from around the patella and any fibrous adhesions deep to the patella released. Following establishment of the lateral gutter, the lateral patellofemoral ligament is identified with the knee still in flexion. Flexing the knee slowly while externally rotating the tibia reduces stress on the extensor mechanism. The medial release may be continued posteriorly around the posteromedial corner of the tibia (Fig. 2).

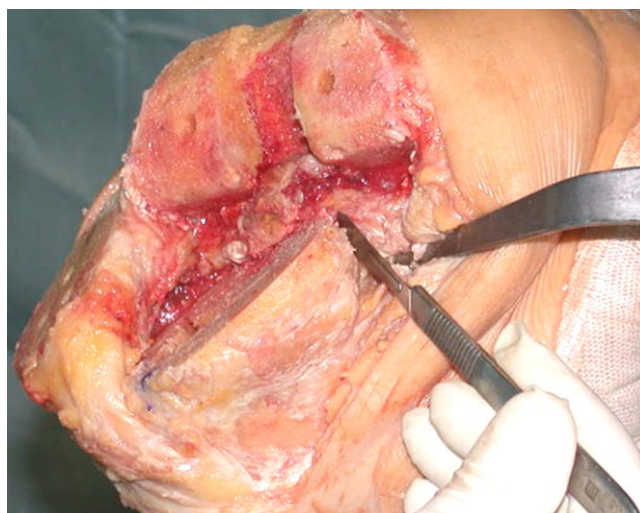In cases where the approach remains difficult, a lateral retinacular release may be considered, allowing easier patellar eversion or sliding it on the side. Removal of the modular polyethylene should be performed as a standard surgical step before extending the soft tissues releases necessary to open the joint.

#### *Quadriceps snip*

If adequate exposure is not achieved with medial parapatellar arthrotomy, a quadriceps snip may be performed.<sup>7</sup> This is typically used when greater exposure is required and involves continuing the arthrotomy in a superior and lateral direction at a 45° angle. This approach should be used to release tension on the extensor mechanism, and if more proximal exposure is needed. No changes are required to the post-operative routine. If performed carefully, there will be no additional morbidity.<sup>7</sup>



**Fig. 1** The medial parapatellar approach.



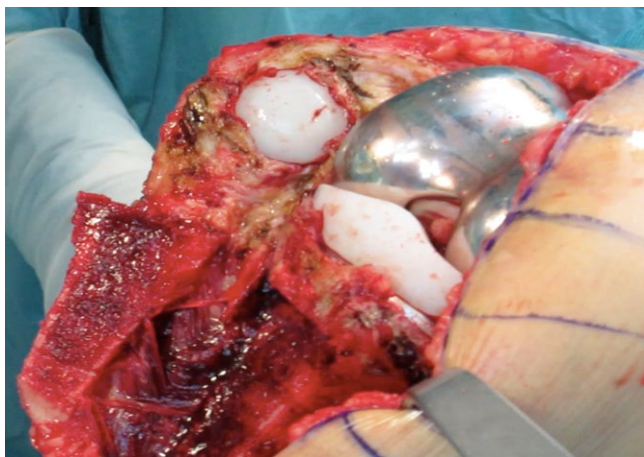
**Fig. 2** Posteromedial corner release.

#### *Quadriceps V-Y turndown*

If a quadriceps snip does not result in adequate exposure, a V-Y quadricepsplasty might be considered.<sup>9</sup> For this approach, the arthrotomy is continued in a distal lateral direction at 45°, combining the snip with an extensive lateral release. This approach is primarily used to lengthen the quadriceps tendon and realign the patella in cases with lateral subluxation. However, the knee must be immobilised post-operatively, with restricted flexion for six weeks. Rehabilitation may consequently be slow, causing extensor lag. Avascular necrosis of the patella because of devascularisation can be the predominant complication of this approach. Reports suggest that the approach can be used conservatively,<sup>7,10-12</sup> particularly when the quadriceps tendon needs to be lengthened,<sup>7</sup> thus reducing the chances of patellar devascularisation.

#### *Tibial tubercle osteotomy (TTO)*

This approach involves an 8 to 10 cm osteotomy down the medial side, with the periosteal hinge left in place laterally



**Fig. 3** Tibial tubercle osteotomy.

and wires or screws used to re-attach the osteotomy (Fig. 3). This approach is especially useful in patients with well-fixed tibial stems, patella baja or with important scarring of the anterolateral tibial area. It does not require a degree of immobilisation if the fixation is stable, but protection with a brace and crutches might be indicated. Typical complications are displacement and malunion of the TTO.

A study comparing V-Y quadricepsplasty and tibial tuberosity osteotomy found that the former was associated with a greater range of movement but a higher incidence of an extensor lag. By contrast, tibial tubercle osteotomy was associated with lower post-operative patient satisfaction.<sup>10</sup> There have, so far, been no prospective randomised studies comparing the different extensile exposures.<sup>7</sup>

## Component removal

Implant removal may be time-consuming and may result in severe bone loss or bone fracture, which can affect the type and quality of subsequent reconstruction. There are a number of tools available for implant removal, including hand instruments such as osteotomes, Gigli saws and punches, power instruments such as power saws, burrs and metal cutting instruments, and finally ultrasonic instruments, to remove the cement. These can aid efficient removal with little bone loss. Some implant systems may also include specific instruments to extract certain designs.<sup>13</sup>

Safe implant removal relies on adequate exposure, with particular attention paid to protecting the extensor mechanism, popliteal vascular structures and the collateral ligaments. Implants should be removed in the following order to allow better exposure for removal of the subsequent component: 1) tibial polyethylene insert; 2) femoral component; 3) tibial component; and (4) patellar component.<sup>13</sup>

Uncemented stems can be relatively straightforward to remove, although roughened or porous stems that are well-fitted may be more problematic. In contrast, well-fixed cemented stems can be very difficult to extract,<sup>14</sup> and may require a case-specific approach. In most cases, the interfaces

of the condylar portion of the tibial or femoral implant are divided, and the entire implant removed with the cement. If that is not possible, the implant may be disassembled at the condylar portion to allow separate extraction of the stem.<sup>13</sup>

## Reconstruction of the femur

Normal knee kinematics can be restored by balancing the soft tissues and the remaining bony anatomy,<sup>2</sup> primarily by re-establishing the correct joint-line position.<sup>15</sup>

Between 50% and 80% of rTKA patients have an elevated joint line,<sup>16,17</sup> and this is associated with lower clinical and functional outcomes such as anterior knee pain, patella baja and mid-flexion instability.<sup>2,16-19</sup> Patella baja causes limitation of flexion, increased wear, anterior knee pain and patellar tendon attrition, while mid-flexion laxity potentially results in progressive stretching and increased instability over time.<sup>2,20</sup>

Nevertheless, the maximum tolerated joint-line elevation has not been established. Clavé et al showed that after rTKA a joint-line elevation of more than 4 mm is associated with lower post-operative function.<sup>21</sup> On the other hand, Kowalczewski et al demonstrated that there is no significant impact on tibiofemoral joint kinematics during passive flexion/extension movement and squatting with a joint-line elevation of 4 mm, and collateral ligament elongation patterns are unaffected. They suggest that the clinical problems associated with joint-line elevation are related to either the patellofemoral joint or joint-line elevation of more than 4 mm.<sup>22</sup>

### Causes of joint-line elevation

Joint-line elevation is associated with proximalisation of the femoral component,<sup>16,17</sup> partly due to distal femoral bone loss. Another factor can be the under-sizing of the femoral component, as the posterior bone loss means that a smaller component is needed to achieve direct seating. The flexion space is therefore relatively large and can also become bigger than the extension space following component removal and joint debridement, as the capsuloligamentous structures used in extension are usually better preserved. A thicker insert may be used to fill the flexion space and the femoral component proximalised to increase the extension space. Use of a thicker polyethylene insert can achieve a stable and functional joint, albeit at the expense of an elevated joint line.<sup>23</sup>

### How to assess the proper joint line

It is difficult to identify the anatomical joint line in rTKA. However, the relationship between bony landmarks such as medial femoral epicondyle, lateral femoral epicondyle, fibular head and inferior patellar pole and the joint line have been described.<sup>2,20</sup> The joint line should, ideally, be approximately 30 mm distal to the medial femoral epicondyle, 25 mm distal to the lateral epicondyle, and 10 to 15 mm proximal to the fibular head, with all three landmarks palpable during rTKA. Using the Insall-Salvati ratio to identify the joint line is not as

accurate in rTKA as in primary TKA.<sup>17</sup> Contralateral knee radiographs may also be obtained to confirm the patient's normal joint line.<sup>2</sup> Joint-level planning can also be referenced off the old prosthesis or by the algorithm developed by Romero et al, based on the distance from medial and lateral condyles to the joint line (Fig. 4).<sup>24</sup> In cases of scarring over the medial epicondylar sulcus, a metal ruler may be passed under the medial collateral ligament until it reaches the ligamentous origin to help establish the joint line.<sup>2</sup>

#### Posterior femoral condylar offset

While restoration of the posterior femoral condylar offset (PCO) is important in TKA as it improves flexion stability and range of movement,<sup>25,26</sup> it is difficult during rTKR due to the loss of posterior femoral condylar bone.<sup>27</sup> This may result in under-sizing of the femoral component.<sup>23</sup> A thicker polyethylene insert is needed to balance the knee in both flexion and extension, which elevates the joint line.<sup>23</sup> However, the impact of PCO loss on outcomes in rTKR has not been established.<sup>27</sup>

#### Restoring the PCO and joint line

The PCO and joint line in flexion can be restored by using a larger femoral component, although this may result in soft tissue impingement and pain. An alternative is to move the femoral component posteriorly.<sup>28</sup> However, the anteroposterior position of the implant is dictated by the femoral stem, leading to anterior component seating and an increased flexion space.<sup>23</sup> A shorter cemented stem may be used, as this is less likely to force the femoral component anteriorly, which allows slight posterior positioning of the femoral component and slight flexion compensating for the wider flexion space.<sup>28</sup>

The flexion-extension space may be balanced by using couplers between the stem and the femoral component, or posteriorly offset femoral stems that restore the PCO. This should provide better flexion-extension soft tissue balance,<sup>29,30</sup> and allow the femoral component to be displaced more posteriorly to balance the flexion gap and avoid joint-line elevation.<sup>28</sup>

### Reconstruction of the tibia

The use of stems to supplement component fixation in rTKA has been shown to improve outcomes and survival,<sup>31-33</sup> as they allow bone defects to be bypassed, deficient bone to be off-loaded and stresses on damaged bone to be reduced. However, controversy remains regarding the optimal method of stem fixation. Good long-term results have been reported for cemented stems,<sup>34-36</sup> which provide immediate fixation with less intramedullary canal intrusion. Cemented stems are less constrained by bone geometry, and they can be shorter than uncemented stems because they do not need to engage the diaphysis.<sup>37</sup> Cemented stems can be difficult to remove, however, and may increase stress-shielding in the surrounding bone.

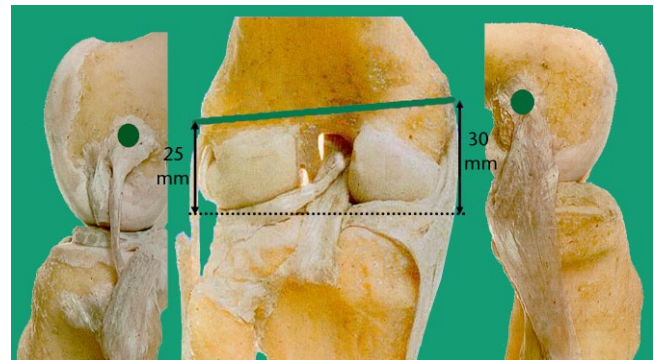


Fig. 4 Distance from the epicondyles to the joint line.

Press-fit diaphyseal stems with cement in the metaphyseal portion of the implant have also been used.<sup>38</sup> Structural integrity of both the femoral and tibial canals is required to use a press-fit stem, and the mechanical limb axis should coincide with the intramedullary canals. Longer stems can also affect component positioning, particularly in the tibia due to the posteromedial position of the canal relative to the plateau. Large metaphyseal bone defects and soft tissue laxity are well-suited to longer, uncemented press-fit stems.

It should be noted, however, that cement fixation is typically required for wide, osteopaenic intramedullary canals, and press-fit stems cannot deliver antibiotics in cases of infection. Older cobalt chromium stems have also been associated with end-of-stem pain.

Uncontained tibial and femoral defects, defined as defects that have no peripheral cortical rim, typically require modular block augments, bulk allograft, or metal metaphyseal sleeves or cones for reconstruction.<sup>39</sup>

One of the biggest problems with the proximal tibia in revision surgery is that the bone geometry determines the alignment of the stem. Any deformity of the proximal tibia may therefore not allow for standard press-fit stem components. In such situation, offset stems in the tibia are indicated as they match the anatomical deformity. They therefore can help to improve the positioning of the tibial component. Offset stems can also be helpful to reconstruct large cavitory defects and, along with stem extensions and metal cones, they may eliminate the need for extensive bone grafting or structural allograft in rTKA. Using cones can give a better metaphyseal fixation allowing surgeons to utilise shorter stems and remain within correct limb alignment.<sup>40</sup>

### Constraint

When selecting revision prosthesis, it is preferable to use the smallest amount of constraint while achieving the most stable joint possible.<sup>2,41-44</sup> Signs of instability should be determined pre-operatively via clinical and radiological examination, alongside examination under anaesthesia just prior to surgery.<sup>2</sup>

The majority of rTKAs can be performed using a posterior stabilised implant, and posterior cruciate-retaining knees are rarely used (except for revisions of unicompartmental arthroplasty). If stability cannot be achieved with a posterior stabilised implant, a more constrained device, such as non-linked constrained (condylar constrained knee [CCK]) or rotating hinge (RH) designs, are preferred.<sup>2</sup> CCK systems are generally indicated in patients with intermediate ligamentous insufficiency and moderate bone loss, whereas RH systems are required in the presence of complete disruption of the ligaments and/or severe bone loss.<sup>45</sup>

## The patella in revision

While many surgeons consider patellar resurfacing a routine part of TKA,<sup>8</sup> others do not routinely resurface the patella.<sup>46</sup> During rTKA, the aim of patella management is to provide a painless articulation and optimal function of the extensor mechanism,<sup>47</sup> while avoiding complications and morbidity. Although the complexity of rTKA means that patellar management is of lesser importance,<sup>5</sup> there is still debate about how best to manage the patella during rTKA.<sup>48,49</sup> The options available depend on the status of the patellar component and residual bone stock,<sup>48,49</sup> and include: retention of a pre-existing patellar component; primary or revision patellar resurfacing, patellar component resection with patellar bony shell retention (patelloplasty), patellectomy, patellar bone reconstruction via bone grafts, augmentation with a porous metal implant, and Gull wing osteotomy.<sup>5,50</sup>

## Conclusions

It is essential that rTKA begins with adequate exposure, followed by careful removal of the implants in an order that minimises damage to the bone stock and optimises the outcome of the procedure. Re-establishment of the joint line should be achieved as far as possible, with the target line planned before starting rTKA. Stems are advised for tibial reconstruction, as they improve outcome, although the choice of stem should be made on an individual basis. Constraint should be kept to a minimum, while aiming for maximum possible stability, and there are a number of options for patellar management.

In summary, rTKA remains a complex procedure, and special attention should be paid to each step of the process in order to achieve the best possible outcome and the goals of a well-aligned, well-balanced and pain-free joint.

### AUTHOR INFORMATION

University Hospital Saint Luc, Brussels, Belgium.

Correspondence should be sent to E. Thienpont, Department of Orthopaedic Surgery, University Hospital Saint Luc, Avenue Hippocrate 10, 1200 Brussels, Belgium.

Email: emmanuel.thienpont@uclouvain.be

### CONFLICT OF INTEREST

ET reports financial support outside the current work in the form of lecture fees and royalties from Depuy Synthes, Medacta and Zimmer Biomet.

### FUNDING

The author or one or more of the authors have received or will receive benefits for personal or professional use from a commercial party related directly or indirectly to the subject of this article.

### LICENCE

© 2016 The author(s)

This article is distributed under the terms of the Creative Commons Attribution-Non-Commercial 4.0 License (<http://www.creativecommons.org/licenses/by-nc/4.0/>) which permits non-commercial use, reproduction and distribution of the work without further permission provided the original work is attributed.

### REFERENCES

- Hamilton DF, Howie CR, Burnett R, Simpson AH, Patton JT.** Dealing with the predicted increase in demand for revision total knee arthroplasty: challenges, risks and opportunities. *Bone Joint J* 2015;97-B:723-8. PMID:26033049.
- McDermott B.** Restoration of stability, maintaining joint line, gap balancing, and constraint selection. In: Bono JV, Scott RD, eds. *Revision total knee arthroplasty*. New York: Springer, 2005:145-51.
- Sheng PY, Konttinen L, Lehto M, et al.** Revision total knee arthroplasty: 1990 through 2002. A review of the Finnish arthroplasty registry. *J Bone Joint Surg [Am]* 2006;88:1425-30. PMID:16818966.
- Stuart MJ, Larson JE, Morrey BF.** Reoperation after condylar revision total knee arthroplasty. *Clin Orthop Relat Res* 1993;(286):168-73. PMID:8425340.
- Naudie DDR, Bell TH, McAuley J.** Technique of revision in total knee arthroplasty: the patella. In: Bonnin M, Amendola NA, Bellemans J, MacDonald SJ, Menetrey J, eds. *The knee joint*. Paris: Springer-Verlag, 2012:1039-48.
- Engh GA.** Exposure options for revision total knee arthroplasty. In: Bono JV, Scott RD, eds. *Revision total knee arthroplasty*. New York: Springer, 2005:63-75.
- Gooding C, Garbus D, Masri BA.** Extensile surgical exposures for revision total knee replacement. In: Scott W, ed. *Surgery of the knee*. Fifth ed. Philadelphia: Churchill Livingstone; 2011:1320-6.
- Daines BK.** Avoiding wound complications in total knee replacement. In: Hirschmann M, Becker R, eds. *The unhappy total knee replacement A comprehensive review and management guide*. Berlin: Springer, 2015:117-26.
- Della Valle CJ, Berger RA, Rosenberg AG.** Surgical exposures in revision total knee arthroplasty. *Clin Orthop Relat Res* 2006;446(446):59-68. PMID:16672873.
- Barrack RL, Smith P, Munn B, Engh G, Rorabeck C.** The Ranawat Award. Comparison of surgical approaches in total knee arthroplasty. *Clin Orthop Relat Res* 1998;(356):16-21. PMID:9917662.
- Scott RD, Siliski JM.** The use of a modified V-Y quadricepsplasty during total knee replacement to gain exposure and improve flexion in the ankylosed knee. *Orthopedics* 1985;8:45-8. PMID:4094951.
- Trousdale RT, Hanssen AD, Rand JA, Cahalan TD.** V-Y quadricepsplasty in total knee arthroplasty. *Clin Orthop Relat Res* 1993;(286):48-55. PMID:8425367.
- Berry DJ.** Removal of the femoral and tibial components for revision total knee arthroplasty. In: Bono JV, Scott RD, eds. *Revision Total Knee Arthroplasty*. New York: Springer, 2005:76-80.

- 14. Cameron HU.** Difficult implant retrieval: a case report. *Can J Surg* 1989;32:220-21. PMID:2653598.
- 15. Lotke PA, Ecker ML.** Influence of positioning of prosthesis in total knee replacement. *J Bone Joint Surg [Am]* 1977;59:77-9. PMID:833180.
- 16. Partington PF, Sawhney J, Rorabeck CH, Barrack RL, Moore J.** Joint line restoration after revision total knee arthroplasty. *Clin Orthop Relat Res* 1999;(367):165-71. PMID:10546611.
- 17. Porteous AJ, Hassaballa MA, Newman JH.** Does the joint line matter in revision total knee replacement? *J Bone Joint Surg [Br]* 2008;90:879-84. PMID:18591596.
- 18. Laskin RS.** Joint line position restoration during revision total knee replacement. *Clin Orthop Relat Res* 2002;(404):169-71. PMID:12439257.
- 19. Hofmann AA, Kurtin SM, Lyons S, Tanner AM, Bolognesi MP.** Clinical and radiographic analysis of accurate restoration of the joint line in revision total knee arthroplasty. *J Arthroplasty* 2006;21:1154-62. PMID:17162175.
- 20. Stiehl JB, Abbott BD.** Morphology of the transepicondylar axis and its application in primary and revision total knee arthroplasty. *J Arthroplasty* 1995;10:785-9. PMID:8749761.
- 21. Clavé A, Le Henaff G, Roger T, Maisongrosse P, Mabit C, Dubrana F.** Joint line level in revision total knee replacement: assessment and functional results with an average of seven years follow-up. *Int Orthop* 2016. PMID:26744167.
- 22. Kowalczewski JB, Labey L, Chevalier Y, Okon T, Innocenti B, Bellemans J.** Does joint line elevation after revision knee arthroplasty affect tibio-femoral kinematics, contact pressure or collateral ligament lengths? An in vitro analysis. *Arch Med Sci* 2015;11:311-18. PMID:25995746.
- 23. Bellemans J.** Restoring the joint line in revision TKA: does it matter? *Knee* 2004;11:3-5. PMID:14967319.
- 24. Romero J, Seifert B, Reinhardt O, Ziegler O, Kessler O.** A useful radiologic method for preoperative joint-line determination in revision total knee arthroplasty. *Clin Orthop Relat Res* 2010;468:1279-83. PMID:19890683.
- 25. Bellemans J, Banks S, Victor J, Vandenneucker H, Moemans A.** Fluoroscopic analysis of the kinematics of deep flexion in total knee arthroplasty. Influence of posterior condylar offset. *J Bone Joint Surg [Br]* 2002;84:50-53. PMID:11837832.
- 26. Malviya A, Lingard EA, Weir DJ, Deehan DJ.** Predicting range of movement after knee replacement: the importance of posterior condylar offset and tibial slope. *Knee Surg Sports Traumatol Arthrosc* 2009;17:491-8. PMID:19139846.
- 27. Clement ND, Hamilton DF, Burnett R.** A technique of predicting radiographic joint line and posterior femoral condylar offset of the knee. *Arthritis* 2014;2014:121069.
- 28. Innocenti M, Matassi F, Carulli C, Soderi S, Villano M, Civinini R.** Joint line position in revision total knee arthroplasty: the role of posterior femoral off-set stems. *Knee* 2013;20:447-50. PMID:23790671.
- 29. Brilhault JM, Ries MD.** Posteriorly offset femoral component to restore anteroposterior position of the distal femur in revision total knee arthroplasty. *J Arthroplasty* 2011;26:214-7. PMID:20570092.
- 30. Mahoney OM, Kinsey TL.** Modular femoral offset stems facilitate joint line restoration in revision knee arthroplasty. *Clin Orthop Relat Res* 2006;446(446):93-8. PMID:16672877.
- 31. Bertin KC, Freeman MA, Samuelson KM, Ratcliffe SS, Todd RC.** Stemmed revision arthroplasty for aseptic loosening of total knee replacement. *J Bone Joint Surg [Br]* 1985;67:242-8. PMID:3980534.
- 32. Bourne RB, Finlay JB.** The influence of tibial component intramedullary stems and implant-cortex contact on the strain distribution of the proximal tibia following total knee arthroplasty. An in vitro study. *Clin Orthop Relat Res* 1986;208:95-99. PMID:3720148.
- 33. Brooks PJ, Walker PS, Scott RD.** Tibial component fixation in deficient tibial bone stock. *Clin Orthop Relat Res* 1984;184:302-308. PMID:6705360.
- 34. Fehring TK, Odum S, Olekson C, Griffin WL, Mason JB, McCoy TH.** Stem fixation in revision total knee arthroplasty: a comparative analysis. *Clin Orthop Relat Res* 2003;416:217-24. PMID:14646764.
- 35. Murray PB, Rand JA, Hanssen AD.** Cemented long-stem revision total knee arthroplasty. *Clin Orthop Relat Res* 1994;309:116-23. PMID:7994949.
- 36. Mabry TM, Vessely MB, Schleck CD, Harmsen WS, Berry DJ.** Revision total knee arthroplasty with modular cemented stems: long-term follow-up. *J Arthroplasty* 2007;22(6)(Suppl 2):100-5. PMID:17823026.
- 37. Baldini A, Balato G, Franceschini V.** The role of offset stems in revision knee arthroplasty. *Curr Rev Musculoskelet Med* 2015;8:383-9. PMID:26373769.
- 38. Parsley BS, Sugano N, Bertolusso R, Conditt MA.** Mechanical alignment of tibial stems in revision total knee arthroplasty. *J Arthroplasty* 2003;18(7)(suppl 1):33-6. PMID:14560408.
- 39. Daines BK, Dennis DA.** Management of bone defects in revision total knee arthroplasty. *Instr Course Lect* 2013;62:341-8. PMID:23395039.
- 40. Radnay CS, Scuderi GR.** Management of bone loss: augments, cones, offset stems. *Clin Orthop Relat Res* 2006;446(446):83-92. PMID:16672876.
- 41. Hartford JM, Goodman SB, Schurman DJ, Knoblick G.** Complex primary and revision total knee arthroplasty using the condylar constrained prosthesis: an average 5-year follow-up. *J Arthroplasty* 1998;13:380-7. PMID:9645517.
- 42. Scuderi GR.** Revision total knee arthroplasty: how much constraint is enough? *Clin Orthop Relat Res* 2001;392:300-5. PMID:11716400.
- 43. Bugbee WD, Ammeen DJ, Engh GA.** Does implant selection affect outcome of revision knee arthroplasty? *J Arthroplasty* 2001;16:581-5. PMID:11503117.
- 44. Cuckler JM.** Revision total knee arthroplasty: how much constraint is necessary? *Orthopedics* 1995;18:932-6.
- 45. Vasso M, Beaufile P, Schiavone Panni A.** Constraint choice in revision knee arthroplasty. *Int Orthop* 2013;37:1279-84. PMID:23700251.
- 46. Pakos EE, Ntzani EE, Trikalinos TA.** Patellar resurfacing in total knee arthroplasty. A meta-analysis. *J Bone Joint Surg [Am]* 2005;87:1438-45. PMID:15995109.
- 47. Garcia RM, Kraay MJ, Conroy-Smith PA, Goldberg VM.** Management of the deficient patella in revision total knee arthroplasty. *Clin Orthop Relat Res* 2008;466:2790-7. PMID:18712583.
- 48. Rand JA.** Treatment of the patella at reimplantation for septic total knee arthroplasty. *Clin Orthop Relat Res* 2003;(416):105-9. PMID:14646747.
- 49. Maheshwari AV, Tsailas PG, Ranawat AS, Ranawat CS.** How to address the patella in revision total knee arthroplasty. *Knee* 2009;16:92-7. PMID:18819807.
- 50. Vince KG, Roidis N, Blackburn D.** Gull-wing sagittal patellar osteotomy in total knee arthroplasty. *Tech Knee Surg* 2002;1:106-12.