



■ FOOT & ANKLE

Assessing risk of damage to posterior ankle structures during total ankle arthroplasty

**C. J. Callaghan,
J. C. McKinley**

*From Department of
Anatomy, Edinburgh
Medical School, The
University of Edinburgh,
Edinburgh, UK*

Aims

Arthroplasty has become increasingly popular to treat end-stage ankle arthritis. Iatrogenic posterior neurovascular and tendinous injury have been described from saw cuts. However, it is hypothesized that posterior ankle structures could be damaged by inserting tibial guide pins too deeply and be a potential cause of residual hindfoot pain.

Methods

The preparation steps for ankle arthroplasty were performed using the Infinity total ankle system in five right-sided cadaveric ankles. All tibial guide pins were intentionally inserted past the posterior tibial cortex for assessment. All posterior ankles were subsequently dissected, with the primary endpoint being the presence of direct contact between the structure and pin.

Results

All pin locations confer a risk of damaging posterior ankle structures, with all posterior ankle structures except the flexor hallucis longus tendon being contacted by at least one pin. Centrally-aligned transcortical pins were more likely to contact posteromedial neurovascular structures.

Conclusion

These findings support our hypothesis that tibial guide pins pose a considerable risk of contacting and potentially damaging posterior ankle structures during ankle arthroplasty. This study is the first of its kind to assess this risk in the Infinity total ankle system.

Cite this article: *Bone Jt Open* 2021;2-7:503–508.

Keywords: osteoarthritis, arthroplasty, iatrogenic, injury, infinity, wright

Introduction

Specialist foot and ankle surgeons receive at least 29,000 ankle osteoarthritis cases per year in the UK.¹ Ankle arthrodesis has been the historical treatment of choice for end-stage ankle osteoarthritis. However, the popularity of total ankle arthroplasty (TAA) is increasing, with the Infinity total ankle system (Wright Medical Technology, USA) currently being the most commonly used ankle arthroplasty system in the UK.²⁻⁴ A systematic review found that between 23% and 60% of patients who underwent TAA reported residual hindfoot pain.⁵ There are many potential reasons for ongoing pain; implant design, size, malalignment, and ligament imbalance are variables that are likely to be important. Perioperative

complications such as infection, nerve or tendon injury, heterotopic ossification, malleolar fracture, impingement, and adjacent joint arthritis are also likely to contribute to residual pain.

Articles looking at the outcome of ankle arthroplasties have been criticized for the inconsistency in the reporting of complications and adverse outcomes. A classification of complications has been proposed and tools have been developed to standardize reporting.⁶⁻⁸ The focus on articles has been mainly directed at the lifespan of the arthroplasty and risk of requiring revision surgery. However, there are a wide range of other potential complications that are important to record and make the patient aware of.⁹

Correspondence should be sent to Christopher J Callaghan; email: s1426087@sms.ed.ac.uk

doi: 10.1302/2633-1462.27.BJO-2021-0057.R1

Bone Jt Open 2021;2-7:503–508.




Fig. 1

This figure demonstrates exposing the anterior ankle joint; a) and installing all relevant transcortical pins (b to d). 1) Ankle joint; 2) rotation guide slide; 3) medial gutter fork; 4) distal most pin; 5) rotation guide pointer; 6) alignment frame; 7) distal pin sleeve; 8) proximal pin sleeve; 9) distal most pin; 10) lateral-distal pin; 11) lateral-proximal pin; 12) central-distal pin; 13) medial-distal pin; 14) central-proximal pin; and 15) medial-proximal pin. These images were acquired with appropriate consent in accordance with the Human Tissue Act 2006.

Damage to posterior ankle structures is a well-recognized complication in ankle arthroplasty, and damage to the tibial nerve and posteromedial tendon has been reported in several series and case reports.¹⁰⁻¹³ The reported rates of intraoperative nerve injury in the literature is variable and varies from 1.8% and 21% but the involved nerve, mechanism of injury, and investigations performed is not often recorded.^{12,14-17} Injury to the posteromedial structures is generally recognized as being due to the saw cut, with one study recommending that the posterior extent of the cut should be performed slowly, and by using repeated smaller excursions of the saw.¹³ Most modern ankle arthroplasty systems use anterior-posterior directed transcortical

pins through the tibia to secure the cutting block. These pins are placed in the metaphysis of the distal tibia where the cortex is thin and tactile feedback to the surgeon is reduced. As a result, it is easy to inadvertently place the pins too deeply into the soft tissues in the posterior ankle. We hypothesized that these pins pose a considerable risk of damaging posterior ankle soft tissue structures if inserted too deeply. The aims of this study are to carry out the preparation steps for ankle arthroplasty in five right-sided cadaveric ankles with all transcortical pins inserted through the posterior cortex, then dissecting the posterior ankle to assess contact between structure and pin.

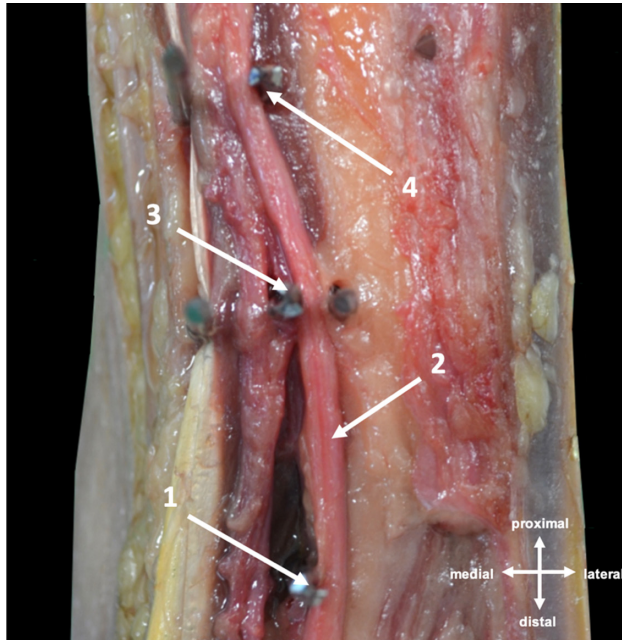


Fig. 2

Distal-most, central-proximal, and central-distal tibial pins making direct contact with the tibial nerve. This image was taken from the posterior aspect of a right-sided cadaveric ankle. 1) Distal-most pin; 2) tibial nerve; 3) central-distal pin; and 4) central-proximal pin. These images were acquired with appropriate consent in accordance with the Human Tissue Act 2006.

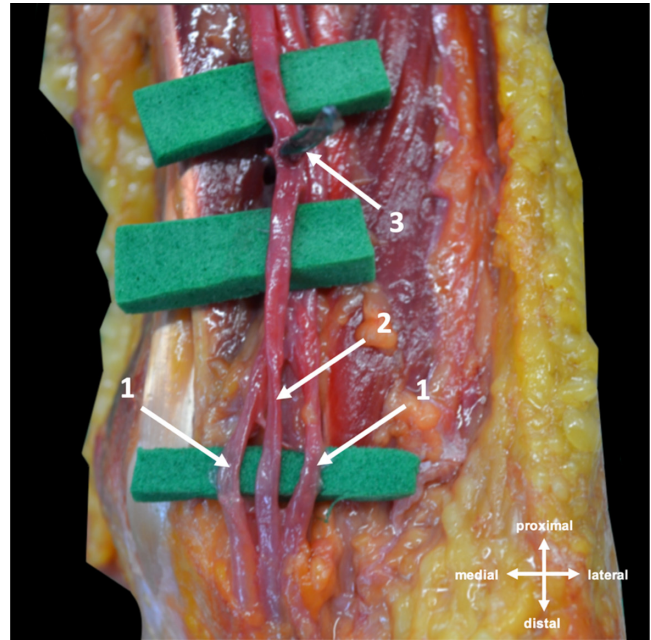


Fig. 3

Distal-most pin causing gross structural damage to the tibialis posterior artery. This image was taken from the posterior aspect of a right-sided cadaveric ankle. 1) Tibialis posterior veins; 2) tibialis posterior artery; and 3) distal most pin. These images were acquired with appropriate consent in accordance with the Human Tissue Act 2006.

Methods

All anatomical specimens were obtained in accordance with the Human Tissue Act 2006, and all appropriate ethical approval and informed consent was obtained. A total of five right-sided fresh-frozen cadaveric legs, with knee and foot intact, were obtained from five female cadavers with an average age of 78.4 years (54 to 101). Exclusion criteria consisted of outward signs of lower limb deformity, soft tissue damage, and previous trauma or injury. All transcortical pins were inserted in an appropriately licensed teaching establishment by the author (JCM), who regularly performs ankle arthroplasties. These transcortical pins were inserted using the Infinity total ankle system and the operative protocol produced by the supplier.¹⁸ The steps carried out to insert these 3.2 mm and 2.4 mm pins are summarized in Figure 1. All pins were inserted well past the posterior cortex of the tibia and left in situ, so that they could be later dissected out. This was to reproduce a scenario where the pins were inadvertently inserted too deeply. All pins were inserted under power, using a standard wire driver. This procedure was repeated for all five cadaveric specimens.

All posterior ankles were dissected within an appropriately licensed teaching establishment by the author (CJC). Each cadaveric specimen was placed in the prone position and the skin was reflected from approximately the level of the proximal pins to the level of the calcaneus. The Achilles tendon was then identified and transected

at the site of attachment on the calcaneus, and reflected proximally beyond the level of the proximal pins. The superficial fascia was then removed and the tibial nerve, tibialis posterior artery, tibialis posterior veins, tibialis posterior tendon, flexor digitorum longus tendon, and flexor hallucis longus tendon were then identified by dissecting the tarsal tunnel and tracing each structure proximally towards the level of the proximal pins. Once traced, each structure was meticulously dissected to expose their relation to the pins involved in this study. This was repeated for all five anatomical specimens. Each pin was observed to assess whether it made direct physical contact with the aforementioned posterior ankle structures. It was recorded if each pin had caused any puncturing or severing injury to any anatomical structure. This was repeated for each anatomical specimen. All observations were made with the presence of an independent second observer to increase the reliability of results, consisting of anatomy demonstrators, MSc students, and MBChB students.

All cadaveric images were taken with a Nikon D3100 14.2-megapixel DX format DSLR Nikon F-mount camera with a Nikon AF-S DX NIKKOR 18 to 55 MM F/3.5 to 5.6 G VR lens. These images were taken with appropriate consent in accordance with the Human Tissue Act 2006.

Results

The tibial nerve was contacted in four of five specimens but there were no signs of gross structural damage to

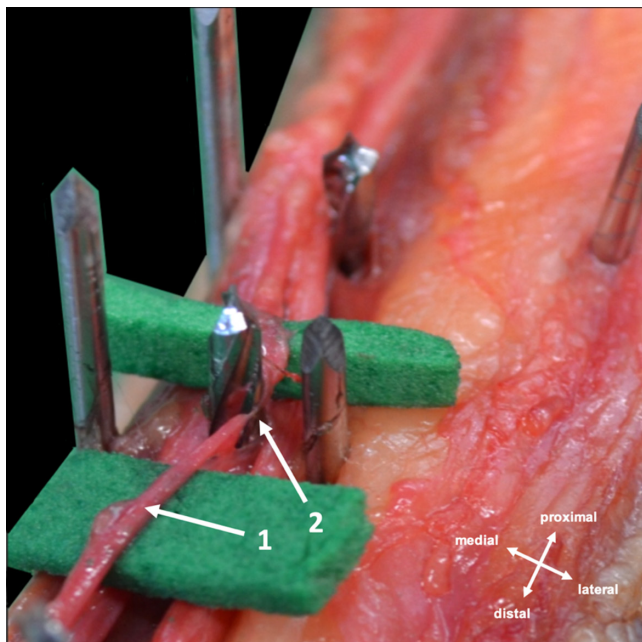


Fig. 4

Central-distal pin causing gross structural damage to one of the tibialis posterior veins. This image was taken from the posterior aspect of a right-sided cadaveric ankle. 1) Tibialis posterior vein; and 2) central-distal pin. These images were acquired with appropriate consent in accordance with the Human Tissue Act 2006

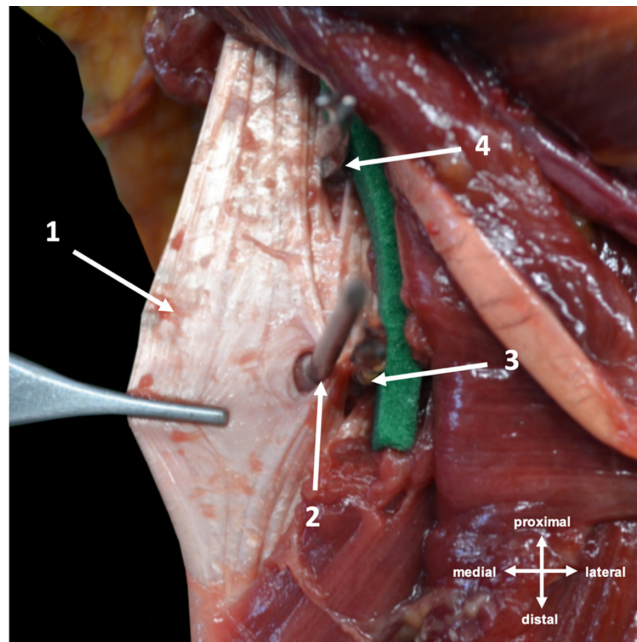


Fig. 5

Medial-distal, central-proximal, and central-distal pins causing gross structural damage to the tibialis posterior tendon. This image was taken from the posterior aspect of a right-sided cadaveric ankle. 1) tibialis posterior tendon; 2) medial-distal pin; 3) central-distal pin; and 4) central-proximal pin. These images were acquired with appropriate consent in accordance with the Human Tissue Act 2006.

the tibial nerve. Figure 2 shows a representative image of contact between the tibial nerve and multiple pins. The tibialis posterior artery was contacted in four of five specimens and the tibialis posterior veins were contacted in four of five specimens. Among all incidences of contact between the tibial pins and the tibialis posterior vasculature, three of 19 showed physical signs of gross structural damage. Figures 3 and 4 show representative images of tibial pins causing gross structural damage to the tibialis posterior artery and tibialis posterior veins respectively. The tibialis posterior tendon was contacted by tibial pins in all five specimens. Among all incidences of contact between the tibial pins and tibialis posterior tendon, 11 of 14 showed physical signs of gross structural damage. Figure 5 shows multiple tibial pins causing gross structural damage to the tibialis posterior tendon. The flexor digitorum longus tendon was contacted in two of five specimens. There were no instances of gross structural damage to the flexor digitorum longus tendon. The flexor hallucis longus tendon did not show any incidence of contact with tibial pins. It was found that the tibial pins aligned with the anatomical axis of the tibia were more likely to contact neurovascular posterior ankle structures. These pins included the distal-most, central-proximal, and central-distal pins. Table I summarizes all instances of contact with the neurovascular and tendinous structures in the posterior ankle by pin location.

Discussion

These findings support our hypothesis that tendinous and neurovascular structures in the posterior ankle are at risk from transcortical pins when performing an ankle arthroplasty, and is the first of its kind to assess this risk in the Infinity total ankle system. These findings are similar to those obtained in a similar study using the Inbone II TAA system (Wright Medical).¹⁹ It is well known that the posterior structures are at risk when performing the saw cuts during a TAA, but we believe that the risks from the pins are less appreciated. Our finding that transcortical pins inserted at the approximate midline of the tibia conferred the highest risk of contacting a posteromedial neurovascular structure is interesting as this is the part of the tibia where most surgeons would aim to place their pins. The Infinity total ankle system gives the options to alternatively place these guide pins medially or laterally, which our results suggest may be safer locations for transcortical pin insertion. We were unable to accurately measure the distance from the posterior tibial cortex to the structures. An MRI study showed that at the level of the tibial cut the tibial nerve and artery were between 2 mm to 6 mm from the posterior surface of the tibia, but did not describe their proximity more proximally.²⁰ Future research could aim to further describe the precise proximity of these anatomical structures from posterior tibial cortical bone at these key pin insertion locations.

Table 1. Each result is represented as the proportion of each pin included in the study that made contact with the relevant anatomical structure.

Structure	Pin location						
	Medial			Central		Lateral	
	Distal-most	Proximal	Distal	Proximal	Distal	Proximal	Distal
TN	3/5	0/3	0/4	3/5	3/5	1/2	1/3
TPA	3/5	0/3	0/4	3/5	4/5	0/2	0/3
TPV	4/5	1/3	0/4	1/5	2/5	0/2	0/3
TPT	0/5	1/3	2/4	5/5	5/5	1/2	0/3
FDL	0/5	2/3	1/4	0/5	0/5	0/2	0/3
FHL	0/5	0/3	0/4	0/5	0/5	0/2	0/3

FDL, flexor digitorum longus tendon; FHL, flexor hallucis longus tendon; TN, tibial nerve; TPA, tibialis posterior artery; TPT, tibialis posterior tendon; TPV, tibialis posterior veins.

Tactile feedback is the method most commonly used by surgeons to ensure that the guidepins are not placed too deeply. However, the posterior cortex of the tibia is relatively thin at the level of the distal guidepins; therefore, the feedback is reduced, particularly in elderly bone.

An image intensifier is now used routinely when carrying out an ankle arthroplasty. One of the strengths of the Infinity arthroplasty system is the design of the jigs to achieve reproducible image intensifier views and ensure correct alignment. We feel that it is important to use the image intensifier in the lateral view when placing the pins to avoid placing them inappropriately too deeply. We feel that although this will increase the radiation exposure, this is likely to be minimal given that multiple images are taken throughout the procedure to achieve alignment and position. Another possible way of mitigating guide-pin protrusion would be the use of patient-specific instrumentation to measure required guide-pin depth prior to surgery. With the increased use of preoperative CT scans, this would be feasible, but we believe that simply an awareness of the potential risk and using an image intensifier could avoid this complication.

Despite the tibial nerve showing no signs of gross structural damage by pin contact during this study, it should be appreciated that it is possible that the tibial nerve could sustain microscopic or even thermal damage that would not be appreciated through direct observation. It should be noted that the nerve was in contact with a pin in four out of the five specimens. In addition, tethering of one of the posterior structures by a wire could potentially lead it to be more susceptible to damage by an osteotome or saw as a result of the increased tension. We hope that these observations will make surgeons appreciate this risk of iatrogenic injury to posterior ankle structures during this step of an ankle arthroplasty. How this iatrogenic damage relates to the eventual clinical outcome is uncertain as there are many factors which can contribute to the success of an ankle arthroplasty. However, we believe that damage to any of the posterior structures could potentially lead to

a poor outcome. Damage to a nerve can lead to unpredictable consequences ranging from altered sensation to severe neurogenic pain. Damage to a blood vessel could lead to excessive postoperative swelling and pain. It is theoretically possible that injury to a vein could be a contributing factor to the development of a deep vein thrombosis. Injury to a tendon could lead to loss of function, tenosynovitis, or pain.

In summary, this study found that tibial guidance pins used in ankle arthroplasty carry a considerable risk of making direct contact with neurovascular and tendinous structures in the posterior ankle if inadvertently inserted too deeply. It is not clear what the direct clinical effect of this would be, but it is important to eliminate any potential factors that could detrimentally affect outcome. We feel that an increased awareness of the potential for guidewires to cause injury is important. We encourage surgeons to take particular care during this step, and to use the image intensifier to check the wire positioning.



Take home message

- All pin locations confer a risk of damaging posterior ankle structures, with central pins more likely to contact posteromedial neurovascular structures.

- This is the first study to assess this risk in the Infinity Total Ankle System.

References

1. Goldberg AJ, MacGregor A, Dawson J, et al. The demand incidence of symptomatic ankle osteoarthritis presenting to foot & ankle surgeons in the United Kingdom. *Foot*. 2012;22(3):163–166.
2. Hendrickx RP, Stufkens SA, de Bruijn EE, Sierevelt IN, van Dijk CN, Kerkhoffs GM. Medium- to long-term outcome of ankle arthrodesis. *Foot Ankle Int*. 2011;32(10):940–947.
3. Pugely AJ, Lu X, Amendola A, Callaghan JJ, Martin CT, Cram P. Trends in the use of total ankle replacement and ankle arthrodesis in the United States Medicare population. *Foot Ankle Int*. 2014;35(3):207–215.
4. National Joint Registry. Most commonly used ankle component brands. https://reports.njrcentre.org.uk/ankles-primary-procedures-components/A08v1NJR?reportid=7B68E9C7-8CB8-4D94-AA33-EE32E821EBCE&defaults=DC__Reporting_Period__Date_Range=%22MAX%22,H__R__Filter__Implant_Type_Name=%22Ankle%20-%20Talar%22 (date last accessed 25 June 2021).
5. Gougoulias N, Khanna A, Maffulli N. How successful are current ankle replacements?: a systematic review of the literature. *Clin Orthop Relat Res*. 2010;468(1):199–208.

6. **Glazebrook MA, Arsenault K, Dunbar M.** Evidence-based classification of complications in total ankle arthroplasty. *Foot Ankle Int.* 2009;30(10):945–949.
7. **Mercer J, Penner M, Wing K, Younger ASE.** Inconsistency in the reporting of adverse events in total ankle arthroplasty. *Foot Ankle Int.* 2016;37(2):127–136.
8. **Vander Griend RA, Younger ASE, Buedts K, et al.** Total ankle arthroplasty: Minimum follow-up policy for reporting results and guidelines for reporting problems and complications resulting in reoperations. *Foot Ankle Int.* 2017;38(7):703–704.
9. **Clough TM, Alvi F, Majeed H.** Total ankle arthroplasty: what are the risks?: a guide to surgical consent and a review of the literature. *Bone Joint J.* 2018;100-B(10):1352–1358.
10. **Peters PG, Miller SD.** Flexor hallucis longus tendon laceration as a complication of total ankle arthroplasty. *Foot Ankle Int.* 2013;34(1):148–149.
11. **Bejjanki NK, Moulder E, Al-Nammari S, Budgen A.** Tarsal tunnel syndrome as a complication of total ankle Arthroplasty: a case report. *Foot Ankle Int.* 2008;29(3):347–350.
12. **Lee KB, Cho SG, Hur CI, Yoon TR.** Perioperative complications of HINTEGRA total ankle replacement: our initial 50 cases. *Foot Ankle Int.* 2008;29(10):978–984.
13. **Myerson MS, Mroczek K.** Perioperative complications of total ankle arthroplasty. *Foot Ankle Int.* 2003;24(1):17–21.
14. **Primadi A, Xu H-X, Yoon T-R, Ryu J-H, Lee K-B.** Neurologic injuries after primary total ankle arthroplasty: prevalence and effect on outcomes. *J Foot Ankle Res.* 2015;8(1):55.
15. **Knecht SI, Estin M, Callaghan JJ, et al.** The Agility total ankle arthroplasty. Seven to sixteen-year follow-up. *J Bone Joint Surg Am.* 2004;86-A(6):1161–1171.
16. **Rippstein PF, Huber M, Coetzee JC, Naal FD.** Total ankle replacement with use of a new three-component implant. *J Bone Joint Surg Am.* 2011;93-A(15):1426–1435.
17. **Zaidi R, Cro S, Gurusamy K, et al.** The outcome of total ankle replacement: A systematic review and meta-analysis. *Bone Joint J.* 2013;95-B(11):1500–1507.
18. **No authors listed.** INFINITY total ankle system surgical technique. http://www.wrightmedia.com/ProductFiles/Files/PDFs/011938_EN_LR_LE.pdf (date last accessed 25 June 2021).
19. **Reb CW, McAlister JE, Hyer CF, Berlet GC.** Posterior ankle structure injury during total ankle replacement. *J Foot Ankle Surg.* 2016;55(5):931–934.
20. **Cadden A, Quinn A, Daniels T.** Posterior anatomy of the ankle and relationship to total ankle arthroplasty – MRI analysis. *Orthopaedic Proceedings.* 2018;94-B(Suppl_XXIII).

Author information:

- C. J. Callaghan, BSc(Hons), MSc, Student
- J. C. McKinley, MBChB, FRCS(Orth), Supervisor
The University of Edinburgh, Edinburgh Medical School, Edinburgh, UK.

Author contributions:

- C. J. Callaghan: Contributed to the research, Wrote and revised the manuscript.
- J. C. McKinley: Contributed to the research, Revised the manuscript.

Funding statement:

- No benefits in any form have been received or will be received from a commercial party related directly or indirectly to the subject of this article.

ICMJE COI statement:

- J. C. McKinley reports that the institution received money from Wright Medical for follow-up of ankle arthroplasty patients in a trial, and receiving payments for lecturing in May 2018, both of which is unrelated to this work.

Acknowledgements:

- The authors would like to acknowledge all anatomy demonstrators, MSc students, and MBChB students for their assistance in being independent secondary observers while gathering results.

© 2021 Author(s) et al. This is an open-access article distributed under the terms of the Creative Commons Attribution Non-Commercial No Derivatives (CC BY-NC-ND 4.0) licence, which permits the copying and redistribution of the work only, and provided the original author and source are credited. See <https://creativecommons.org/licenses/by-nc-nd/4.0/>